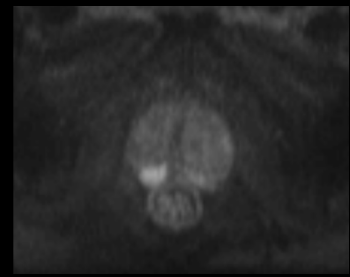


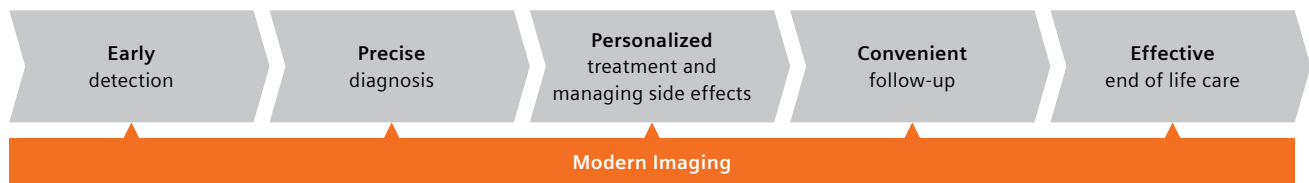
MR imaging in prostate cancer care



Today, MRI is reaching maturity in its ability to manage prostatic disease. As well as helping to detect prostate cancer earlier and deliver more precise diagnoses, MR imaging can reduce harm to patients by allowing men with negative MRI findings to avoid unnecessary biopsies.

Beyond detection and diagnosis, precision imaging also has a significant role to play in managing patients with diagnosed cancer. This can include smart and targeted imaging-guided treatments, efficient follow-ups, and effective monitoring of therapy results in patients with advanced prostate cancer.

Prostate cancer care pathway¹



Patient comfort and efficiency with no need for endorectal coils

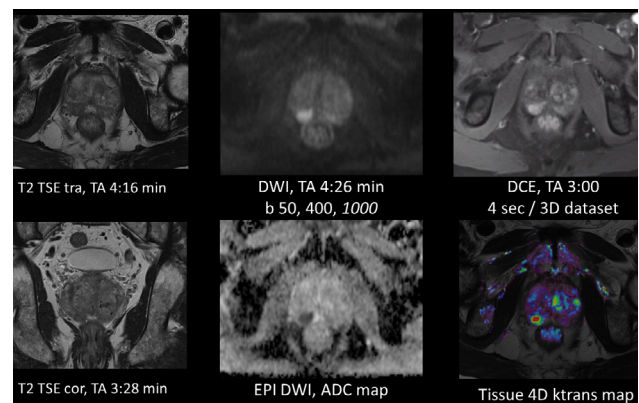
According to the recommendation of the generally established PI-RADS v2 guidelines for prostate MRI, “contemporary 1.5T scanners that employ a relatively high number of external phased array coil elements and RF channels (e.g. 16 or more)” can be used routinely for prostate MRI with no need for an endorectal coil. Our entire fleet of contemporary MRI scanners fulfill this requirement with Tim 4G coil technology, providing a pelvic array with at least 18 active elements (12 integrated spine coil elements + 6 body array coil elements) and up to 36 elements (18 integrated spine coil elements + 18 body array coil elements) in the relevant FOV. In addition to increasing patient comfort and acceptance, the convenience of not using an endorectal coil accelerates patient preparation and benefits the medical staff involved. With the shortest MRI systems on the market,



our MAGNETOM portfolio allows you to examine anxious and/or claustrophobic patients while keeping their head outside the bore at all times.

Efficient MR imaging performed with no endorectal coil and in less than 15 minutes serves a triage test to avoid unnecessary biopsies

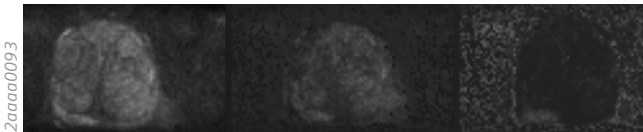
A core prostate imaging protocol typically involves T2-weighted scans in at least two planes, diffusion-weighted imaging, and dynamic contrast-enhanced imaging. As shown below, all relevant contrasts can be acquired in about 15 minutes acquisition time. You can therefore examine a patient in a slot lasting between 20 and 25 minutes.



Images courtesy of Benson Radiology, Australia

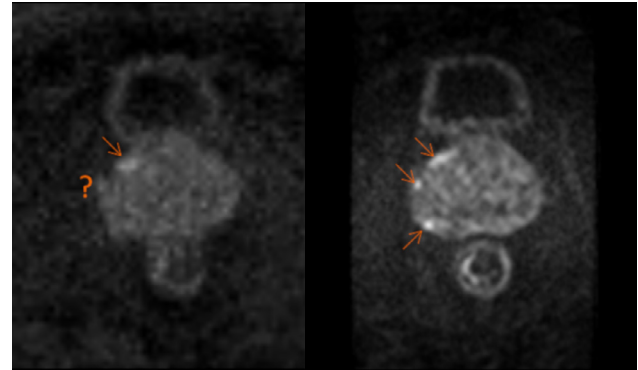
Increased lesion conspicuity and shorter acquisition time with calculated high b-values

The automated calculation of high b-value images up to $b=5000 \text{ s/mm}^2$ is a standard feature on MAGNETOM MRI scanners and enables increased lesion conspicuity in DWI. Studies show that the diagnostic value is comparable to measured high b-value images. Calculated high b-values can therefore considerably reduce scan times.



Clinical case with a subtle finding in b800 images, with b2000 and b3500 (from left to right). Due to benign prostate hyperplasia (BPH) tissue with considerable diffusion restriction, a lesion in the peripheral zone cannot be differentiated objectively from the BPH areas. At higher b-values, the BPH is more suppressed, clearly indicating a strong diffusion-restricted area in the peripheral zone.

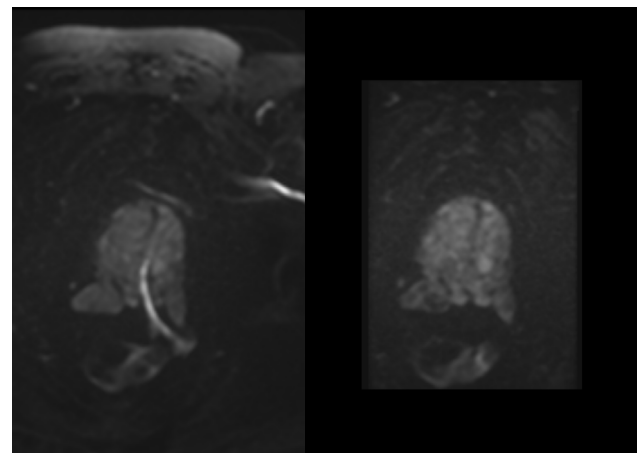
Images courtesy of Mercy Private Radiology, Australia



Direct comparison of conventional DWI (b 50, 1000, 1500, ADC, $2.1 \times 2.1 \times 3 \text{ mm}^3$, TA 3:23 min) (left) and ZOOMit^{PRO2} (b 50, 1000, 1500, ADC, $0.95 \times 0.95 \times 3 \text{ mm}^3$, TA 3:29 min) (right) shows improved visibility of small pinpoint lesions close to the capsule.

Higher robustness toward susceptibility artifacts, i.e. with hip replacements

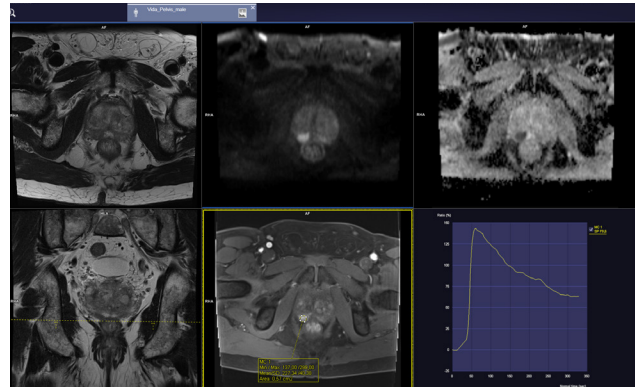
ZOOMit^{PRO2} is a new method for performing robust, high-resolution DWI of the prostate. It enables zoomed FOVs and high resolution scanning for improved lesion conspicuity in DWI at both 1.5T and 3T. In addition, the special acquisition scheme of ZOOMit^{PRO} helps to minimize artifacts caused by frequency offsets and inhomogeneities in the presence of hip or other metal implants¹; a frequent problem in the group of men undergoing prostate MRI.



Conventional DWI (b 50, 1000, $2.0 \times 2.0 \times 3 \text{ mm}^3$, TR/TE 3700 / 87 ms, TA 4:40 min) with severe artifact caused by hip replacement on the left side (left); high-resolution DWI at 1.5T with b 50, 1000, $1.8 \times 1.8 \times 3 \text{ mm}^3$, TR/TE 4100 / 80 ms and 4:28 min acquisition time using ZOOMit^{PRO2} (right).

syngo.MR Prostate reading and reporting

The standard *syngo*.MR Prostate workflow enables streamlined and comprehensive reading of multiparametric prostate MRI cases. All data is presented in a clearly arranged hanging protocol, enabling synchronized viewing and analysis of the case with, for instance, mean curve analysis or dynamic display of contrast-enhanced series. A PI-RADS v2-compliant finding dialogue standardizes the documentation of findings.



Findings

MR Prostate 2

ROI1 0.88 cm²

Details MR Prostate 2

Type MR Prostate

Region PZpm

Laterality Right

Finding Site Apical

T2W 4

DWI 4

DCE +

EPE No

PI-RADS 4

Index Lesion Yes

Current

Seminal Vesicles

R

AS AS

TZa TZa

TZp TZp

PZa PZa

PZpl PZpl

CZ CZ

Base

AS AS

TZa TZa

TZp TZp

PZa PZa

PZpl PZpl

PZpm PZpm

Mid

AS AS

TZa TZa

TZp TZp

PZa PZa

PZpl PZpl

PZpm PZpm

Apex

AS AS

TZa TZa

TZp TZp

PZa PZa

PZpl PZpl

PZpm PZpm

Urethra

Overall Rating

Comment

Marker Tools

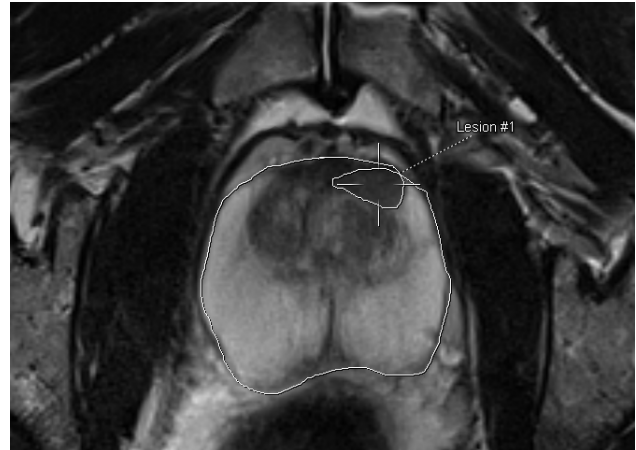
ROI Circle

ROI Freehand

Biopsy Line

syngo.MR Prostate Biopsy support

MR/US-fusion biopsies typically require proper segmentation of the organ in the MR images so that the images can be fused with real-time ultrasound information during the biopsy procedure. This often means extra work for the radiologist, who has to manually contour the prostate at a dedicated workplace. To remove this mundane step from the workflow, we offer an automated segmentation of the prostate as a standard tool within the syngo.MR Prostate workflow⁴. This allows you to export the prostate contours and the manually indicated lesion locations as a guide for the urologist during biopsy.



Learn more!

See one physician's experience with Profound Medical's TULSA in this interactive white paper.

"As patients and doctors demand more options for non-invasive treatments, the use of the MRI bore in image-guided procedures is likely to grow."⁵

—Joseph Busch, MD

Busch Center's TULSA Procedure program is the result of strong partnerships between medical technology companies and clinicians.

Click to read white paper

MR guided non-invasive prostate cancer treatment

Busch Center pioneers in-bore treatment using MAGNETOM Skyra



Dr. Joseph J. Busch, Jr.
Busch Center in Alpharetta, GA, USA

¹<http://www.prostate.org.au/awareness/further-detailed-information/understanding-prostate-cancer-treatments-and-side-effects/understanding-surgery-for-prostate-cancer/introduction/>

²WIP – work in progress the product is currently under development and is not for sale in the US and in other countries. Its future availability cannot be ensured.

³The MRI restrictions (if any) of the metal implant must be considered prior to patient undergoing MRI exam. MR imaging of patients with metallic implants brings specific risks. However, certain implants are approved by the governing regulatory bodies to be MR conditionally safe. For such implants, the previously mentioned warning may not be applicable. Please contact the implant manufacturer for the specific conditional information. The conditions for MR safety are the responsibility of the implant manufacturer, not of Siemens.

⁴Requires syngo.via VB40².

⁵The outcomes and statements provided by customers of Siemens Healthineers are unique to each customer's setting. Since there is no "typical" hospital and many variables exist (e.g., hospital size, case mix, and level of service/technology adoption), there can be no guarantee that others will achieve the same results.

Siemens Healthineers Headquarters

Siemens Healthcare GmbH
Henkestr. 127
91052 Erlangen, Germany
siemens-healthineers.com

USA

Siemens Medical Solutions USA, Inc.
Healthcare
40 Liberty Boulevard
Malvern, PA 19355-9998, USA
siemens-healthineers.us