# MAGNETOM Verio – An Initial Indian Experience

**Dr. Sumita Kundu, M.D., DMRD; Dr. S. K. Sharma M.D.**

*Consultant Radiologists, EKO MRI Centre, Kolkata, India*

## Introduction

The MR unit of our institute, EKO MRI Centre, was established in 1992 with a 1 Tesla System. A 1.5 Tesla unit was subsequently added in response to increasing patient load and demand for MRI. When we found it necessary to further enhance our services we replaced the 1 Tesla unit with a 3 Tesla MRI. MAGNETOM Verio with its unique equation of 70 cm + 3T + Tim (Total imaging matrix) was our unanimous choice.
One of the main features that helped us decide in favour of MAGNETOM Verio is its wide bore (70 cm) which was unthinkable in the 3T MRI segment.
In the past few months we have had several instances where we have benefited from this wide bore system. Not only were we able to accommodate more obese patients, but also patients with deformities, which prevented them from lying straight in the bore. Patients with conditions like ankylosing spondylosis; kyphosis etc. could be comfortably positioned for scanning. In fact we have been able to scan patients even in semi-reclining position with good image quality. Several patients who have been claustrophobic in other MRI scanners were more compliant in the Verio and rarely has there been an instance of abandoning the scan due to patient discomfort.
The Tim technology complimented with iPAT (integrated Parallel Acquisition Technique) has enabled us to significantly cut down our scan time and increase patient throughput. This has facilitated us to perform whole-body metastasis screening with a reasonable scan time, which in itself is an advantage as many of these patients, particularly those with skeletal metastasis, are in pain and not able to tolerate long scan times.
We have used the MAGNETOM Verio to scan patients from head to toe. The high signal-to-noise ratio (SNR) of 3T MRI with a wide bore magnet along with Tim technology has certainly made MR scanning easier for us and more comfortable for our patients. We have been able to achieve excellent results in musculoskeletal, neuro and body MRI and have faced no problems in scanning patients of various age groups and physical habitus.
The following are examples of patients who have been part of our initial interesting experience on the MAGNETOM Verio system.

## Case 1: Villous Adenoma

### Patient history

A 61-year-old male presented with a history of intermittent bleeding per rectum and mucoid stool since 3 years. Per rectal examination was suggestive of a large polypoid mass at the anterior wall of the rectum with unknown upper extent. There is a history of polypectomy in the anal region about 12 years back.

### Image findings

The rectum is distended and shows a well defined space occupying lesion (SOL) with frond-like projections from a central core. The SOL shows hypointense signal in T1 and T2-weighted images while the central core is markedly hypointense in T2-weighted images with enhancement in the contrast enhanced study. The

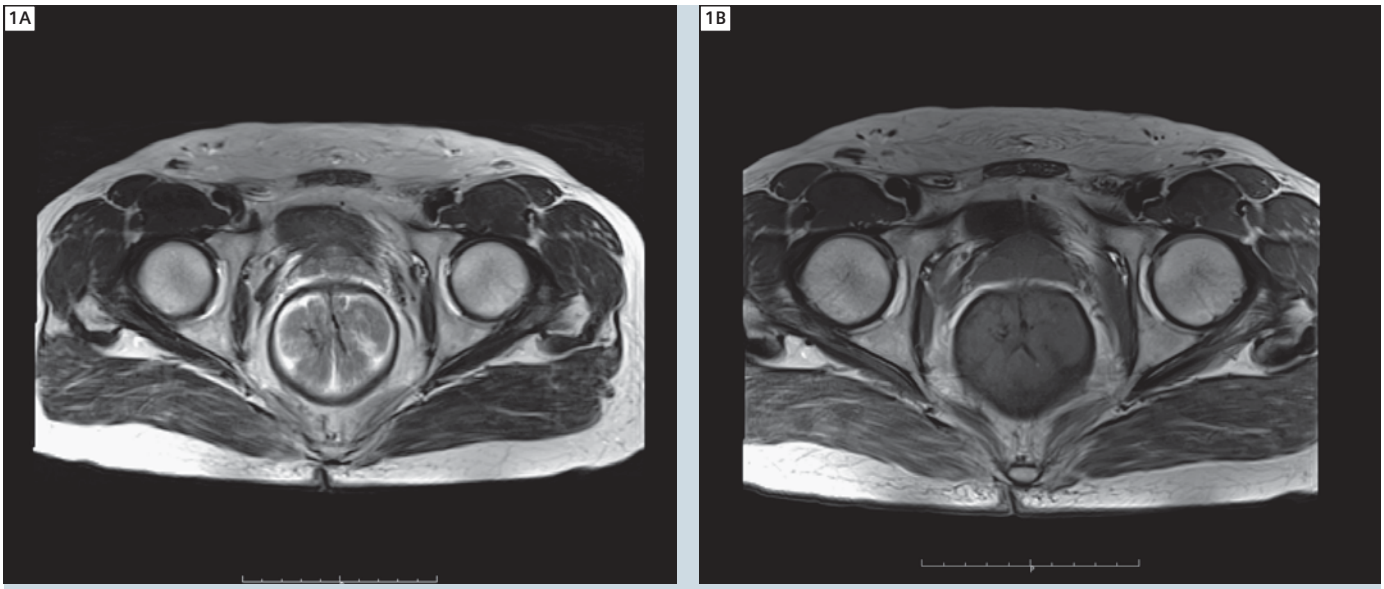


**1** **A:** T2-weighted axial image. Distended rectum, hypointense mass with hypointense branching core surrounded by fluid content.
**B:** T1-weighted axial image, showing hypointense mass.

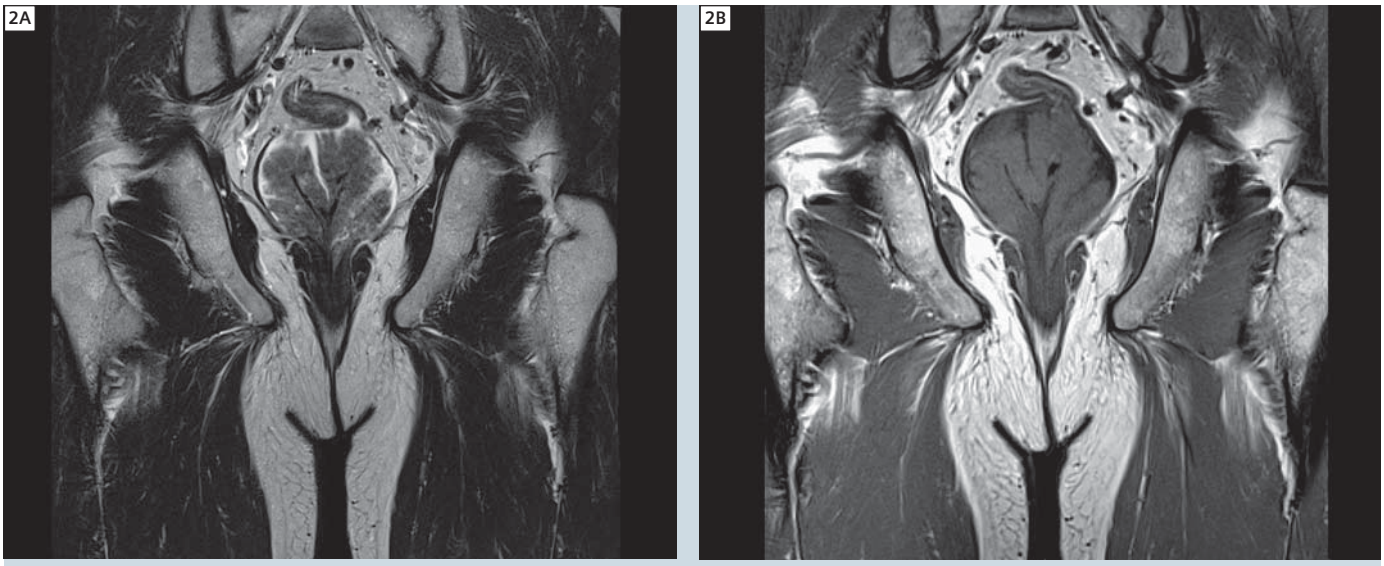


**2** **A:** T2-weighted coronal image. Frond like projections of the mass seen. **B:** T1-weighted coronal image.

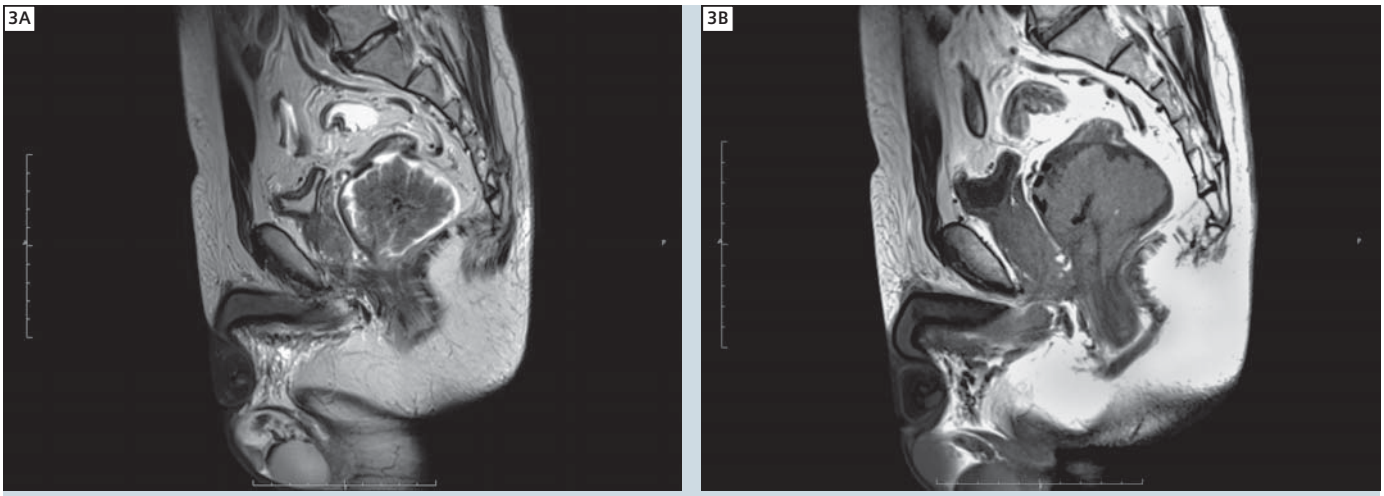


**3** **A:** T2-weighted sagittal image. Anterior rectal wall thickened, mass attached just above the anorectal junction. **B:** T1-weighted sagittal image.

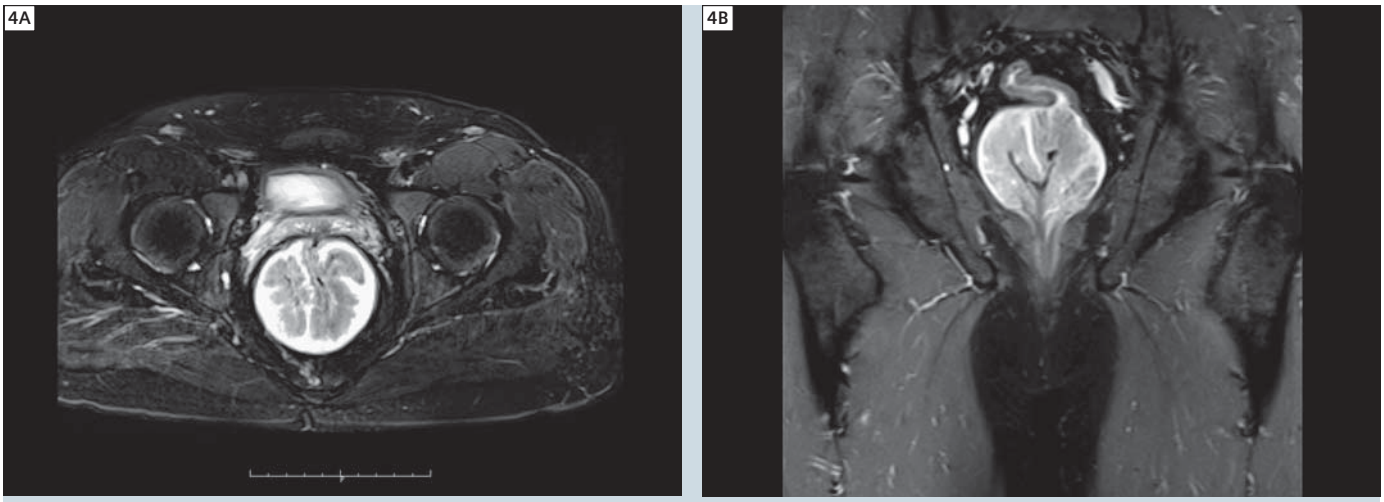


**4** **A:** Fat suppressed T2-weighted axial image. No intramural extension of the mass. Anterior attachment can be clearly seen. **B:** Coronal STIR image.

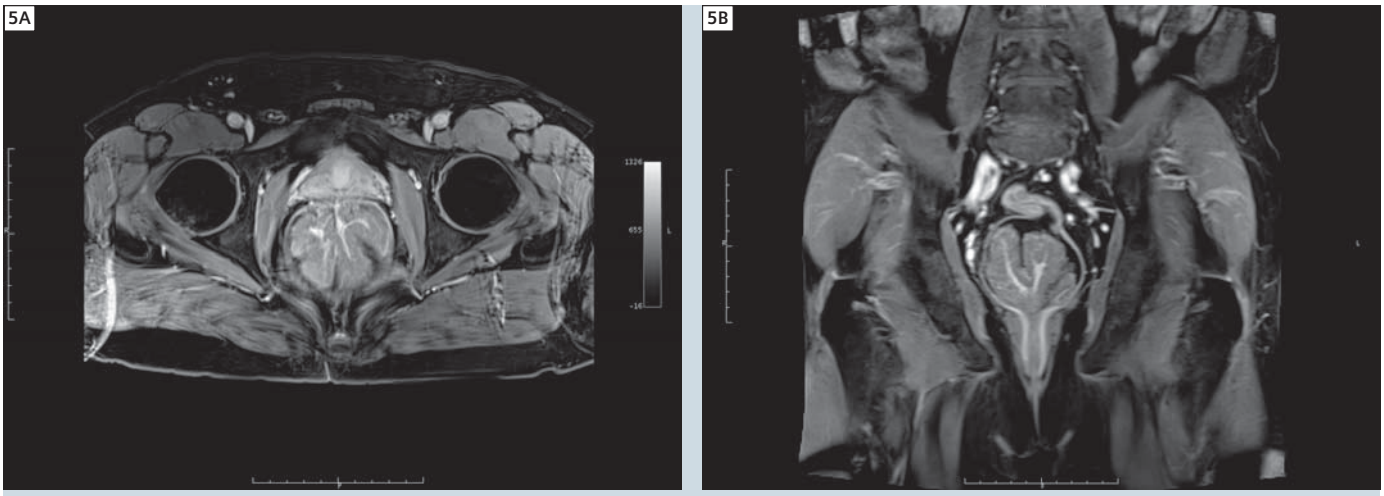


**5** **A:** Contrast enhanced T1-weighted axial image. Fairly intense enhancing central branching core. **B:** Contrast enhanced T1-weighted coronal image. The enhancing nature of the mass is well appreciated, mass clearly delineated from the rectal wall.

remaining part of the SOL shows mild enhancement and is surrounded by fluid. The SOL measures 7.0 cm in AP, 6.7 cm in transverse and 6.2 cm in cranio-caudal axes and appears to be attached to the anterior wall just above the anorectal junction. The rectal wall adjacent to the base of the lesion anteriorly is thickened and shows tortuous flow voids.
Remaining parts of the anorectal region do not show any significant abnormality. No evidence of peri-rectal or pelvic lymph node enlargement is seen. Fat planes around the rectum are preserved and no extra-luminal invasion of the rectal mass is noted.
Urinary bladder does not show any intraluminal mass.
Prostate shows normal size, shape and parenchymal signals.
Visualised muscles and bones do not show any significant abnormality.

## Impression

The findings are suggestive of a mass in the rectum with signal characteristics, morphology and enhancement pattern consistent with a villous adenoma. It appears to be attached to the anterior rectal wall just above the anorectal junction and shows increased vascularity in the region of its base. No evidence of perirectal invasion or enlarged lymph nodes is noted.

6

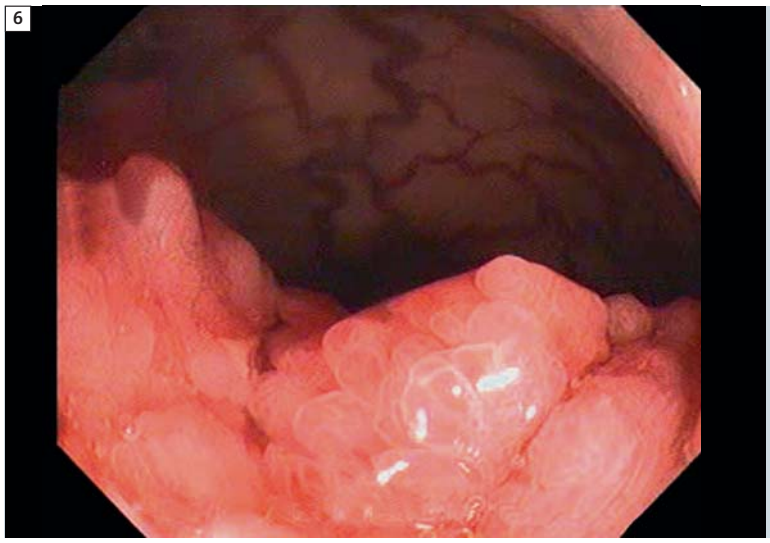

**6** Colonoscopy. Polypoid mass 3 cm from the anal verge extending up to 10 cm, compromising the lumen.

7A

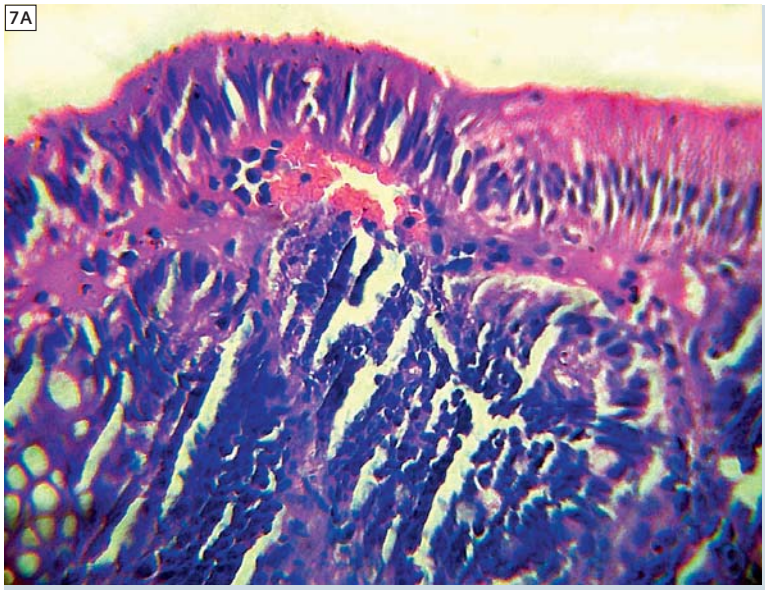

**7** Histopathology: Villous structure with vascular branching core.

7B

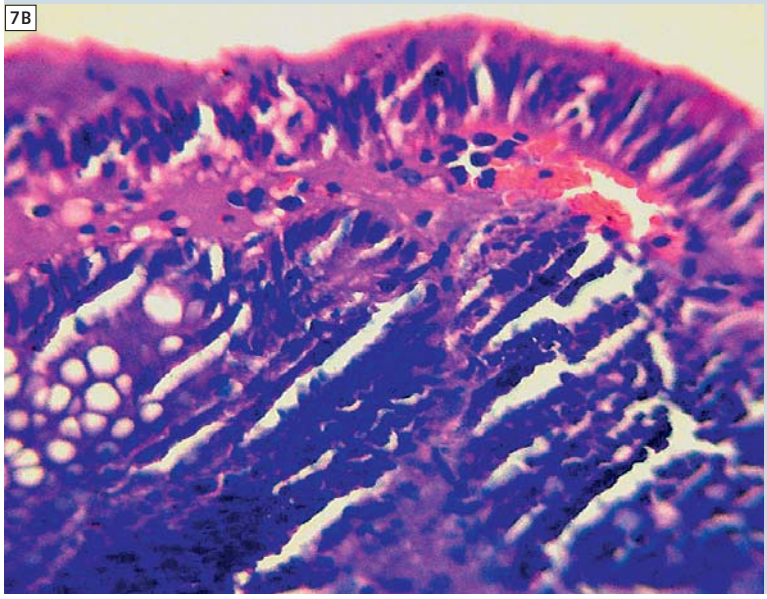

Villous has pseudo stratified lining without atypia.

**Diagnosis:** Villous Adenoma.

## Case 2: Internal Carotid Artery Dissection

### Patient history

A 52-year-old male presented with a history of acute onset of hemiparesis and severe headache. There is no history of Hypertension or Trauma.

### Image findings

**Brain:** There is a large hyperintense area in frontal, parietal, temporal and insular regions of the right cerebral hemisphere and in the right basal ganglia in FLAIR and TSE T2-weighted images with hypo-intensity in the T1-weighted images. There are areas of restricted diffusion in this lesion. Left parasellar region is nor-

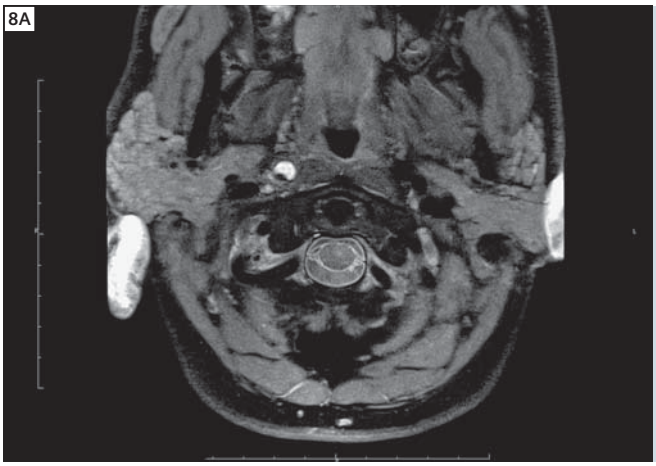
8A

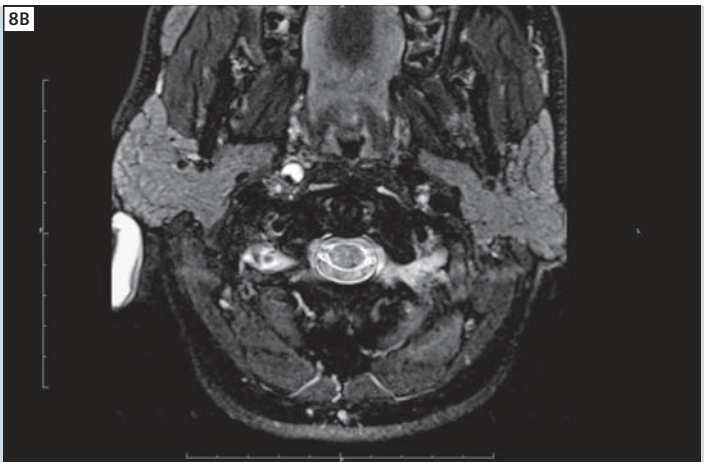
8B

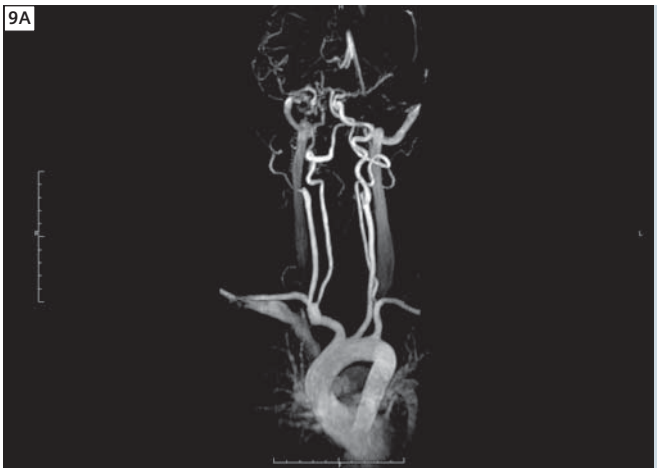
9A

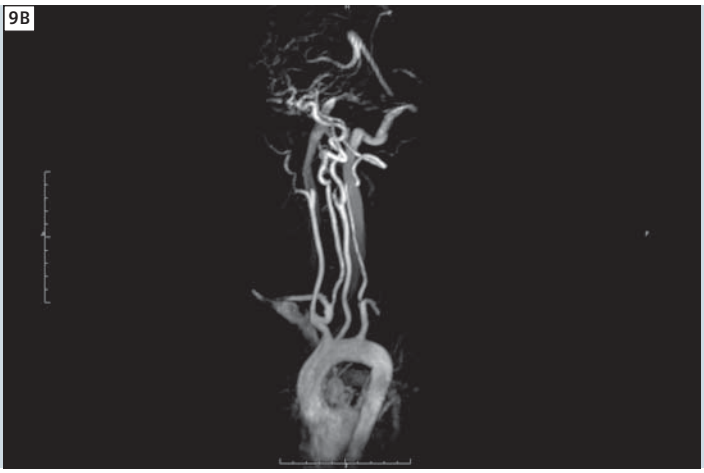
9B

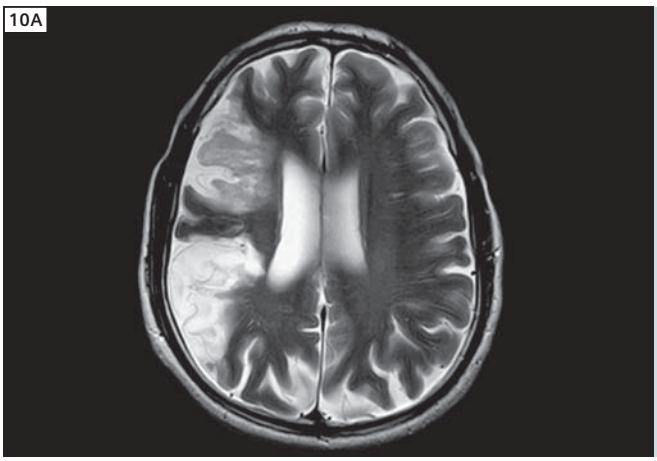
10A

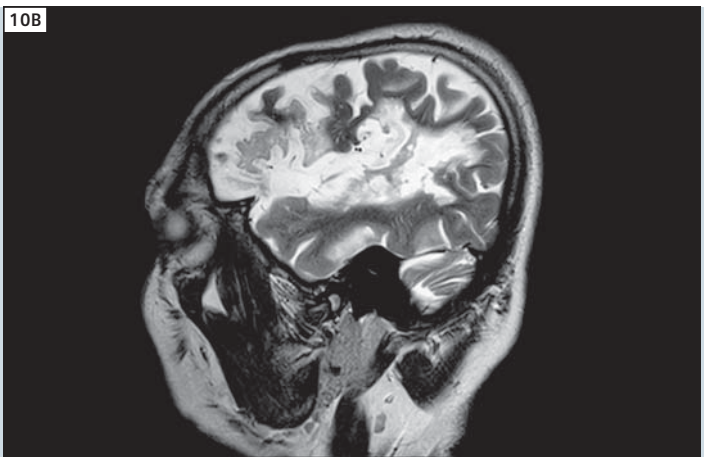
10B

mal but there is loss of flow void in right internal carotid artery (ICA) in the cavernous part and carotid canal.

**MR Angiogram of the neck:** Right common carotid artery shows normal flow signal, origin, course, calibre and bifurcation but there is loss of normal flow signal and luminal enchancement of the right internal carotid artery about 0.8 cm distal to its origin. T1, T2 and proton density-weighted axial images in this region show an ovoid, eccentric hyperintensity with thin hypointense strands within it and a small area of hypointensity in its posterio-lateral aspect. Enchancement is seen in the lumen of the intracranial part of the right internal carotid artery in contrast enchanced angiogram with luminal narrowing. Right common carotid artery shows normal flow void in T1-weighted transverse images.

Left common carotid artery, intracranial and extracranial parts of left internal carotid artery show normal flow void and luminal enhancement with normal course, calibre, flow signal and bifurcation. Extracranial and intracranial parts of both vertebral and visualized parts of external carotid arteries also show normal appearance.

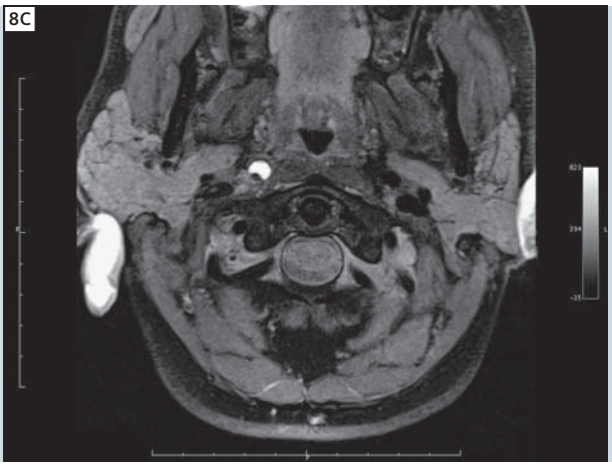


**8** Ovoid eccentric hyperintensity in the right internal carotid artery (ICA).
**A, B:** Proton-Density-weighted transversal image with fat saturation.
**C:** T2-weighted transversal image with fat saturation.

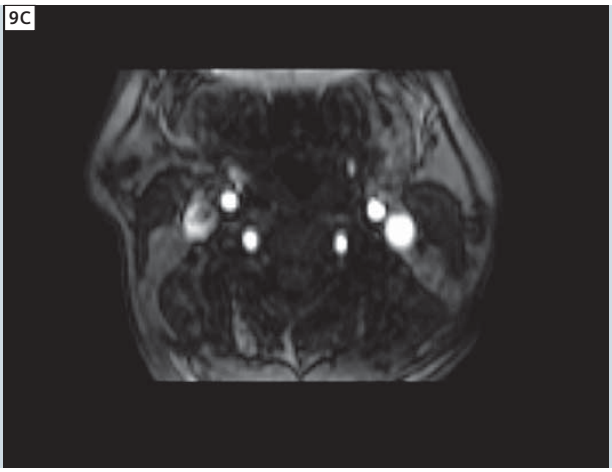


**9** **A, B:** Contrast enhanced MR Angiography (ceMRA) of the neck. Note the loss of flow in the right ICA.
**C:** Transversal ceMRA.

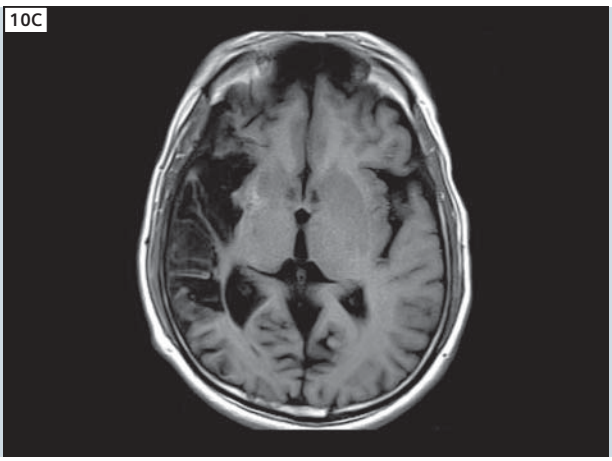


**10** Follow-up scan of the brain.
**A, B:** T2-weighted transversal and coronal image showing the infarct.
**C:** T1-weighted FLAIR image showing the infarct in the MCA (Middle Cerebral Artery) territory.

## Impression

The findings are suggestive of right internal carotid dissection with eccentric intramural haematoma just beyond the proximal extracranial part of right internal carotid artery. There is loss of flow in the right internal carotid artery beyond the dissection up to the intracranial part with a large acute to subacute infarction in right middle cerebral artery territory, involving the frontal, parietal, temporal, insular and basal ganglia regions. Empty sella turcica is noted.

## Case 3: Ankylosing Spondylosis

### Patient history

A 46-year-old female presented with a history of neck pain radiating to the left shoulder for the last 2 years and low back pain radiating to left lower limb for the last 3 years. She has a stooped gait and was advised MRI of cervical and lumbosacral spine. She was refused at other MRI scanners as she was unable to lie down straight in the magnet due to her kyphosis and her inablility to extend her left lower limb.

### Image findings

**Cervical spine:** There are mild degenerative changes in the endplates of cervical vertebrae with focal areas of fatty marrow change. There appears to be forward bending of the spine but cervical vertebrae otherwise show normal height and alignment.
Intervertebral discs show normal height with evidence of dessication at C4–C5 and C5–C6 levels.

**Lumbosacral spine:** L5 vertebra is completely sacralized and degenerative changes are noted in the endplates of lumbar vertebrae and facet joints. Height, alignment and marrow signals of the visualised lumbosacral vertebrae are otherwise normal but subarticular fatty marrow change is seen in both sacro-iliac joints in some regions. Small area of marrow oedema is also noted in



**11** The patient is unable to extend her left lower limb, but may be positioned comfortably in the 70 cm bore of the MAGNETOM Verio.

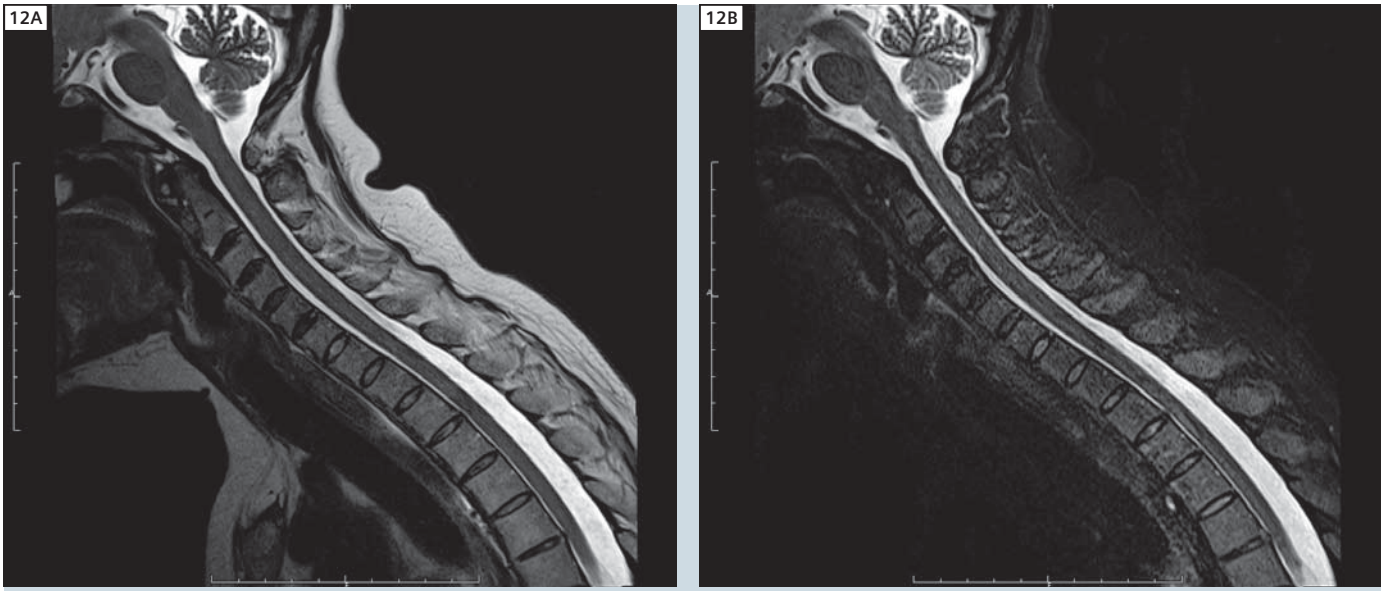


**12** Degenerative changes. **A:** T2-weighted sagittal image. **B:** T2-weighted sagittal TIRM DarkFluid image.

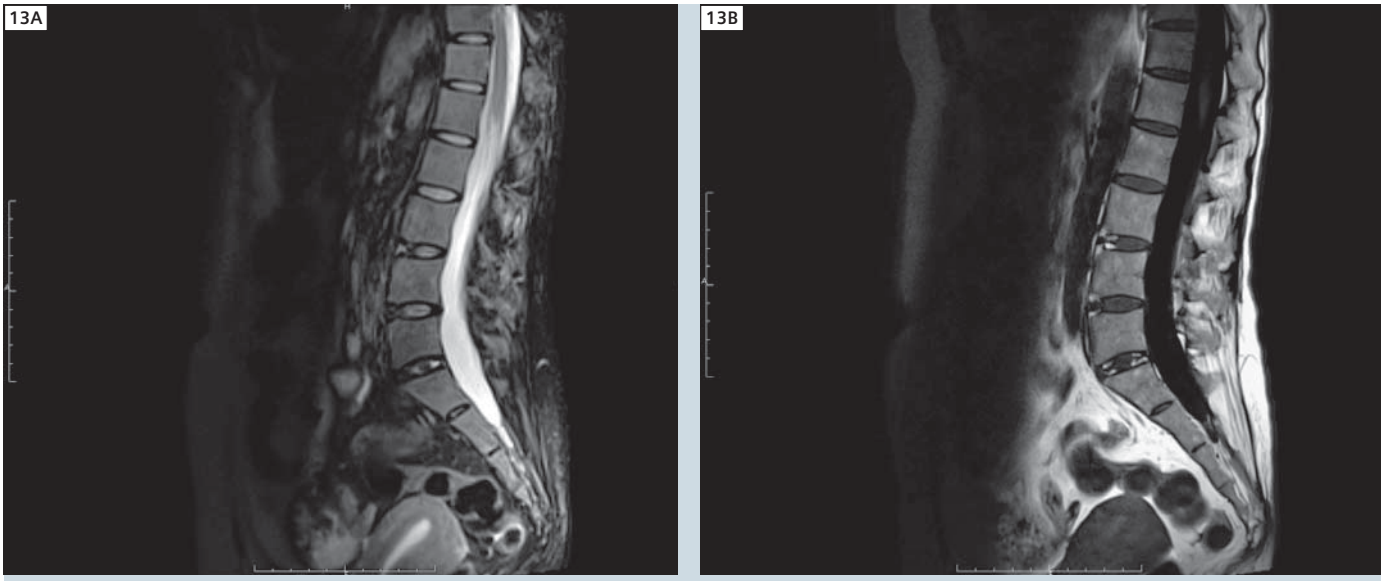


**13** T2 and T1-weighted sagittal images show calcification of discs.

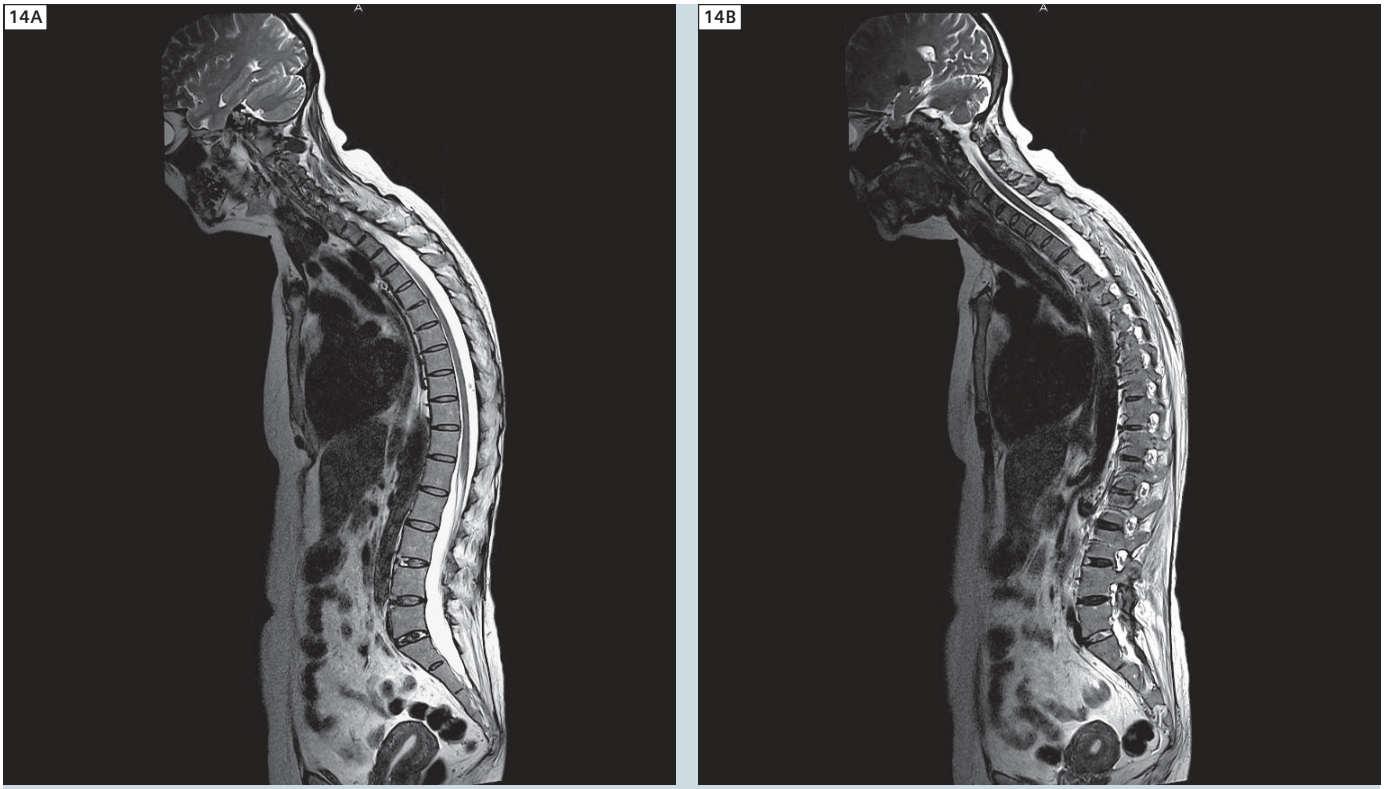


**14** T2-weighted sagittal whole spine image. Kyphosis, sacralization of L5 vertebra with calcification of the lumbar discs.

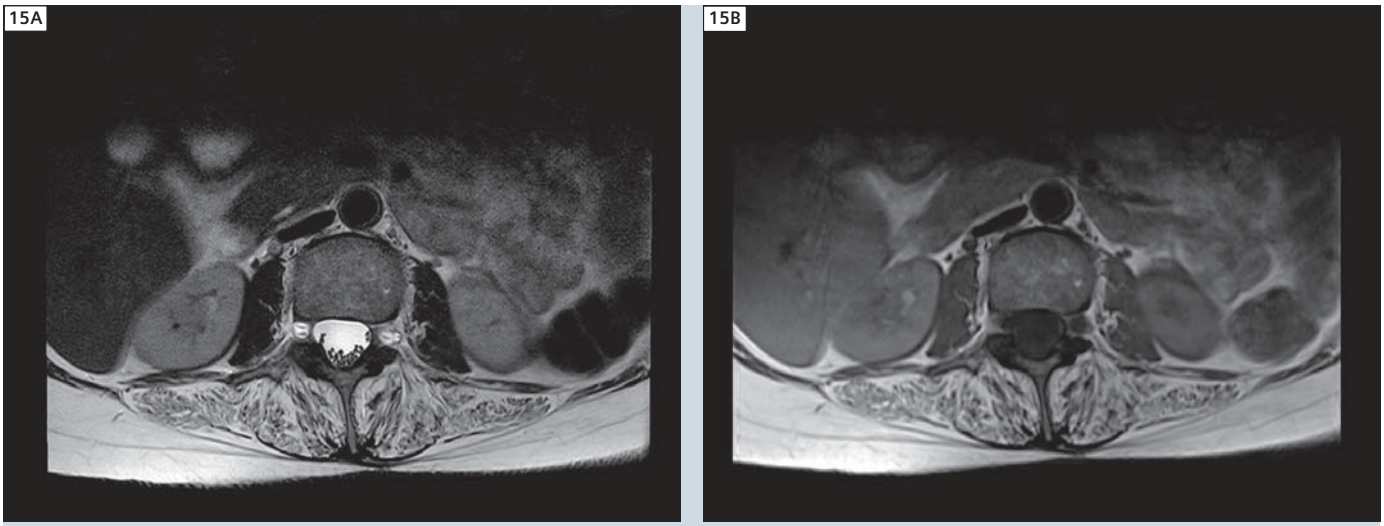


**15** T2 and T1-weighted axial images showing squaring of vertebra.

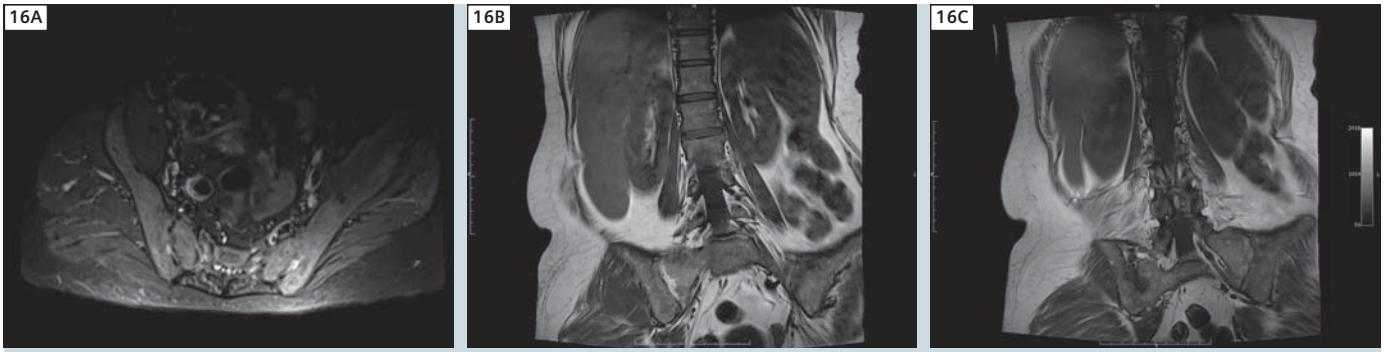


**16** **A:** T2-weighted TIRM image showing bilateral sacroiliitis. **B, C:** T1-weighted coronal images showing bilateral sacroiliitis.

iliac aspect of left sacro-iliac joint with oedema in the joint space.
Lumbar inter-vertebral discs show evidence of dessication with calcification at L2–L3, L3–L4 and L4–L5 levels.

## Impression

The findings are suggestive of degenerative changes in the cervical and lumbar spine with sacralisation of L5, calcification of lumbar discs and bilateral chronic sacroilitis with bony ankylosis favouring an inflammatory arthropathy like ankylosing spondylosis. No evidence of compression on the cord or nerve roots is seen though a mild posterior disc bulge at L3–L4 is noted.

**Contact**
Dr. Sumita Kundu, M.D., DMRD
Consultant Radiologist
EKO MRI Centre
54 J L Nehru Road
Kolkata – 700071
India
Phone +91 33 2282 8105
enquiry@ekoxray.com


Dr. S. K. Sharma and Dr. Sumita Kundu