

Case Report: Combining [^{18}F] PET with MR for Detection of Bone Metastases in One Simultaneous Examination

Markus Lentschig, M.D.; Christiane Franzius, M.D.

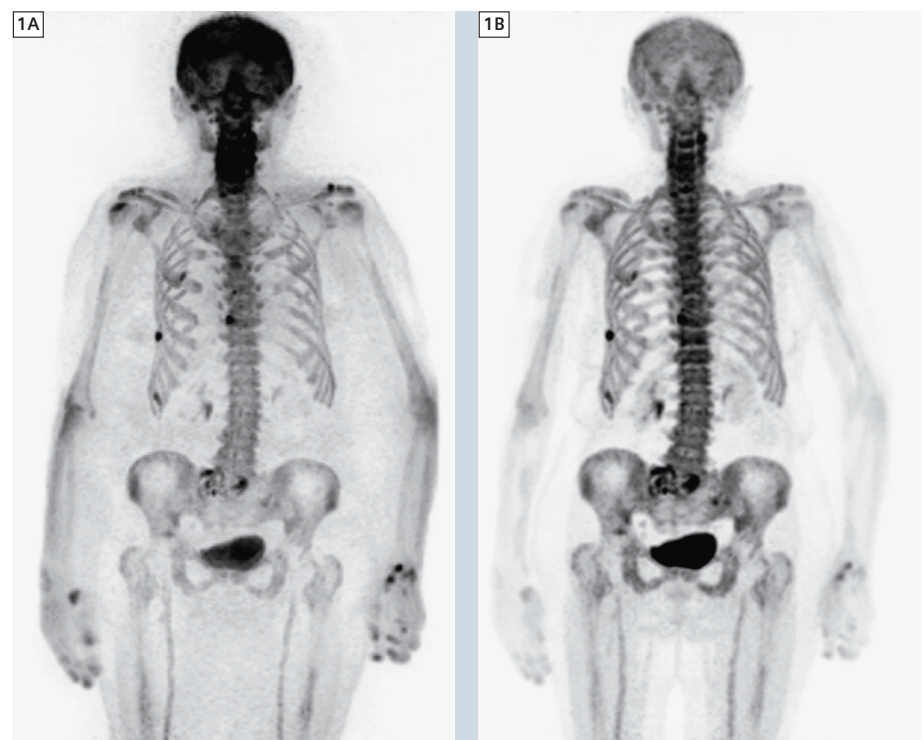
ZEMODI, Zentrum für Moderne Diagnostik, Bremen, Germany

Background

In nuclear medicine, bone scanning is based on the principle of scintigraphy using bone-seeking radiopharmaceuticals. [$^{99\text{m}}\text{Tc}$] (or [^{99}Mo]) -labelled polyphosphonates are used as tracers for this purpose. They accumulate in sites of increased bone formation; metastases are detected either by increased uptake of the lesion itself (osteoplastic), as reaction of the surrounding healthy bone matrix or as defect (osteolytic). Bone scintigraphy has found its way into several clinical guidelines over the last decades and is a standard procedure in the evaluation of bone metastases. However, degenerative changes of bones are challenging to diagnose accurately especially in elderly patients. The low sensitivity of scintigraphy for (small) osteolytic lesions often requires complementary imaging, either X-ray, computed tomography (CT) or – especially in case of bone tumors and bone marrow involvement – magnetic resonance imaging (MRI). It has to be stated that bone scintigraphy is also associated with poor spatial resolution and as a consequence of the imaging mechanism itself this method has limited diagnostic specificity for lesion characterization and an insufficient sensitivity for bone marrow diseases. Positron emission tomography (PET) using [^{18}F]-fluoride has already demonstrated to be a clinically useful alternative to traditional bone scintigraphy. Interestingly, [^{18}F] was initially replaced by [$^{99\text{m}}\text{Tc}$]-labelled polyphosphonates as osteotropic tracer. But with the development of modern PET/CT technology, the advantages over traditional bone

scintigraphy are eminent; [^{18}F] PET adds diagnostic information mainly by its superior resolution compared to scintigraphy and nowadays PET is routinely acquired as 3D data. In addition, CT used as input for attenuation correction helps to characterize suspicious bone modeling. Also it should be kept in mind that from a patient perspective, [^{18}F] PET/CT is considered to be the more convenient procedure (with special focus on preparation time and scan duration). Independent of its diagnostic advantages, the

importance of [^{18}F] PET has increased recently because of its importance as a substitute for conventional skeletal scintigraphy in a time with limited availability of [^{99}Mo]/[$^{99\text{m}}\text{Tc}$]. To ensure healthcare, [^{18}F] PET has now become part of common outpatient care [1–5]. Within the last decade, MRI has also increasingly challenged the clinical value of bone scintigraphy with superior diagnostic performance. The potential to assess not only changes of the bone but especially of the bone marrow and soft



1 Maximum intensity projection (MIP) of the [^{18}F] PET data (1A) uncorrected and (1B) after attenuation correction (MR based).

tissue in general at highest sensitivity can add important information and have a clear impact on patient care. This is already proven for dedicated patient cohorts. In combination with the advent of multi-regional MRI and further advances in MR technology, diffusion-weighted imaging (DWI) is used more and more routinely to add functional information to MRI. The images derived from such an exam show PET-like appearance; however, the underlying mechanism is restriction of water motion. How DWI will add further diagnostic accuracy in the detection of bone metastases and especially therapy follow-up is still subject of debate but its potential is more than evident [6–11]. Combining [^{18}F] PET and MRI for evaluation of bone processes is therefore appealing but was only available in a small number of very selected cases up to now. One practical reason is the associated effort for conducting, synchronizing (time and indication wise) and reading two complex exams (this is especially true for MRI, where a standard whole-body scan produces more than 1000 images which have to be read). In addition, fusion techniques, which are often used to assist in this task, are of limited value especially for scans covering a larger volume simply because of different positions of the bones between the two examinations. The limitation of two separate exams can only partially be overcome by positioning aids (with all their associated disadvantages). It can, however, be overcome by using hybrid MR/PET systems (with the advantage to perform only one scan). Much has been written about the need and the technology behind this new hybrid imaging modality (see also the most recent issues of MAGNETOM Flash). It should be pointed out that simultaneous MR and PET imaging also has advantages in clinical routine over a sequential approach – not only from a workflow aspect.

A very obvious aspect is that it clearly improves spatial registration between metabolic and morphological information by reducing the time gap between the acquisition of MR and PET. This is a clear advantage not only in imaging the pelvis, bowel, lung and liver, but also in patients with limited capability for holding still in one position over a longer time period. Also it should be mentioned that there are no limitations in the performance of the individual imaging methods of such a combined simultaneous MR/PET system. Hybrid MR/PET systems rely on segmentation algorithms for providing the input function of the attenuation correction. At this point in time, bone segmentation is available only for dedicated areas like the skull base and not yet integrated in whole-body scanning. Nevertheless, based on existing data and experience, the need for bone segmentation can be negated in a clinical setting especially when a qualitative reading of PET is performed. The need for quantification of PET is unquestioned for follow-up exams and, so far, the introduced error as compared to a standard PET/CT (which has also a certain level of confidence only) seems to be negligible even for longitudinal studies – if performed with an MR/PET system. Nevertheless, the advent of this technology has reminded us that the discussion about the accuracy of PET quantification is of high importance and far from concluded (which is also true for the comparability of results acquired with different PET/CT systems). The diagnostic capabilities of MR and PET alone and in combination are of course dependent on the underlying pathology and the applied MR imaging methods and tracers. [12–15]

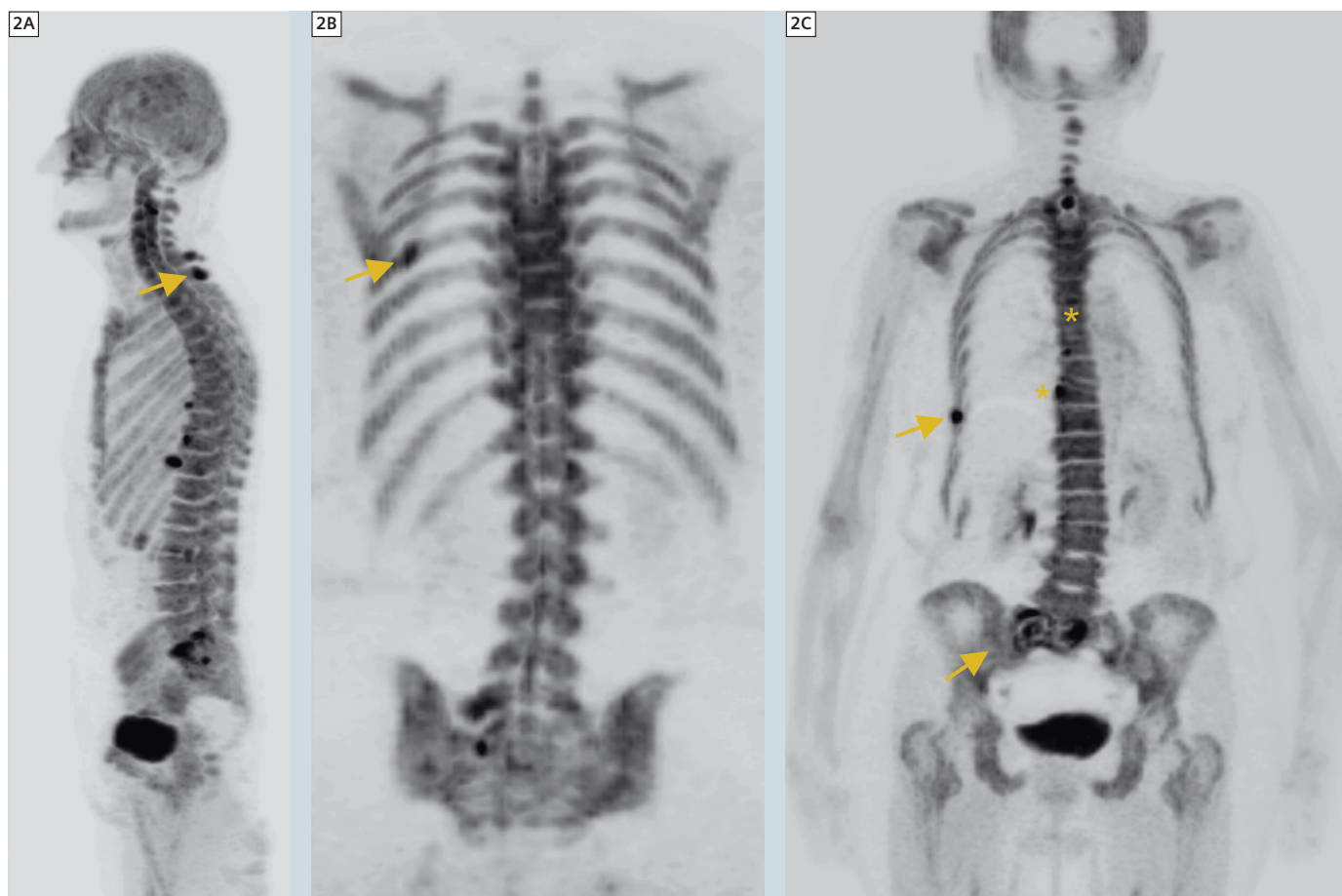
Case report

Patient history and sequence details

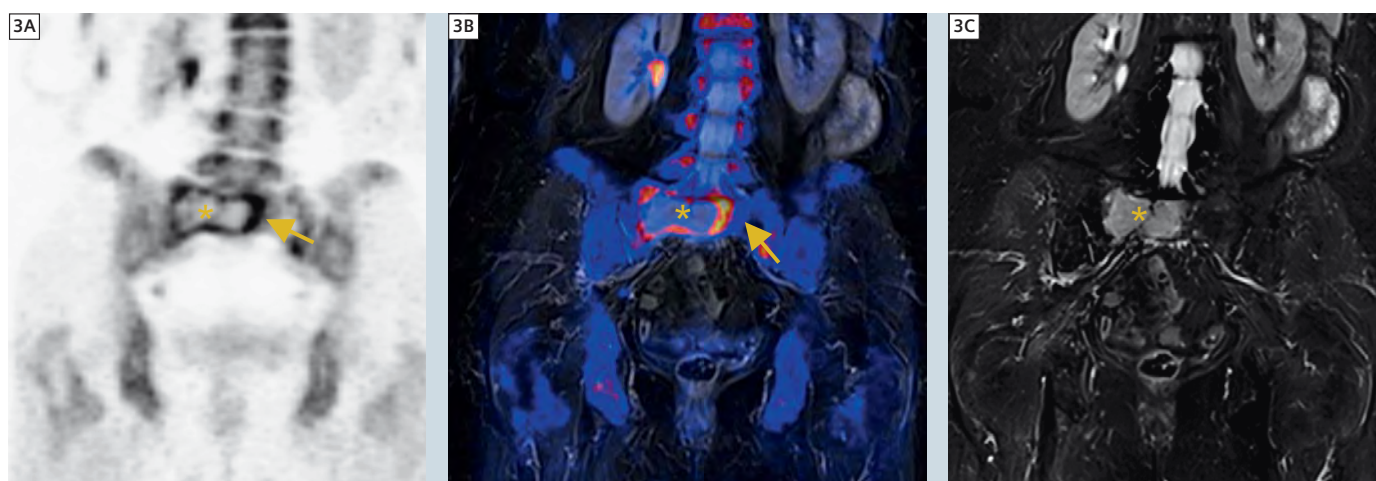
A 91-year-old female with severe sacral pain was referred to our institution for a bone scan with [^{18}F] as substitute to bone scintigraphy. The patient was diagnosed in 1986 with breast cancer and in 2004 a malignoma of the uterus was treated. Application of [^{18}F] was performed according to guidelines. MR/PET was conducted as a multi-step exam covering the whole body. During simultaneous PET acquisition, a coronal T1w TSE (512 matrix, 450 mm FOV, 5 mm SL) and T2w STIR (384 matrix, 450 mm FOV, 5 mm SL) was acquired. In addition, a transversal DWI was measured (b-values 50, 400, 800 s/mm², spectral fat saturation, 192 matrix, 5 mm SL; inline ADC calculation). All images shown were acquired using Biograph mMR (Siemens Healthcare, Erlangen, Germany) and a combination of the head/neck, spine and body coils.

Imaging findings

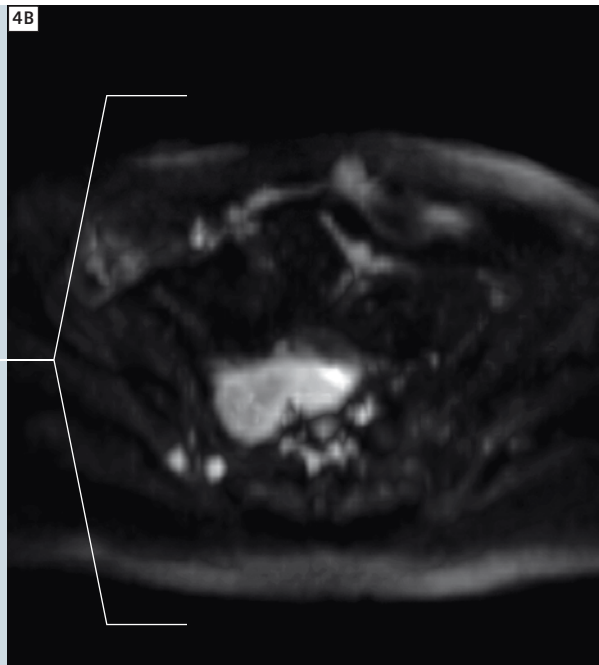
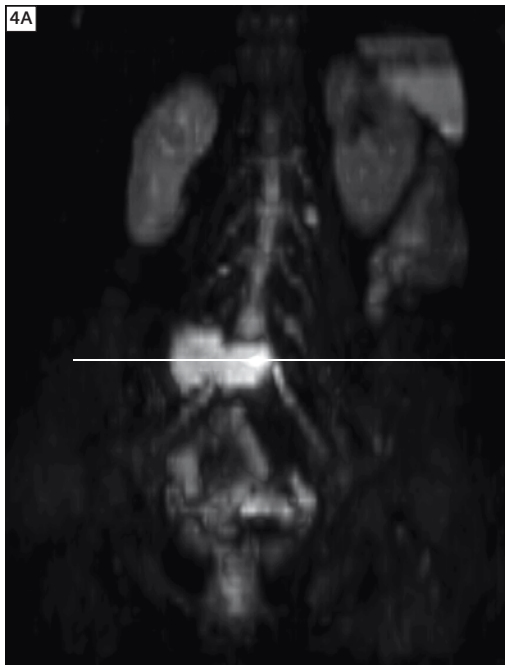
A large osteolytic lesion is shown within the sacral bone (massa lateralis). A clear mismatch between lesion size and corresponding bone formation is obvious. In addition, tumor-suspicious bone formation with corresponding lytic aspect in MRI is demonstrated for the 10th and 7th right rib. Based on DWI, these lesions are characterized by high signal on the original b-value images and restriction of water diffusion. In addition, multiple degenerative bone formations without corresponding oedema in MRI are visualized: spondylosis of the thoracic spine and coxarthrosis of the right hip are the most obvious ones. Focal uptake is also seen in the dorsal process of the 6th and 7th cervical vertebra. Based on T2w STIR images at least for the bone formation of the 7th vertebra a corresponding hyperintense lesion with space occupying aspects at least on the coronal original orientation can be shown. Often reactive oedema can be seen also in degenerative findings, however, based on the space occupying appearance further manifestation of the bone metastases



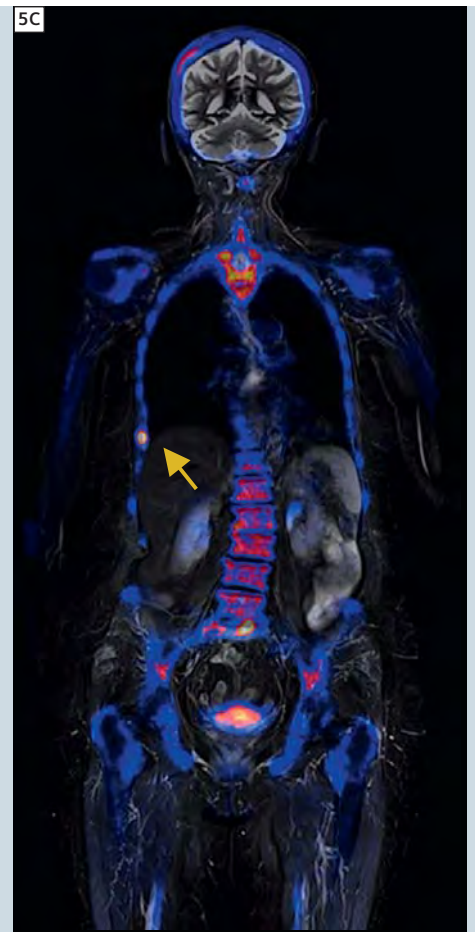
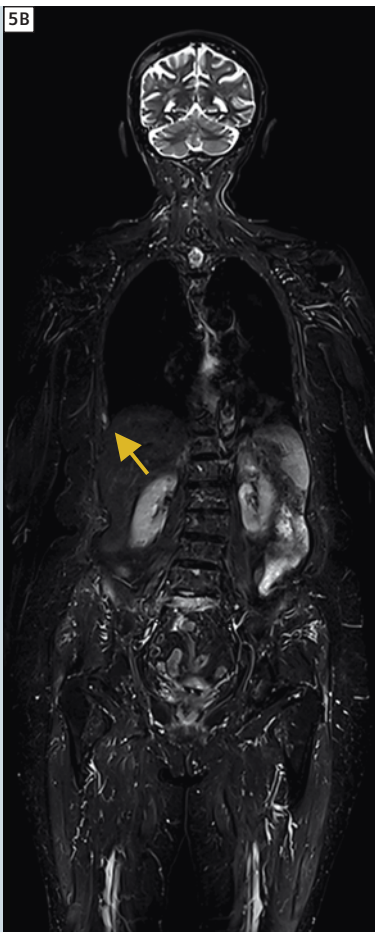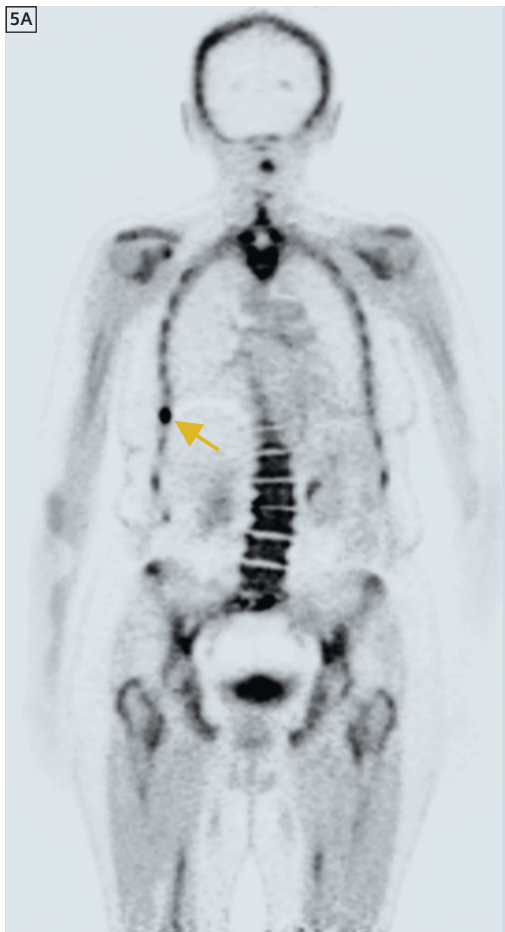2 Sagittal MIP (2A), coronal (2B), thick-slice MIP (2C) showing pathologic bone formation within the os sacrum and the 10th and 7th right rib as well as the 7th/6th cervical vertebra (dorsal processus) (arrows). In addition, multiple degenerative bone formation can be seen (e.g. spondylosis of the thoracic spine; asterisk).



3 Clear mismatch between bone formation (arrows) and true extend of the metastasis (asterisk) in the massa lateralis of the os sacrum is shown. Coronal multiplanar reconstruction (MPR) of the [¹⁸F] PET (3A), overlay of metabolic information on MRI (3B), corresponding coronal T1w TIRM (3C).



4 Thick-slice MPR based on the $b = 800 \text{ s/mm}^2$ DWI images. By suppression of the background the tumor tissue is well delineated. ADC mapping (not shown) did proof restriction of water diffusion. Coronal (4A) and transversal (4B) reformation.



must be concluded. No evidence for further metastases within the long bones of the upper and lower (not shown) extremities, no fractures or soft tissue involvement, no spinal cord compression. The used protocol was mainly focused on the skeletal system, however, further tumor manifestations outside the bone (including lymph nodes) can be ruled out with sufficient diagnostic accuracy.

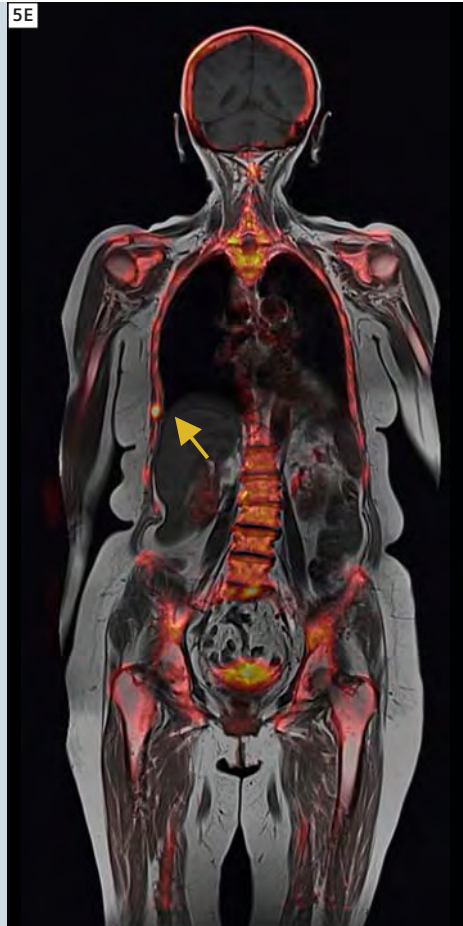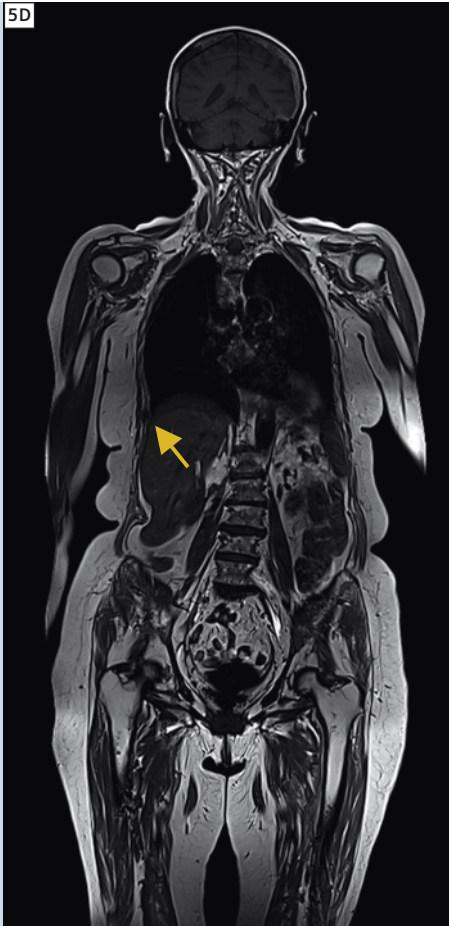Diagnosis

Multifocal metastatic disease of the skeletal system has to be concluded. Based on imaging findings and patient history, a late metastatic manifestation of the mamma carcinoma seems to be the most plausible explanation. With increased

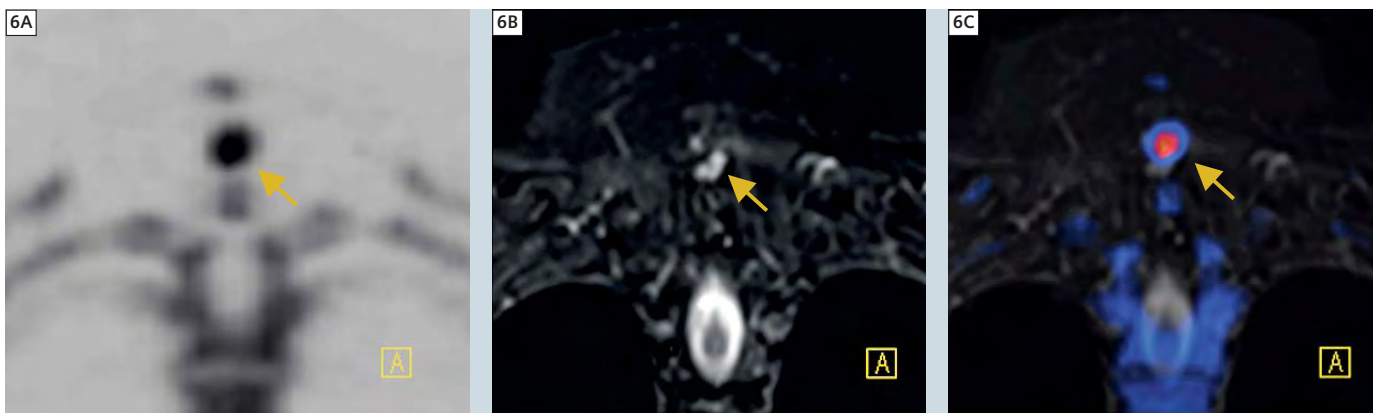
numbers of successful treatment of the primary tumor and also in concordance with latest epidemiological data, tumor recurrence of mamma carcinoma after the 5-years follow-up interval has to be taken into account. However, a third tumor manifestation cannot be ruled out based only on imaging findings and missing presence of a potential primary tumor. Therefore the final conclusion of this exam has to be bone metastases of a cancer of unknown primary (CUP). Because of clinical presentation (severe pain), a therapy relevance is obvious but further diagnosis and therapy will be to be discussed in detail and based on a very individual decision as a consequence of the patients age and general condition.

Conclusion

Combining [^{18}F] PET and MRI in one simultaneous exam is appropriate when it comes to providing best patient care. Based on the knowledge with PET and MRI alone, it is more than justified in our opinion to state that this imaging method can be applied to a large cohort of patients. While the presented case may be a not so common clinical scenario for the future application of MR/PET, it clearly demonstrates the potential of this method as the most accurate method for evaluation of osseous and bone marrow processes. Especially in cases with suspicion of bone marrow involvement and for younger patients, simultaneous MR/PET will play an important role in the future. How far



5 Excellent spatial registration between MRI and PET data is shown exemplary with the small osteolytic metastasis of the right lateral thoracic wall (10th rib). Coronal MPR of [^{18}F] PET (5A), corresponding T2w TIMR (5B), overlay of PET data on T2w TIRM (5C), corresponding T1w TSE without (5D) and with (5E) overlay of PET information.



6 The pathologic bone formation of the 6th and especially 7th (coronal MPR of the PET is shown in **(6A)**) dorsal processus of the cervical vertebra has also to be rated as potentially metastastic. A space occupying lesion with similar imaging features as shown for the other metastases can be demonstrated on the coronal T2w TIRM MRI (**6B**); the overlay of the PET data (**6C**) shows a slight spatial mismatch of the two imaging modalities as a consequence of the different imaging mechanisms of [¹⁸F] PET (bone formation metabolism) and MRI (soft tissue characteristics).

this method will be added to, or will even replace, conventional imaging will of course be also a question of upcoming therapy options and tracers e.g. for evaluation of hormone receptor status. But certainly the presented combination of [¹⁸F] PET and MRI is already a further step towards a more accurate and patient-specific diagnoses and therapy selection – and all within one exam.

References

- 1 Cook GJ. PET and PET/CT imaging of skeletal metastases. *Cancer Imaging*. 2010 Jul 19;10:1-8.
- 2 Hellwig D, Krause BJ, Schirrmeyer H, Freesmeyer M. [Bone scanning with sodium ¹⁸F-fluoride PET and PET/CT. German guideline Version 1.0.]. *Nuklearmedizin*. 2010;49(5):195-201. Epub 2010 Sep 13.
- 3 Hahn S, Heusner T, Kümmel S, Köninger A, Nagarajah J, Müller S, Boy C, Forsting M, Bockisch A, Antoch G, Stahl A. Comparison of FDG-PET/CT and bone scintigraphy for detection of bone metastases in breast cancer. *Acta Radiol*. 2011 Nov 1;52(9):1009-14. Epub 2011 Oct 3.
- 4 Withofs N, Graye B, Tancredi T, Rorive A, Mella C, Giacomelli F, Mievie F, Aerts J, Waltregny D, Jerusalem G, Hustinx R. ¹⁸F-fluoride PET/CT for assessing bone involvement in prostate and breast cancers. *Nucl Med Commun*. 2011 Mar;32(3):168-76.
- 5 Yen RF, Chen CY, Cheng MF, Wu YW, Shiau YC, Wu K, Hong RL, Yu CJ, Wang KL, Yang RS. The diagnostic and prognostic effectiveness of F-18 sodium fluoride PET-CT in detecting bone metastases for hepatocellular carcinoma patients. *Nucl Med Commun*. 2010 Jul;31(7):637-45.
- 6 Pfannenberger C, Aschoff P, Schanz S, Eschmann SM, Plathow C, Eigentler TK, Garbe C, Brechtel K, Vonthein R, Bares R, Claussen CD, Schlemmer HP. Prospective comparison of ¹⁸F-fluorodeoxyglucose positron emission tomography/computed tomography and whole-body magnetic resonance imaging in staging of advanced malignant melanoma. *Eur J Cancer*. 2007 Feb;43(3):557-64. Epub 2007 Jan 16.
- 7 Müller-Horvat C, Radny P, Eigentler TK, Schäfer J, Pfannenberger C, Horger M, Khorchidi S, Nägele T, Garbe C, Claussen CD, Schlemmer HP. Prospective comparison of the impact on treatment decisions of whole-body magnetic resonance imaging and computed tomography in patients with metastatic malignant melanoma. *Eur J Cancer*. 2006 Feb;42(3):342-50. Epub 2005 Dec 20.
- 8 Schmidt GP, Reiser MF, Baur-Melnyk A. Whole-body MRI for the staging and follow-up of patients with metastasis. *Eur J Radiol*. 2009 Jun;70(3):393-400. Epub 2009 May 19. Review.
- 9 Ketelsen D, Röthke M, Aschoff P, Merseburger AS, Lichy MP, Reimold M, Claussen CD, Schlemmer HP. [Detection of bone metastasis of prostate cancer – comparison of whole-body MRI and bone scintigraphy]. *Rofo*. 2008 Aug;180(8):746-52. Epub 2008 May 29. German.
- 10 Wu LM, Gu HY, Zheng J, Xu X, Lin LH, Deng X, Zhang W, Xu JR. Diagnostic value of whole-body magnetic resonance imaging for bone metastases: a systematic review and meta-analysis. *J Magn Reson Imaging*. 2011 Jul;34(1):128-35. doi: 10.1002/jmri.22608. Epub 2011 May 25.
- 11 Padhani AR, Koh DM, Collins DJ. Whole-body diffusion-weighted MR imaging in cancer: current status and research directions. *Radiology*. 2011 Dec;261(3):700-18. Review.
- 12 Schlemmer HP, Pichler BJ, Krieg R, Heiss WD. An integrated MR/PET system: prospective applications. *Abdom Imaging*. 2009 Nov;34(6):668-74.
- 13 Schwenzer NF, Schmidt H, Claussen CD. Whole-body MR/PET: applications in abdominal imaging. *Abdom Imaging*. 2012 Feb;37(1):20-8.
- 14 Delso G, Martinez-Möller A, Bundschuh RA, Ladebeck R, Candius Y, Faul D, Ziegler SI. Evaluation of the attenuation properties of MR equipment for its use in a whole-body PET/MR scanner. *Phys Med Biol*. 2010 Aug 7;55(15):4361-74. Epub 2010 Jul 20.
- 15 Delso G, Fürst S, Jakoby B, Ladebeck R, Ganter C, Nekolla SG, Schwaiger M, Ziegler SI. Performance measurements of the Siemens mMR integrated whole-body PET/MR scanner. *J Nucl Med*. 2011 Dec;52(12):1914-22. Epub 2011 Nov 11.

Contact

Markus G. Lentschig, M.D.
ZEMODI
Zentrum für Moderne Diagnostik
Schwachhauser Heerstr. 63a
28211 Bremen
Germany
Phone +49 421 69641-600
Fax +49 421 69641-649
www.zemodi.de