

# AXIOM Innovations

The Magazine for Interventional Radiology, Cardiology and Surgery

[www.siemens.com/angiography](http://www.siemens.com/angiography)

December 2012

**SIEMENS**

## syngo DynaPBV Body

Patient-Individualized  
Interventional Therapy

Page 14

## A Clear View of Innovative Stents

New Bioabsorbable  
Stent Testing

Page 54

## CMF Surgery

goes for Hybrid OR

Page 64

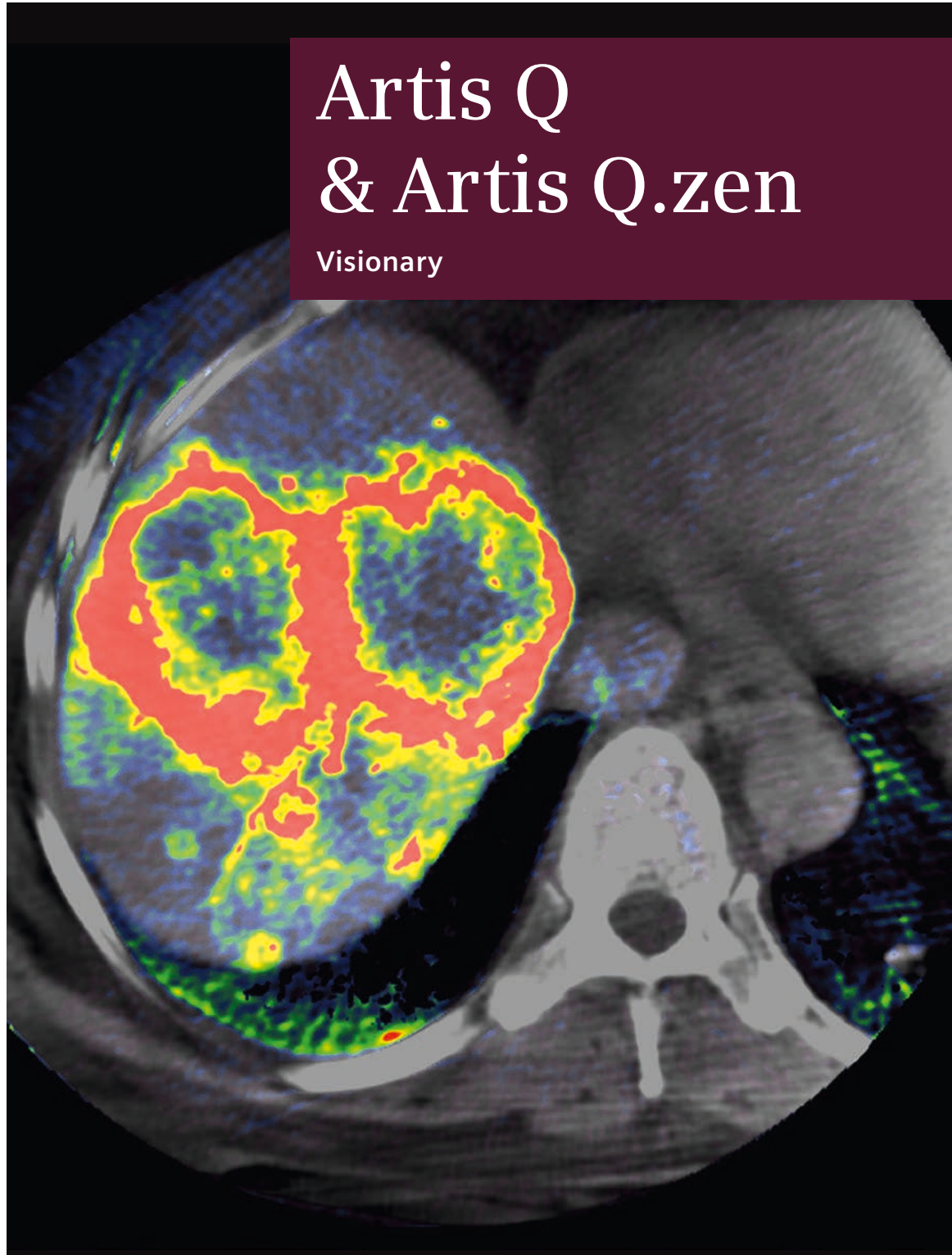
## New Addition to Thoracoscopic Surgery

The Hybrid Concept  
Expands to New  
Disciplines

Page 68

## Artis Q & Artis Q.zen

Visionary



16

“Image quality and dose reduction are our passions ... and we keep pushing the envelope.”

Dr. Heinrich Kolem,  
CEO of the Angiography & Interventional X-Ray Systems, Business Unit (AX)  
at Siemens Healthcare

## Dear Reader,

Image quality and lower dose are two aspects that have always been of great clinical importance to our customers. Two new product lines which focus on these two aspects will be available from Siemens Healthcare AX soon: the Artis Q®, and the Artis Q.zen®. The Artis Q is a visionary breakthrough in X-ray generation and detection that takes performance and precision to a new level. The Artis Q.zen introduces a new flat-detector technology to the market for a visionary breakthrough in ultra-low-dose imaging. Both product lines are empowered by a new X-ray tube. This tube has been designed around a unique flat-emitter technology that enables powerful short pulses generated on small square focal spots. This allows our customers to clearly visualize devices and vessels even in the most challenging situations.

In addition to X-ray generation, detection is crucial for high image quality. The Artis Q is available with a new optimized large detector. This detector is designed especially to deliver high image quality with *syngo*® DynaCT. The 16-bit output enables a high

dynamic range of 65,000 grayscale values leading to enhanced soft tissue contrast in 3D imaging.

Our customers always strive to lower dose, especially during long-lasting, complex procedures. With the Artis Q.zen, we introduce a groundbreaking new detector technology based on crystalline silicon, which reduces the electronic noise when imaging at ultra-low dose levels.

Image quality is a mandatory requirement from our customers and we are proud to be able to offer the most powerful system on the market. However, we don't stop there. We drive innovation further with advanced applications to support precise guidance during interventions. In cardiology, we are introducing CLEARstent Live for real-time stent enhancement, and IVUSmapk for integrated co-registration of intra-vascular ultrasound information (IVUS) onto the angio image. For advanced interventional procedures, we are launching a series of 3D tools: including *syngo* DynaCT Micro to visualize even the smallest devices,



**Dr. Heinrich Kolem**  
CEO AX Division

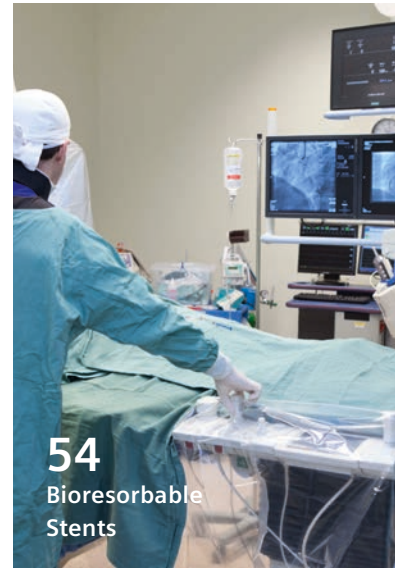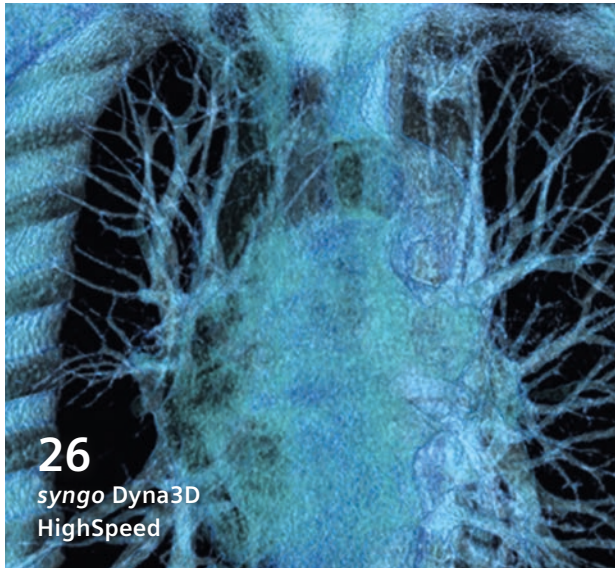
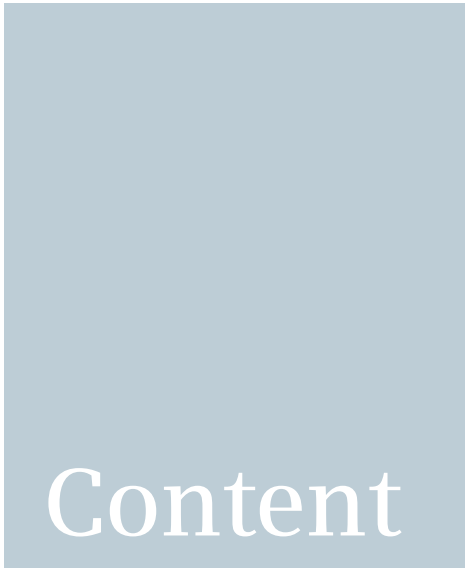*syngo* Dyna3D HighSpeed to acquire a 3D dataset in less than 3 seconds, and *syngo* DynaPBV Body, which establishes perfusion imaging in the body.

Artis Q and Artis Q.zen bring unprecedented quality to interventional imaging. This breakthrough is the result of a hard-working, passionate team that is united by one belief: We at AX not only address the needs of our customers today, but anticipate their future requirements and help them fight the most threatening diseases. Our pioneering spirit, our unquenchable curiosity, and our inventive imagination have always been trendsetting. Today, with the launch of Artis Q and Artis Q.zen, we are taking that next step.

I invite you to discover these exciting new systems and familiarize yourself with their key features.

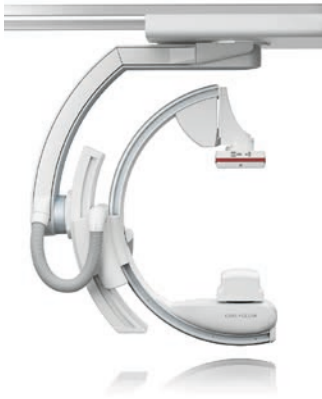Please enjoy reading on for more details in this AXIOM Innovations!

Dr. Heinrich Kolem



**26**  
syngo Dyna3D  
HighSpeed

**54**  
Bioresorbable  
Stents



**10** **Artis Q / Artis Q.zen**  
A new era is about to begin. Let's start to be visionary in performance, precision and sensitivity.

**2** Editorial

**6** News

Cover Story

**10** **Artis Q, Artis Q.zen**  
Pushing the Frontiers of interventional imaging

**14** **syngo DynaPBV Body**  
Insight into perfusion

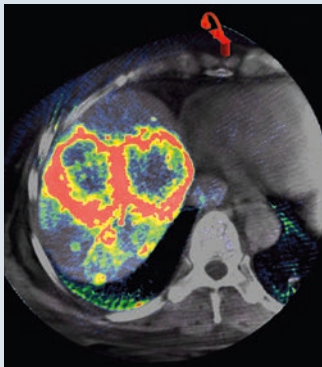
**18** **Arteriography for Isolation of the Hepatic Arterial Bed**  
Clinical case

**20** **TACE in Multifocal Primary Liver Cancer**  
Clinical case

**24** **Hepatic Blood Volume Imaging**  
Clinical case

**26** **syngo Dyna3D HighSpeed**  
Freeze the motion

**28** **Transarterial Thoracic Chemoembolization**  
Clinical case

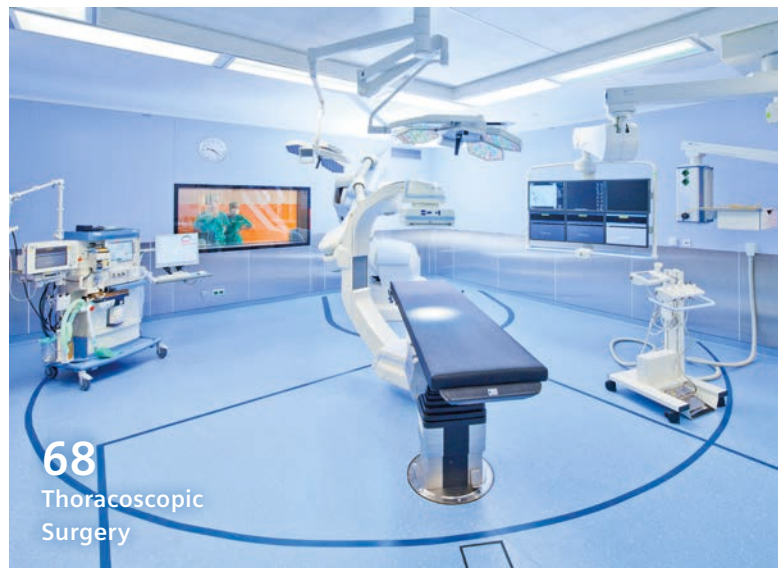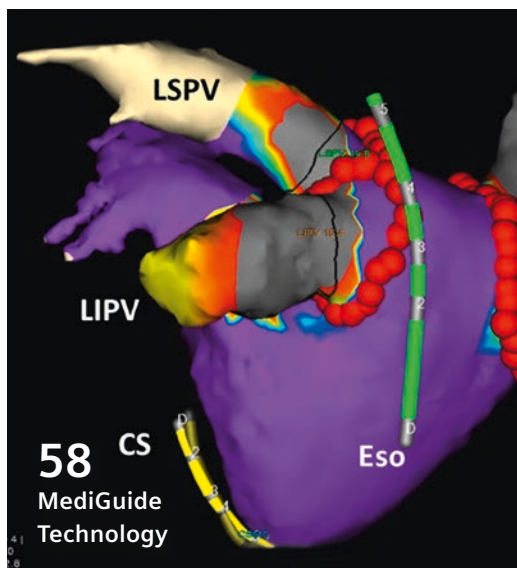

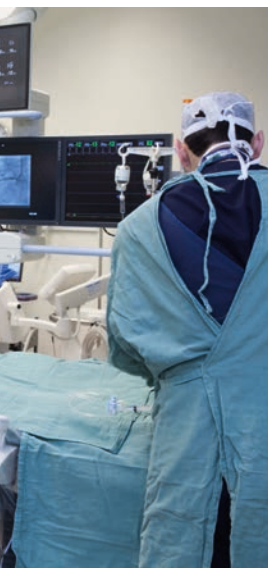
**Cover**

*syngo DynaPBV Body*  
Courtesy of Prof. Thomas Vogl, M.D., Department of Diagnostic and Interventional Radiology, University of Frankfurt/Main, Germany.

The statement by Siemens' customers described herein are based on results that were achieved in the customer's unique setting. Since there is no "typical" hospital and many variables exist (e.g., hospital size, case mix, level of IT adoption) there can be no guarantee that other customers will achieve the same results.





**30 syngo DynaCT Micro**  
Boosting the level of detail

**34 IVUSmap**  
IVUS Information Localized  
within Coronary Tree

**36 CLEARstent Live**  
Stent enhancement in real time

## Angiography

**38 syngo DynaPBV Body**  
Blood volume imaging opens new  
prospects for tumor treatment

**44 Revascularization of Peripheral  
Vascular Disease**  
Clinical case supported by  
*syngo* iFlow

**46 Lower Limb Revascularization**  
Clinical case supported by  
*syngo* iFlow

**48 Acute Stroke Recanalization**  
Clinical case supported by *syngo*  
DynaPBV Neuro and *syngo* iFlow

**50 Interhemispheric Venous  
Phase Timing**  
Clinical case supported by  
*syngo* iFlow

**52 Hepatocellular Carcinoma  
Treatment**  
Clinical case supported  
by *syngo* DynaCT

## Cardiology

**54 A Clear View of Innovative Stents**  
Artis zee helps physicians in Brazil  
during trials of bioresorbable stents

**58 Pulmonary Vein Isolation  
without Fluoroscopy**  
Clinical case with MediGuide  
Technology

## Surgery

**60 EVAR-3D Guidance**  
Clinical case showing benefits for  
Artis zeego Club members

**64 A Hybrid OR for CMF Surgery –  
Breaking a Fly on the Wheel?**  
Interview

**66 Minimally Invasive  
Liver Resection**  
Clinical case supported by  
*syngo* DynaCT

**68 Very Promising Addition**  
Hybrid rooms are now used  
for thoracoscopic surgery

**74 Going Hybrid for Cardiac  
Procedures**  
Clinical case showing Surgical  
Repair of Post-MI VSD

## Customer Care

**76 Artis zeego**  
An indispensable tool  
for routine work

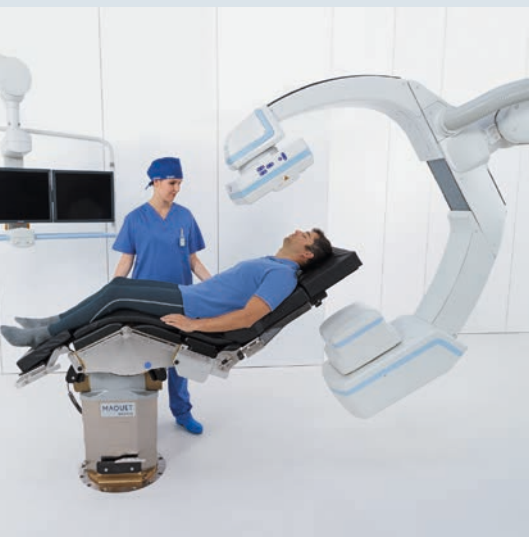**78 Continual Learning Experience  
Through Innovation**  
Cardiac workshop in Singapore

**80 Upcoming Congresses**

**82 Subscription & Information**

## 83 Imprint

## A Global First: Hybrid OR with Artis zeego and the MAQUET MAGNUS OR Table



Artis zeego flexibly adapts to the different segments of the MAQUET MAGNUS OR table.

The first installation of a hybrid OR with the combination of Artis zeego and MAQUET's MAGNUS OR table was completed at The Valley Private Hospital in Mulgrave, Victoria, Australia in August 2012.

The hospital decided to build an operating room that could be used for interventional and hybrid procedures, as well as for open surgery. Cardiac surgeons and cardiologists are working in the theatre performing a range of procedures, from PCI to transcatheter aortic valve implantations (TAVI) to bypass surgery. For this purpose the team at Valley Private Hospital decided to build their 60m<sup>2</sup> OR around equipment that allows for truly multi-disciplinary room usage: The Artis zeego angiography system from Siemens and the MAGNUS OR table from MAQUET.

Based on a robotic design, Artis zeego is the only system on the market which can flexibly adapt to all angulations of the table segments. It even enables intra-operative 3D imaging with *syngo DynaCT* in an angulated table position. The MAQUET MAGNUS table, integrated with Artis zeego and ceiling-mounted angiography systems<sup>1</sup>, is an innovative OR table system that comes with different tabletops: a one-piece carbon fiber

tabletop which is especially useful for vascular surgeons for peripheral vascular procedures, and for cardiologists performing PCIs. This tabletop can be exchanged with different configurations of a segmented table. The flexible segments allow for superior patient positioning that is being used by cardiac surgeons for thoracic procedures, vascular surgeons for carotid procedures or neurosurgeons for spinal or cranial treatment.

The hybrid operating theatre features MAQUET's VARIOP Solution, a fully integrated video management system, MAQUET anesthetic and surgical pendants and surgical lights.

The Valley hybrid OR will open up opportunities to attract a variety of specialties and unique procedures with the state-of-the-art Siemens MAQUET solution.

<sup>1</sup>Completion of the integration with Artis.Q ceiling is expected for mid 2013.

## Siemens Dominates the Hybrid OR Market: 500 installations



St Mary's Hospital in Richmond is part of the Bon Secours Virginia Health system offering a full range of services including cardiac, women's, children's, orthopedics, oncology, neurosciences and surgery.

Only a few years ago the term 'hybrid OR' was hardly known in the surgical community. Today, the concept of a

conventional OR equipped with an angiography system has become standard of care in many surgical disciplines. Especially in the field of cardiovascular surgery, minimally invasive and hybrid approaches have become the treatment of choice for many indications such as aortic stenosis or abdominal aneurysms. For these procedures, high-end intra-operative imaging in 2D as well as 3D is key. With a wide array of angiography systems, three integrated OR table families, and dedicated software applications, Siemens is dominating the market in the field of hybrid operating rooms. The 500th order for a hybrid OR came

from Bon Secours Heart & Vascular Institute at St. Mary's Hospital in Richmond, Virginia, US. Bon Secours is the fourth largest health provider in Virginia and offers a full range of services at seven award-winning hospitals. Marc Katz, M.D., chief medical officer at St. Mary's Hospital, about the hybrid OR project: "After a comprehensive, industry-wide search we have chosen to partner with Siemens for our hybrid suite. The cutting edge technology will allow us to continue our focus and innovation in minimally invasive techniques to enhance patient outcomes and satisfaction."

## Making Work Easier For Complex EP Procedures

An increasing number of people are suffering from cardiac arrhythmias, a condition diagnosed and treated by means of electrophysiology. One of the leading centers in this highly specialized field of cardiology is the Institute for Clinical and Experimental Medicine in Prague, Czech Republic.

Professor Josef Kautzner, M.D., Director of the Department for Cardiology at the Prague Institute for Clinical and Experimental Medicine (IKEM), and his team perform around 850 ablations per year. In more than 50 percent of the cases, these are complex procedures for the treatment of atrial fibrillation and ventricular tachyarrhythmias. In order to be able to provide every patient with the optimal treatment the integration of many systems is key.

The more complex the electrophysiology procedures become, the higher the requirements concerning workflow are. While multimodality imaging and integration do not significantly reduce the time required, they do permit more efficient and concentrated work.

A good example of the integration of

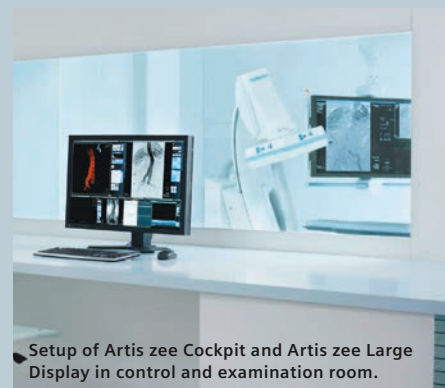state-of-the-art technologies is the Artis zee angiography system from Siemens which was recently installed in Prague. The work of the electrophysiologists in the catheter laboratory with its density and wealth of information is now also provided with visual support. Instead of having to monitor three or four individual displays during an ablation, the electrophysiologists now have all the information combined on the new Artis zee Large Display.

The electrophysiologist can choose the layout of this 56" display directly from the tableside control panel. The Large Display can handle even the high-resolution signals of the latest mapping and recording systems. A special algorithm ensures the precise display of the intracardiac ECG recordings in any size on the screen.

A conventional HD video output can be used, to distribute the video signal in-house to a lecture room or feed a video encoder for live broadcast and to record the content of the screen for teaching. In the control room, the new 30"-screen-based Artis zee Cockpit ensures an

improved overview. The cockpit allows calling up a range of information such as hemodynamic results or various images from different systems that are used during the procedure in the intervention and control room.

In contrast to the previous approach which required multiple monitors, now a single computer mouse and one monitor are sufficient for making all the information relating to measurement results or from multimodality imaging and recording available at a fingertip and make the EP lab a better place to work.



Setup of Artis zee Cockpit and Artis zee Large Display in control and examination room.

The team involved in the project decided to install Siemens' Artis zeego system together with the integrated MAQUET MAGNUS table. The combination of the angiography system and the surgical table allows for truly multi-disciplinary usage of the OR.

200 Artis zeego systems have already been installed in hybrid ORs around the world. Due to its robotic technology it allows for extremely flexible positioning in the crowded OR environment and offers a number of unique benefits no other system on the market can deliver. Being a floor-mounted unit, Artis zeego keeps the ceiling space above the OR



Dr. Marc R. Katz, chief medical officer at Bon Secours Heart & Vascular Institute at St Mary's Hospital in Richmond, Virginia, US.

field free of imaging components and hence makes it the system of choice from a hygiene perspective as well. Highly advanced software solutions for a wide range of surgical disciplines provide the physician with excellent image guidance in 2D and 3D – right in the OR.

Dr. Katz on the usage of the cardiovascular hybrid OR: "We plan to utilize the hybrid suite to both enhance the spectrum of minimally invasive procedures we currently perform as well as to add new innovative options to help patients achieve superior results with rapid recovery and return to full activity."



## Cardiac Surgery: Greater Complexity and Greater Safety Alike for the Patients

Dante Pazzanese Cardiology Institute in São Paulo installs Brazil's first hybrid operating room in a surgical center, equipped with the Artis zeego from Siemens.

Founded in 1954, Dante Pazzanese Cardiology Institute (IDPC) is a public hospital specializing in heart diseases. It is being recognized as one of the most innovative cardiovascular centers in Brazil and abroad. The hospital performs diagnosis and therapy of cardiovascular disease, including heart and kidney transplantations.

In addition, IDPC also holds cardiology and cardiovascular surgery residency programs, training roughly 200 professionals per year.

Over the last decades, the institute has also stood out for pioneering research that has resulted in important techniques such as open-heart surgery to correct dextro-transposition of the great arteries ('Jatene Procedure') and geo-

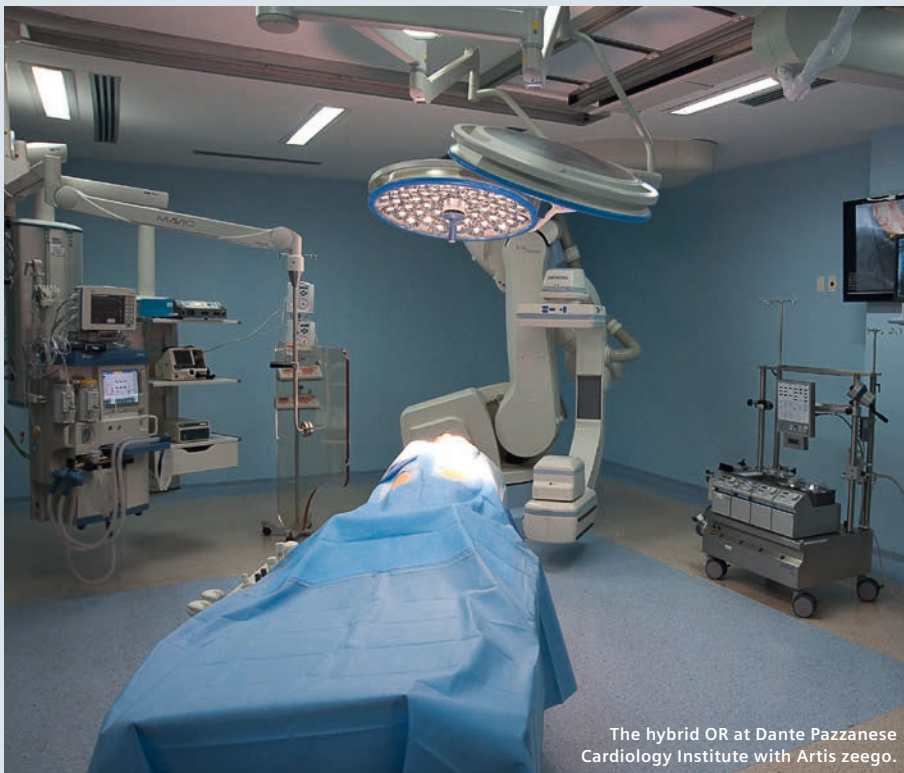metric reconstruction of left ventricular aneurysms, developed by Professor Adib Domingos Jatene, M.D. Another technique pioneered at the institute by Professor José Eduardo M. R. Sousa, M.D., was the use of sirolimus-coated stents to prevent restenosis in coronary arteries.

In March 2012, IDPC inaugurated Brazil's first hybrid OR. In an area of 130 m<sup>2</sup>, the room combines the equipment of a conventional OR with state-of-the-art interventional imaging. The Artis zeego, Siemens' robotic angiography system, was chosen mainly for its outstanding flexibility and high image quality in both 2D and 3D imaging, thanks to syngo DynaCT. It helps guide complex heart surgeries, as well

as vascular operations. Patients already attended to include both individuals with degenerative diseases, and pediatric cardiac patients.

IDPC cardiologist Alexandre Abizaid, M.D., explains that the hybrid OR allows for a new surgical concept – multidisciplinary – and expands the treatment potentials. "Before, we basically had two possibilities for treating a patient: percutaneous procedures, and open-heart surgery. With the hybrid room, we can perform both in the same room, even at the same time. If we decide for a percutaneous approach and the patient suffers a complication, such as an obstruction, it is possible to convert immediately to open surgery without the need to transfer the patient to another room," said the specialist. Now being used full-time, IDPC's hybrid room has proven especially beneficial in four fields: coronary surgeries with the introduction of mammary grafts followed by the placement of stents; valve substitutions; birth defects (such as hypoplasia of the left ventricle), and aortic diseases.

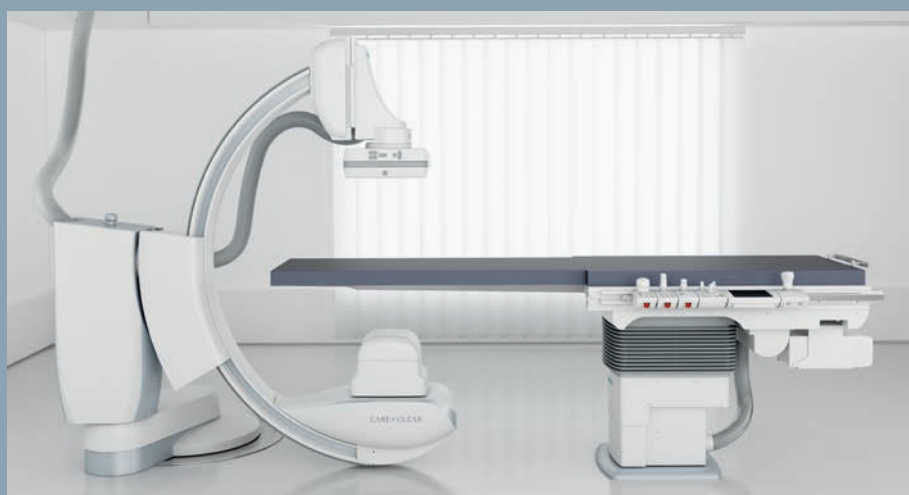
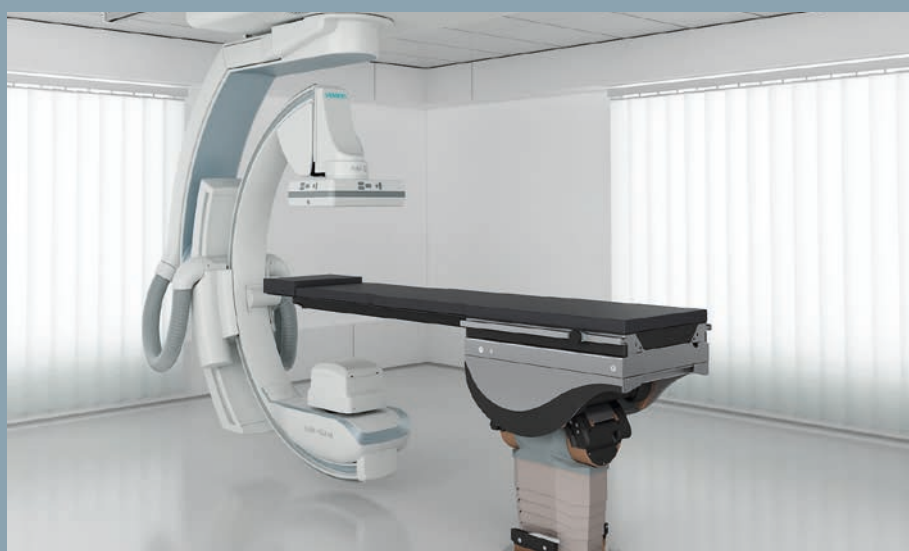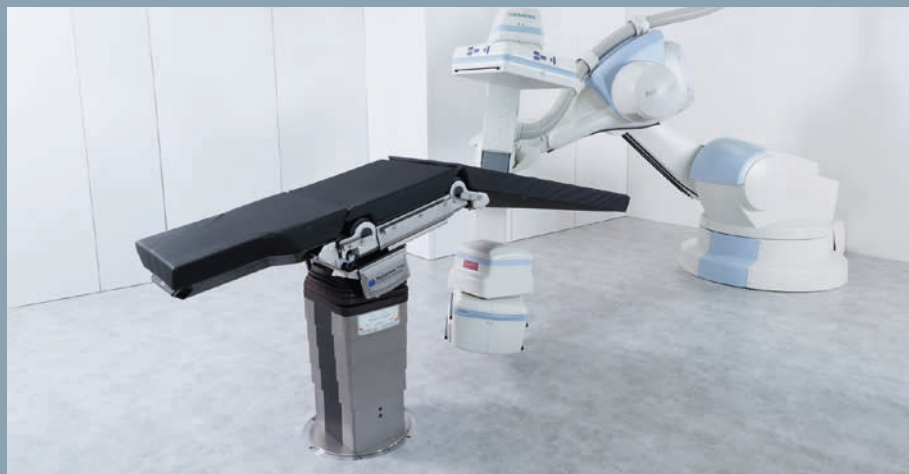"The resources of a hybrid OR allow specialists to operate very complex cases while at the same time providing greater patient safety," said Dr. Abizaid. Artis zeego represents a significant advancement thanks to its high quality images and ergonomic features. "During the procedure, a surgeon can resort to CT-like images produced intra-operatively by the system and verify the extension of lesions or the correct placement of stents, for example," described Dr. Abizaid. "As soon as the machine is no longer necessary for the procedure, the robotic arm is placed in a corner of the surgical room, freeing up space for the other stages of the procedure," said the specialist.



The hybrid OR at Dante Pazzanese Cardiology Institute with Artis zeego.

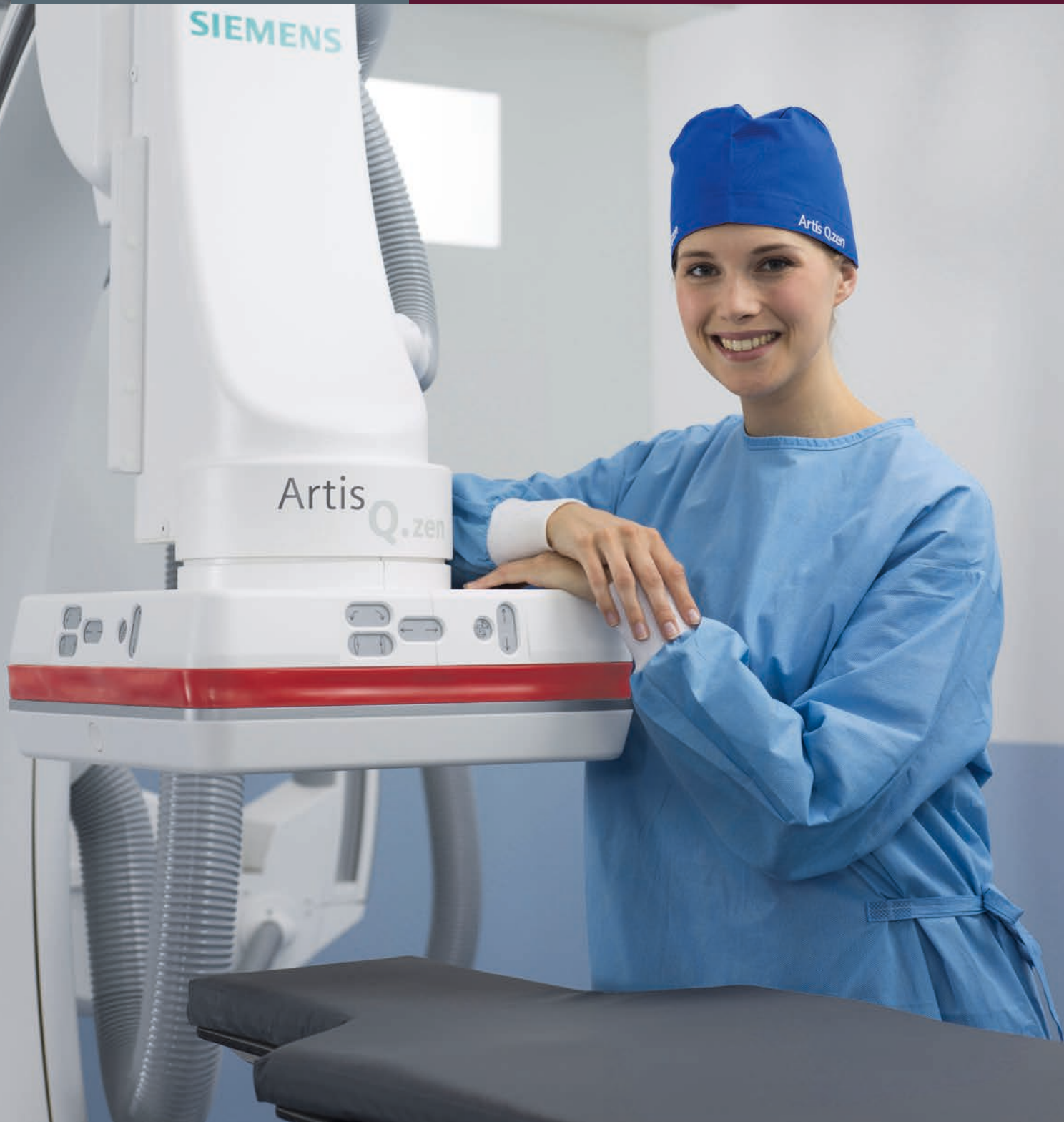

# Excellent Fit for the Hybrid OR



The new product range of Artis Q also is an excellent fit for hybrid operating rooms. Hybrid ORs feature an angiography system along with all the equipment of a standard operating theater, allowing for new procedures and a wider patient range to be treated. Artis zeego and Artis Q ceiling systems are now available fully integrated with different configurations of the MAQUET MAGNUS OR table. It comes with a one-piece carbon top for artifact-free imaging with full body coverage and different configurations of a segmented tabletop for superior patient positioning. The benefit of the combination of an angiography system with a surgical table is that the OR can be used in a truly multi-disciplinary fashion, allowing for minimally invasive treatment, hybrid operations, and open surgery. Furthermore, the requirements of a multitude of surgical disciplines can be catered to – be it a sitting patient position with a segmented tabletop in neurosurgery or head-to-toe coverage in vascular procedures with a long, fully radiolucent carbon fiber table. In addition, Artis zeego and ceiling-mounted systems are also integrated with different versions of the TRUMPF TruSystem 7500 OR tables which offer similar benefits. The tried-and-proven Siemens Artis OR table, featuring a fully free-floating tabletop, also remains an essential part of the available portfolio. All tables are now also available with a wireless footswitch, giving the user more flexibility and hygienic advantages compared to the wired version. This selection of three fully integrated table families represents the widest portfolio of integrated surgical tables on the market, allowing Siemens to respond best to very specific customer needs and preferences.

# Artis Q & Artis Q.zen



# Pushing the Frontiers of Interventional Imaging

At this year's RSNA, Siemens Healthcare's business unit for Angiography and Interventional X-ray systems (AX) introduces two new product lines for interventional imaging: Artis Q and Artis Q.zen. They stand for a visionary breakthrough in X-ray generation and detection that achieves an unprecedented level of performance, precision, and sensitivity.

## Visionary in performance

**The new tube – heart of the Artis Q and Artis Q.zen imaging system.**

In a light bulb, the filament is the element that produces light. Thomas Edison tested over 6,000 different filaments before he found one that was tough enough to stand up to daily use.

### Flat Emitter Technology for all focal spots

- up to 70 % increased visibility of small vessels compared to previous tube technology enabled by small square focal spots
- up to 43 % shorter pulses enabled by higher pulse power

Similarly, the emitter lies at the heart of an X-ray tube. The more heat an emitter can withstand, the better it can per-

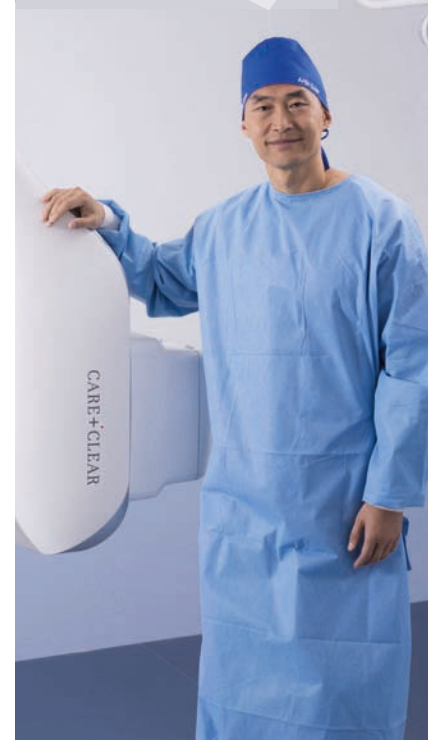form. "High performance" means more power and smaller focal spots. We are the only company on the market that has mastered the art of constructing a tube with a flat emitter. Every other tube uses a filament emitter not too different from what was found in Edison's original light bulb. The flat emitter, by comparison, is as revolutionary as an LED lamp. Flat emitters are precisely-machined plates that are much thicker than the conventional filaments. For this reason, they can handle higher temperatures to provide high power for short pulses.

**The new X-ray tube scores high in all areas – it combines small focal spots with high pulse power.**

The higher power of the flat emitter tube allows for up to 43 % shorter X-ray pulse width. The short pulse helps remove motion artifacts much like a

To help our customers fight the most threatening diseases and make the transition to next-generation healthcare, we have raised the bar and developed the Q technology.

**Here are the Q facts!**





camera flash or a strobe light does in photography. Smaller focal spots also boost performance. Like a pinhole camera that takes good pictures if the aperture – the pinhole – is very small, the new flat emitter technology offers the same effect. The source of the X-ray has a smaller aperture, so the image will also be sharper. But even though challenging, improving the tube was not enough for us.

## Visionary in sensitivity

**Artis Q.zen: The first angiography system with a crystalline silicon detector for ultra-low-dose imaging.**

Creating order from chaos: Traditionally, detectors employ amorphous silicon wafers, which are irregular in structure. The nature of their composition limits circuit density because it is difficult to etch fine structures onto a chaotic “canvas.” This, in turn, leads to electronic noise. In contrast, the new detector technology introduced with the Artis Q.zen uses crystalline silicon wafers, which are uniform in structure and allow higher circuit density.

- First X-ray detector based on crystalline silicon technology used in interventional imaging systems
- The active matrix dramatically reduces electronic noise
- Less electronic noise enables ultra-low-dose imaging

The Artis Q.zen is the first angiography system ever to be equipped with crystalline silicon technology. Getting there has been a tremendous challenge. But now, certain properties of crystalline silicon immediately generate specific improvements in interventional imaging. The higher circuit density of crystalline silicon allows amplification at the level of individual pixels. And amplification at the pixel level in the crystalline silicon detector was the key to significantly reducing electronic noise.

Basically, the detector opens up a whole new field of interventional applications in ultra-low-dose imaging. A range in which – until now – electronic noise destroyed too much of the signal to produce satisfying images.

## Visionary in precision

**New applications help physicians stay at the cutting edge and make interventions fast, live, and personal.**

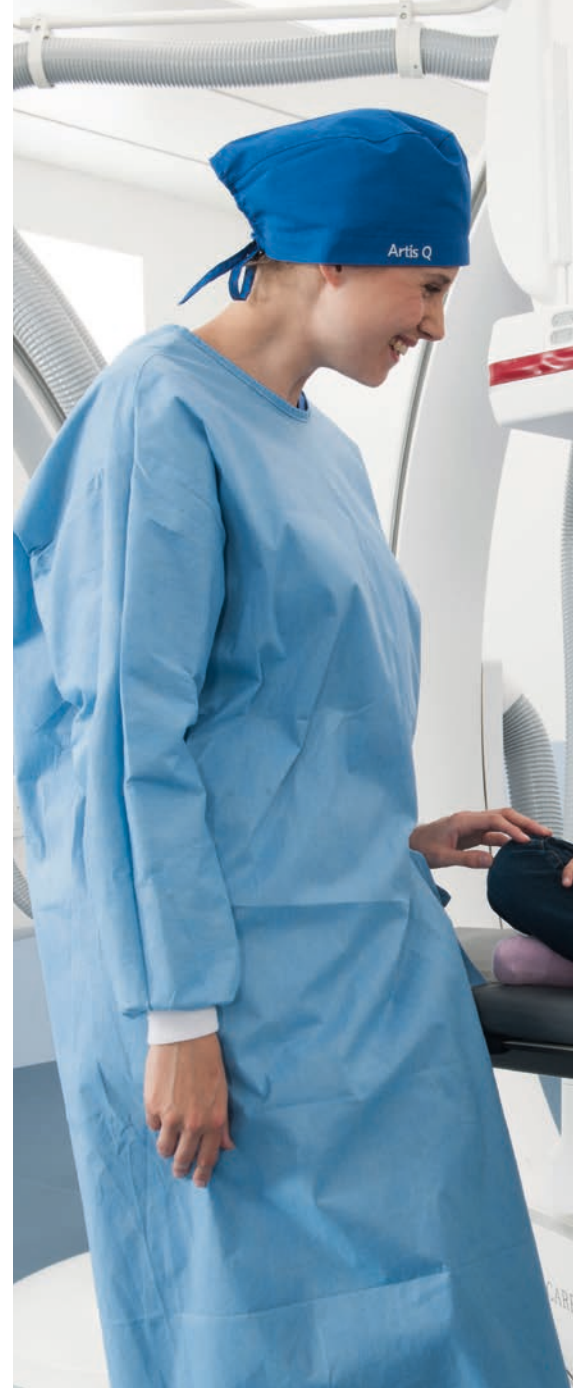Day after day, our curiosity and passion for innovation inspire us to develop new tools for enhanced visualization. Together with its range of new applications, Artis Q provides ultra-high resolution for safer guidance and better outcomes. The AX vision was to develop tools for the cath lab that “visualize the invisible” in 2D and 3D imaging. We are convinced that the Q technology will redefine precision because precision has to be personal, fast, and live. Need some examples of what we mean? Here you go:

### Precision is detailed

The new large detector with high dynamic range delivers due to the 16-bit analog-digital conversion over 65,000 gray scale values for precise 3D reconstruction. This leads to increasing contrast resolution and providing homogenous image quality even at image borders.

### Precision is personal

*syngo* DynaPBV Body is a new 3D functional imaging protocol that provides additional physiological information about the patient’s condition before and during interventional treatment. Blood volume maps visualize the distribution of blood in lesions and surrounding tissue. This insight into perfusion aids doctors in characterizing lesions. A further step towards personalized treatment. (see also page 14)







### Precision is fast

The new *syngo* Dyna3D HighSpeed feature allows the Artis zeego to perform a 200 degree rotation in less than three seconds. Speed is good for patients, especially those with compromised kidney function. And *syngo* Dyna3D HighSpeed saves a significant amount of contrast agent, because the faster you scan, the less contrast you need to inject. Speed is also essential for lung scans, where patients have to hold their breath. They really appreciate imaging that lasts only a few seconds. (see also page 26)

### Precision is live

Accurate visibility is crucial in interventional cardiology. Increasingly complex procedures require precise information about the stent to be implanted, as well as previously deployed stents, the location of coronary lesions, and cardiac anatomy. With CLEARstent Live, the enhanced imaging of the devices is now displayed live, while the doctor pushes a catheter through the blood vessel. Another unique feature: The images remain available for review after the procedure is complete – both for documentation purposes and to show the patient what has been done. (see also page 36)

### Precision is more

The integrated IVUSmap application combines the advantages of intravascular ultrasound (IVUS) and angiography through co-registration. By linking the two modalities, the application provides spatial localization for IVUS images within the coronary tree and adds information about vessel, volume, and wall structure to angiography.

### “Could you ever imagine a Ferrari in gray?”

Artis Q and Artis Q.zen are top-of-the-line: both visionary in performance thanks to a unique, flat-emitter technology and visionary in precision with new advanced guidance tools to support safer procedures.

Artis Q.zen is also visionary in sensitivity with its unique crystalline detector technology enabling high image quality for ultra-low-dose imaging.

And it is no surprise that the design shows just how exceptional the Artis Q.zen technology is: The crimson red stripe on the crystalline silicon detector makes a bold statement. Or could you ever imagine a Ferrari in gray?

Have a closer look at:

[www.siemens.com/artis-q](http://www.siemens.com/artis-q)

[www.siemens.com/artis-q-zen](http://www.siemens.com/artis-q-zen)

### To overcome ...

physical boundaries in X-ray generation, we developed a new flat emitter X-ray tube to generate powerful pulses with small focal spots – for more certainty when treating obese patients or for steep angulations. This is cutting-edge performance.

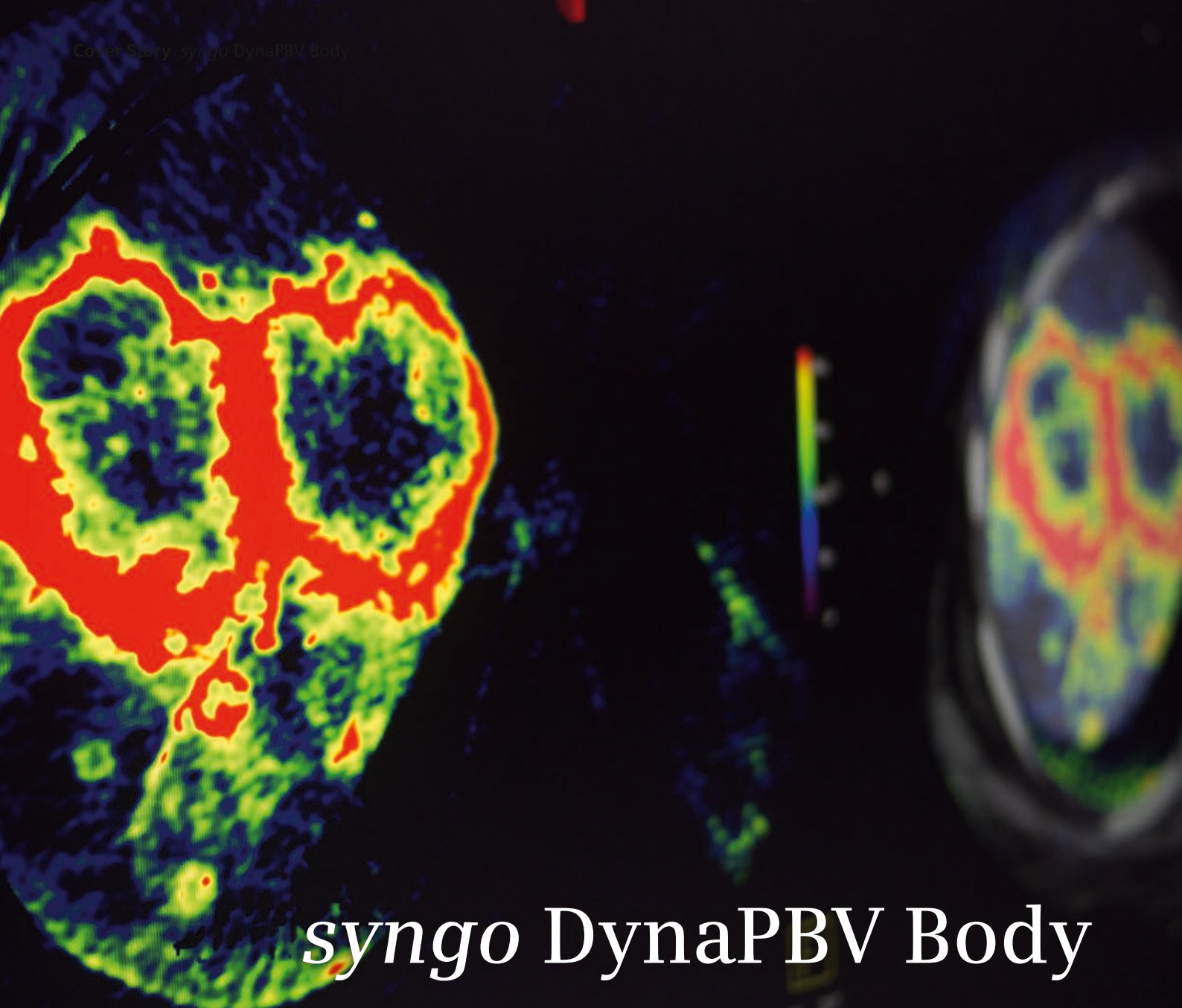
### A number ...

of new applications for Artis Q and Artis Q.zen are now available to support precise guidance and innovate radiology, cardiology, and surgery interventions – visionary precision in action.

### Dose saving ...

has always been our passion and we keep pushing the envelope to continually decrease radiation

exposure for patients and staff. Our vision was to build firstly a new tube boosting image quality up and radiation levels down and combine it with a detector that visualizes devices even at ultra-low doses, thanks to new dose-sensitive crystalline silicon detector technology. Today, the new crystalline silicon detector provides a quantum leap in sensitivity.



# *syngo* DynaPBV Body

Insight into Perfusion.  
Aiming for Patient-Individualized  
Interventional Therapy

For the first time in the interventional lab, the trend towards patient-individualized treatment during every step of interventional therapy will be fortified by the new 3D functional imaging *syngo* DynaPBV Body. It indicates the distribution of blood in lesions and surrounding tissue by means of color-coded cross-sectional blood volume maps and even allows qualitative measurement of blood volume in lesions in order to assess changes in perfusion over the course of treatment.

*syngo* DynaPBV Body is a new 3D functional imaging protocol that allows physicians to obtain additional – physiological – information about the patient's condition before and during interventional treatment. Blood volume maps visualize the distribution of blood in lesions and surrounding tissue. This insight into perfusion aids doctors in characterizing lesions. Qualitative blood volume measurements allow for comparison of blood distribution as an effect of treatment or of biological processes such as angiogenesis. The blood volume information is acquired in a double-sweep protocol where in an automatic run, a native *syngo* DynaCT acquisition is followed by a contrast-enhanced *syngo* DynaCT. As a consequence, with one *syngo* DynaPBV Body acquisition the physician

obtains cross-sectional blood volume maps in addition to the high-resolution *syngo* DynaCT contrast-enhanced images that allow for e.g., delineation of vessels for treatment planning. The novelty of *syngo* DynaPBV Body – in comparison to blood volume imaging in the brain provided by *syngo* Neuro PBV IR introduced in 2009 – is its ability to compensate for non-rigid patient motion caused by e.g., breathing. The potential of providing this kind of functional information to the interventional radiologist is vast. In interventional oncology for example, assessing tumor perfusion allows aligning the interventional therapy to the specific characteristics of a tumor, and supports defining the optimal end point in embolization procedures. Knowing the change in tissue perfusion

as a consequence of e.g., tumor embolization, tumor ablation or recanalization of occluded vessels in lower extremities via percutaneous transluminal angioplasty procedures, makes treatments safer, ensures a better outcome and might even be used as predictor for treatment response.

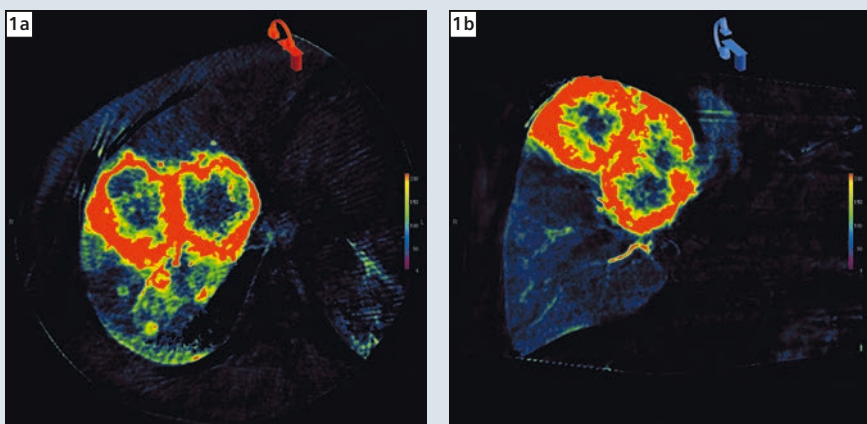
Read more about the experiences of interventional oncologists with *syngo* DynaPBV Body on the following pages.

Have a closer look at:  
[www.siemens.com/interventional-oncology](http://www.siemens.com/interventional-oncology)

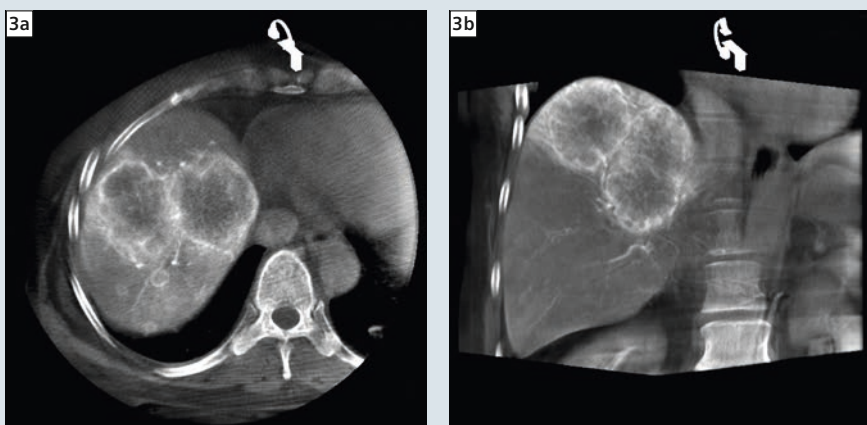
**Contact**  
[simone.henrichs@siemens.com](mailto:simone.henrichs@siemens.com)

“We will use *syngo* DynaPBV Body before and after embolization to assess the effectiveness and the safety of TACE.”

Prof. Philippe L. Pereira, M.D.,  
Director of Department of Radiology,  
Minimally Invasive Therapies and Nuclear Medicine,  
SLK Clinics, Heilbronn, Germany



**1** [a+b] Blood volume map of HCC showing two huge adjacent tumor nodules with necrotic core and elevated perfusion at the rim of the tumor – [a] axial view, [b] coronal view.

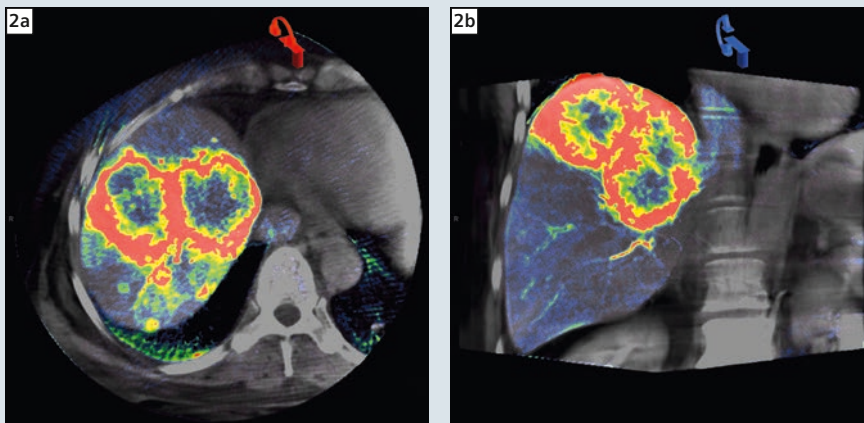


**3** [a+b] The *syngo* DynaPBV acquisition protocol also provides the contrast-enhanced *syngo* DynaCT as a standalone dataset e.g., for delineation of vessels – [a] axial view, [b] coronal view.



“We compared the blood volume of pre-procedural liver *syngo* DynaPBV with CT perfusion. The initial results showed a very good correlation between them.”

Prof. Xu Jianrong,  
Department of Radiology,  
Renji Hospital,  
Shanghai, China



**2** [a+b] The *syngo* DynaPBV Body blood volume map can be loaded together with the native *syngo* DynaCT in order to embed the blood volume information into the corresponding anatomic information – [a] axial view, [b] coronal view.

Images to demonstrate *syngo* DynaPBV Body courtesy of Prof. Thomas Vogl, M.D., Department of Diagnostic and Interventional Radiology, University of Frankfurt/Main, Germany

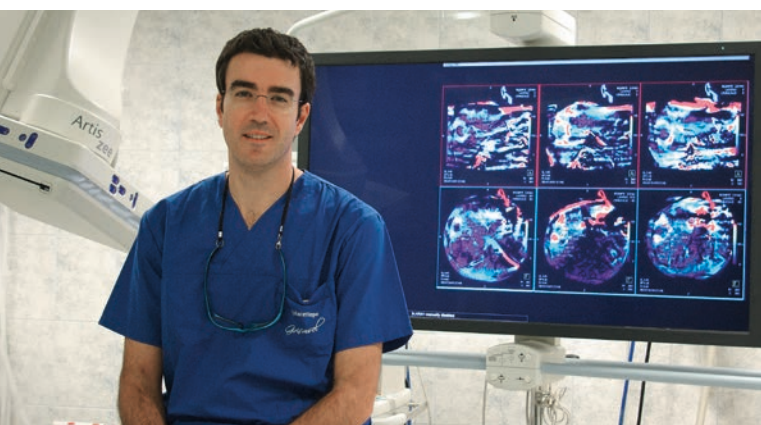## Main Benefits

- Move towards personalized therapy in the interventional lab
- Supports identification of the optimal end point during embolization
- Potential to identify non-responders directly after interventional therapy

# Preparatory Arteriography for Isolation of the Hepatic Arterial Bed Prior to Radioembolization Therapy Supported by *syngo* DynaPBV Body

Courtesy of Bora Peynircioğlu, M.D.,

Associate Professor of Radiology, Department of Radiology, Hacettepe University Hospital, Ankara, Turkey



**Bora Peynircioğlu, M.D.,**  
Associate Professor of Radiology,  
Department of Radiology,  
Hacettepe University Hospital,  
Ankara, Turkey

## Patient history

A 46-year-old male presented with chronic upper abdominal pain and jaundice. Subsequent CT examination revealed a large pancreatic mass with additional lesion (partially necrotic) in the liver showing similar contrast enhancement pattern.

## Diagnosis

Patient was diagnosed with liver metastasis from pancreatic cancer not eligible for surgical resection, and did not respond to chemotherapy. A radioembolization (RE) therapy was planned.

## Treatment

During the preparatory arteriography for RE, C-arm CT images with perfusion study were both obtained before and right after the embolization of the gastroduodenal artery (GDA) (see fig. 1a, b and 2a, b). This study is routinely performed in every patient who is a candidate for RE therapy and aims to prevent non-target Yttrium90 (Y90) embolization in case of reflux during

actual RE session. Potential extrahepatic shunts (to the esophagus, stomach or intestine) from the hepatic arterial bed are to be micro-catheterized and occluded (mostly with microcoils) and pulmonary shunt is to be measured with subsequent infusion of technetium tagged macroalbumin aggregate, which simply mimics the behavior of actual Y90 infusion. In this particular patient, the GDA was embolized with microcoils not because of feeding the liver metastasis but only for preventing reflux during actual Y90 infusion, which successfully took place within ten days after this preparatory session. This type of side branch embolization prior to RE therapy is considered to be mandatory, however, eventually leading to increased tumor perfusion caused by redistribution of the hepatic arterial blood flow/volume. A significant perfusion increase can be appreciated in both color perfusion maps and in qualitative measurements representing real-time documentation of blood flow redistribu-

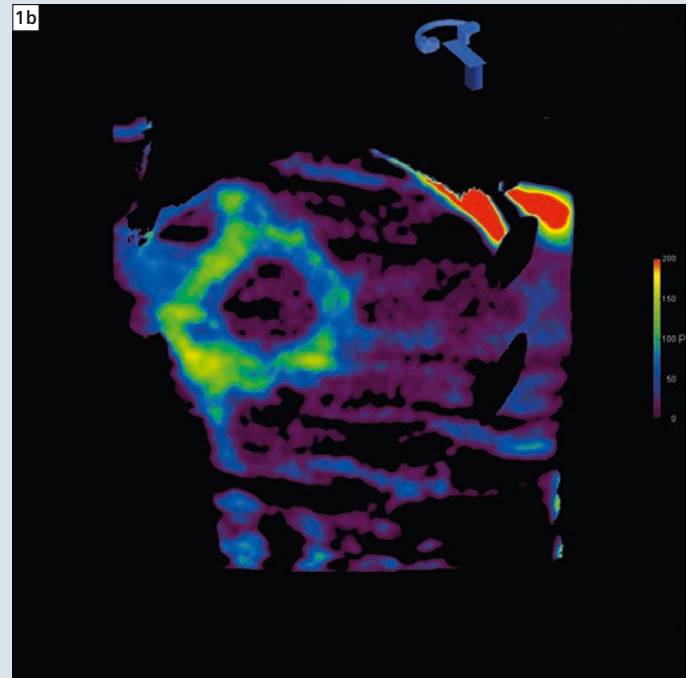
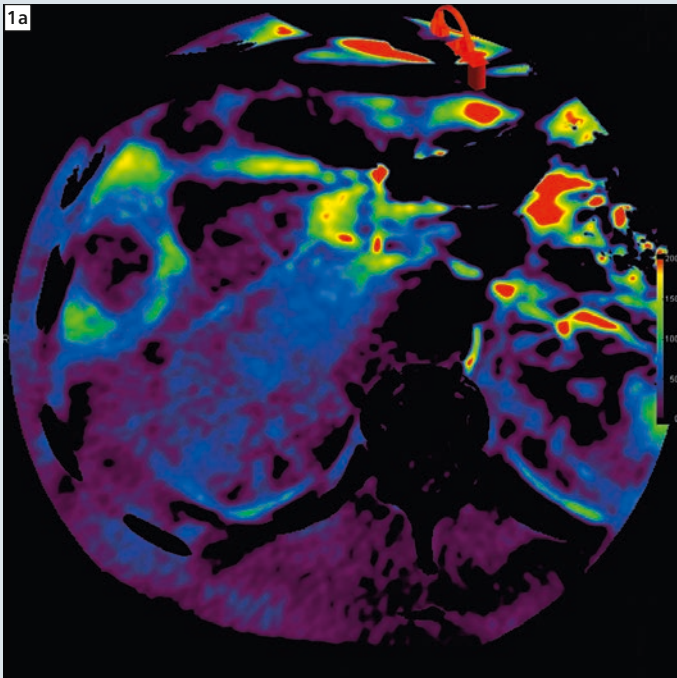
tion. For the first time in the angio lab, this unwanted increase in tumor perfusion due to occlusion of the GDA could be shown through *syngo* DynaPBV Body blood volume maps.

## Comments

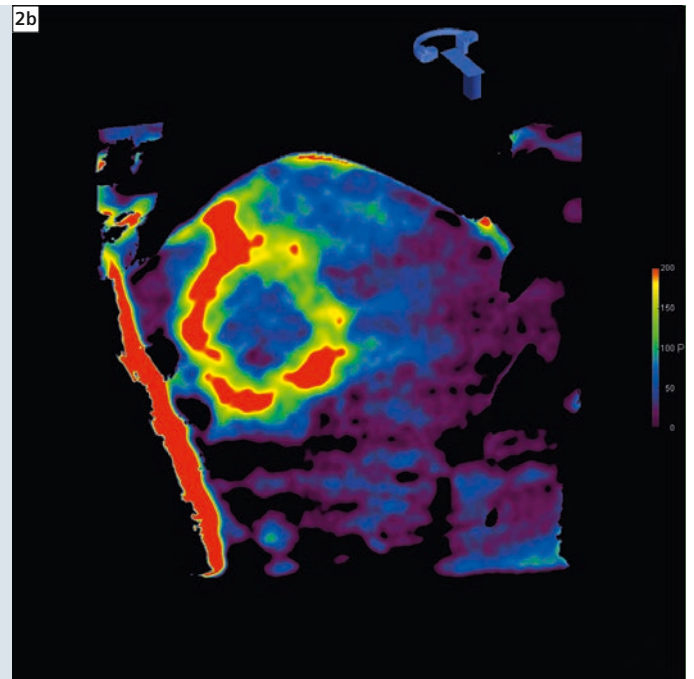
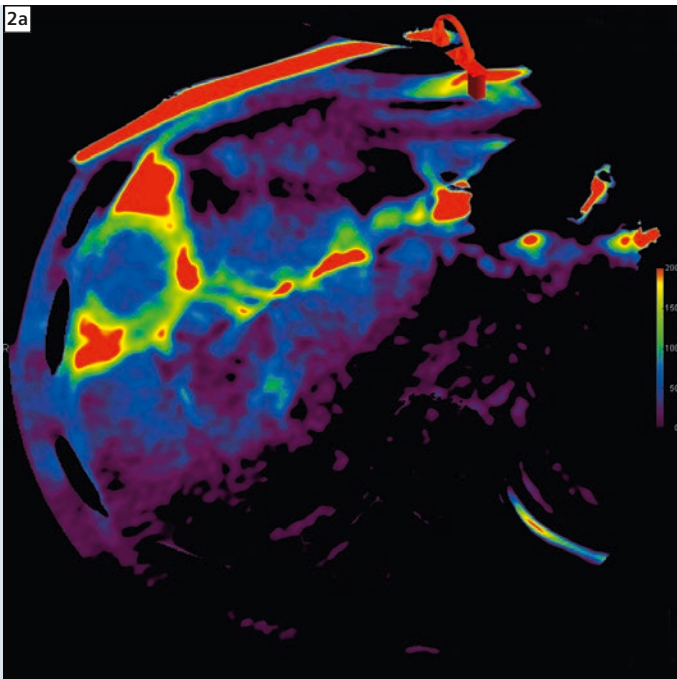
As the *syngo* DynaPBV Body documents the significant real-time increase in the tumor perfusion (see fig. 2a, b), interventionalists, oncologists, and nuclear physicians are well advised to keep the waiting period between the preparatory arteriogram and actual treatment session as short as possible particularly if the GDA is to be embolized. Although further studies with more patients are warranted, any physician aware of this fact would take the appropriate measures immediately.

## Contact

simone.henrichs@siemens.com



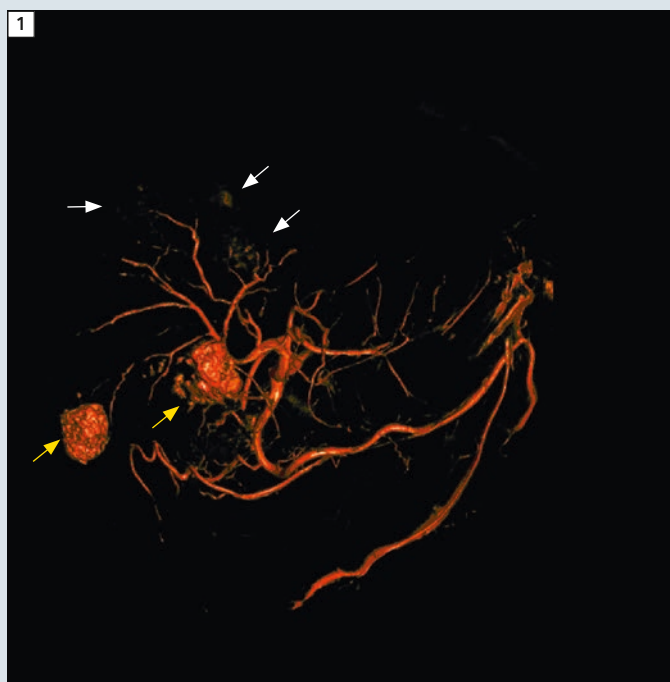
**1** [a+b] syngo DynaPBV Body images obtained before the embolization of the GDA – [a] axial, [b] sagittal view.



**2** [a+b] syngo DynaPBV Body images obtained right after the embolization of GDA with microcoils show a significant increase in tumor perfusion caused by redistribution of the hepatic arterial blood flow/volume – [a] axial, [b] sagittal view.

# Transarterial Chemoembolization (TACE) in Multifocal Primary Liver Cancer Supported by syngo DynaPBV Body

Courtesy of Philippe L. Pereira, M.D., PhD, EBIR, and Kristina Krüger, Department of Radiology, Minimally Invasive Therapies and Nuclear Medicine, SLK Clinics GmbH, Heilbronn, Germany



**1** 3D-reconstruction during arteriography for planning. Post-TACE imaging of 2 HCCs in segment 5 and 6 (yellow arrows) and 3 hypervascular non-treated HCCs in liver segments 7 and 8 prior to chemoembolization (white arrows).

## Patient history

A 65-year-old male with non-specific bilobar liver lesions was referred to our center due to diagnosis of suspected primary liver cancer for complementary examinations and to discuss therapy algorithm.

## Diagnosis

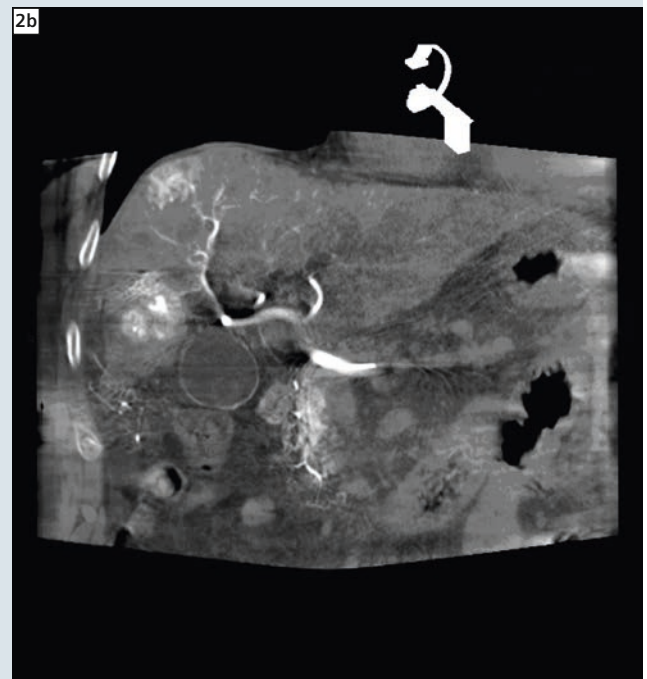
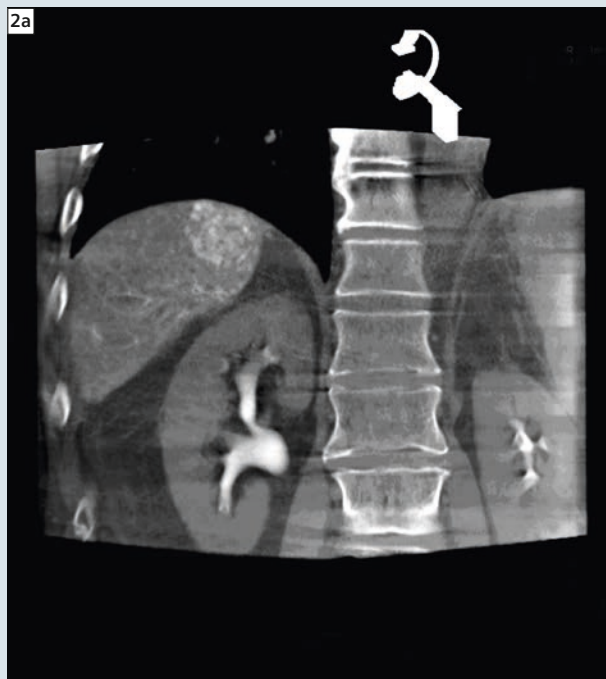First, a detailed laboratory examination showed a chronic hepatitis C virus (HCV) infection. A biopsy of one representative liver tumor was performed during contrast-enhanced ultrasound examination. To assess the extent of liver

involvement, a dynamic MRI completed the diagnosis. MR imaging showed a multifocal hepatocellular carcinoma and advanced liver cirrhosis. Both contrast-enhanced ultrasound and MRI of the liver showed HCC-typical characteristics



“*syngo DynaPBV Body* helps us in the definition of perfusion of the tumor, especially in hypovascular metastasis. When we use small particles for TACE of secondary liver tumors we are willing to use *syngo DynaPBV Body* before and after treatment to assess the effectiveness and the safety of TACE.”

Philippe L. Pereira, M.D., PhD, EIBR,  
 Director of the Department of Radiology,  
 Minimally Invasive Therapies and Nuclear Medicine,  
 SLK Clinics GmbH, Heilbronn, Germany



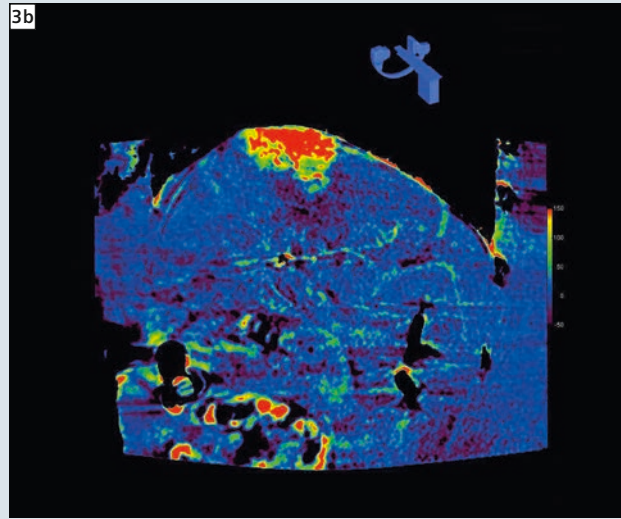
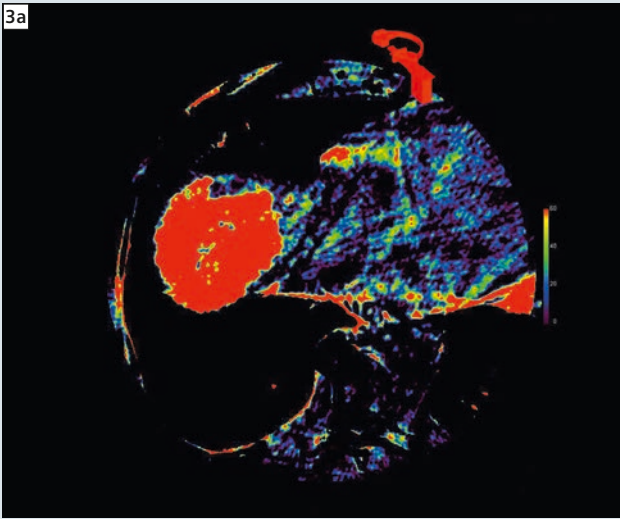
**2** *syngo DynaCT* images with hypervascular HCC [a] in segment 7 and [b] in segment 8. Note lipiodol and residual perfusion of the previously treated HCC in liver segment 6.

like wash-out phenomenon and “node-in-node” sign. Finally, the histopathology demonstrated a well differentiated HCC. No ascites or hilar lymph nodes and no extrahepatic disease were noted.

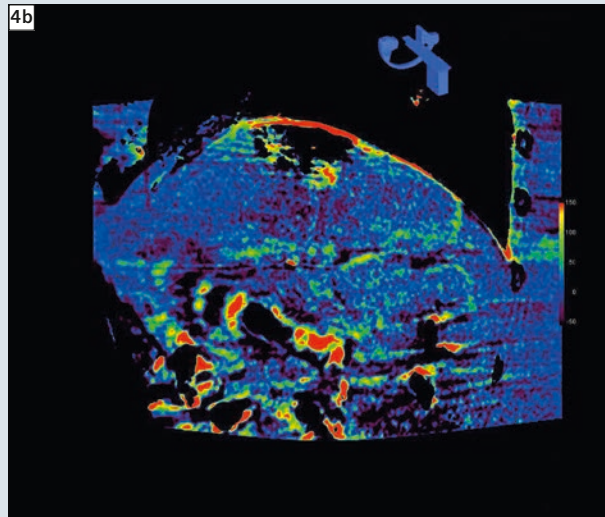
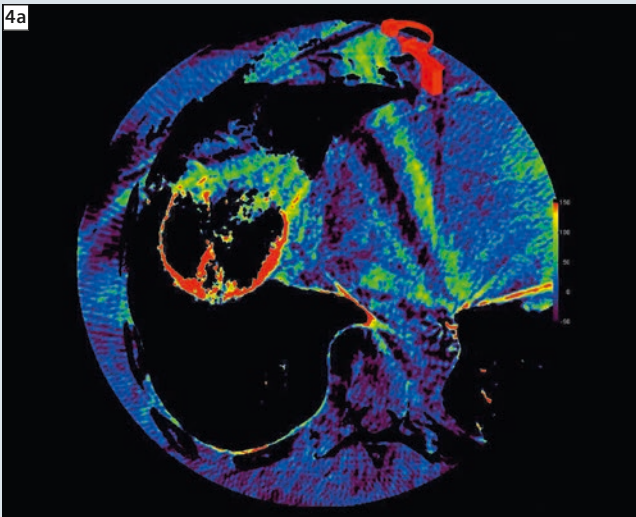
### Treatment

In a multidisciplinary tumor board we decided to treat the multifocal HCC in this patient evaluated as Child-Turcotte-Pugh “A” by performing a conventional TACE (cTACE) with farmorubicin and lipiodol. The patient’s situation improved

with a good partial response after the first cycle of cTACE of 2 hypervascular HCCs in segment 5 and 6 (yellow arrows on fig. 1). Unfortunately, liver function decreased at that time and further cTACE was not longer possible.



**3** Blood volume map of a 80x65 mm HCC tumor located in the liver dome before cTACE showing an increased and homogenous perfusion of the tumor. No necrotic areas, and normal perfusion of the remaining liver parenchyma.



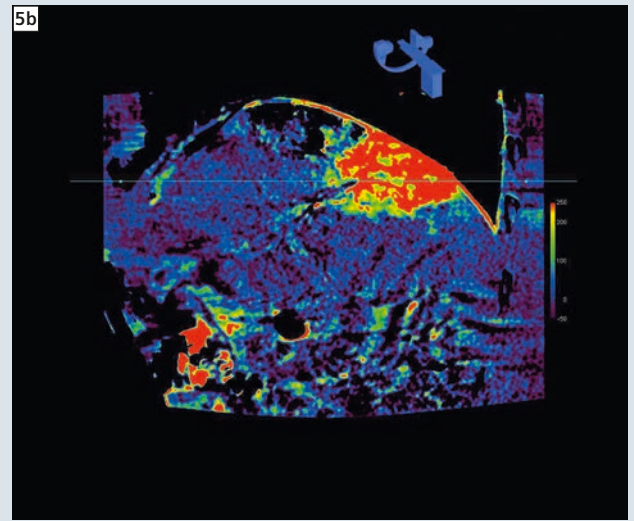
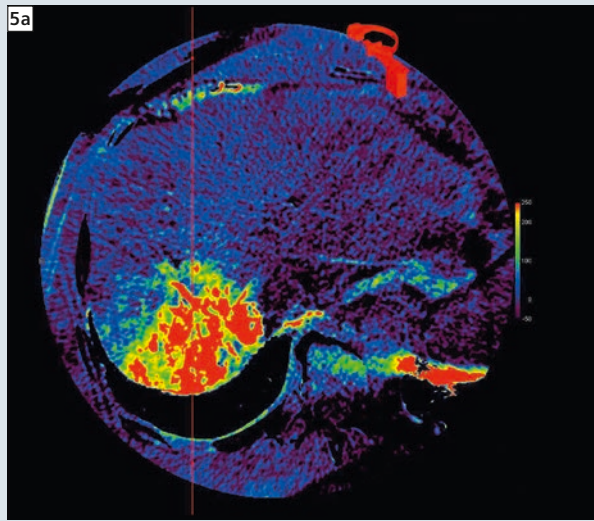
**4** Blood volume map of same HCC tumor during cTACE with farmorubicin and lipiodol showing a near complete hypoperfusion of the HCC.

a 4-month interval, cTACE of three HCC in liver segments 7 and 8 was possible with reduced dose of chemotherapeutic agent up to 25% (white arrows on fig. 1). At follow-up, non-treated HCCs in segment 7 and 8 of the liver showed a local progression. After a further therapy interval, liver function allowed a

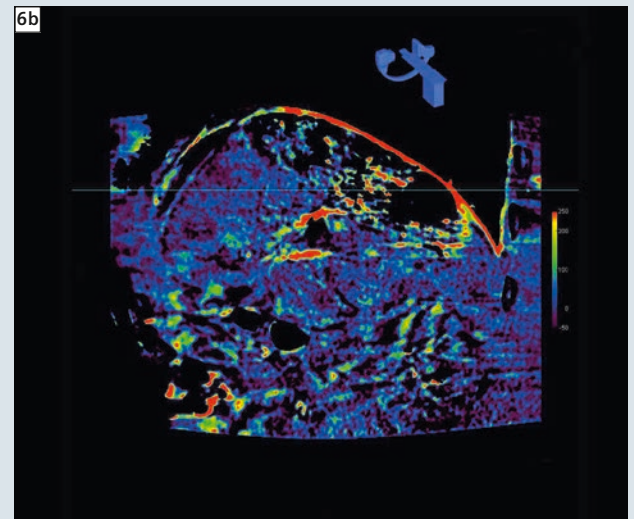
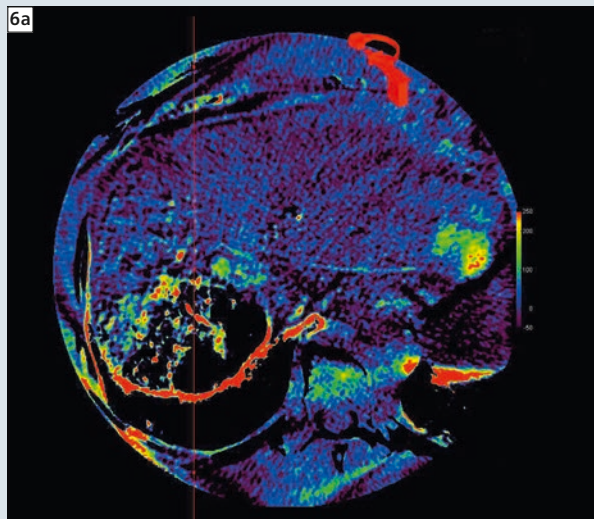
new cycle of cTACE to treat progredient HCCs in segment 7 and 8 (fig. 2a and 2b). To minimize the adverse effects of further TACE with respect to liver function, we decided to use Parenchymal Blood Volume (PBV) imaging to define an end point for monitoring the course of chemoembolization.

### Comments

At the beginning of each cTACE, a blood volume map of the liver was acquired using *syngo* DynaPBV Body functionality. The color-coded cross-sectional images show the hypervascularity of large HCCs (fig. 3a, 3b and 5a, 5b). At the anticipated end point of each chemoembolization, a second blood



**5** Blood volume map of a second infiltrative HCC located in the dorsal part of segment 8 and segment 7 before cTACE.



**6** Blood volume map of the second HCC after cTACE with devascularization of the tumor.

volume map was acquired to assess vascularization of tumors and tumor perfusion (fig. 4a, 4b and 6a, 6b). The lack of tumor perfusion during chemoembolization led us to stop the treatment, although the classical stasis of contrast medium was not reached. With respect to the reduced liver function in this

specific patient, one major aim of the treatment was to limit the amount of cytotoxic drug by assessing the optimal end point of TACE, based on perfusion imaging obtained with *syngo* DynaPBV Body. We also used *syngo* DynaCT images to perform the embolization as selectively as possible.

#### Contact

[simone.henrichs@siemens.com](mailto:simone.henrichs@siemens.com)



# Hepatic Blood Volume Imaging Within Catheter Labs

## Supported by *syngo* DynaPBV Body

Courtesy of Prof. Xu Jianrong, M.D.  
 Department of Radiology, Renji Hospital, China

### Patient history

A 70-year-old male with a 16-year history of type-B hepatitis and cirrhosis presented with symptoms of easy fatigability and anorexia for more than two months.

### Diagnosis

Regular upper abdominal CT scan found a space-occupying lesion of about 3.3 x 2.9 cm in the right posterior lobe of the liver. The lesion showed early enhancement in the arterial phase and early wash-out in the venous phase, which is a imaging sign of hepatocellular carcinoma (HCC) (fig. 1). There was no abnormal increase in alfa-fetoprotein (AFP) level.

Multi-slice CT perfusion was carried out with intravenous injection three days before the transcatheter arterial chemoembolization (TACE) procedure. Image post-processing was performed with *syngo* volume perfusion CT Body. *syngo* DynaPBV Body acquisition was performed in the interventional suite right before the TACE procedure. The catheter tip for the injection was located at proper hepatic artery. The *syngo* DynaPBV Body acquisition protocol is a 5s DSA protocol. The data is automatically reconstructed and visualized as color-coded blood volume map.

### Treatment

The blood volume (BV) map of CT perfusion showed a highly perfused round-shaped lesion in the right posterior lobe of the liver (fig. 2). The *syngo* DynaPBV map displayed a similar appearance (fig. 3 and 4). The BV value of the tumor spots and normal liver parenchyma sites were measured with both imaging methods. For this case, the BV of the tumor spots were 176.4 cc/1000 cc and 323.3 cc/1000 cc, the BV of normal liver parenchyma were 111.1 cc/1000 cc and 24.1 cc/1000 cc for CT perfusion and *syngo* DynaPBV Body respectively. The BV value with the *syngo* DynaPBV Body seems to be higher than that with perfusion CT. Possible reasons for this phenomenon might be the different injection protocols and different algorithms which were applied in these two methods.

### Intra-arterial liver *syngo* DynaPBV Body examination protocol

Imaging protocol	5s DSA
Contrast quantity	36 cc (370 mg/cc) diluted to 25 %
Injection rate	3 cc/sec
Injection duration	12 sec
X-ray delay	7 sec
Injection site	Proper hepatic artery
Reconstruction preset	DynaPBV-Body

### Comments

*syngo* DynaPBV Body for liver was proved clinically feasible in this case. The BV maps of the two different methods were visually comparable. Because of the different injection protocols, the BV value of CT perfusion represents the total blood volume from both hepatic artery and portal vein, while the qualitative BV measurement gained with the prototype software for performing flat panel blood volume measurements, only indicates the blood volume from pure arterial perfusion. To make the comparison more precise, we assumed that  $CT-PBV_{arterial} = CT-PBV \times HPI$  in the further study<sup>2</sup>. The HPI (hepatic perfusion index) represents the proportion of hepatic arterial perfusion out of the total perfusion. The initial result of this study showed although the qualitative BV measurement of *syngo* DynaPBV Body, is higher than CT perfusion, a good correlation between the BV values from the two different methods was achieved<sup>2</sup>.


Furthermore, *syngo* DynaPBV Body may enhance small tumor (diameter 0.5-1.0 cm) detection rate, which could affect the strategy of the procedure so as to optimize management of HCC diagnosis and treatment in future studies.

<sup>2</sup> Zhuang Z, Ye H, Beilner J, et al. Hepatic Blood Volume Imaging Using Flat Detector CT in Comparison to Conventional Multislice CT Perfusion: A Pilot Study in Patients with Hepatocellular Carcinoma. 2012; RSNA.

**Contact**  
 janina.beilner@siemens.com

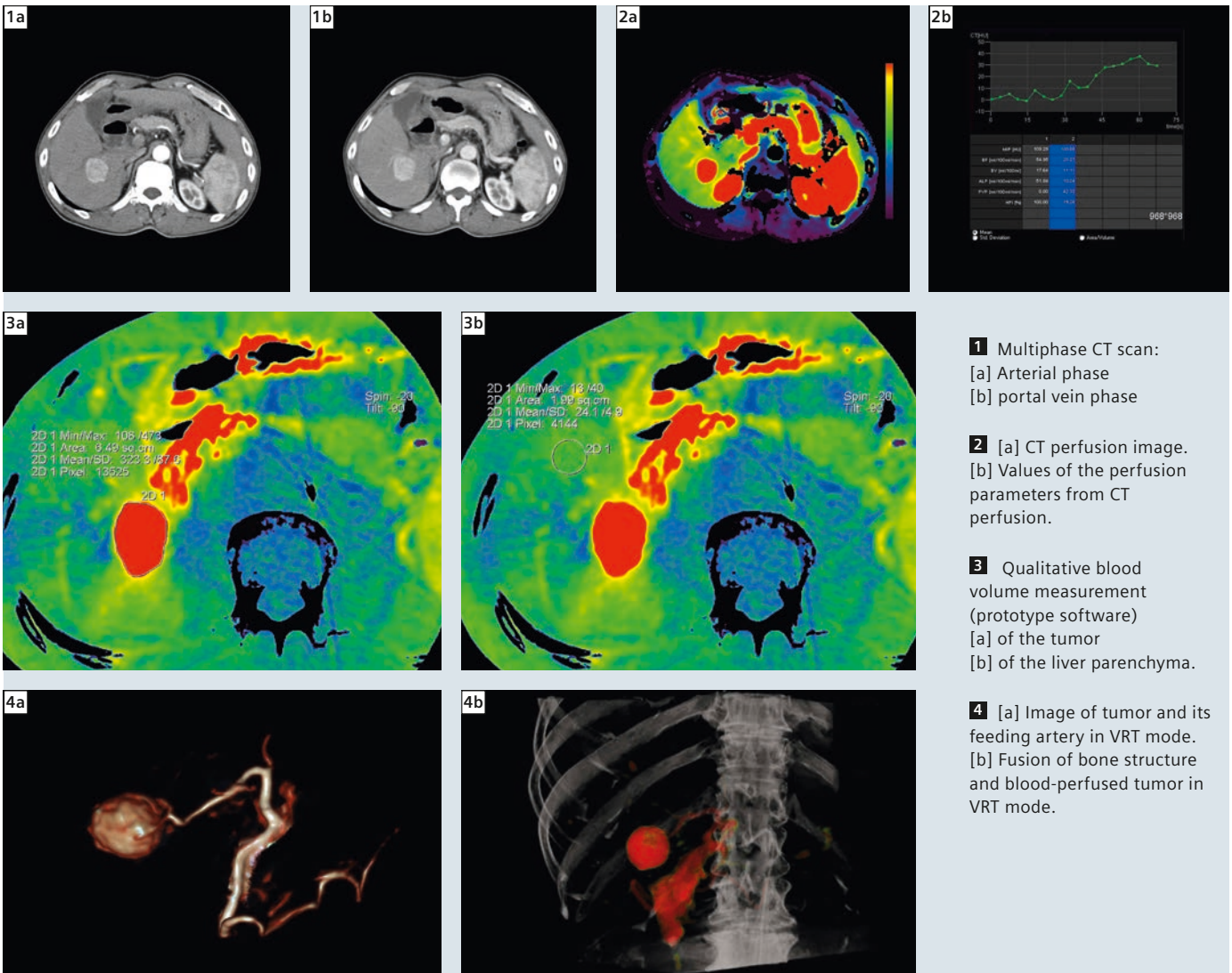


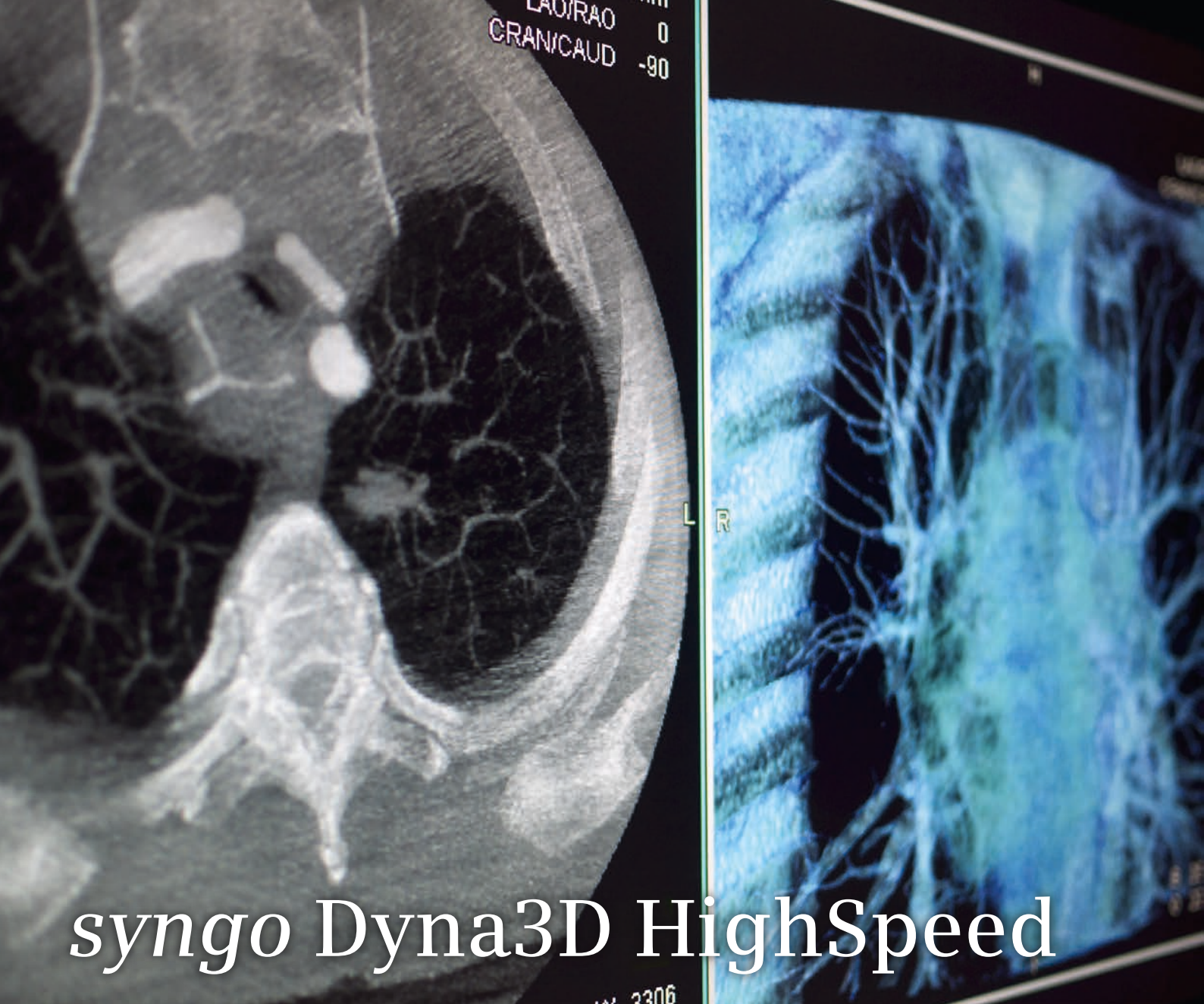
From left to right: Dr. Chi Jiachang, Dr. Zhuang Zhiguo, Prof. Xu Jianrong, and Dr. Zhang Xuebin.



“Until now, we compared the blood volume of pre-procedural *syngo* DynaPBV Body with CT perfusion. The initial results showed a very good correlation between them. In the next step, we want to do the *syngo* DynaPBV Body in liver cancer before and right after TACE to assess the effect of the procedure, making an optimal end point for embolization.”

Prof. Xu Jianrong, M.D., Department of Radiology, Renji Hospital, China





# syngo Dyna3D HighSpeed

Freeze the Motion  
for a Better Treatment



## Artis zeego with Q technology reaches new boundaries of speed with syngo Dyna3D HighSpeed

With 3D imaging, physicians have valuable support in visualizing e.g., bronchi or vessels, for planning and therapy. Now syngo Dyna3D HighSpeed goes one step beyond. It is a unique benefit of the new Artis zeego robotic-assisted C-arm system and provides virtually unlimited movement and reaches new boundaries of speed.

The flat detector rotates 200° approx. 50% faster to deliver the image in less than three seconds. This faster acquisition has three main benefits: the possibility to reduce contrast medium, the minimization of motion artifacts

(i.e., breathing artifacts), and increased patient comfort by cutting breathhold time by nearly half.

Movement is always a challenge in obtaining a diagnostic image, and the faster rotation allows for a shorter patient breathhold. This enables acquiring 3D datasets even in very sick patients and in challenging organs like the lung. The result is great image quality and sharp delineation of e.g., arteries and their small branches.

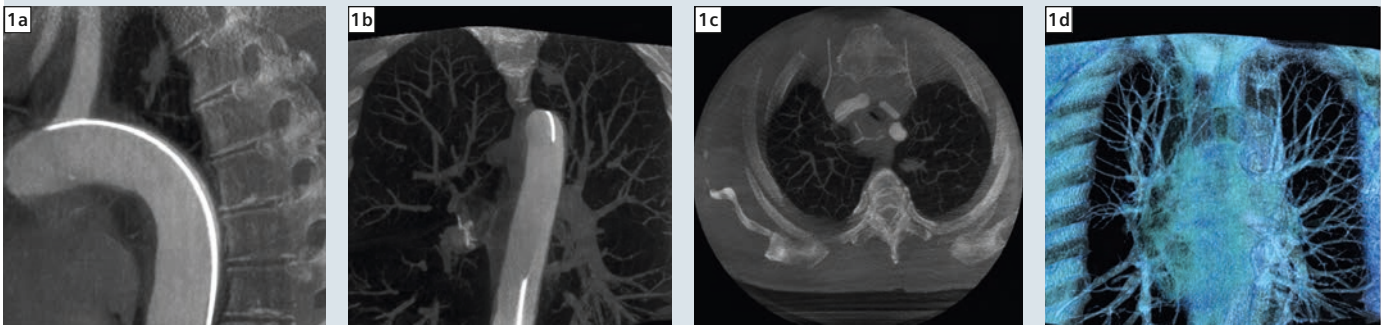
An additional benefit of syngo Dyna3D HighSpeed is the savings in contrast medium. With the rotation time cut

nearly in half, up to 30% contrast medium can be saved compared to a regular 5s protocol.

The new Artis zeego delivers unparalleled applications like syngo Dyna3D HighSpeed, greatly benefitting the treatment of the thoracic and abdominal organs.

### Contact

mariana.aquino@siemens.com



**1** [a-d] Transarterial thoracic chemotherapy supported by syngo Dyna3D HighSpeed  
Images courtesy of Prof. Thomas Vogl, M.D., Department of Diagnostic and Interventional Radiology, University of Frankfurt/Main, Germany.

## Main Benefits

- Fewer motion artifacts, less contrast media (~30%)
- Image acquisition in a single breathhold (less than 3 seconds)
- Better visualization of moving organs (i.e. lungs)

# Transarterial Thoracic Chemotherapy Supported by *syngo* Dyna3D HighSpeed

Courtesy of Prof. Thomas J. Vogl, M.D., Stefan Zangos, M.D., PhD,  
Institute for Diagnostic and Interventional Radiology at the University Hospital of Frankfurt/Main, Germany.



“*syngo* Dyna3D HighSpeed is a new technology allowing faster 3D interventional imaging in less than three seconds. This results in fewer motion artifacts and sharper images while imaging moving organs, 30% less contrast material and more treatment confidence.”

Prof. Thomas J. Vogl, M.D.,  
Director of the Institute for Diagnostic and Interventional Radiology  
at the University Hospital of Frankfurt/Main, Germany

## Patient history

61-year-old female with adenocarcinoma of the lung. She suffers from recurrent tumor after surgery, radiation and systemic chemotherapy. Actual third line therapy protocol.

## Diagnosis

No systemic metastases, local intrapulmonary infiltration.

## Treatment

Transarterial thoracic chemotherapy with a mix of mitomycin, gemcitabine and cisplatin injected in the ascending aorta performed after using the *syngo* Dyna3D HighSpeed protocol with the following injection protocol:

### Examination protocol

Flow rate:	15 cc/sec
X-ray delay:	2 sec
Volume:	75 cc (25 cc contrast, 50 cc NaCl)

## Comments

The very short acquisition time of less than 3 seconds makes it possible to acquire 3D datasets without breathing motion artifacts even in very sick

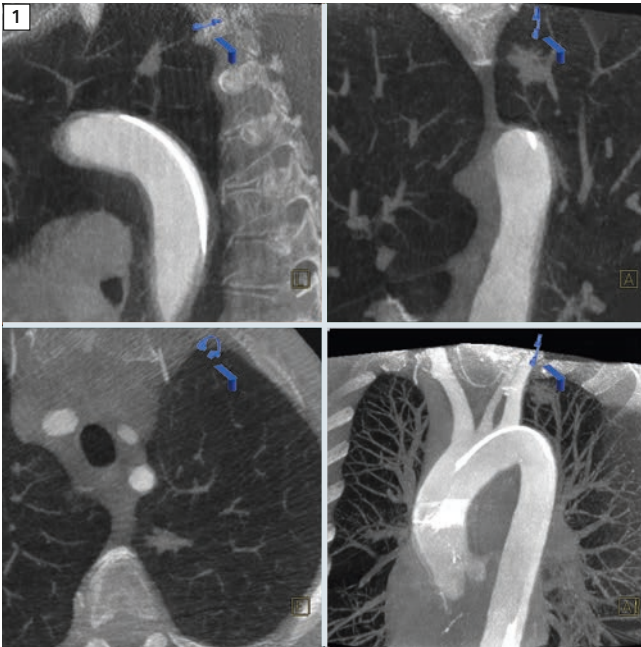
patients. The presented images show very good and sharp delineation of pulmonary arteries and their small branches, the tumor, as well as the intercostal arteries.

*syngo* Dyna3D HighSpeed allowed performing the 3D acquisition with only 25 cc of contrast and helped to save nearly 30% contrast media compared to a regular 5 sec. protocol. In comparison a regular 5 sec. protocol would have required a 7 sec. injection protocol, resulting in a total volume of 105 cc with 35 cc of contrast.

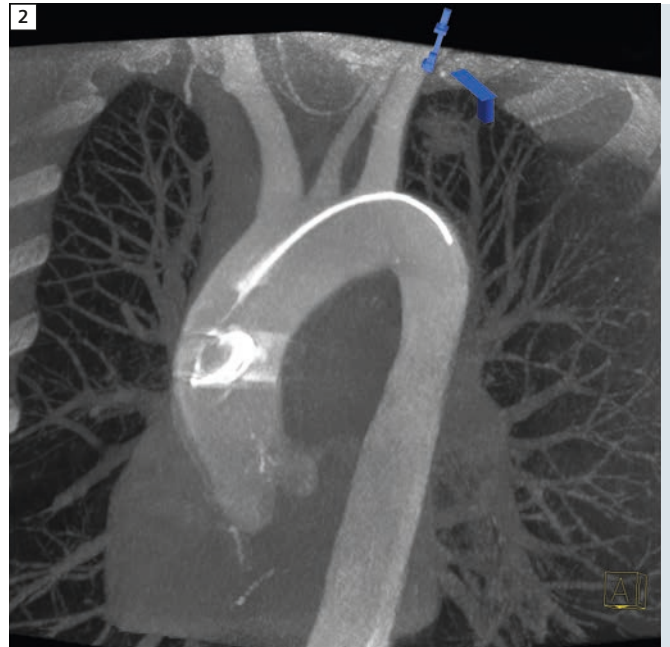
## Contact

[martin.rodén@siemens.com](mailto:martin.rodén@siemens.com)

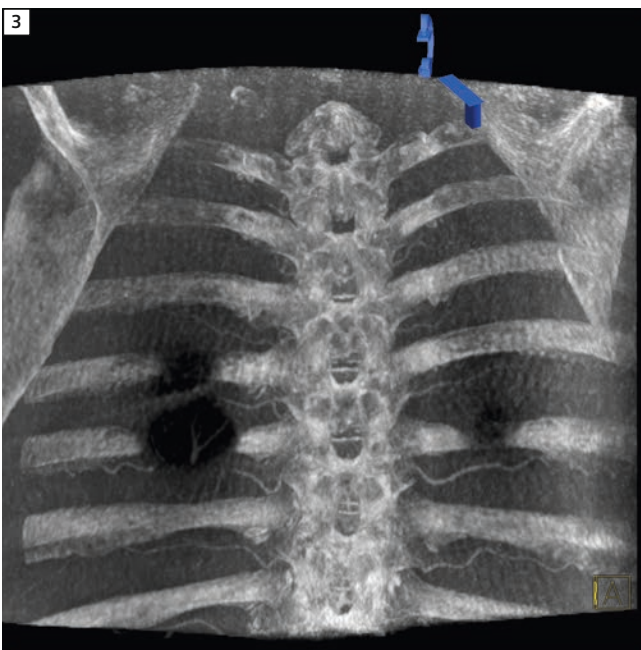




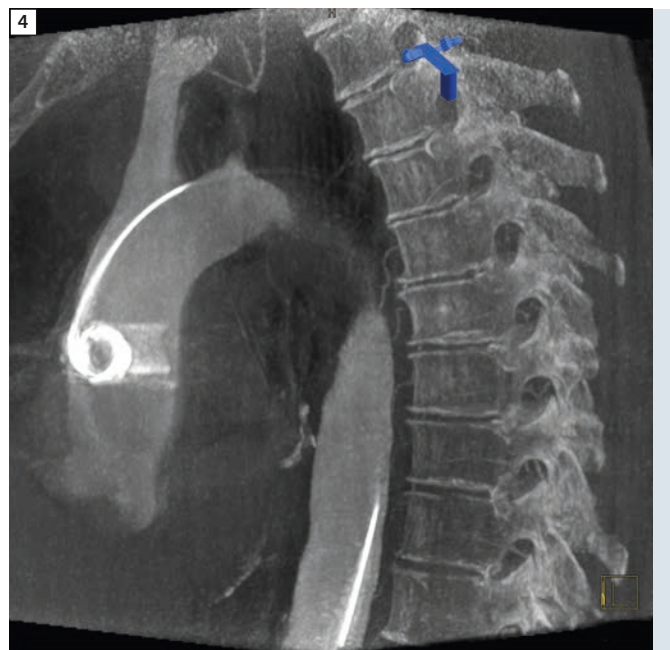
**1** MIP visualization of tumor (arrow) in the left lung.



**2** MIP visualization of pulmonary arteries with the tumor (arrow).



**3** Coronal MIP visualization of intercostal arteries.



**4** Sagittal MIP visualization of intercostal arteries.



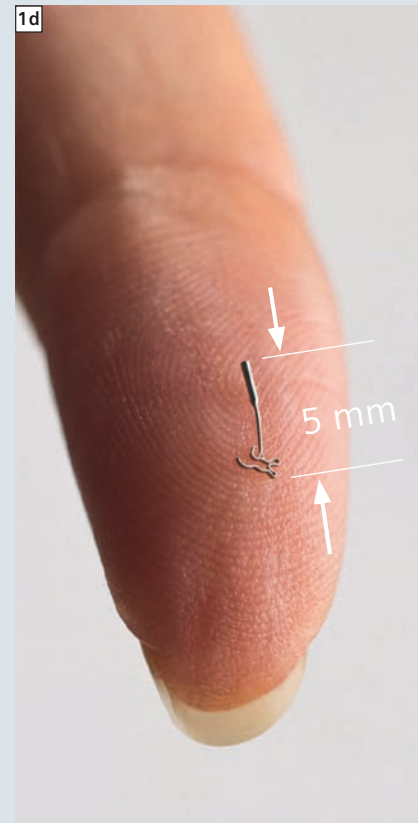
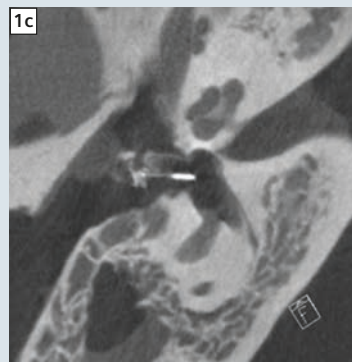
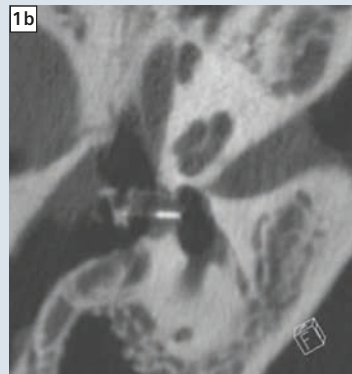
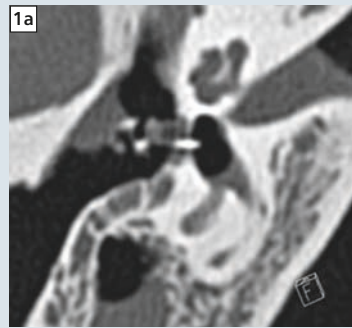
*syngo* DynaCT Micro

Boosting the level of detail



“Our preliminary experience shows that the higher spatial resolution is visible on the images. The bony structures are more sharply delineated and more impressive. Neuroradiology depends on the visualization of small structures, this is exactly what *syngo DynaCT Micro* provides.”

PD Tobias Struffert, M.D.  
Department of Neuroradiology, University of Erlangen, Erlangen, Germany



**1** Comparative view of temporal bone preparation.  
[a] MSCT  
[b] *syngo DynaCT*  
[c] *syngo DynaCT Micro*  
[d] Prosthesis

Today, *syngo DynaCT* is an established imaging technology that has opened up a high number of applications. Depending on the protocol used, low contrast imaging can be performed with excellent spatial resolution. Up to now, 2x2 binning (i.e. read-out of a 2x2 square with 4 detector pixels as one) is used for regular *syngo DynaCT* in interventional neuroradiology. *syngo DynaCT Micro* enables the acquisition of 3D data sets using a 1x1 binning with a field of view of 22 cm (Zoom 3). Using this technology, all detector pixels are read out separately, and thus provide an improved spatial resolution

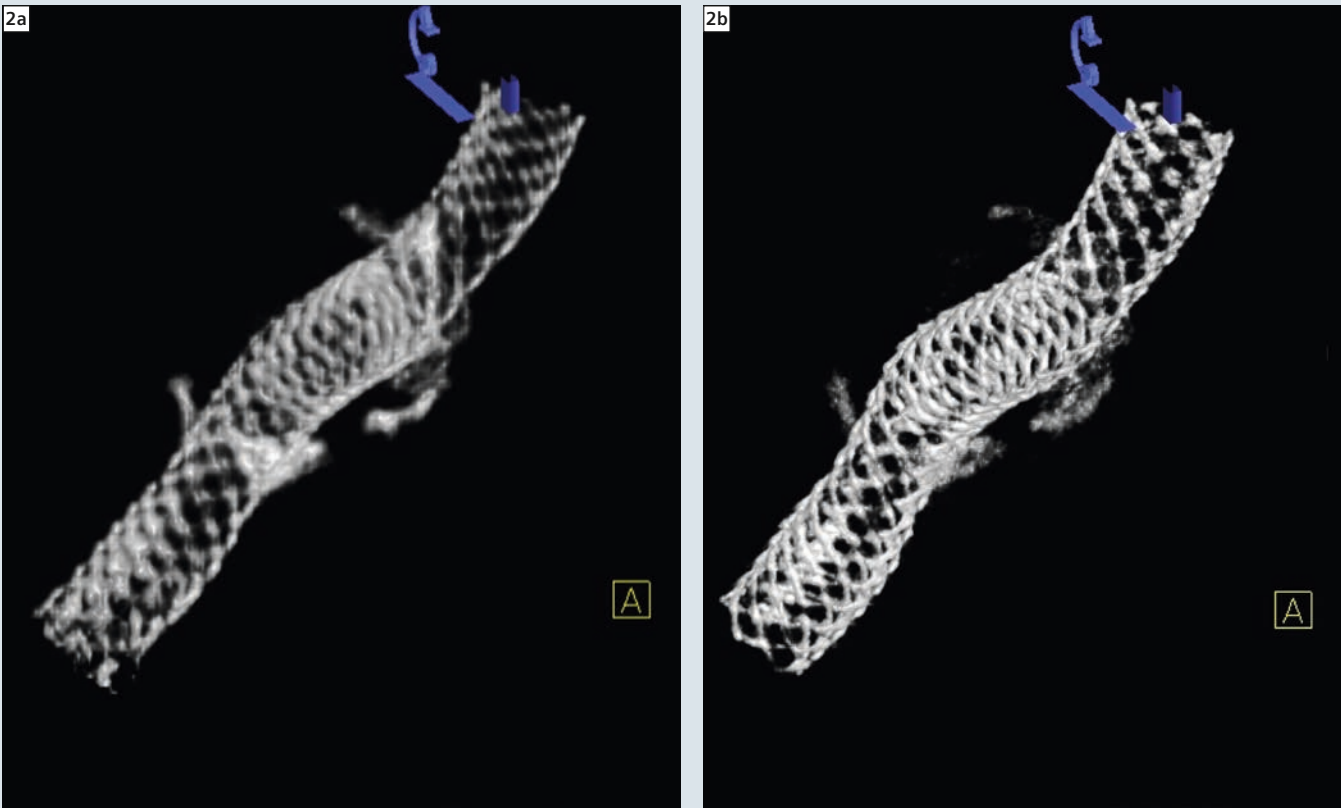
that enables greater detail precision especially in high contrast objects. To demonstrate the improved spatial resolution a temporal bone specimen was analyzed with different imaging techniques for a comparative visualization study. A 5 mm long stapes prosthesis was implanted in the specimen by regular procedure and examined using the following programs:

1. Siemens AS Plus: MultiSliceCT (128 rows, typical temporal bone program)
2. Artis: DynaCT Head (20 s DR)

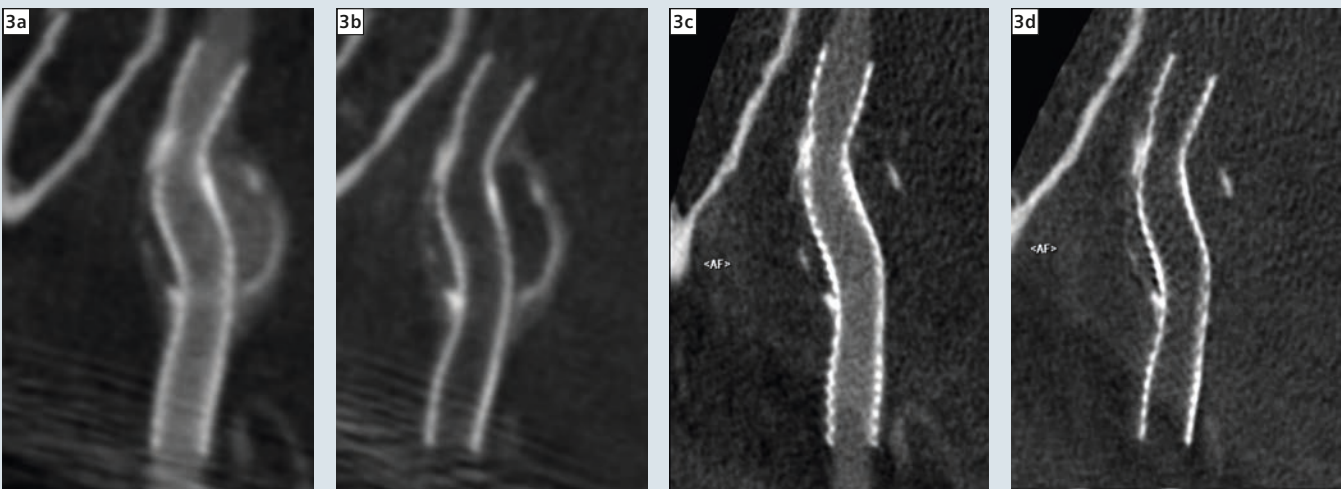
3. Artis: DynaCT Micro (20 s DR in Zoom 3)

The two *syngo DynaCT* datasets were reconstructed with the HU kernel and sharp image impression. For CT reconstruction, the kernel B70 S was selected. Corresponding axial slices with a thickness of 0.5 mm have been reconstructed.

The comparative view (fig. 1a - d) reveals, that the image quality of regular *syngo DynaCT* (fig. 1b) is already considerably better than MSCT (fig. 1a). Using *syngo DynaCT Micro* (fig. 1c), the image quality improves even more.



2 Comparative VRT display of a flow diverter with calcification of the aneurysm wall. [a] syngo DynaCT; [b] syngo DynaCT Micro.



3 MPR reconstructions of a flow diverter: Baseline examination [a] with and [b] without contrast agent using syngo DynaCT; follow-up exam (c) with and (d) without contrast agent after three months using syngo DynaCT Micro.



The trabecular structure of the mastoid cells is considerably sharper. Even the structure of the implant is significantly better than in the regular *syngo* DynaCT (fig. 1 b).

Also for high-resolution imaging of intracranial stents and flow diverters, *syngo* DynaCT has become a well-accepted method. After intravenous administration of contrast agent, minimally invasive monitoring can be used to evaluate the implantation of the device like to confirm that the implant has completely unfolded and adapted to the vessel wall.

A flow diverter was implanted in a fusiform vertebral aneurysm of a patient (fig. 2 a, b). Immediately after implantation, intravenous *syngo* DynaCT imaging was taken as a baseline exam (10sDSA). In the follow-up three months later, the 10s DSA program was performed as a high-resolution *syngo* DynaCT Micro program. In each case, 60 cc of contrast agent was administered.

Compared to the VRT reconstructions (fig. 2 a, b), the implant already appears

well unfolded in regular *syngo* DynaCT mode (fig. 2 a). In high-resolution *syngo* DynaCT Micro mode (fig. 2 b), however, the mesh structure of the flow diverter is seen with considerably better resolution. Several calcifications of the aneurysm wall are also visible.

In the MPR reconstructions, the high-resolution *syngo* DynaCT Micro mode (fig. 3 a, b) reveals no intimal hyperplasia. The individual struts of the flow diverter are well recognizable. With regular *syngo* DynaCT mode (fig. 3 c, d), the struts of the flow diverter are barely visible in the baseline exam. Here, the aneurysm is still perfused. When the two datasets are compared, the flow diverter is much easier to evaluated using *syngo* DynaCT Micro.

### Summary

As a result of the initial examinations using *syngo* DynaCT Micro high-resolution mode, the images clearly show that a better spatial resolution can be achieved.

The initial exams of the temporal bone

specimen also show considerable improvement in the visualization of the trabecular structure. Furthermore, the image of the stapes prostheses in the temporal bone specimen is much sharper in the high-resolution *syngo* DynaCT Micro view.

High-resolution *syngo* DynaCT Micro can also be used with intravenous contrast injection. The delineation of the implant is superior and the lumen easier to assess. The high-resolution imaging of implants is therefore a good indication for *syngo* DynaCT Micro.

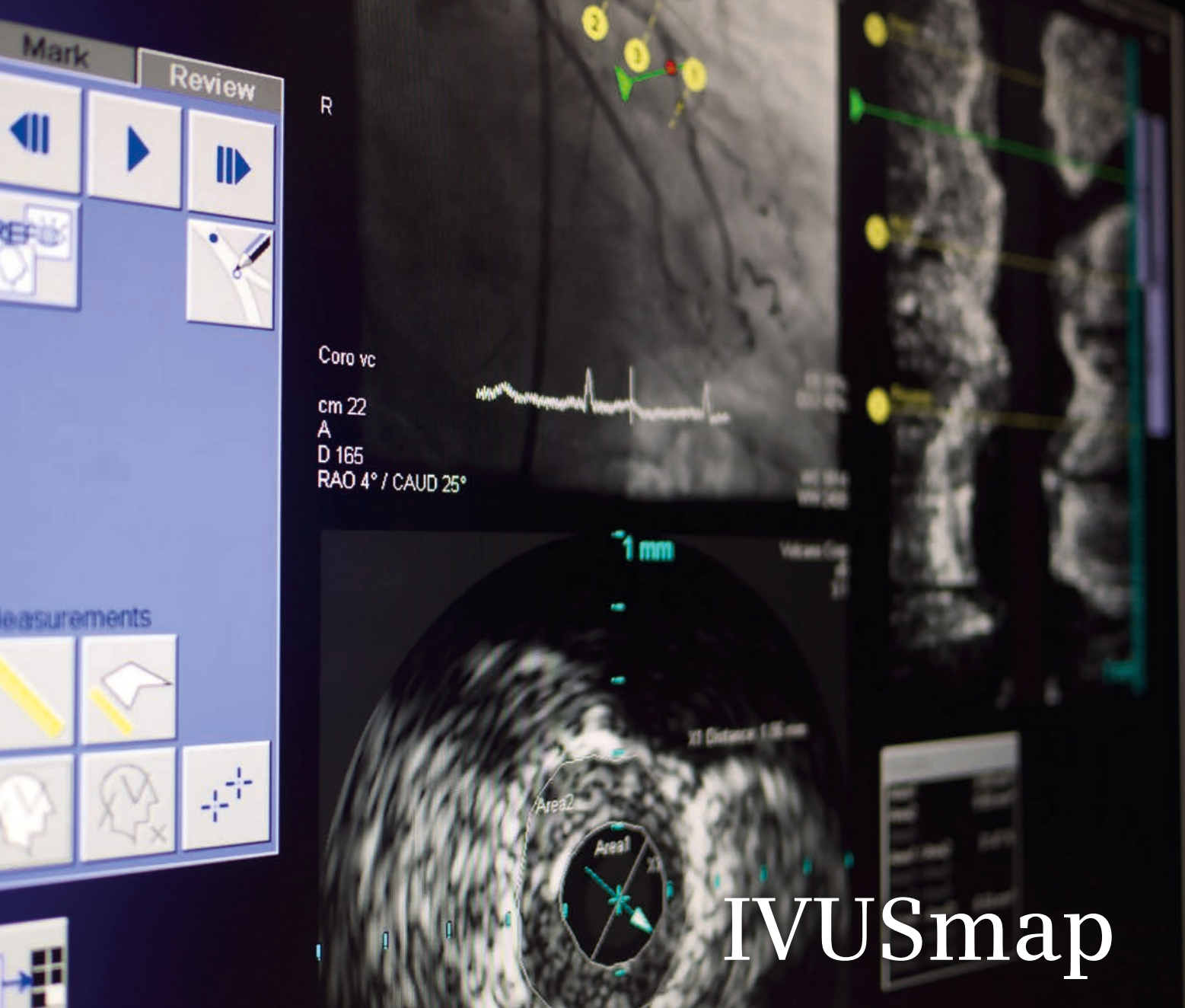
Using high-resolution *syngo* DynaCT Micro will considerably broaden the spectrum of *syngo* DynaCT applications, in particular for imaging implants and bony structures, i.e. fractures.

### Contact

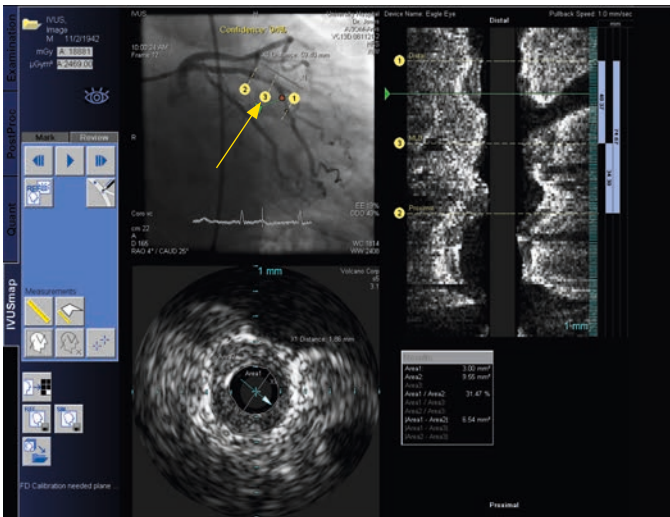
kerstin.raber@siemens.com

## Main Benefits

- Higher resolution by using every single pixel
- Improved spatial resolution
- Better visualize small structures like stents or ossicle prostheses



# IVUS Information Localized within Coronary Tree



The red dot (yellow arrow) in the angiography image corresponds to the position of the currently visualized IVUS cross-section. Bookmarks on co-registered angiography and IVUS images (yellow circles) help to localize critical segments.

“Before IVUSmap, the operator was trapped with one eye on the angiogram and one eye on the IVUS, in his head trying to fuse them into one morphological image.”

Evelyn Regar, M.D., Thorax Center,  
Department of Cardiology, Erasmus Medical  
Center, Rotterdam, Netherlands

Intravascular ultrasound (IVUS) is an invasive imaging modality used during coronary catheterization to complement the information provided by angiography. However, IVUS lacks spatial orientation and the relationship between angiographic and IVUS images is left to the experience of the physician. Early stage diseases or long diffused lesions make it even more challenging to mentally establish a cor-

respondence as no evident anatomical landmarks can be used.

IVUSmap, an optional application integrated in the new Artis Q and Artis Q.zen systems, maps each frame of an IVUS pullback to its corresponding position within the coronary tree of a reference angiographic image. After co-registration, the angiographic road-map image is linked side-by-side with the corresponding IVUS images. This

allows to navigate in either modality while keeping track of the corresponding location. As a consequence, the localization of lumen and wall structure is readily available to support the diagnosis.

IVUSmap allows the setting of bookmarks at decisive IVUS frames, such as stent landing zones. The corresponding positions are highlighted in angiography and can be used to guide the therapy, e.g. during stent deployment or to control its final position. Co-registration between angiography and IVUS may also be a pivotal tool in assessing implanted bioresorbable scaffolds as they are barely visible in angiography. IVUSmap is the result of continued development efforts between Siemens and Volcano Corporation to bring co-registration to interventional cardiology. IVUSmap can be fully executed from the tableside control. The tight integration with Volcano's s5i IVUS console ensures a seamless workflow including shared patient registration and automatic image data transfer.

## Main Benefits

- Additional vessel wall information supports planning of therapy
- Bookmarks can guide stent deployment
- Efficient integration and automated workflow

### Contact

andrea.beulcke@siemens.com



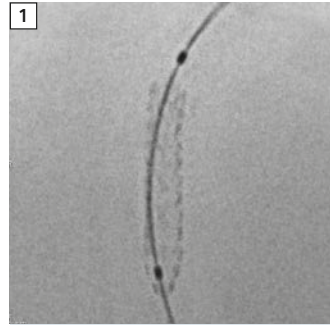


# CLEARstent Live

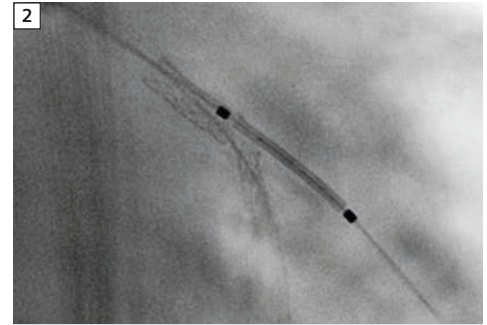
Stent Enhancement in Real Time



Real-time stent enhancement allows precise positioning of stents in relation to previously deployed stents or cardiac anatomy. This facilitates complex procedures like bifurcational stenting.



**1** CLEARstent used for stent deployment assessment showing insufficient expansion of distal stent end requiring post-dilatation.



**2** CLEARstent Live real-time stent enhancement used for precise stent positioning in LAD bifurcation prior to deployment of third stent.

*Images courtesy of Kristoff Cornelis, M.D., AZ, Maria Middelaers Ghent, Belgium.*

During complex coronary interventions (PCI), physicians often need to place stents next to each other without overlap and at the same time with as little gap in between as possible. Stent gaps have been associated with in-stent restenosis, an excessive growth of tissue inside the stent that reobstructs the coronary vessel.

On the other hand, overlapping stents may result in stent fracture, which has also been associated with in-stent restenosis and successive stent thrombosis, recurrent angina or myocardial infarction.

To assess the correct deployment of stents, either stent enhancement like CLEARstent or intra-vascular ultrasound (IVUS) can be used. IVUS allows for a cross-sectional image of the coronary vessel, which allows the expansion of the stent to be seen in relation to the vessel wall.

CLEARstent allows the evaluation of a stent before the implantation, yet it has been designed to deliver highest image quality for assessment of an implanted stent. To achieve this, it takes a couple of seconds to calculate and will not allow manipulation of the catheter

while the image is being enhanced. CLEARstent Live can help as fast as it takes to step on the pedal. It is activated during a low dose acquisition protocol, CLEARstent Live makes the image enhancement happen in real time. This allows for catheter manipulation while getting a clear visualization of previously deployed stents or cardiac anatomy in relation to the currently positioned stent.

### Technical aspects

CLEARstent Live is based on the same principle as CLEARstent, identifying the golden balloon markers and enhancing the stent by rotating and manipulating the images to position the markers on top of each other. Differently to CLEARstent though, this processing is ongoing and displays the live result in real time. The enhanced image is displayed on the Artis Assist monitor while the regular acquisition is shown on the Artis Live monitor. CLEARstent Live can enhance any frame rate up to 15 f/s and similar to CLEARstent, CLEARstent Live runs on the Artis system and does not require an additional workstation. It offers full PACS compatibility by saving the resulting scenes as DICOM files, which can be exported and reviewed with any DICOM viewer.

## Main Benefits

- Simultaneous display of live and stabilized images with up to 15 f/s
- Facilitation of complex procedures
- PACS compatibility for review of scenes using any DICOM viewer

### Contact

hanno.herrmann@siemens.com

# *syngo* DynaPBV Body: Blood Volume Imaging Opens New Prospects for Tumor Treatment

*syngo* DynaPBV Body visualizes the distribution and amount of blood in abdominal, thoracic and peripheral tissue. The impact of providing such 3D functional information directly in the interventional suite seems immense. A better understanding of tissue perfusion has the potential to help interventional radiologists reach the most promising individualized treatment decision, monitor interventional procedures and define the optimal end point of therapy, and give a prognosis on treatment response directly after therapy.

When nuclear medicine, MR and CT made perfusion imaging available, it was a major step towards a better understanding of lesions resulting in a more optimized individual treatment plan. However intra-procedurally, such physiologic information directly in the interventional suite was still missing. With the launch of *syngo* NeuroPBV IR in 2009, blood volume imaging allowed for treatment monitoring during the course of neurointerventions by e.g., visualizing the reperfusion of an infarcted area. This information is vital to the neuroradiologist since it makes treatment success evident and supports the determination of the treatment end point without the need to transfer the patient from the interventional suite to CT, MR or nuclear medicine.

What has been available exclusively to neuroradiology over the last three years is now also available for imaging the body's physiology. The visualization of the amount of blood in lesions and surrounding tissue during interventions in thoracic, abdominal and peripheral regions will support interventional radiologists in adapting their treatment to

the unique condition of the patient. The blood volume information is derived from two 3D image data sets – a native run followed by a fill run – which are acquired within one *syngo* DynaPBV Body acquisition. However, in the body region patient movements can have an impact on image quality. New *syngo* DynaPBV Body functionality faces this challenge and compensates for motion caused by patient agitation, breathing, intestinal peristaltic movements, or pulsation of big vessels during 3D acquisition. The underlying technique is a non-rigid 3D/3D registration. It aligns image content from the mask and fill run and suppresses motion artifacts. *syngo* DynaPBV Body will contribute enormously to the endeavor of personalizing treatment in the interventional suite. Getting information about the perfusion of lesions at any time during the intervention will help medical professionals to understand the patient's condition better and, as a consequence, to adapt therapy decisions to physiological parameters revealed by the assessment of blood volume. In tumor treatment, interventional radiologists

may use this physiological information to make their decisions about the type, size and amount of particles used in embolization procedures with more confidence. *syngo* DynaPBV Body helps determine the end point of embolization, which is difficult with certain new embolization materials. The functional information may aid the clinician in his decision on whether and how to repeat the treatment. And there is even potential for deriving information on treatment response from the blood volume information given.

Clinicians may also take advantage of *syngo* DynaPBV Body in therapies beyond tumor treatment e.g., when assessing the success of percutaneous transluminal angioplasty (PTA) for occluded vessels in the periphery by evaluating the re-perfusion of tissue distal to the occlusion e.g., in diabetic feet. The *syngo* DynaPBV Body application has been examined in the interventional radiology department of five different centers in Asia, USA and Europe.



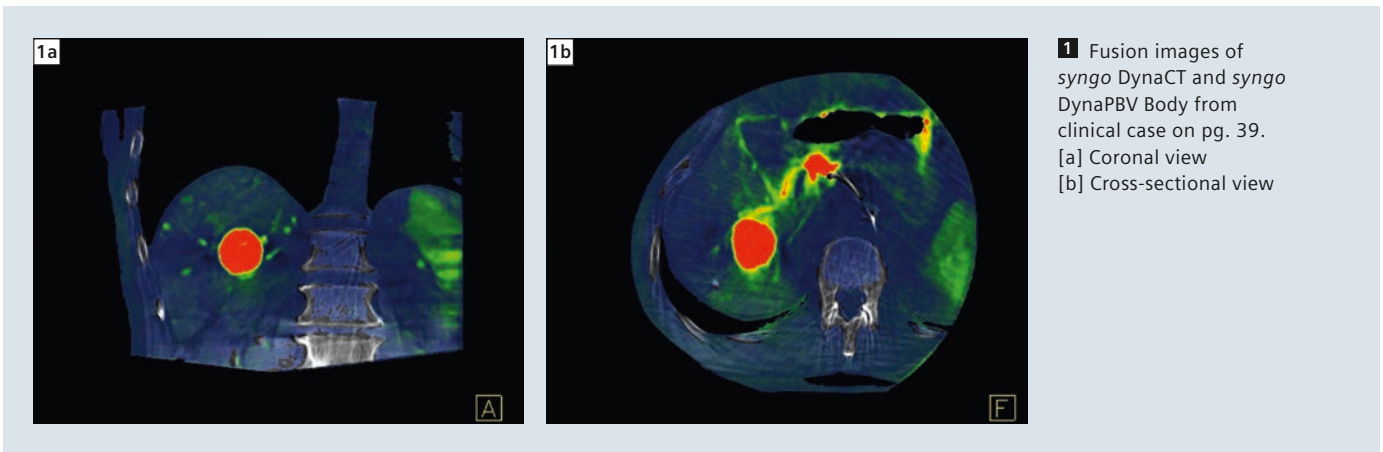
**Prof. Xu Jianrong, M.D.,** Department of Radiology, Renji Hospital Shanghai, China, used *syngo* DynaPBV Body in transarterial chemoembolization (TACE) of primary liver tumors. In his study, he assessed the reliability of the new software application by comparing the blood volume derived from pre-procedural *syngo* DynaPBV Body with the arterial portion of the blood volume derived from pre-procedural CT perfusion. The results show a good correlation between the

blood volume values obtained from CT and *syngo* DynaCT. (see clinical case on pg. 39 f.)

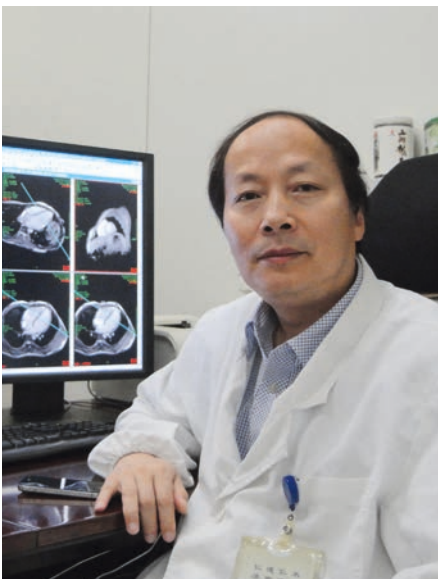
As a further learning from the study, Prof. Xu and his team observed an increase in the detection rate for hepatocellular carcinoma (HCC) tumors smaller than 1 cm in diameter when evaluating pre-interventional *syngo* DynaPBV Body datasets.

“In the next step,” Prof. Xu said, “we want to do the liver *syngo* DynaCT perfusion before and right after TACE

to assess the effect of the procedure to determine an optimal end point for embolization.” According to Prof. Xu, *syngo* DynaPBV Body also has potential in the treatment of organs other than liver. One example is spleen embolization, where a partial embolization is required, but no peri-procedural quantitative assessment of the splenic perfusion is available right now. He sees *syngo* DynaPBV Body as a valuable tool to gather the physiologic information he lacks.



**1** Fusion images of *syngo* DynaCT and *syngo* DynaPBV Body from clinical case on pg. 39. [a] Coronal view [b] Cross-sectional view



“Currently, we use *syngo* DynaPBV Body in the liver for the TACE procedure. Besides the application in the liver, I think the *syngo* DynaPBV Body is potentially useful in spleen embolization, where partial embolization is required. But now there is no peri-procedural quantitative assessment for it. So I think *syngo* DynaPBV Body may serve as a good tool.”

Prof. Xu Jianrong, M.D.,  
Department of Radiology, Renji Hospital, Shanghai, China





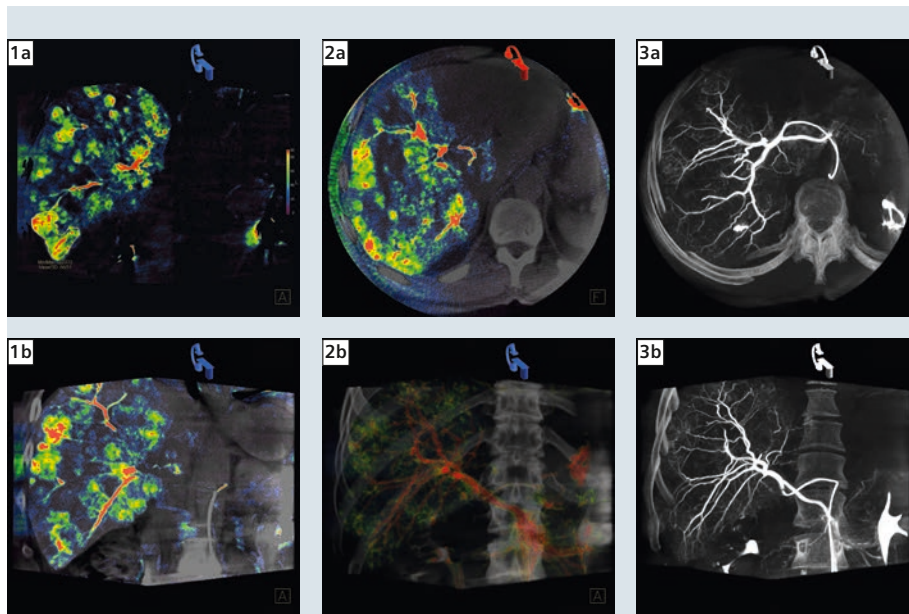
In his institution, **Prof. Thomas J. Vogl, M.D.**, Director of the Department of Diagnostic and Interventional Radiology, University Clinics Frankfurt a.M., Germany, already uses *syngo* DynaPBV Body in his daily work mainly in primary liver cancer and liver metastases. However, he has also gained experience in primary and secondary lung cancer, head and neck neoplasms, and pelvic indications such as pelvic perfusion of recurrent cervical cancer.

“With *syngo* DynaPBV Body we get information on the vascular supply, on the vascular bed of tumors, on the perfusion and also on the amount of blood volume. And changes in blood volume can help us to optimize our therapy.” Prof. Vogl points out that in one shot, the *syngo* DynaPBV Body acquisition provides a blood volume map with a coverage of 25 x 20 cm in conjunction with a high-resolution contrast-filled *syngo* DynaCT. “It allows us to both delineate the vessels and simultaneously analyze the amount of perfusion in the area of interest.”

For him, the most interesting applications for *syngo* DynaPBV Body are the definition of the end point of a therapy,

and decision support on whether therapy is best repeated or terminated. When asked for his view on the future of functional imaging in the interventional lab, he said: “Functional imaging based on angiographic procedures has always been of great interest – both for MS CT applications and *syngo* DynaCT. I think it’s one further step toward molecular

imaging in our interventional oncology procedures, which means that not only are we treating tumors, but we are also trying to get information on response, non-response, therapy control. That, I think, is the major impact of this technology.”



“We are not only treating tumors, but we are also trying to get information on response, non-response, therapy control. That, I think, is the major impact of this technology.”

Prof. Thomas J. Vogl, M.D.,  
Director of the Department of Diagnostic and Interventional Radiology,  
University Clinics Frankfurt a.M., Germany



“*syngo* DynaPBV may help in monitoring the perfusion avoiding an over-embolization and occlusion of tumor feeding arteries.”

Prof. Philippe L. Pereira, M.D.,  
 Director of the Department of Radiology,  
 Minimally Invasive Therapies and Nuclear Medicine,  
 SLK Clinics Heilbronn, Germany

**1** [a+b] Multifocal hepatic metastases in coronal view.  
 [a] PBV color map indicating blood volume in tumor nodules.  
 [b] PBV color map fused with native *syngo* DynaCT.

**2** [a+b] PBV color map fused with native DynaCT.  
 [a] axial view  
 [b] VRT view

**3** [a+b] High-resolution contrast-filled *syngo* DynaCT taken from *syngo* DynaPBV Body acquisition.  
 [a] axial view  
 [b] coronal view

Images courtesy of Prof. Thomas Vogl, M.D.



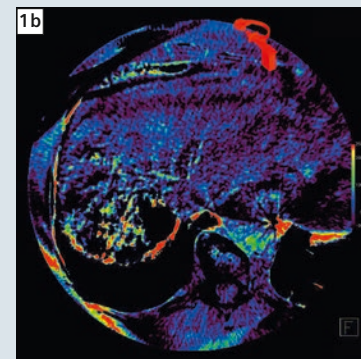
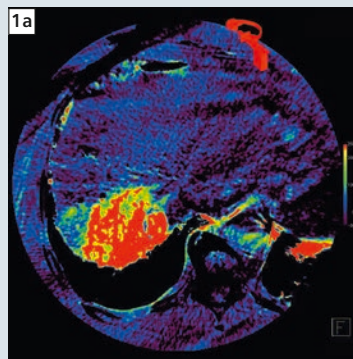
**Prof. Philippe L. Pereira, M.D.,**  
 Director of the Department of Radiology, Minimally Invasive Therapies and Nuclear Medicine, SLK Clinics Heilbronn, Germany, investigated the accuracy of *syngo* DynaPBV Body in secondary liver cancer by comparing *syngo* DynaPBV blood volume with CT perfusion blood volume. The study demonstrated a good correlation. In clinical routine, he wants to use the functionality to assess the effectiveness and safety of TACE procedures in secondary liver tumors, such as hypovascular metastases from melanoma. “We have new modalities to treat liver tumors now,” he said and explained the use of small drug-loaded particles

40-70 μm in size. “These small particles are very aggressive for the tumor of course – this is what we want – but also for the vessels. And we have to be very cautious in using these small particles. *syngo* DynaPBV Body may help in monitoring the perfusion with these very small particles and avoid an over-embolization and occlusion of tumor feeding arteries. So we have the possibility to re-assess the tumor through the same vessels after the first session.” Prof. Pereira sees further clinical use of *syngo* DynaPBV Body to assess tissue perfusion during and after fibrinolysis of the muscle, in evaluation of the perfusion of kidneys, or in radiofrequency ablation of the renal arteries.



**1** [a+b] Blood volume map of an infiltrative HCC before and after cTACE showing the devascularization of the tumor.

Images courtesy of Prof. Philippe L. Pereira, M.D., also see page 41.



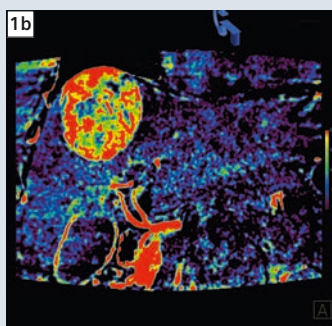
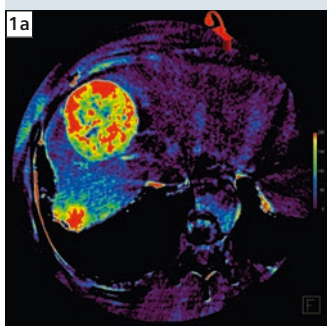


**Prof. Bora Peynircioğlu, M.D.,**  
Department of Radiology,

Hacettepe University Ankara, Turkey, evaluated changes in blood volume as an effect of transarterial chemoembolization (TACE), radioembolization (RE) or preparation angiography for RE by assessing blood volume of primary and metastatic hepatic malignancies pre- and post-embolization. The qualitative measurements with *syngo DynaPBV Body* showed a significant decrease in mean blood volume of more than 65% after TACE and more than 50% after RE. The measurement also showed a severe

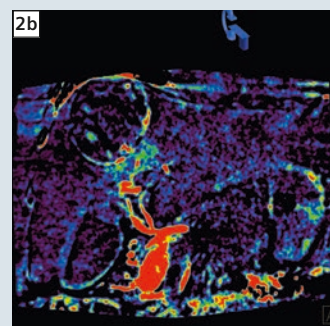
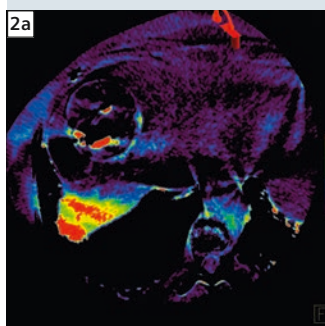
increase in tumoral blood volume after side branch embolizations for RE preparation (see clinical case on p. 18). In addition, Prof. Peynircioğlu verified the results of *syngo DynaPBV Body* against dynamic multi-detector CT (M.D.CT) perfusion for pre-embolization blood volume measurements. CT perfusion measurements were based on intravenous injection, and qualitative C-arm blood volume measurements were based on intraarterial injection into the celiac axis. Prof. Peynircioğlu could prove that the mean blood volume measurements highly correlated between

*syngo DynaPBV Body* and CT perfusion. Next, Prof. Peynircioğlu wants to assess a possible correlation between a decrease in perfusion as a result of therapy and tumor response for the different embolization procedures. He postulates that “blood volume measurements with *syngo DynaPBV Body* may be a potential technique to predict the tumor response at a very early phase immediately at the end of the embolization procedure.”

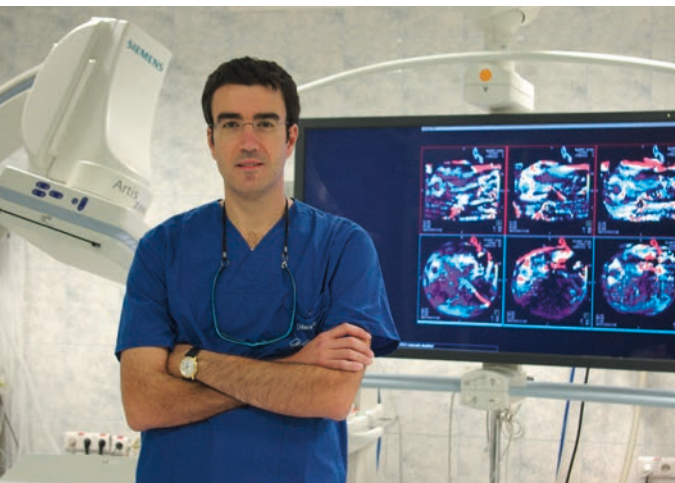

**1** [a+b] *syngo DynaPBV Body* images obtained before TACE. [a] axial, [b] sagittal view.

Images courtesy of Prof. Bora Peynircioğlu, M.D.



**2** [a+b] *syngo DynaPBV Body* images obtained right after TACE show a significant decrease in tumor perfusion. [a] axial, [b] sagittal view.



“Blood volume measurements with *syngo DynaPBV Body* may be a potential technique to predict the tumor response immediately at the end of the embolization.”

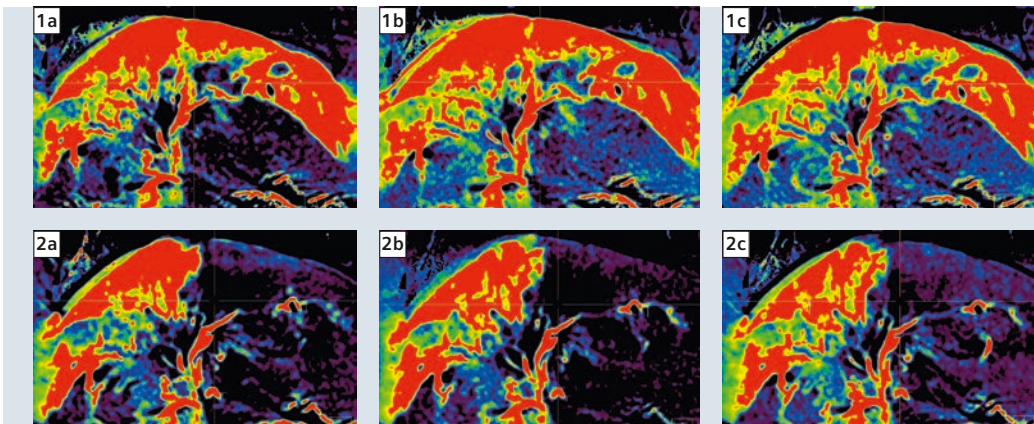
Prof. Bora Peynircioğlu, M.D.,  
Department of Radiology, Hacettepe University Ankara, Turkey





“Quantitative images of blood volume and perfusion could provide imaging biomarkers that will allow patient-specific choice of therapy, as well as monitoring of progress during the intervention.”

Prof. Rebecca Fahrig, PhD, Department of Radiology,  
Stanford University School of Medicine, Stanford, USA



Verification of reproducibility of syngo DynaPBV Body measurements:

**1** [a-c] blood volume color maps of three successive pre-embolization scans

**2** [a-c] blood volume color maps of three successive post-embolization scans



The team of Nishita Kothary, M.D. and Rebecca Fahrig, PhD, Department of Radiology, Stanford University School of Medicine, USA, performed a pre-clinical study in six swine with the target of verifying the reproducibility and accuracy of flat panel CT blood volume measurements. For validation of reproducibility of syngo DynaPBV qualitative measurements, each animal was scanned three times in a sequence before and after partial embolization of the left liver lobe. The study proved a high reproducibility by statistic analysis. For all animals, the three successive scans pre- as well as post-embolization generated the same images and qualitative measurements.

For verification of accuracy, syngo DynaPBV blood volume measurements were compared to blood volume measurements from 64-slice helical CT perfusion. The determination of both, flat panel CT and CT blood volume, were based on intra-arterial injection of undiluted iodinated contrast into the hepatic artery. The study showed that

flat panel CT and helical CT measured essentially the same in each pig with a correlation of 0.94.

Comparison of pre- and post-embolization blood volume values showed remarkable differences, demonstrating the capability of syngo DynaPBV Body to measure perfusion changes immediately after embolization. Dr. Kothary shared her view on today's and the future clinical use of blood volume and perfusion imaging in a presentation at WCIO 2012: "In the future, quantitative measurement of blood volume, using software applications such as syngo DynaPBV Body may aid in detection and differentiation of tumors impacting treatment."

The main benefit of having blood volume information on hand, however, is seen in therapeutic monitoring, in the determination of the end point of treatment, and in the prognosis of therapy outcome. "Choosing and targeting therapies is going to be a huge deal," said Dr. Kothary. With new therapeutic particles such as drug-eluting beads

(DEB) it is very difficult to decide how many particles need to be delivered. The visual feedback obtained from lipiodol is missing. However, blood volume information can support the interventionalist in his decision on when to define the end point and it can also deliver prognostic indicators. As an example, Dr. Kothary mentioned that prognostically, infiltrative tumors don't do well, but interventionalists don't have quantitative measures for it. The expectation is, however, that infiltrated tumors have very different hemodynamics and perfusion parameters than encapsulated tumors. "If we truly could quantify blood flow and blood volume, we could differentiate tumors, we could measure changes during the treatment and determine the prognosis of what we treated and that will determine what treatment we use."



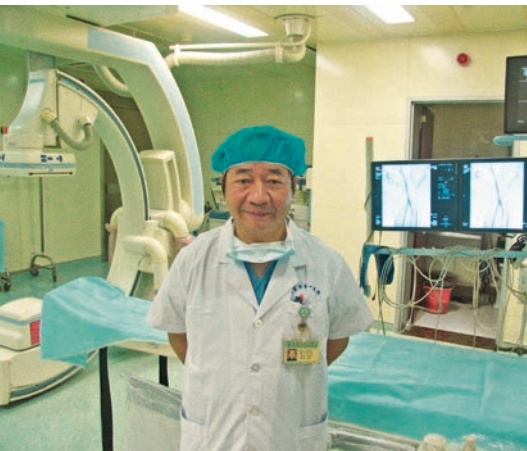#### Contact

simone.henrichs@siemens.com

# Real-Time Assessment of Revascularization of Peripheral Vascular Disease Supported by *syngo* iFlow

Courtesy of Jianping Gu, M.D., and Wensheng Lou, M.D.

Department of Interventional Radiology, Nanjing, No.1 Hospital, Shanghai, China



“If we can standardize the DSA acquisition and evaluation method, *syngo* iFlow is a powerful imaging tool for peripheral intervention procedures, not only for the assessment of the outcome, but also for intra-procedural decision making.”

Jianping Gu, M.D., Department of Interventional Radiology, Nanjing, No.1 Hospital, China

## Patient history

A 75-year-old male patient with a 8-year history of hypertension suffered from lower extremity arterial occlusive disease. He was treated with the implantation of a stent three years ago. After two years, the symptoms of intermittent claudication emerged and gradually progressed. Half a month ago, the patient revisited the hospital, presenting with severe pain and numbness in his right lower limb, causing his maximum walking distance to fall below 20-30 meters.

## Diagnosis

The middle and upper segments of the right superficial femoral artery were occluded, while the lower segment still showed sufficient perfusion due to collateral flow. The popliteal, peroneal, anterior tibial, and posterior tibial arteries were not obstructed but presented with localized plaque formations. A severe stenosis existed at the bifurcation of the posterior tibial artery.

## Treatment

A balloon dilatation (5F, 4x120 mm, Admiral, Invatec, Italy) and a following thrombolysis therapy were performed at the upper segment of the right superficial femoral artery. The DSA examination performed after nine days showed a minor improvement of circulation, but the occlusion still existed. In the next few days, two stents (6x150 mm, Protege, EV3) were implanted into the right superficial femoral artery to reopen the vessel. However, the post-DSA showed a new occlusion at the bifurcation of the popliteal artery, presumably due to an embolus from the superficial femoral artery. A careful analysis of pre- and post-*syngo* iFlow measurements, which can be seen in figures 1-5, indicated that the perfusion and circulation around the distal arteries were sufficient. After a risk-benefit analysis, the physician decided that no further treatment would be needed. After the procedure, the patient was asymptomatic.

## Comments

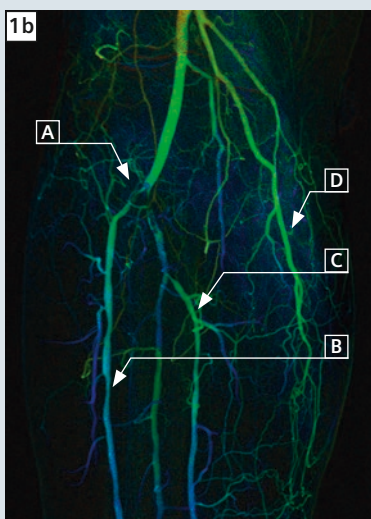
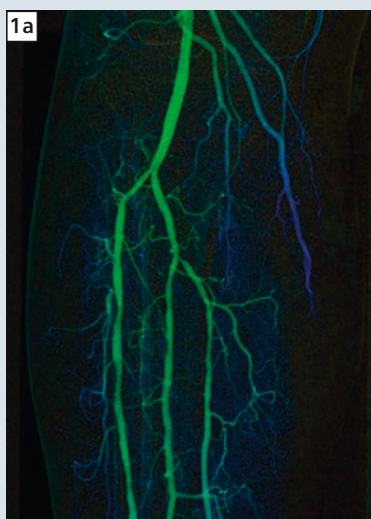
In most cases *syngo* iFlow was used as an offline tool to post-process the DSA images and to help the physician for diagnosis or assessment. This case demonstrated the capabilities of *syngo* iFlow to evaluate the perfusion and circulation in and around distal arteries during the interventional procedure. The functional information was very valuable for choosing the right treatment strategy for the next step.

*syngo* iFlow images were able to achieve precise measurements concerning time-to-peak of contrast medium flow in distal arteries.

The case demonstrates that *syngo* iFlow provides essential hemodynamic and perfusion information to support the decision making for the management of intra-procedural complications during a peripheral vascular intervention.

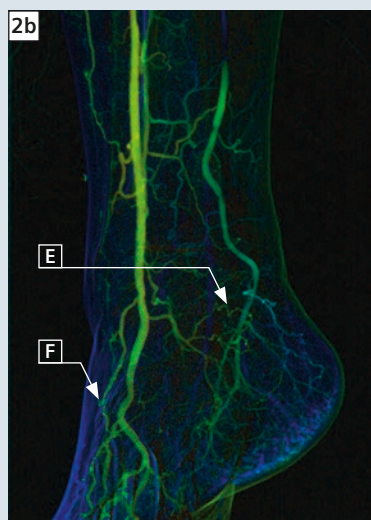
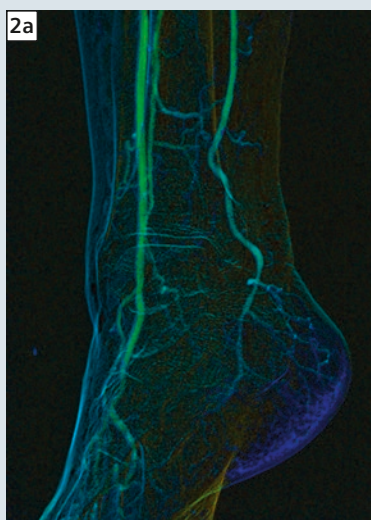
## Contact

janina.beilner@siemens.com



**1** [a] *syngo iFlow* image before treatment of the stenosed superficial femoral artery. [b] During stenting of the superficial femoral artery an occlusion of the popliteal bifurcation was caused by an embolus (A). *syngo iFlow* shows the hemodynamic changes in the distal vessels. Time-to-peak (TTP) analysis based on the *syngo iFlow* images showed an increased flow in a collateral branch (D). At the same time blood flow within the anterior (B) and posterior tibial arteries (C) slowed down.

- A: Bifurcation of popliteal artery
- B: Anterior tibial artery TTP ↑ 2.5 s
- C: Posterior tibial artery TTP ↑ 1.5 s
- D: Collateral branch artery TTP ↓ 2.5 s



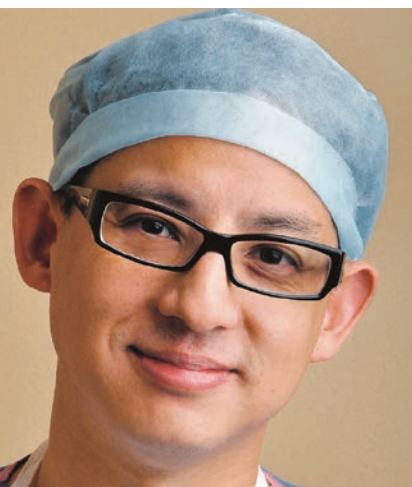**2** *syngo iFlow* measurement shows improved distal blood flow after intervention despite the embolus. [a] *syngo iFlow* image before treatment [b] *syngo iFlow* image after treatment

TTP shows that (E) the blood flow in the malleolar artery was almost the same as before (TTP ↑ 0.5 s) and that (F) the blood flow in the dorsalis pedis artery was improved (TTP ↓ 3.5 s).



# Lower Limb Revascularization Supported by syngo iFlow

Courtesy of Peter Ashley Robless, M.D., MBChB, FRCS, FEBVS,  
Department of Cardiac, Thoracic and Vascular Surgery, National University Hospital, Singapore



“Using syngo iFlow helps us to quantify the pre- and post-intervention perfusion for angiosome-specific revascularization.”

Peter Ashley Robless, M.D., MBChB, FRCS, FEBVS,  
Department of Cardiac, Thoracic and Vascular Surgery,  
National University Hospital, Singapore

## Case 1 (Figures 1 – 3)

### Patient history

57-year-old male with disabling and worsening claudication.

### Diagnosis

Bilateral Iliac stenosis and right superficial femoral artery occlusion;  
Ankle Brachial Pressure Index (ABPI)  
R: 0.4  
L: 0.5.

### Treatment

Left external iliac angioplasty and stenting (EV3 Protégé 8x40 mm)  
Right external iliac angioplasty  
Subintimal angioplasty of the right SFA  
Proglide closure left CFA.

## Case 2 (Figures 4 and 5)

### Patient history

73-year-old male with 2-week history of pain. He had previous femoropopliteal bypass occlusion, and currently suffers from atrial fibrillation and TIA. The patient is an ex-smoker.

### Diagnosis

Left common iliac artery occlusion, severe right common iliac artery stenosis and femoral-popliteal artery occlusion.

### Treatment

Kissing iliac stenting with Medtronic Complete SE stents (R: 8x40 mm L: 7x60 mm) and 1 Boston Scientific Epic stent

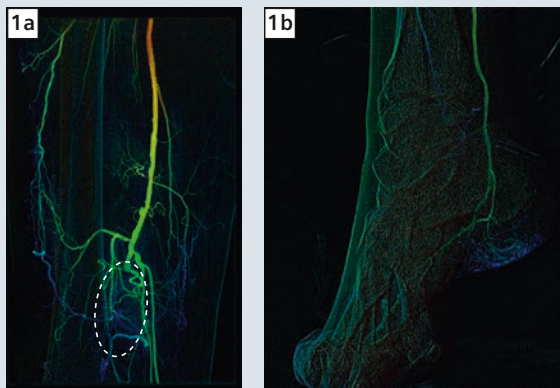
(7x60 mm) on the left EIA  
Hybrid Iliofemoral popliteal bypass performed. Right common femoral endarterectomy with BioNova Patch and a non-in-situ reversed non-reversed femoral popliteal bypass with saphenous vein was performed.

### Comments

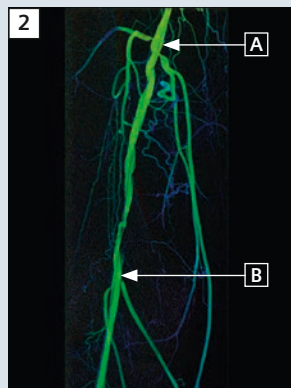
syngo iFlow provides a real-time color-coded visualization of DSA images allowing quantitative analysis of contrast flow through an area of interest. It may help in the quantification of the pre- and post-intervention perfusion for angiosome-specific revascularization.

**Contact**  
yuanjiang@siemens.com

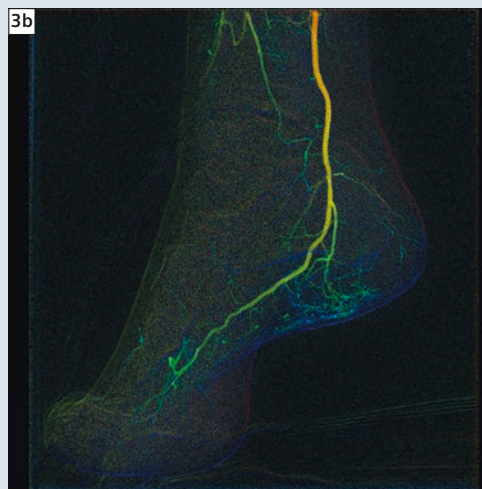
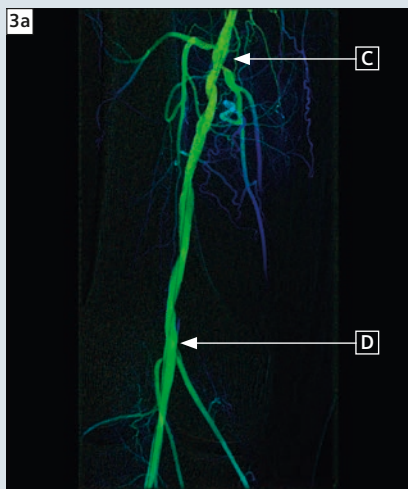
### Case 1



**1** [a+b] syngo iFlow images of superficial femoral arteries [a] and posterior tibial arteries of the right foot [b] before angioplasty. The dashed circle indicates the occlusion.

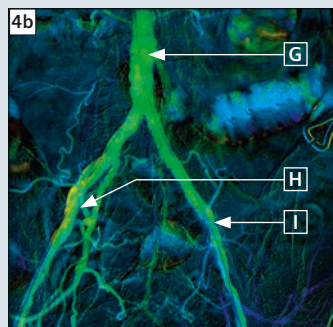
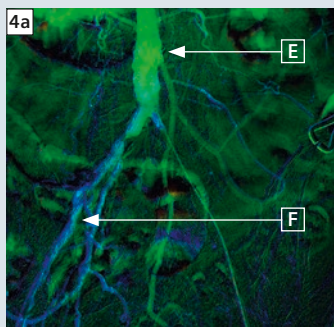


**2** syngo iFlow image of femoral arteries after the first angioplasty. (TTP: A 3.20 s | B 4.53 s)

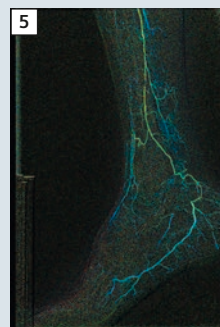


**3** [a+b] syngo iFlow images of femoral arteries [a] and arteries of the right foot [b] after the second angioplasty. (C 3.00 s | D 3.73 s)

### Case 2



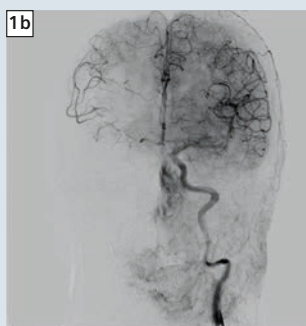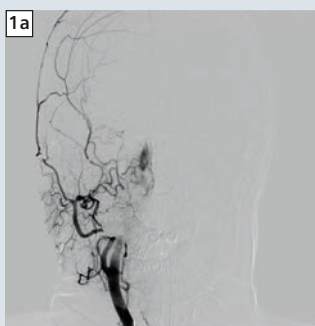**4** [a+b] syngo iFlow images of the aortic bifurcation and iliac arteries before [a] (E 2.95 s | F 4.53 s) and after [b] kissing iliac stenting (G 2.13 s | H 2.93 s | I 2.93 s).



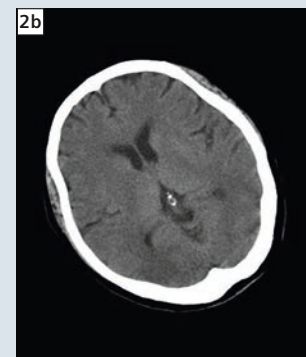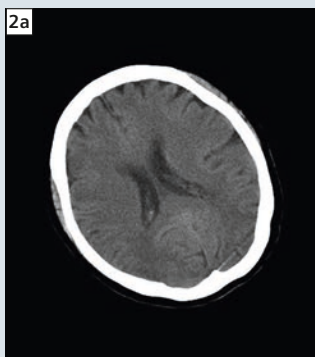
**5** syngo iFlow image of arteries of the right foot after subsequent femoropopliteal bypass.

# Acute Stroke Recanalization Supported by *syngo* DynaPBV Neuro and *syngo* iFlow

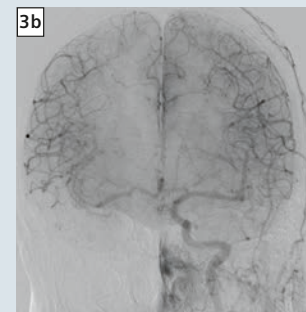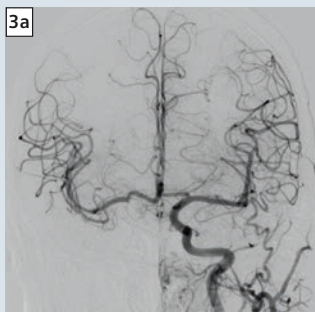Courtesy of Prof. Jianmin Liu, M.D.,  
Department of Neurosurgery, Shanghai Changhai Hospital, Shanghai, China



**1** Pre-treatment:  
[a] a total occlusion in the initial part of the R-ICA;  
[b] a severe stenosis at the M1 segment of the right middle cerebral artery.



**2** Pre-procedural CT: no ischemic lesion or infarction was found.  
[a] Cross-sectional image at the middle lateral ventricles level,  
[b] cross-sectional image at basal ganglia level.



**3** Post-treatment: Despite the occlusion on the R-ICA, M1 segment of the R-MCA was re-opened by stent-assisted mechanical recanalization and the right intracranial vasculature was improved.  
[a] Post-procedural angiography in early arterial phase;  
[b] post-procedural angiography in late arterial phase.

It showed an enormously low perfusion area around the right middle cerebral artery (R-MCA) (fig. 4).

The right common carotid artery (R-CCA) digital subtraction angiography (DSA) demonstrated a total occlusion in the initial part of the R-ICA. The left internal carotid artery (L-ICA) angiography showed there was a severe stenosis at the M1 segment of the right middle cerebral artery (R-MCA). The R-MCA dominated cerebral area was partially compensated by right-ACA and soft-meningeal micro-vessels (fig. 1).

## Treatment

According to the pre-procedural DSA findings, stent-assisted mechanical recanalization was performed with a 4.0 x 20 mm self-expanding retrievable intracranial stent (Solitaire AB, Covidien, USA) within R-ICA and R-MCA. The following DSA examination showed a morphological improvement of the M1 segment of the R-MCA while the R-ICA was not totally recanalized with only an opacification of the distal part of the communicating segment of the R-ICA. Moreover, DSA roughly showed that not only the left-ICA area but also the right-ICA area was supplied by L-ICA through the anterior communicating artery with sufficient blood filling (fig. 3).

A second *syngo* DynaPBV Neuro run was performed with the same acquisition and injection protocol to verify the improvement of parenchymal perfusion. CBV images illustrated that the perfusion of the right brain hemisphere was dramatically improved and the CBV values were similar to those on the left side (fig. 5).

## Patient history

64-year-old female patient suffered from sudden aphemia, drowsiness and left limb paralysis for 40 minutes, with rightward gaze deviation.

## Diagnosis

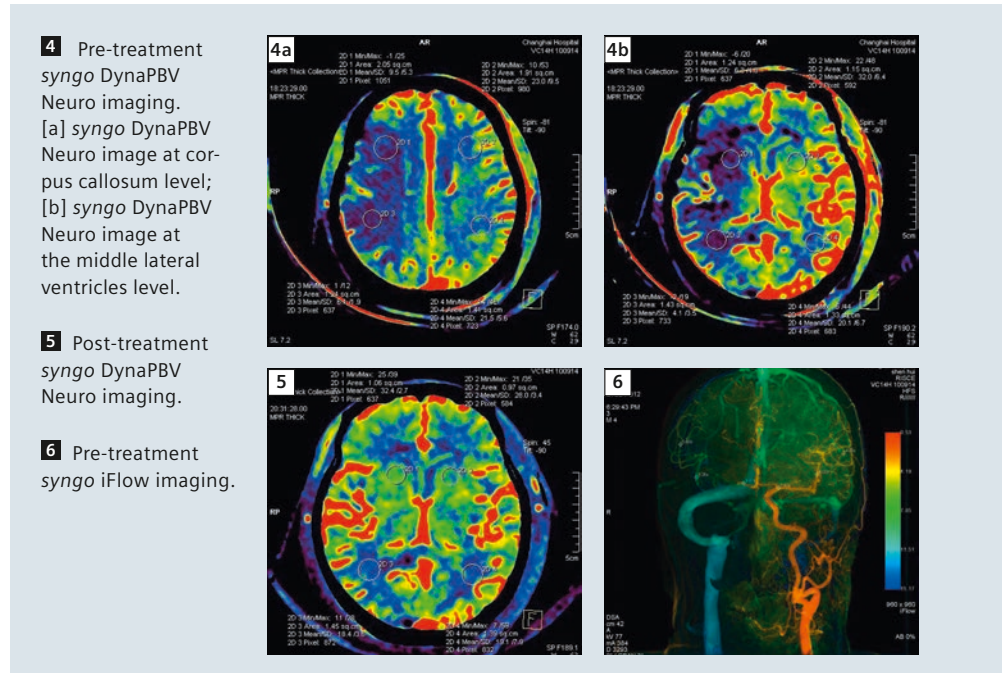
Pre-procedural cerebral CT scan showed no ischemic lesion or infarction (fig. 2). An intravenous 3D *syngo* DynaPBV Neuro examination was performed under general anesthesia to examine the viability of the brain parenchyma.



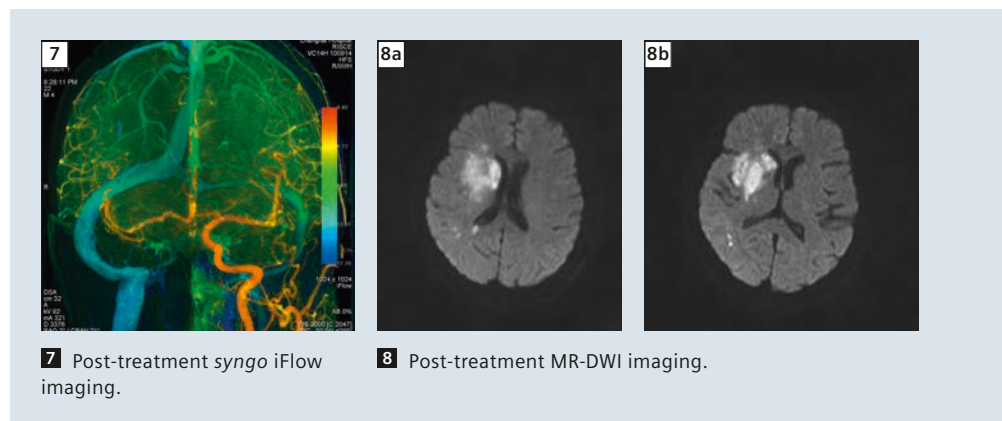
The pre- and post-LICA angiographies were post-processed by *syngo* iFlow (fig. 6, 7). The prolonged blood flow and the improved perfusion in the ipsilateral side were vividly demonstrated by the color-coded images. In addition, there was an obvious delay of time-to-peak (TTP) value in the M2 segment of the R-MCA compared to the contralateral side pre-procedurally while the post-procedural TTP of the bilateral sides turned into the same level, manifesting the improvement of the hemodynamic status. To avoid the risk of re-thrombosis induced by further recanalization, a clinical decision was made to terminate the procedure as the anticipated clinical outcome was already achieved despite the remaining occlusion in the R-ICA. Post-procedural MR images showed an evident shrinkage of the infarction area compared to the pre-procedural *syngo* DynaPBV Neuro (fig. 8). The acute stroke symptoms were clearly relieved after the procedure the patient recovered well was discharged from hospital within nine days.

**Comments**

*syngo* DynaPBV Neuro allows physicians to evaluate cerebral blood volume (CBV) directly in the catheter suite. It can save precious time for physicians to make a credible clinical decision or to determine the end point of interventional procedures when treating patients with acute ischemic stroke. As reported in this case, *syngo* DynaPBV Neuro may also overcome the limitation of DSA by illustrating functional improvement instead of the morphological change in the vessels,



**4** Pre-treatment *syngo* DynaPBV Neuro imaging. [a] *syngo* DynaPBV Neuro image at corpus callosum level; [b] *syngo* DynaPBV Neuro image at the middle lateral ventricles level.  
**5** Post-treatment *syngo* DynaPBV Neuro imaging.  
**6** Pre-treatment *syngo* iFlow imaging.



**7** Post-treatment *syngo* iFlow imaging. **8** Post-treatment MR-DWI imaging.

which is more critical and meaningful for evaluating the curative effect for acute stroke. It assists physicians for better diagnosis, treatment check-up and prognosis prediction. The CBV improvement varies from patient to patient depending on several

factors especially the door-to-balloon time; for these reasons, more data is needed for further study.

**Contact**

janina.beilner@siemens.com

# Quantification of Interhemispheric Venous Phase Timing during Balloon Test Occlusion Supported by syngo iFlow

Courtesy of Alexander Bock, M.D., Head of the Department of Clinical and Interventional Neuroradiology and Andreas Jödicke, M.D., Director of the Department of Neurosurgery Vivantes Klinikum Neukölln, Berlin, Germany



Alexander Bock, M.D.,  
Head of the Department of Clinical  
and Interventional Neuroradiology,  
Department of Neurosurgery Vivantes  
Klinikum Neukölln, Berlin, Germany

Balloon test occlusion (BTO) of the ICA has been performed to identify patients who are at risk for ischemia and stroke following permanent ICA occlusion as a part of surgical or endovascular treatment of extensive cervical and skull base tumors, inaccessible wide-necked ICA aneurysms and some direct arteriovenous fistulas.

BTO has several variations and technical nuances in detecting patients who tolerate permanent ICA occlusion<sup>1</sup>. In summary, the symmetry of the cortical vein filling, when comparing the vascular territory of occluded ICA and the artery to be tested (contra lateral ICA or dominant VA), has the best angiographic positive predictive value for an uneventful ICA occlusion<sup>2,3</sup>.

Visual estimation of venous filling in angiographic series is subjective. In addition, some patients with mainly collateral flow both through  $A_{com}$  and  $P_{com}$  have lower opacification of the veins in the occluded ICA territory.

The important indicator for negative BTO is the synchronicity, rather than the symmetry of the cortical vein opacification when comparing both hemispheres. syngo iFlow exactly

quantifies the time of maximal venous opacification in standard angiographic series including the venous phase. In BTO we use a threshold for the venous time delay > 1 sec between examined and occluded ICA territory to predict a higher risk for ischemic events after permanent ICA occlusion.

For BTO the patient received 5000 IU intravenous heparin. For ICA occlusion a Hyperform or Hyperglide balloon (ev3; Neurovascular, Irvine, California, USA) was positioned within the C4 segment. DSA series of the contralateral ICA were obtained in a standard biplane projection using 3 frames per second (Artis zee, biplane angiographic system, Siemens; Erlangen, Germany).

1. Lesley WS, Rangaswamy R. Balloon test occlusion and endosurgical parent artery sacrifice for the evaluation and management of complex intracranial aneurysmal disease. *J NeuroIntervent Surg* 2009;1:112-120
2. Abud DG, Spelle L, Piontin M, Mounayer C, Vanzin JR, Moret J. Venous phase timing during balloon test occlusion as a criterion for permanent internal carotid artery sacrifice. *AJNR* 2005;26:2602-2609
3. Rooij van WJ, Sluzewski M, Slob MJ, Rinkel GJ. Predictive value of angiographic testing for tolerance to therapeutic occlusion of the carotid artery. *AJNR* 2005;26:175-178

## Case 1

52-year-old male patient presented with severe left eye proptosis and blindness caused by fast growing residual meningioma of the medial sphenoid wing with predominant infiltration of the orbit (fig. 1). After particle embolization of the external tumor feeding arteries extirpation of the meningioma was planned. BTO was performed under general anesthesia and normotensive conditions for potential resection of left ICA (fig. 2). syngo iFlow data showed no delay of the venous phase between occluded left ICA (8,3 s) and right ICA (8,2 s) due to a patent  $A_{com}$  cross-flow (fig. 3).

## Case 2

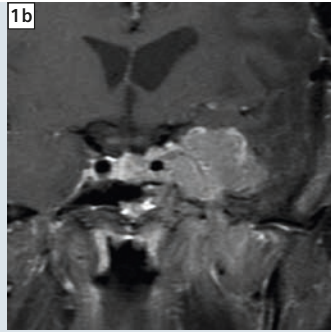
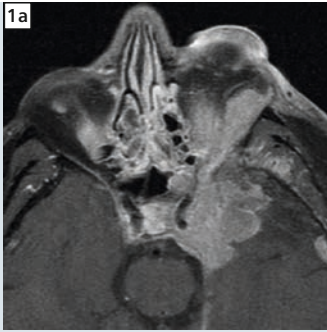
63-year-old female patient presented with a sinusoidal carcinoma infiltrating the skull base and the left cavernous sinus (fig. 4). BTO was performed for left-sided ICA in preparation of a radical tumor resection (fig. 5). A venous phase delay of 2 sec of the occluded left side ICA territory was observed and predicted a high risk for ischemia in case of ICA sacrifice (fig. 6).

## Conclusion

syngo iFlow is a fast and very powerful tool in the detection and quantification of interhemispheric venous phase time delay during balloon test occlusion.

## Contact

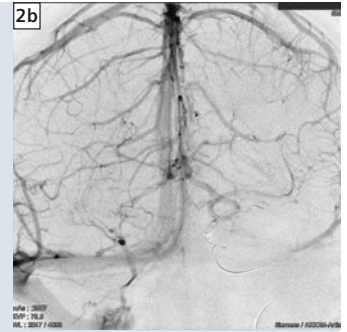
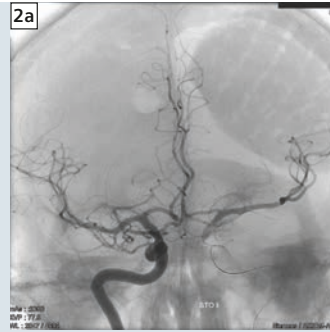
yiannis.kyriakou@siemens.com



**1** [a+b] Meningioma of medial sphenoid wing with marked infiltration of the left orbit and cavernous sinus as shown in post-contrast fat-saturated T1w transversal [a] and coronal [b] images. The cavernous and

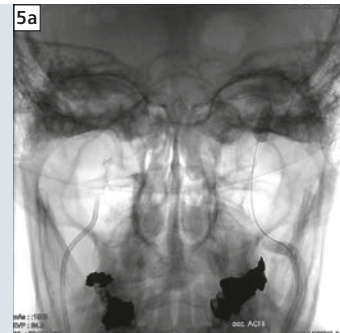
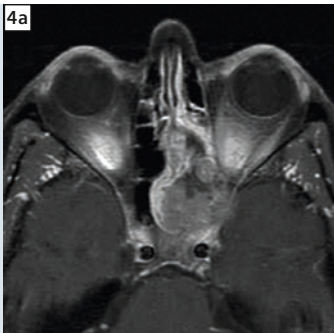
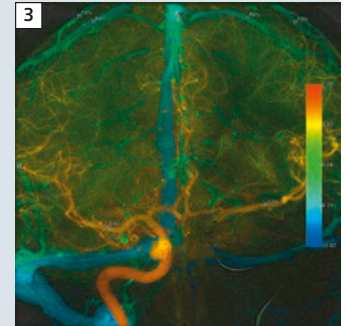
cisternal part of left ICA is surrounded by the tumor.

**2** [a+b] For BTO the left ICA was occluded at the cavernous segment using a 4x7 mm Hyperform balloon [a]. The

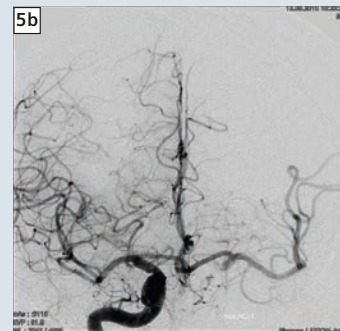
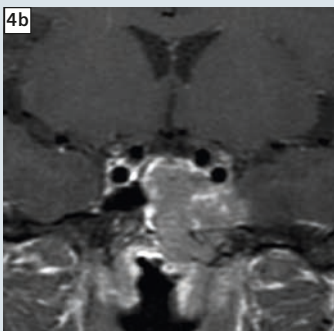


angiogram of injected contralateral ICA shows a symmetric venous filling in both hemispheres [b].

**3** syngo iFlow clearly quantifies the synchronicity of the cortical vein filling in both hemispheres.

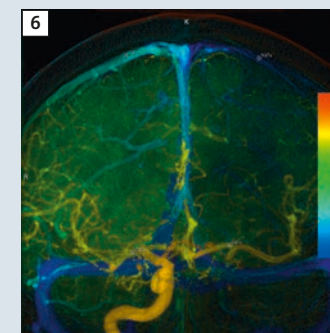
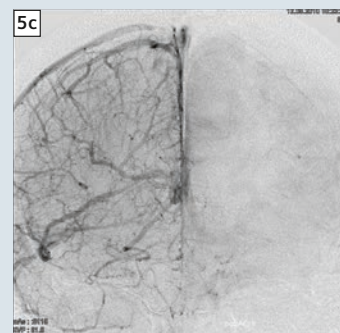
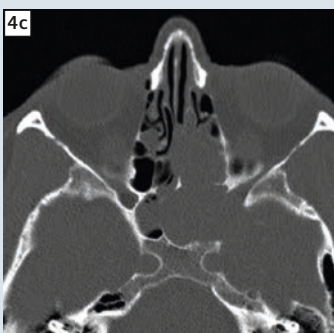


**4** [a+b+c] A sinusoidal carcinoma infiltrates the cavernous sinus close to ICA as shown in T1w fat-saturated post-contrast transversal [a] and coronal [b] images with marked bone erosion of sphenoid part of the carotid channel in CT [c].



**5** [a+b+c] BTO was performed using a Hyperglide balloon (4x10 mm) positioned in the petrous segment of left ICA [a]. DSA series of the right ICA showed a good  $A_{com}$  cross-flow supplying the left ICA territory [b], but with delayed venous filling compared to the right ICA territory [c].

**6** By means of syngo iFlow a delay of 2 sec. between the venous phase of the hemispheres was detected and clearly quantified.





# HCC – Residual Tumor Targeted Supported by *syngo* DynaCT

Tobias F. Jakobs, M.D., Head of the Department of Diagnostic and Interventional Radiology,  
Hospital Barmherzige Brüder Munich, Munich, Germany.



“*syngo* DynaCT enables to quickly identify the tumor-feeding vessel and target the residual tumor without treating non-tumor-bearing, healthy liver parenchyma.”

Tobias F. Jakobs, M.D.,  
Head of the Department of Diagnostic and  
Interventional Radiology,  
Hospital Barmherzige Brüder Munich,  
Munich, Germany

## Patient history

A 78-year-old male with alcohol-induced liver cirrhosis and a single HCC (8 cm) in the right liver lobe (fig. 1, arrow). A single transarterial chemoembolisation (TACE) with drug-eluting beads (100-300 µm) loaded with 100 mg doxorubicin was performed six weeks before. First control MR imaging revealed residual, nodular contrast enhancement in the anterior portion of the former tumor, representing residual tumor tissue (fig. 2, arrow). It was decided to retreat the patient by means of TACE.

## Diagnosis

Hepatocellular Carcinoma (HCC).

## Treatment

On the day of the repeated TACE the initial angiogram (fig. 3) performed with a 4F Cobra catheter placed in the right hepatic artery showed the potential tumor feeders (white arrows) supplying the tumor (yellow arrow). One of these potentially feeding arteries was catheterized and an additional run was performed (fig. 4). At this point it remained unclear whether the whole residual tumor would be covered from this position or whether the other potential feeders needed to be explored as well. A *syngo* DynaCT was performed (fig. 5 a-c and 6) which demonstrated, that (compared to the pre-treatment MRI) the residual HCC would be completely covered from this position (and

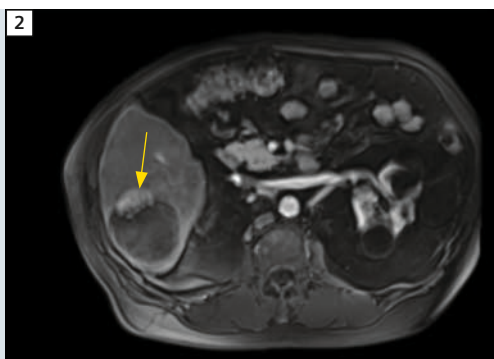
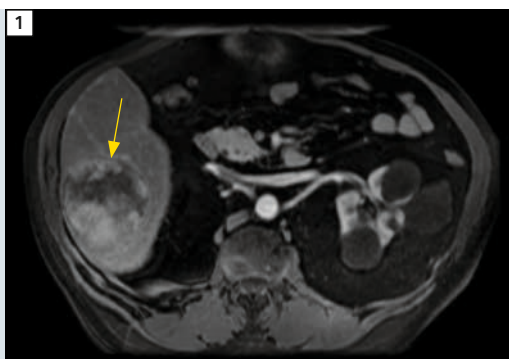
nearly no healthy liver parenchyma) and no efforts were needed to search for additional feeders. Drug-eluting beads were infused safely from this catheter position.

## Comments

Performing *syngo* DynaCT assured the interventional radiologist that the whole residual tumor would be covered from the displayed catheter position and that there was no need to search for additional tumor-feeding arteries.

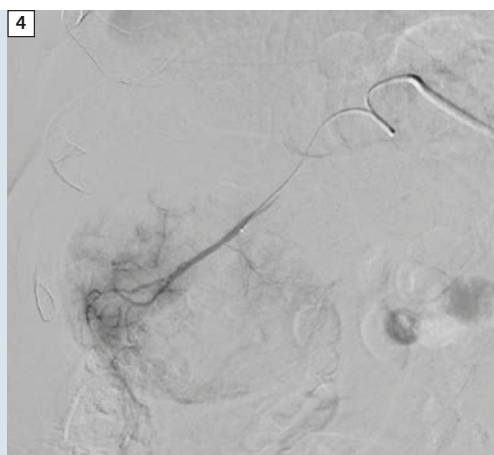
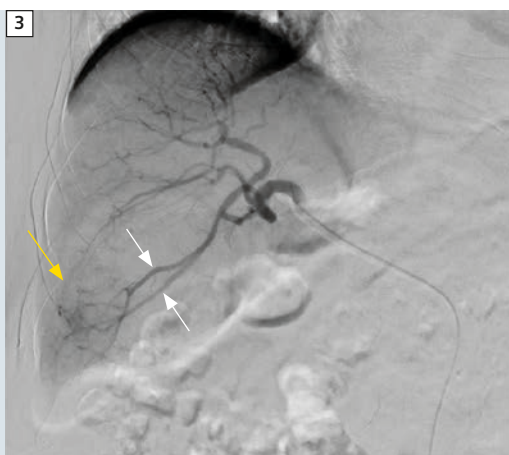
## Contact

simone.henrichs@siemens.com



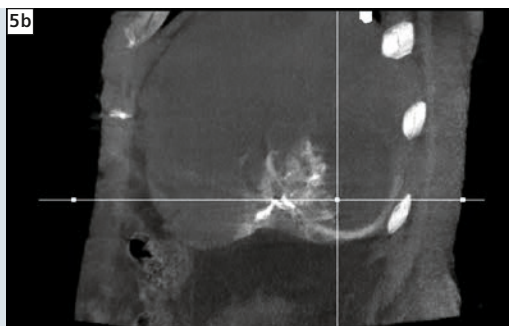
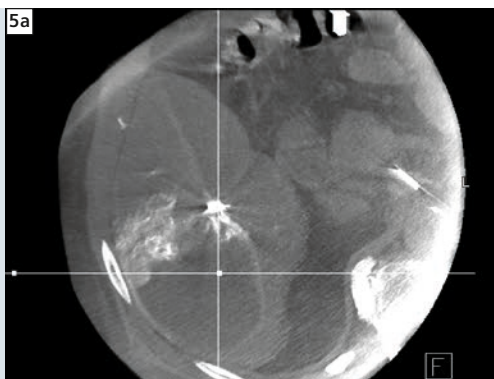
**1** Initial MRI illustrating single HCC with a size of 8 cm in the right liver lobe (arrow).

**2** Control MRI revealing residual tumor tissue (arrow) in the anterior portion of the former tumor.

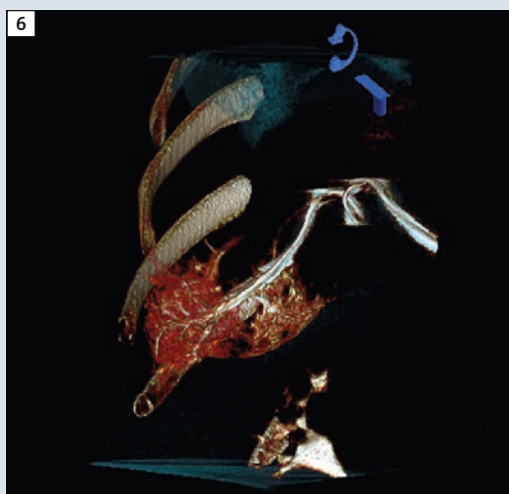
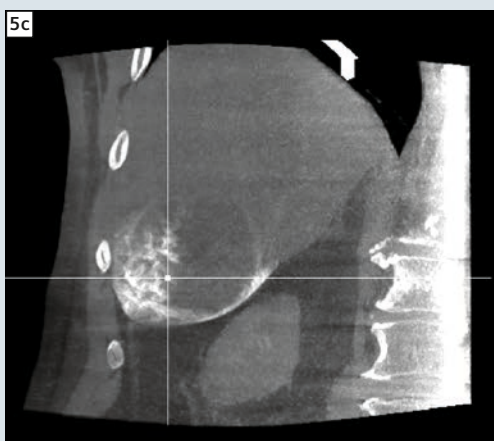


**3** Angiography shows vessels (white arrows) which are potentially supplying the tumor (yellow arrow).

**4** Selective angiogram of one of the feeding arteries.

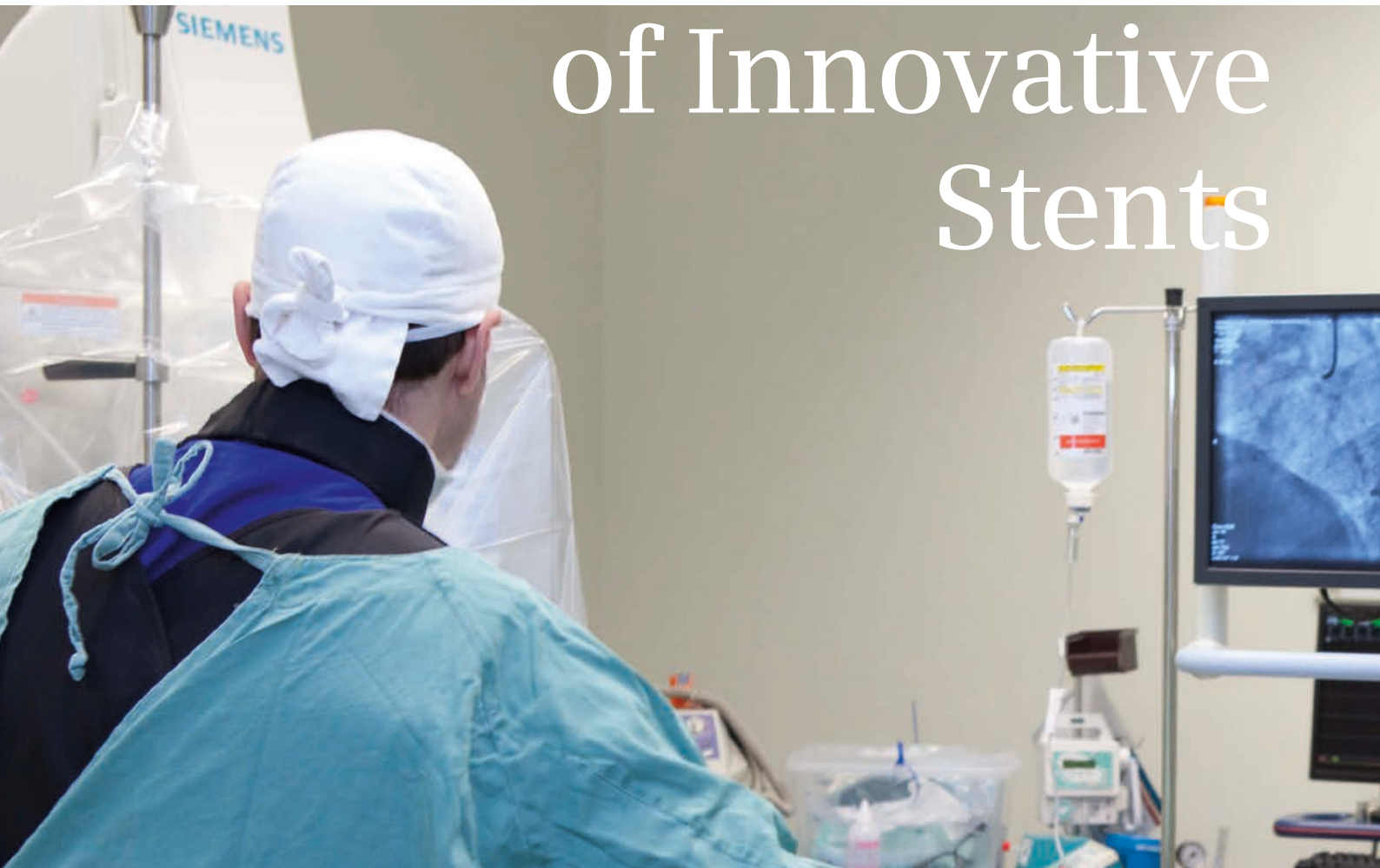

**5** [a-c] The complete coverage of the residual HCC could be verified by syngo DynaCT (MIP representation).



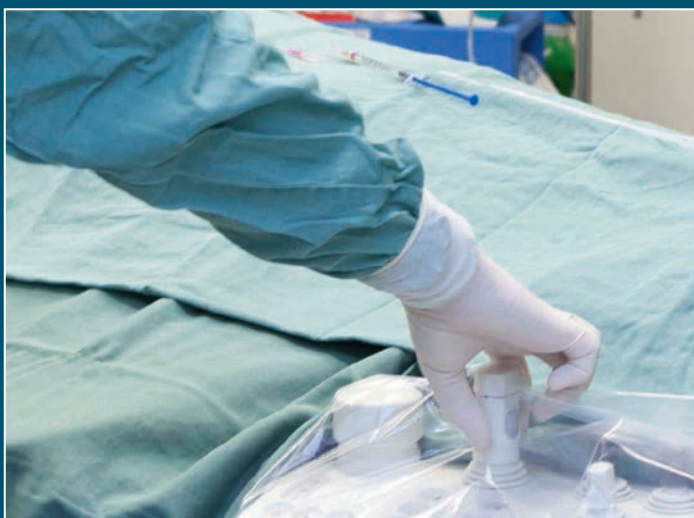**6** Complete coverage of residual HCC shown by syngo DynaCT (VRT representation).

# A Clear View of Innovative Stents

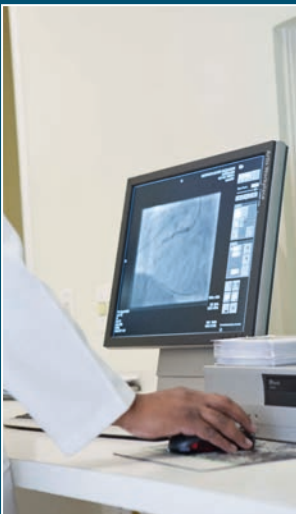
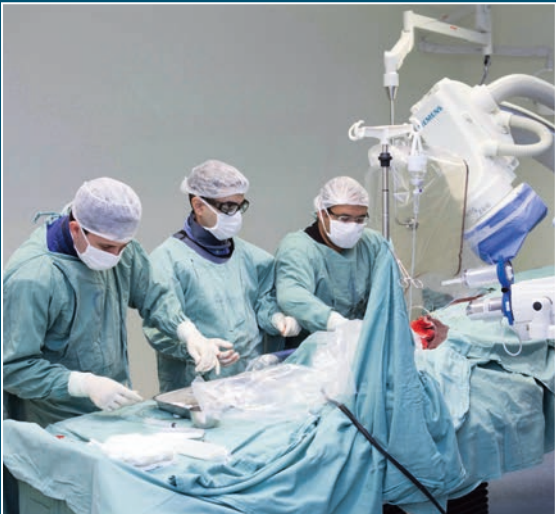
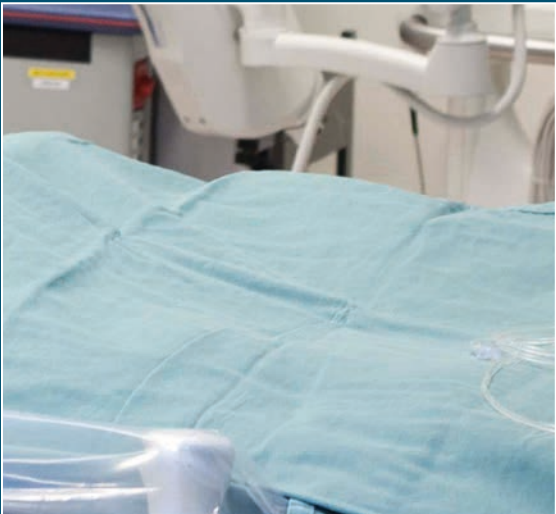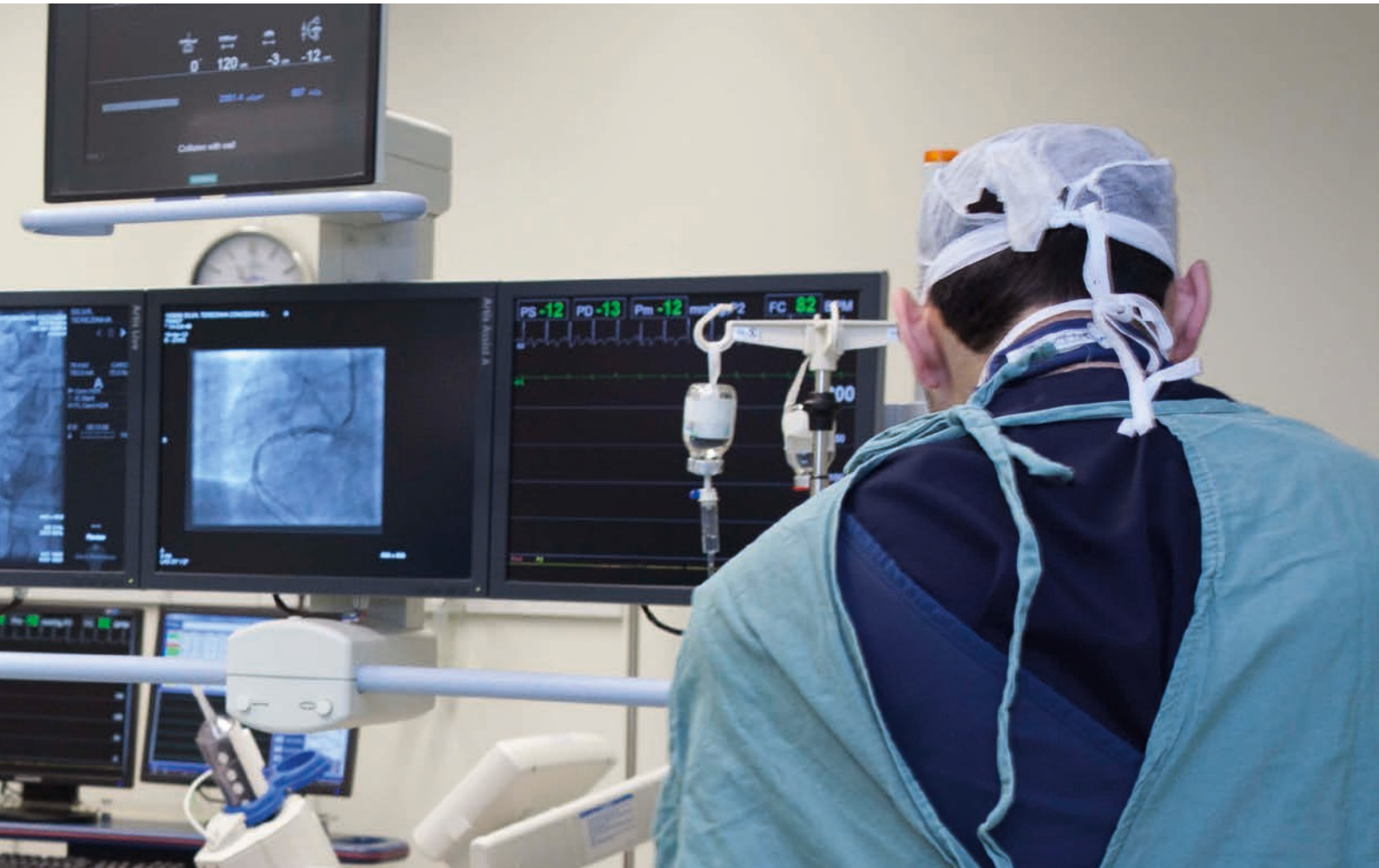At a leading cardiology clinic in Brazil, the Artis zee system from Siemens helps physicians in the clinical trials of bioresorbable polymeric scaffolds.

By Reinaldo José Lopes







Alexandre Abizaid, M.D., and his colleagues at Dante Pazzanese Cardiology Institute, a major medical and research facility in São Paulo, Brazil, are taking part in an international clinical trial of bioresorbable polymeric scaffolds that could have potential advantages over current pharmacological stents. Most of these polylactic acid scaffolds, however, are challenging to image: They are not opaque to X-rays, except for two millimeter-wide platinum “dots” at their tips. To surmount that problem, Dr. Abizaid and his fellow researchers are using the Artis zee system by Siemens.

“The take-home message for me as an interventional physician is that you need high-quality equipment and outstanding image resolution in order to optimize the performance of your implant, and that goes not only for polymeric scaffolds but for metallic stents as well, either bare-metal or drug-eluting ones,” says Dr. Abizaid.

He explains that, although drug-eluting stents have been shown to be an improvement over bare-metal stents – reducing the rate of restenosis from 30% to 5% because they minimize the

rate of intimal hyperplasia – there are still important trade-offs concerning their use. One of them is the need for long-term dual antiplatelet therapy to protect the patient against stent-derived thrombosis. According to Dr. Abizaid, bioabsorbable scaffolds help to address this shortcoming, as they are completely absorbed after 18 months. The polymeric scaffolds would still require dual antiplatelet therapy, however only for the first six to twelve months post-implantation.

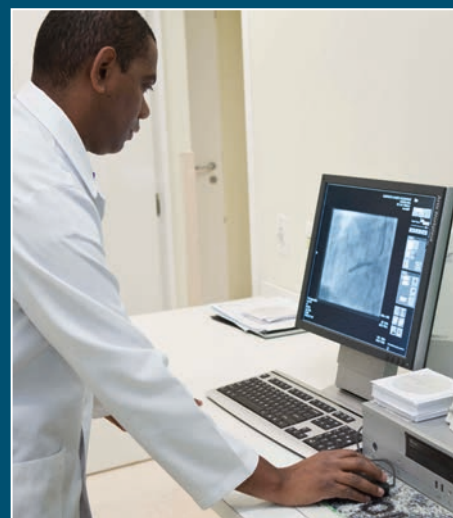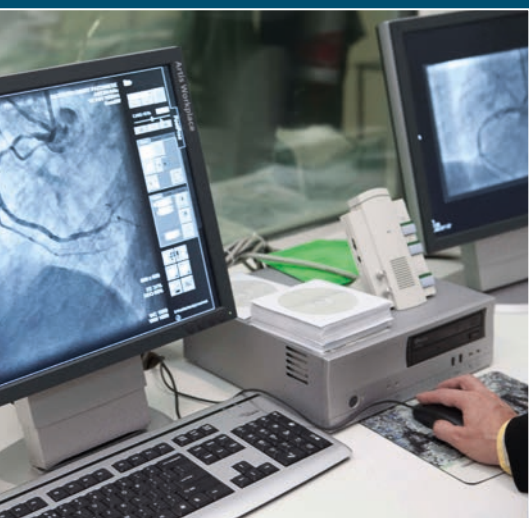There is also the hope that polymeric

scaffolds might avoid the so called “late catch-up” of conventional drug-eluting stents – in such cases, restenosis may be kept at bay at first, only to surface after two years. Besides, some kinds of patients – the ones with more serious coronary disease at younger ages, for example – may have more to gain from bioresorbable stents if repeated implantations are required.

“If several vessels receive a metallic stent, you’re going to have a major problem on your hands if the patient happens to need surgery in the future,”

“We need to know exactly where the stent boundaries are. That is why viewing those little millimeter-wide dots is so important.”

Alexandre Abizaid, M.D.,  
Dante Pazzanese Cardiology Institute, São Paulo, Brazil





explains Dr. Abizaid. “Where do you think a surgeon will be able to insert the saphenous vein during coronary bypass surgery if the whole arterial network already has a metal framework?”

This kind of permanent network would not be in place once polymeric scaffolds were absorbed. Finally, polymeric stents, unlike their metallic counterparts, do not create artifacts during tomography, says Dr. Abizaid. “Therefore, the follow-up of patients that receive them could be less invasive.”

### Precision is Paramount

The team at Dante Pazzanese relies on the precise measurements done by Artis zee, starting with quantitative coronary angiography, as a means to avoid problems that could specifically affect polymeric scaffolds.

“Precision regarding size is crucial for bioresorbable stents because they are far less tolerant to post-dilation than metallic stents, which simply go along with it when you use a bigger balloon,” explains Dr. Abizaid. “If you do the same with a polymeric stent, odds are you are going to fracture it, and nobody wants

that. We need to know exactly where the stent boundaries are. That is why viewing those little millimeter-wide dots is so important.”

According to Dr. Abizaid, Artis zee may also be used during late follow-up. “It is going to depend on the symptoms and on the previous exams,” he says. “If the patient shows up, after six or nine months, with angina pectoris and pain, and if a nuclear medicine exam shows ischemia, we will have to do a catheterization.” By viewing the stent’s landmarks inside the vessel, the team should be able to decide whether to use a new stent or to do a surgical intervention.

The Brazilian clinical trials of three different models of bioresorbable stents started in September 2011 at Dante Pazzanese itself. The first patient, a 66-year-old woman, had 93 percent of her right coronary artery obstructed. Two other major medical facilities in Brazil, the Albert Einstein Israelite Hospital (also in São Paulo) and the Instituto do Coração do Triângulo Mineiro (in Minas Gerais State) are also taking part in the trial.

The three hospitals have already treated about 40 patients – the aim is to reach a number of about 100 patients by the end of this year. And, according to Dr. Abizaid, early data looks promising.

“I had the privilege of presenting the results from the six-month follow-up, including 300 patients – ours and from other sites around the world – earlier this year. The revascularization rate is pretty similar to what we see in metallic stents and there is a low rate of thrombosis – both things are consistent with what we thought before the trial,” he says. “Of course, there could be a price to pay for the absorption. It might not be such an innocent thing after all, but so far we don’t see any signs of trouble.”

*Reinaldo José Lopes is the science and health editor at Folha de S.Paulo, Brazil’s leading daily newspaper.*

### Contact

hanno.herrmann@siemens.com



“The revascularization rate is pretty similar to what we see in metallic stents and there is a low rate of thrombosis.”

Alexandre Abizaid, M.D.,  
Dante Pazzanese Cardiology Institute, São Paulo, Brazil



# Pulmonary Vein Isolation without Fluoroscopy During Left Atrial Procedure: Impact of a New Sensor-Guided Navigation-System – The MediGuide Technology

Courtesy of Thomas Gaspar, M.D.,  
Department of Electrophysiology and Rhythmology,  
Heart Center Leipzig, Leipzig, Germany

## Patient history

A 62-year-old female patient with lone atrial fibrillation. Treatment including a beta-blocker and specific antiarrhythmic drugs (flecainide) did fail in controlling recurrences of the arrhythmia. Stress electrocardiogram and transthoracic echocardiography has not shown relevant structural heart disease. The left ventricular ejection fraction was normal with 60%, the left atrium was slightly enlarged (42 mm in the parasternal long axis).

## Diagnosis

Highly symptomatic, drug-refractory paroxysmal atrial fibrillation indicates catheter-interventional treatment with the aim of circumferential isolation of the pulmonary veins.

## Treatment

The procedure was performed under the guidance of a 3D electro-anatomic mapping system (NavX-EnSite Velocity) supplemented by a novel sensor-based electromagnetic tracking system (MediGuide; MG) installed within the fluoroscopy detector of a flat panel X-ray imaging system (Artis zee). Special sensor-equipped catheters can be localized in 3D and in real-time resulting in 4D visualization within a moving organ image, such as pre-acquired X-ray cine loops.

Before catheter insertion two cine loops in a 20° RAO and 50° LAO were recorded for 5 sec. and a dosage of 453  $\mu\text{Gym}^2$ , each. Based on these cine loops, the MG sensor-enabled electrophysiology catheters were advanced non-fluoroscopically and positioned in the coronary sinus and the apex of the right ventricle. Consecutively, LA angiograms were acquired for serving as dynamic cine loops during the LA procedure. For that, 50 cc of non-ionic iodinated contrast material was injected through a pigtail catheter into the common pulmonary artery trunk. The fluoroscopic acquisition started after 4 sec. of lung passage time and takes 4 sec. in a 20° RAO and 6 sec. in a 50° LAO projection, respectively. The cumulative fluoroscopy dosage after these steps was 1356  $\mu\text{Gym}^2$ . Hereafter a single transseptal (TSP) puncture was made. For safety reasons and due to the fact that neither a TSP sheath nor a TSP needle equipped with the MG sensor is available, this was performed under fluoroscopic guidance with a steerable sheath. This resulted in a cumulative fluoroscopy time and dosage of 2.6 min. and a dosage of 1985  $\mu\text{Gym}^2$ . Hence, no fluoroscopy was necessary up to the end of the procedure.

The four PVs were reconstructed as individual NavX-EnSite anatomies with an

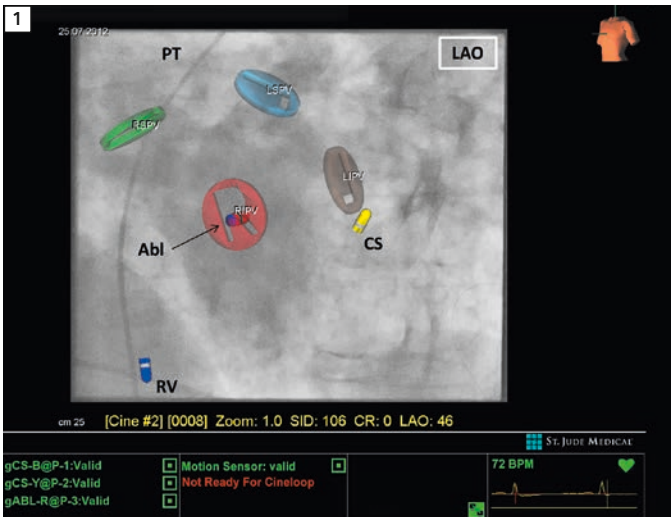
MG sensor-equipped irrigated tip ablation catheter and subsequently served as the anchor structures to register the 3D CT image. LA mapping and ablation were performed using a specific MG sensor-equipped irrigated tip ablation catheter. That catheter could be tracked within the LA angiogram in real-time (fig. 1, 2). Circumferential ablation around both ipsilateral PVs was performed at the atrial side of the PV antrum (fig. 3). Bidirectional conduction block was the end point of the procedure, and was confirmed by the circular mapping catheter.

Successful pulmonary vein isolation was performed within 159 min. with a total fluoroscopy time of 2.6 min. and a fluoroscopy dosage of 1985  $\mu\text{Gym}^2$ .

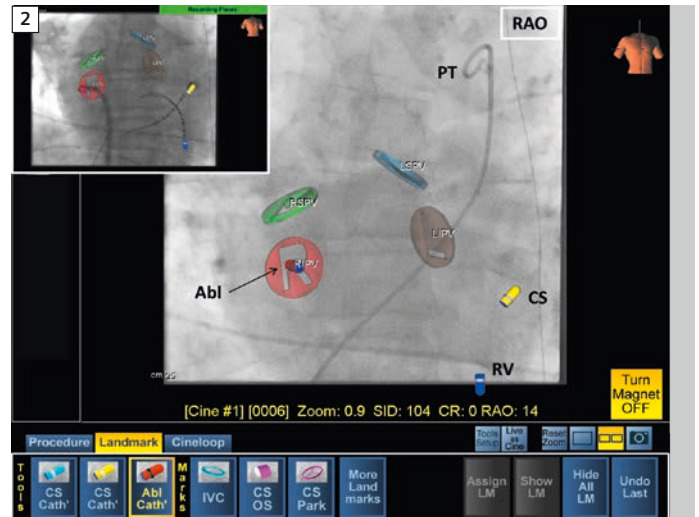
1. Piorkowski C, Hindricks G. Nonfluoroscopic sensor-guided navigation of intracardiac electrophysiology catheters within prerecorded cine loops. *Circ Arrhythm Electrophysiol.* 2011 Aug; 4 (4):e36-8
2. Rolf S, Sommer P, Gaspar T et al.: Ablation of Atrial Fibrillation using Novel 4D Catheter Tracking within Auto-Registered LA Angiograms. *Circ Arrhythm Electrophysiol.* 2012 Jul 7. [Epub ahead of print]

## Contact

dietrich.till@siemens.com



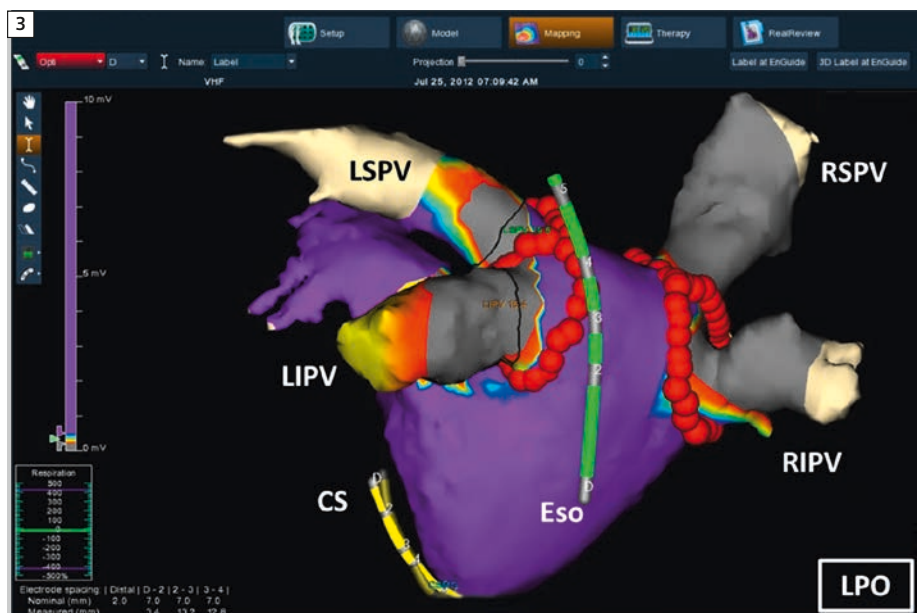
**1** Screen shot of the MediGuide user interface during a pulmonary vein isolation procedure in a left anterior oblique projection (LAO). Three MediGuide sensor-enabled catheters are tracked real time and non-fluoroscopically by the electromagnetic sensor field and projected as an icon on their intracardiac position within prerecorded left atrium angiographies. One catheter is placed in the coronary sinus (CS - yellow icon), one in the apex of the right ventricle (RV - blue icon) and the sensor-enabled ablation catheter is on the ostium of the right inferior pulmonary vein (Abl - red icon). During mapping of the pulmonary veins their ostia are marked by chips of different color (right superior pulmonary vein - RSPV, green chip; right inferior pulmonary vein - RIPV, red chip; left superior pulmonary vein - LSPV, blue chip; left inferior pulmonary vein - LIPV; grey chip).



**2** Screen shot of the MediGuide user interface during a pulmonary vein isolation procedure in a right anterior oblique projection (RAO) combined with the validation of displayed catheter position on fluoroscopy (small image on left upper side). Similar to fig. 1, three MediGuide sensor-enabled catheters are tracked in real time and non-fluoroscopically by the electromagnetic sensor field and projected as an icon on their intracardiac position within prerecorded left atrium angiographies. For validation catheter positions are now visualized simultaneously on live fluoroscopy and non-fluoroscopically within the MediGuide surface. The overlay of the fluoroscopic catheter image and the non-fluoroscopic catheter icons indicates the accuracy of the system for catheter localization.

“The application of this promising new catheter tracking technology integrated into Artis zee offers nearly fluoroscopy-free operations even in complex ablation procedures.”

Thomas Gaspar, M.D.,  
Electrophysiology and Rhythmology,  
Heart Center Leipzig, Leipzig, Germany



**3** Visualization of the 3D model of the left atrium at the end of the procedure within the electroanatomic mapping system.

# EVAR-3D Guidance

## How Artis zeego Club Can Help to Facilitate the Exchange of Surgical Workflows

Visionary surgeons around the world are continuously developing new applications for hybrid operating rooms. Translating these new workflows to other surgical sites can be a challenge, because there are hardly any global forums to exchange hands-on know-how. The Artis zeego Club fills this gap as it is illustrated here with the new EVAR-3D Guidance workflow for AAA cases.

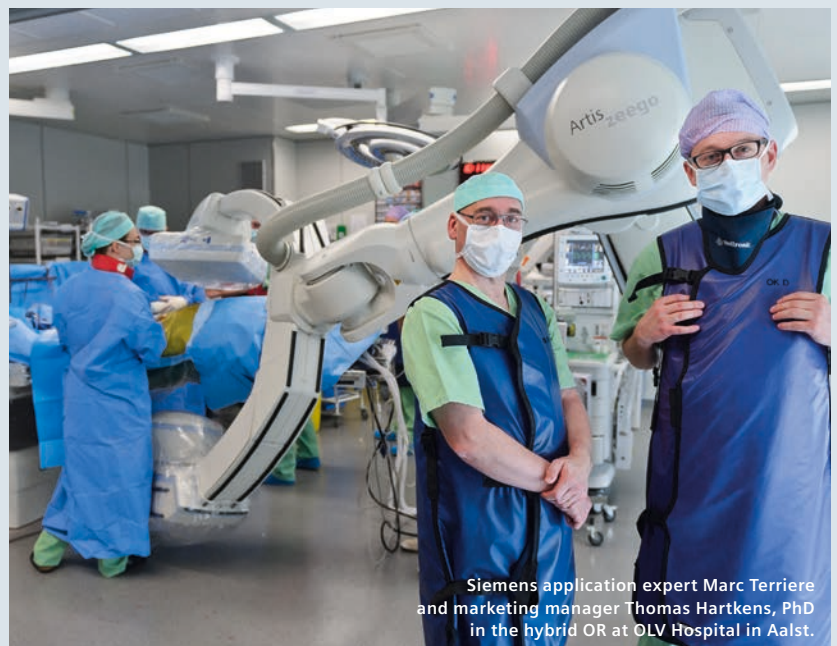At LINC 2012 in Leipzig, Lieven Maene, M.D., vascular surgeon at the OLV Hospital in Aalst Belgium, introduced EVAR-3D Guidance, a new workflow to fuse intra-operative 3D images with live fluoroscopy to guide endovascular procedures utilizing Siemens' Artis zeego and *syngo* iGuide Toolbox. He envisaged and implemented this new workflow



Lieven Maene, M.D.,  
OLV Hospital,  
Aalst, Belgium.



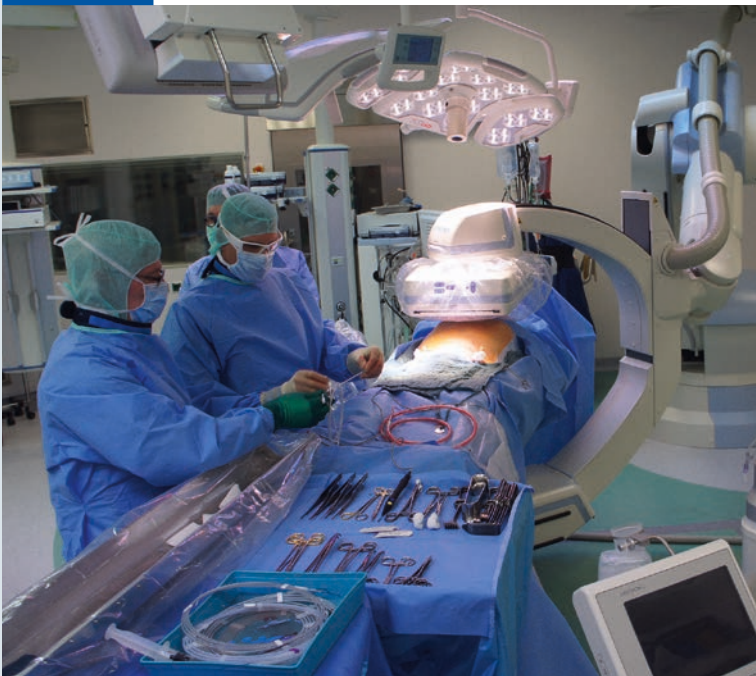Johannes Gahlen, M.D. (right)  
and Wilko Staiger, M.D. (left),  
Ludwigsburg Hospital, Germany.



Siemens application expert Marc Terriere  
and marketing manager Thomas Hartkens, PhD  
in the hybrid OR at OLV Hospital in Aalst.



## Step 1 Placement of the catheter at the Ludwigsburg Hospital



As a member of this club Dr. Gahlen has access to latest technical developments, case spotlights, special event, and chances to network with other users. In addition, he receives privileged advice and assistance from Artis zeego experts. In this case, the support team of the Artis zeego Club from Siemens headquarters came to the Ludwigsburg hospital to support the first case and walked through each individual step of the workflow. The patient presented with an abdominal aortic aneurysm (AAA) requiring a Cook Medical Zenith Fenestrated AAA Endovascular Graft, which needs special care to ensure that the renal ostium remains free from occlusion. The following steps were performed with the help of the Artis zeego Club:

### Step 1

#### Placement of the catheter

In general, stiff catheters deform the iliac arteries and the aorta when advanced into the aorta. Thus, the anatomy in pre-operative images might not exactly match the intra-operative situation. Therefore, information derived from pre-operative images or images acquired before the catheters are inserted might not meet the accuracy required for precise 3D guidance. In contrast, in this workflow the catheter with the endograft is inserted in the aorta, but not released, before the 3D *syngo* DynaCT acquisition. By acquiring the 3D image after inserting the catheter, the deformations are captured and the final overlay of the 3D image matches the live fluoroscopy with minimal distortions.

by himself with the help of a local Siemens' application expert. Dr. Maene presented a patient with ischemia of the bowel and an occlusion of the superior mesenteric artery. "We could go with trial and error: a lot of scraping of the inside of the aorta, trying to find this orificium," said Dr. Maene. A better strategy, he said, would be to utilize EVAR-3D Guidance, via 3D angiography, 3D navigation mapping and a live system that would guide the operator. Dr. Maene's workflow description impressed the audience with its simplicity and efficacy. In response to the presentation, panel member Frank Veith, NYU Cardiac and Vascular Institute, New York, joked:

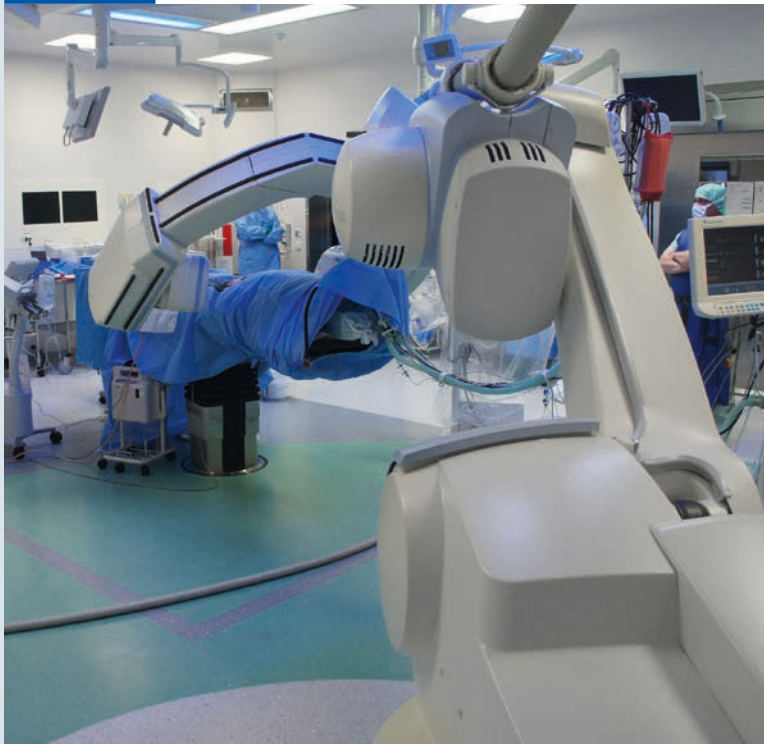"It's fantastic – the nurses could do the cases with this [system]."<sup>4</sup>

<sup>4</sup> "3D mapping for the hybrid operating room" in LINC review 2012, Liam Davenport (editor), MediFore Limited (publisher), page 16-18, 2012.

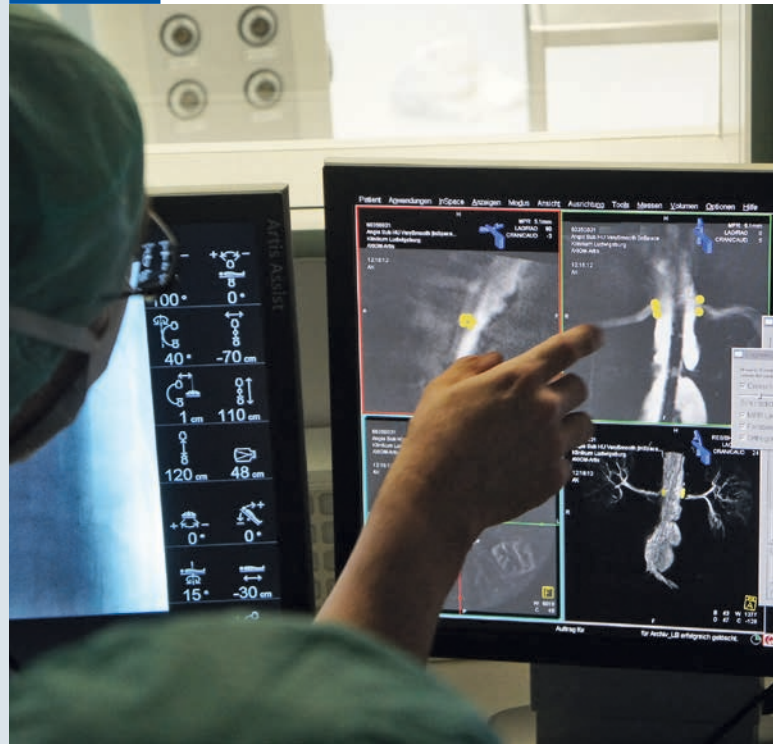### Sharing surgical workflows

LINC panel member Johannes Gahlen, M.D., head of the Vascular and Endovascular Department at Ludwigsburg Hospital in Germany, did not hesitate and decided to implement this workflow in his hybrid operating room with the help of the Artis zeego Club.

## Step 2 3D syngo DynaCT acquisition



## Step 3 3D planning at the workstation



### Step 2

#### 3D syngo DynaCT acquisition

The 3D syngo DynaCT is acquired with the catheter in place. For instance, a five-second digital subtraction angiography (DSA) protocol with undiluted 6 cc contrast agent injection per second can be chosen. The image is analyzed at the 3D workstation in the control room.

### Step 3

#### 3D planning at the workstation

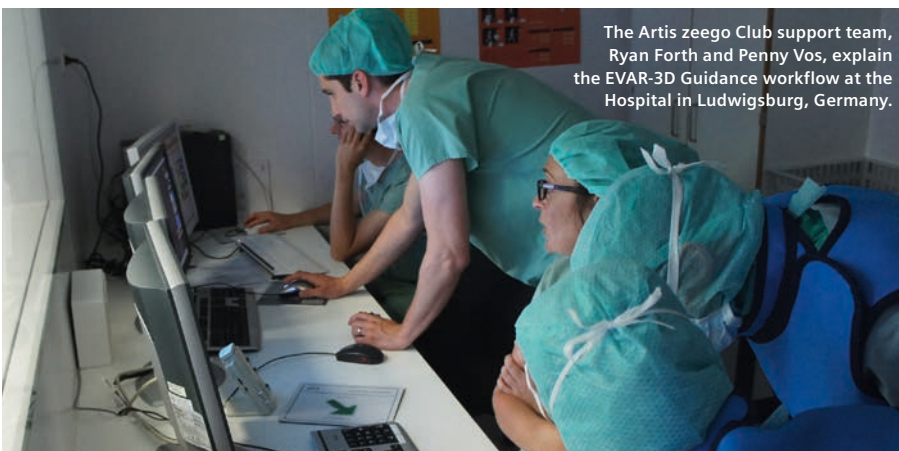The workstation displays the syngo DynaCT image in three orthogonal slices as well as a 3D volume rendering in the lower right window. The surgeon marks the landing zone or the ostia of the renal arteries in one of the multi-planar views in the form of a guidance ring dis-

played as yellow dots. Later in the OR, the guidance rings help the surgeon to place guidewires into the renal arteries. The automatic outlining is switched on, which provides additional information about the anatomy, including the position of the renal arteries.

### Step 4

#### 3D guidance on live fluoroscopy

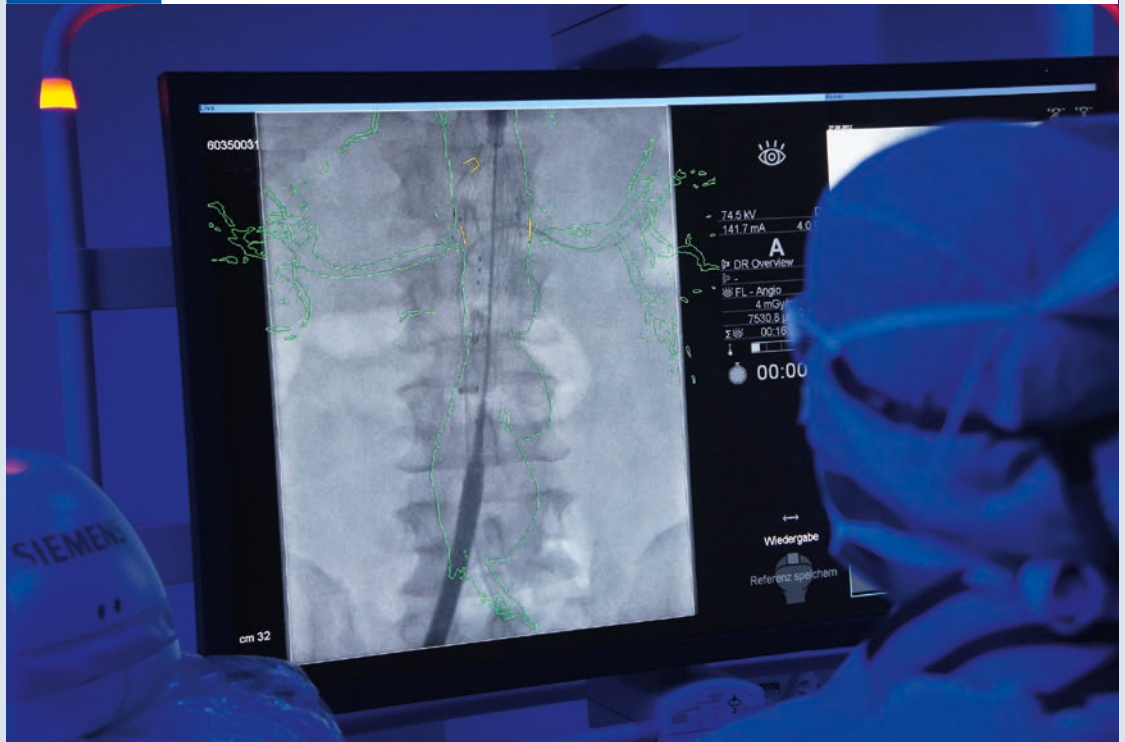
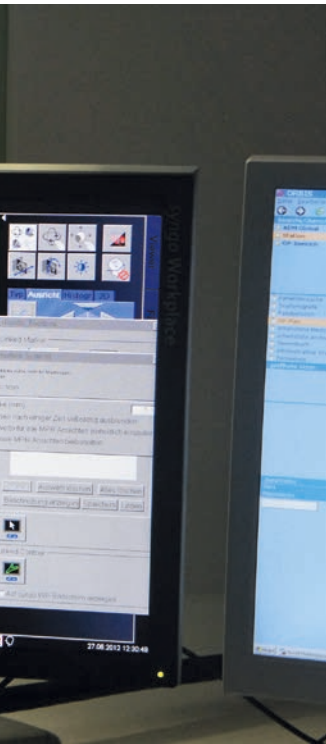
The three-dimensional plan prepared at the workstation is automatically overlaid on top of the fluoroscopy images. It includes the aorta outline and the manually drawn guidance rings. The 3D overlay is linked with the C-arm, i.e. the workstation recognizes any movement of the C-arm and recalculates the overlay accordingly. For example, when the surgeon moves the C-arm so that the ring becomes a line, the C-arm angulation is exactly perpendicular to



The Artis zeego Club support team, Ryan Forth and Penny Vos, explain the EVAR-3D Guidance workflow at the Hospital in Ludwigsburg, Germany.



## Step 4 3D guidance on live fluoroscopy



the corresponding vessel which is considered an optimal view of the anatomy. The 3D guidance markers support the surgeon in placing guidewires into the renal arteries. The outline is updated continuously when the C-arm is moved and indicates the actual anatomy without injecting contrast agent.

Altogether, the new EVAR-3D guidance workflow results in optimal C-arm angulation, perpendicular to the vessel of interest, and provides a precise 3D overlay. It helps surgeons to place the catheter in the aorta or navigate guidewires into the ostia of renal arteries, for instance. Finally, this will lead to reduced procedure times, lower X-ray dose, and use of less contrast agent.

## The Artis zeego Club

The Artis zeego Club was founded to advance new procedure methods and uses of the Artis zeego system. It is a loose community of Artis zeego users around the world who receive privileged advice and assistance from a dedicated Artis zeego expert team at Siemens' headquarters. They also have access to technical and clinical knowledge through unique video demonstrations, webcasts and

educational programs. Artis zeego members also receive continuous system software updates at no extra charge\*. The online platform of the Artis zeego Club is an opportunity to network with peers, share insights and learn from each other via the private Artis zeego discussion forum. Members can learn from peers to enhance their current practice and widen clinical offerings.

\* Service and application training not included

### Contact

thomas.hartkens@siemens.com  
ryan.forth@siemens.com

[www.siemens.com/artis-zeego-club](http://www.siemens.com/artis-zeego-club)  
[www.siemens.com/surgery](http://www.siemens.com/surgery)



# A Hybrid OR for CMF Surgery – Breaking a Fly on the Wheel?

“The Artis zeego connects all planning and intra-operative tools across disciplines on one common platform.”

Prof. Alexander Schramm, M.D., D.M.D.,  
Department of Cranio-Maxillary-Facial  
Surgery, Army Hospital, Ulm, Germany



Why is a small field like cranio-maxillofacial trauma interested in using a highly sophisticated hybrid OR? How is the system used and the procedures financed? All this and more is explained in this interview with Prof. Alexander Schramm, M.D., D.M.D., chairman of Cranio-Maxillary-Facial Surgery at the Army Hospital in Ulm, Germany. His department focuses on implantology, traumatology, tumor therapy, and dysgnathia.

## Multidisciplinary use of the hybrid OR at the University Hospital in Ulm

**Professor Schramm, you are the first CMF surgeon to use a hybrid OR.**

**Where do you see the advantages?**

The difference between a conventional OR and a hybrid OR is foremost the unique integration of intra-operative navigation and intra-operative imaging; additionally the hybrid OR allows a semi-automated use of telemanipulators. That means that for the first time we are able to acquire large volume images of soft tissue during surgery and then connect it with all pre-operative planning modalities and intra-operative navigation tools.

Especially for skull base tumors, the Artis zeego in the hybrid OR is an important indication-expanding system.

**Are these kinds of surgeries limited to one surgical field or is the approach a multidisciplinary one?**

Skull base tumors principally require an interdisciplinary approach for neurosurgeons, ENT and CMF surgeons. Also interventional radiology, radiation therapy, oncology and anesthesiology

are involved. And this is exactly where we see the advantage of the hybrid concept. It connects all planning and intra-operative tools across disciplines on one common platform. This really facilitates interdisciplinary work. Different software and different medical systems can be used in the hybrid environment.

**You don't have an Artis zeego system in your hospital but instead use the one at the university hospital. Why?**

The answer is easy: A small field like CMF surgery can not use the hybrid OR to full capacity. Other surgical disciplines in our hospital decided on other solutions. I am quite happy about that because I have a special situation here in Ulm where I can use all the facilities and have all the possibilities.

**The initiative to build a hybrid OR was initiated by Professor Gebhard, Director of Surgery and Head of Traumatology. How did you get involved and how was the joint usage of the room financed?**

The application, the permission and financing for incorporating a hybrid OR into the newly built hospital was based on diverse conditions. One of them was

to come up with an interdisciplinary concept and this included CMF surgery. CMF surgery is located in the Army Hospital, which is a teaching hospital of the University of Ulm and the only CMF department in Ulm with inpatient beds. Regarding different financing models and usage of the room, we are currently under negotiations. One option would be to rent anesthesia and nursing personnel; another would be to use the anesthesia capacity of the University of Ulm.

#### Which indications, other than tumor surgery, could you imagine for the Artis zeego?

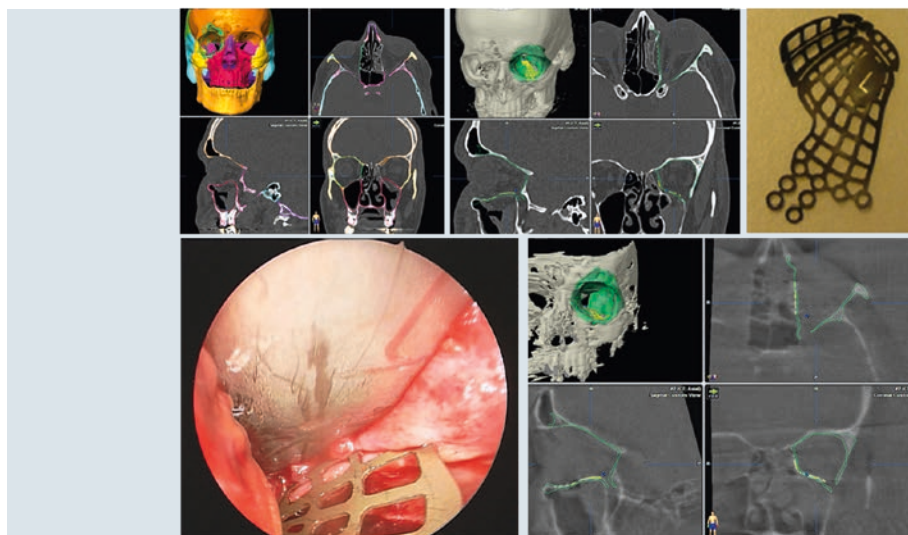
Complex trauma surgery is an outstanding area of application for the Artis zeego, because here we have the possibility to take care of patients who have difficult and/or extensive panfacial fractures right away.

Especially the pre-operative planning phase can be shortened as well as the surgery time, and because of the large volume and quick acquisition of images, we get to demonstrate the entire facial skull. This is helpful, when neighboring disciplines like neurosurgery, ENT surgery, ophthalmology and spine surgery have to be involved.

Another advantage is the joint care together with traumatologists and orthopedic surgeons. All essential requirements are aligned so that the patient can be taken care of in a multidisciplinary approach. I believe this is a key value for the use of hybrid OR in CMF surgery.

**In your conventional setting you use the Brainlab navigation system and the Siemens Orbic 3D mobile X-ray system. Are there any limitations?**

A limiting factor is radiation dose. For that we still need clinical and pre-clinical data of patients and co-workers



Virtual reconstruction and planning of the procedure, here an orbita reconstruction. Pre-forming of patient matching plates and exact intra-operative placement due to image guided surgery (CMF planning software by Brainlab® AG, Feldkirchen, Germany, and intra-operative 3D imaging by Siemens AG).

and this demands a risk-benefit analysis. Only when this is done can we give recommendations regarding dose reduction according to the ALARA principle (as low as reasonably achievable).

#### Do you already have a concept of clinical studies with the Artis zeego in your new hybrid OR?

We plan to measure dose in the OR prospectively and monitor retrospectively for evaluation. With this analysis we can determine how much dose is required for which procedures. That is, every procedure needs to be evaluated for this data.

#### Just imagine money and room restraints were not a factor. If you could plan a hybrid OR, how would you proceed and what would you integrate?

One issue is definitely resources regarding working personnel. A well-educated nursing staff is of importance for OR assistance, from both a surgical and

radio-technical standpoint. It is definitely in our interest to push the academic education of nursing workforce. Furthermore anesthesiologists play a certain role during surgical procedures. All in all sufficient staff within our department is of key importance to guarantee the best workflow. As soon as the issue regarding resources is solved, technical requirements can be planned and should be fulfilled. Pre-operative planning must be connected extensively with intra-operative imaging and intra-operative navigation. Additionally, the integration of robotic systems and telemanipulators should be promoted so that in the future integration without interface problems is possible. Once we are able to achieve these goals, a hybrid OR can be economically used over the long term and is definitely planned.

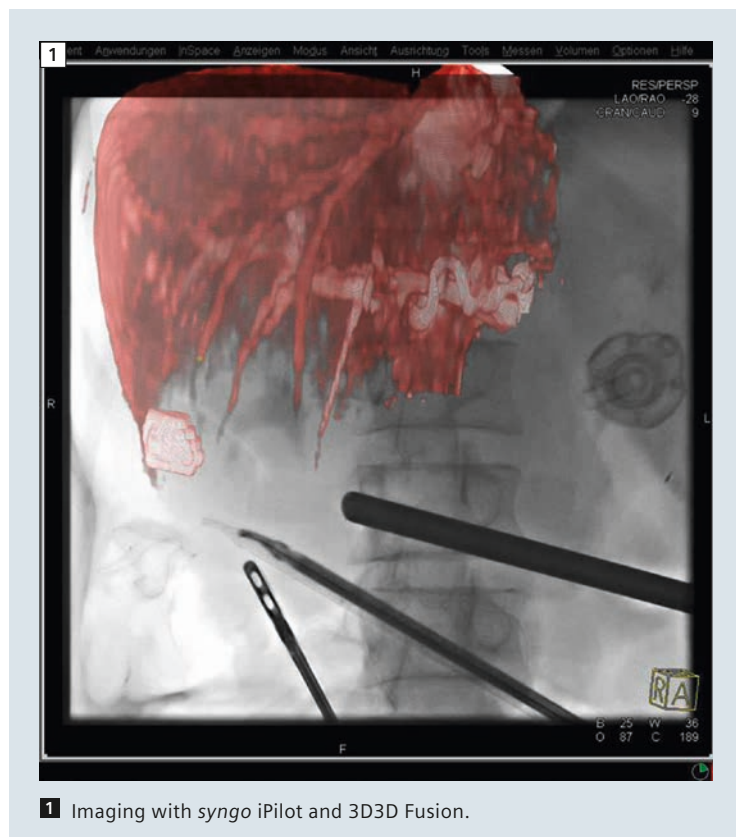
#### Contact

ina.schwabenland@siemens.com

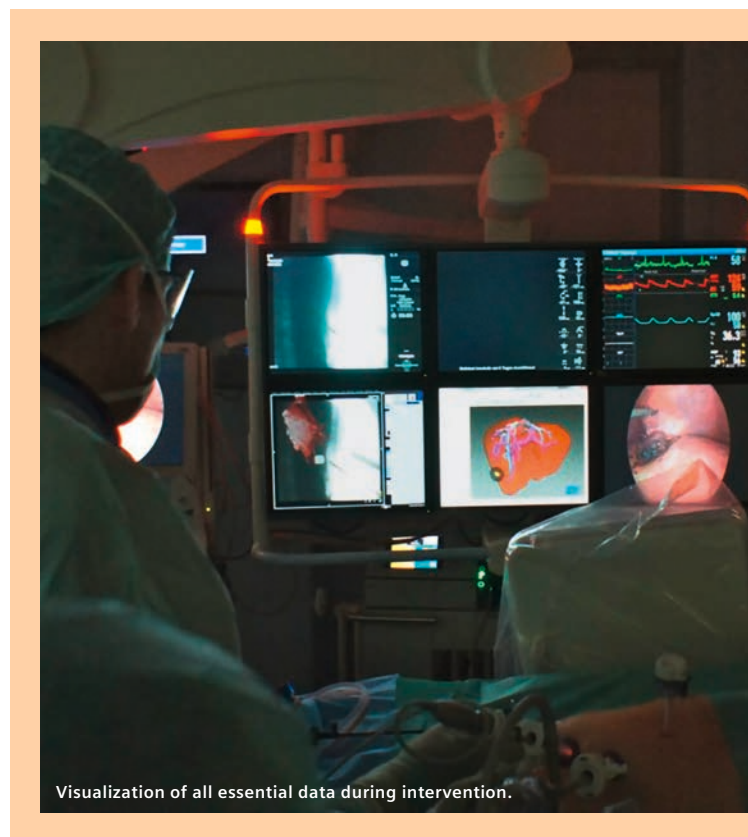
# Minimally Invasive Liver Resection Supported by *syngo* DynaCT

Courtesy of PD Beat Müller, M.D., Prof. Jürgen Weitz, M.D.

Department of General, Visceral and Transplantation Surgery, University Hospital of Heidelberg, Heidelberg, Germany



1 Imaging with *syngo* iPilot and 3D/3D Fusion.



Visualization of all essential data during intervention.

## Patient history

The 62-year-old male patient suffered from hepatocellular cancer due to a chronic hepatitis C.

## Diagnosis

Hepatocellular carcinoma located in liver segment 6.

## Treatment

The minimally invasive approach was planned due to the favorable localization of the tumor. A pre-operatively acquired MRI scan was segmented for pre-operative planning with the help of the DKFZ in Heidelberg. The segmentation helped to segment the liver from the rest of the abdomen

and to make vessels and the tumor visible within the organ. Surgery started with placing 4 ports and an insufflation of CO<sub>2</sub>. The abdomen was prepared for optimal access to the tumor and therefore the position of the patient was changed to reverse Trendelenburg (10°) and tilt to the left (15°). Then a *syngo* DynaCT was performed and the 3D volume was automatically registered with the pre-operative MRI volume. The fusion of both volumes could be visualized in the 2D fluoroscopic image to get a real-time update of the current situation. This fluoroscopic control with *syngo* iPilot, 3D/3D

Fusion, proved helpful in navigation the instruments very precisely (fig. 1). The cancerous tissue was removed and surgery was finished successfully without any adverse events.

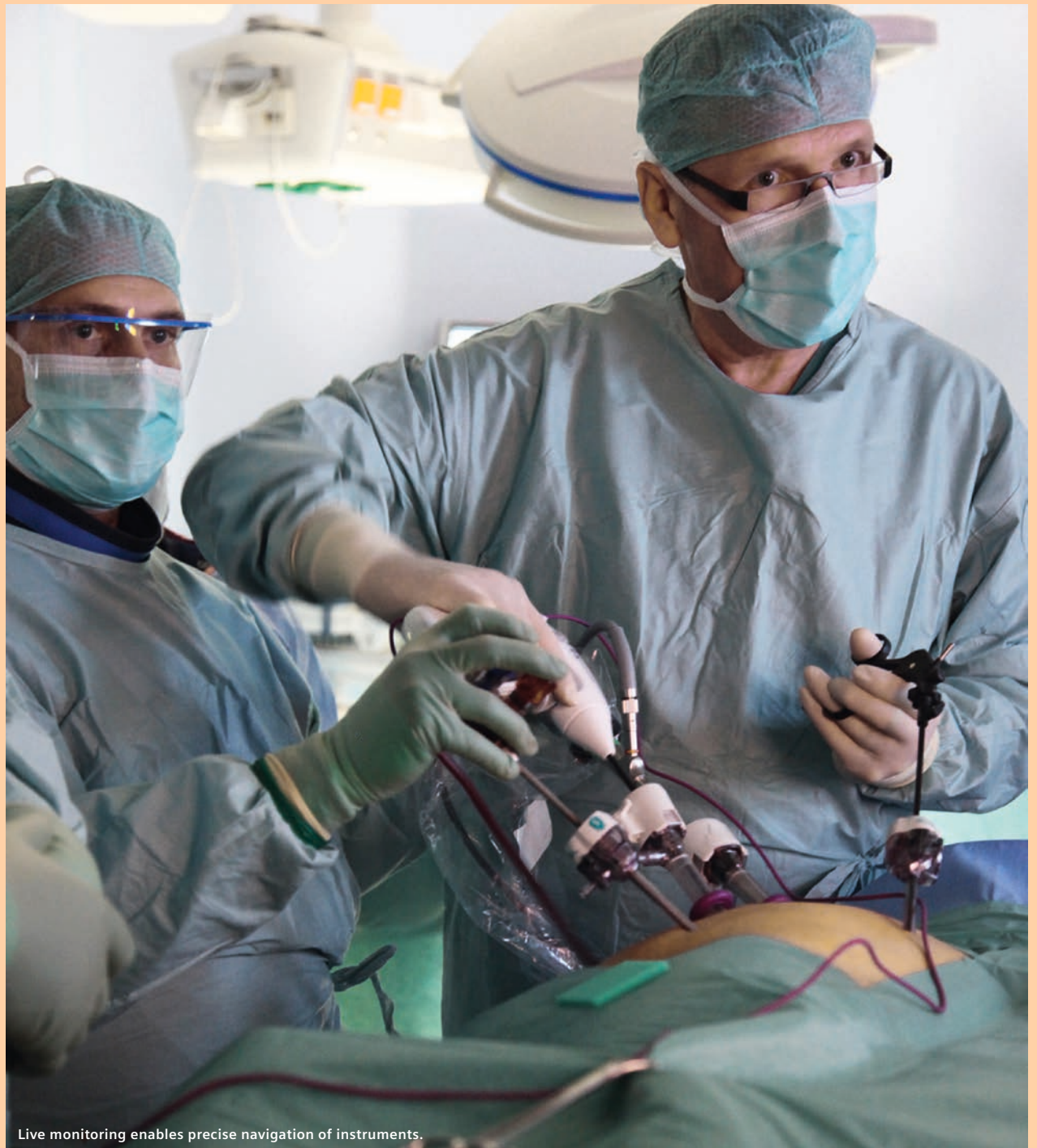## Comments

It was the first case in liver surgery supported by *syngo* DynaCT and the future advancement of the technologies involved will be very interesting and are definitely being planned.

## Contact

ina.schwabenland@siemens.com





Live monitoring enables precise navigation of instruments.

# Very Promising Addition

Hybrid rooms are now being used for interventional imaging during thoracoscopic surgery

By Hildegard Kaulen, M.D.

Völklingen is a district town on Germany's western border. Integral to the city are the Völklinger Ironworks, which is a UNESCO World Heritage Site, and the Heart, Lung, and Vascular Centers of the SHG Hospitals, which are among the largest and most advanced in southwestern Germany. AXIOM Innovations spoke with medical director Helmut Isringhaus, M.D., about the use of hybrid operating rooms in thoracic procedures.

**Dr. Isringhaus, diagnostics and surgery are performed on the same table in a hybrid OR. To date, angiographies and heart surgeries have been performed there. You now want to use the hospital's hybrid OR and its new Artis zeego for video-assisted thoracoscopic surgery (VATS) with interventional imaging. What gave you the idea?**

A hybrid OR has a lot of advantages. The spectrum of interventions is much broader there. More minimally invasive procedures are being done. A hybrid OR also promotes cooperation between the individual disciplines, e.g., between cardiologists and cardiac surgeons. I think this is extremely important, because it supports innovation. Why shouldn't we take advantage of this potential in thoracic procedures as well? The pathologists can quickly assess a tissue sample. If the biopsy was done in the hybrid OR, the patient can be operated on immediately. I think this is a major advantage.

**What indications warrant the use of the hybrid OR?**

Small, peripheral solitary pulmonary nodules with unclear malignancy need assessment. VATS gets to its edges quickly, because the thoracic surgeons have to do without their sense of touch when operating through the port. Deeper lesions are often only palpable with the fingers; they can't be seen. That's why such solitary pulmonary nodules can be difficult to find in VATS. False negative diagnoses can result if surrounding healthy lung tissue is removed instead of the nodule itself. That's why many physicians resect more tissue than necessary, to be sure that the lesion has in fact been removed. If the lesion turns out to be benign, the patient would have been put through quite a lot – for nothing. Based on experience in Asia and Europe, interventional imaging during VATS makes it possible to accurately see and remove even tiny lesions.

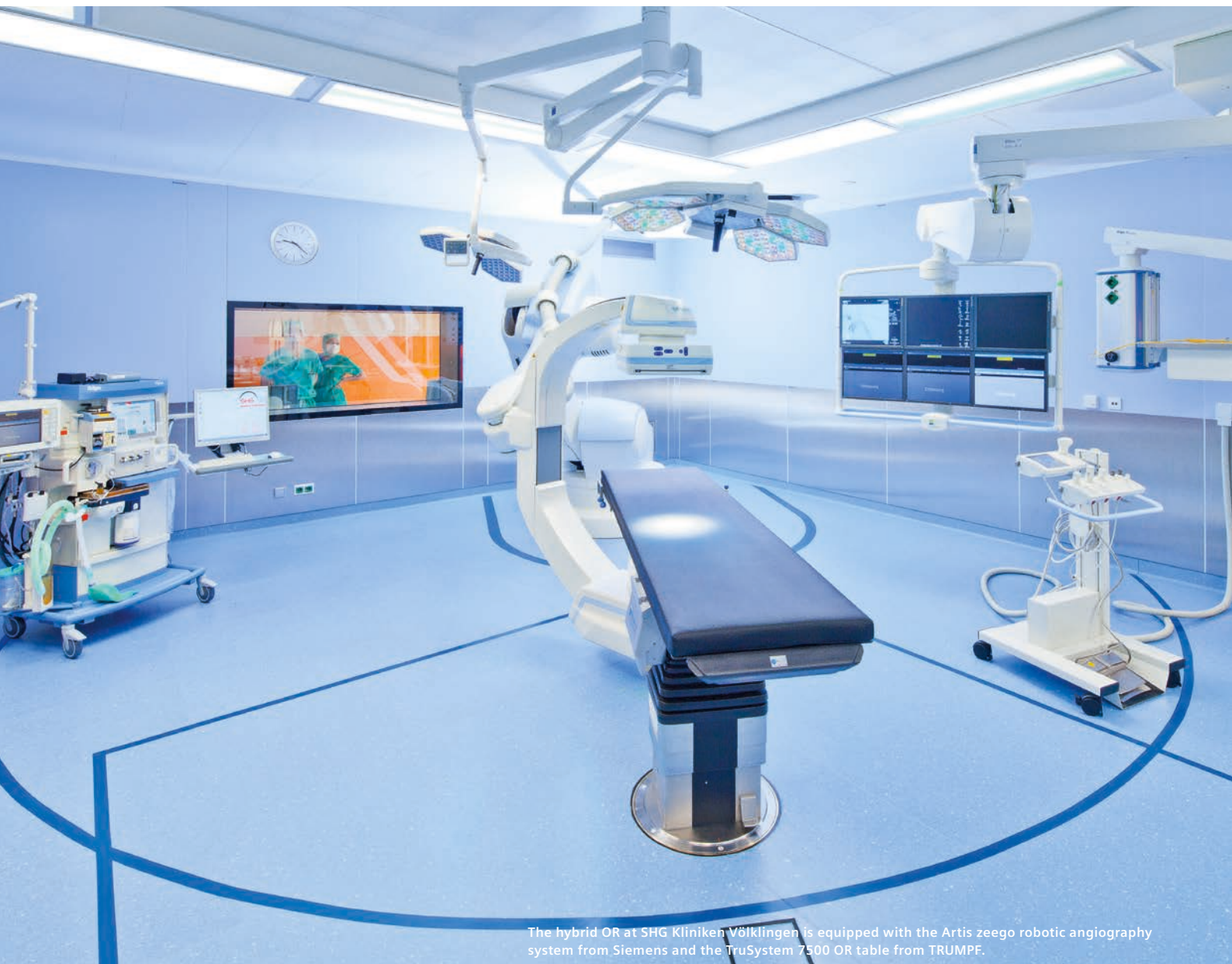**What procedure do you follow?**

With the patient in the hybrid OR, we will first run a syngo DynaCT scan using our Artis zeego angiography system. This lets us generate three-dimensional images similar to CT images. These images then allow us to localize the solitary pulmonary nodule in the 3D dataset. Then we mark the nodule using a needle made of radio-opaque material so that it is visible during VATS under fluoroscopy. After the tissue is removed through the port, we have the pathologists examine it right

away. If it is found to be malignant, we remove the tumor-bearing lobe and the adjacent lymph nodes in the same session. For the time being we'll be using open thoracotomy. Once we have gained more experience, we'll add in the minimally invasive VATS lobectomy.

**But small, solitary peripheral lung nodules make up only 10 percent of lesions that need follow-up examinations. Conventional methods can continue to be used for larger and centrally located solitary nodules. Are we talking about a niche application here?**

No. CT-screening for early detection of lung cancer is a hot topic right now. Several American specialist societies have already published their initial recommendations (see info on page 68). The screening is aimed at discovering tumors while they are still curable. So the need for follow-up examinations is going to be much greater. This requires a less invasive procedure with a high degree of accuracy. VATS with interventional imaging is just such a procedure. But even without screening, our needs are already substantial. Many small, peripheral pulmonary nodules are detected, often by accident, during cardio or thoracic CTs. On top of that, the geographic area we service is quite extensive. We treat patients from all over Saarland, its adjoining states, from Luxemburg, and even France. For us, that's no niche application.



The hybrid OR at SHG Kliniken Völklingen is equipped with the Artis zeego robotic angiography system from Siemens and the TruSystem 7500 OR table from TRUMPF.





Dr. Helmut Isringhaus,  
Head of the Department  
of Cardiothoracic  
Surgery



SHG Kliniken  
in Völklingen,  
Germany

One important aspect of the procedure's success is marking the lesions, because only then are they visible during fluoroscopy and can be removed in their entirety. How do you intend to mark the nodules?

There are two possibilities. Once we have localized the nodule using DynaCT, we can either mark it using micro-coils or with contrast agent. The needle path can be planned using a dedicated software called *syngo* iGuide. In Asia in particular they have gained experience with the contrast agents lipiodol and iopamidol.

#### Where do you see the risks?

We'll only be able to answer that once we have been able to use interventional imaging with VATS much more extensively. In case of doubt, we'll proceed with an open thoracotomy. So we'll only be doing what we normally do anyway. We will simply change over to the current standard. In terms of radiation dose, the DynaCT scan adds approx. 3 to 4 mSv.

#### Helmut Isringhaus, M.D.

Dr. Isringhaus studied medicine at the Universities of Göttingen, Vienna, and Kiel. He is a cardiac and thoracic surgeon. He served in a variety of positions at Saarland University Medical Center in Homburg before he took over as Medical Director of the Clinic for Cardiothoracic Surgery at the SHG Hospital in Völklingen in 1991. That same year he founded the Saar Heart Center (HerzZentrum Saar), where today over 5,000 cardiac catheter examinations and over 1,000 heart operations are performed each year. The founding of the Saar Lung Center (LungenZentrum Saar) followed in 2008, and last year the German Cancer Society certified it as a lung cancer center.

#### Do you think that there will also soon be early detection screening for lung cancer in Germany?

Lung cancer continues to have a high mortality rate, in spite of advances in treatment. The best strategies for lowering mortality are early detection and prevention. I can envision insurers offering integrated benefits contracts for the high risk group of heavy and long-time smokers in future. This type of contract could include the screening,

surgery to remove the tumor, and good after-care. That's another area that still needs attention.

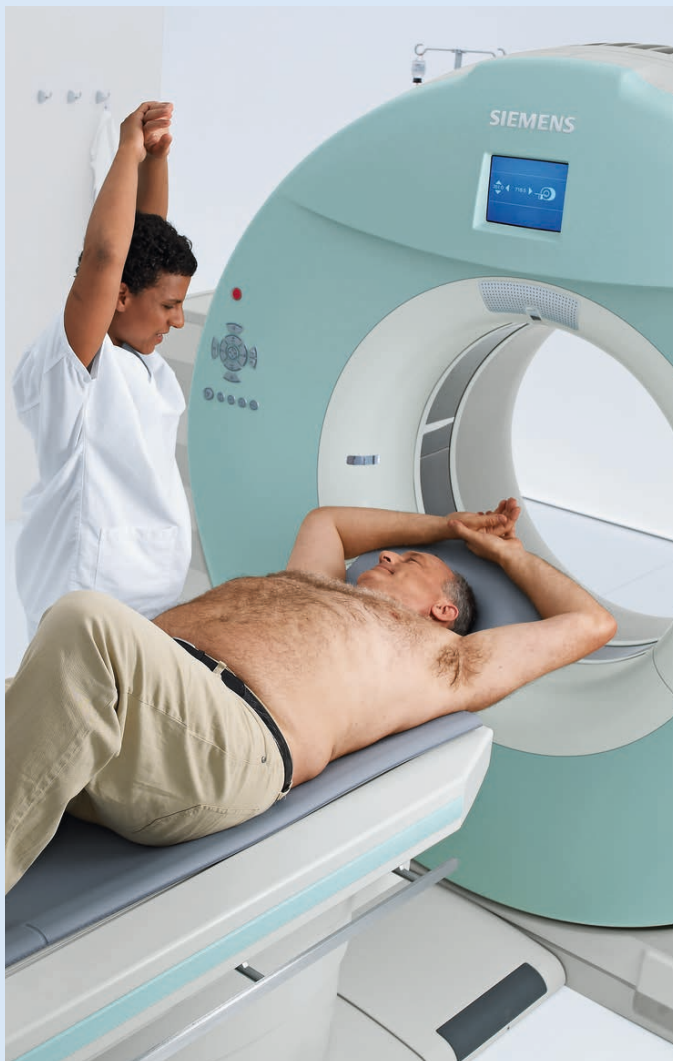*Dr. Hildegard Kaulen is a molecular biologist. After positions at Rockefeller University in New York and Harvard Medical School in Boston, she has worked as a free-lance science journalist since the mid 1990s.*

#### Contact

anne.figel@siemens.com

## Low-Dose CT Screening for Early Detection of Lung Cancer

Several months ago, JAMA (The Journal of the American Medical Association) published recommendations for the early detection of lung cancer using low-dose CT (LDCT) (Vol. 307, pg. 2418). These recommendations are based on the systematic evaluation of the available evidence from four American specialist associations. The study was directed by Prof. Peter Bach, M.D., of the Memorial Sloan Kettering Cancer Center in New York. Prof. Bach and his colleagues included eight randomized controlled trials and thirteen cohort studies. Three of the randomized trials reported information on how LDCT screening influences mortality from lung cancer. The most informative data comes from the National Lung Screening Trial (NLST) with 53,454 participants (NEJM, Vol. 365, pg. 395). In this study, a high-risk



group was screened three years in a row either using LDCT or a conventional X-ray. They were then observed over a 6 1/2 year period.

With the LDCT screening, the relative risk of dying from lung cancer dropped by 20%, and the absolute risk fell by 6.7%. Based on those figures, three deaths can be prevented in every thousand persons screened. The two smaller studies showed no such benefit. In JAMA Prof. Bach and colleagues also quantify the possible harm. Each screening round of 100 participants produced 20 that needed further testing. This number was confirmed in nearly all the studies. In the end, however, only approx. 5% actually had lung cancer. The results of the follow-up studies on the other 19 participants turned out to be benign and were therefore unnecessary. This number varied from study to study. Most of the follow-up examinations were done using a diagnostic CT or PET scan. Much riskier and invasive follow-up procedures were mostly – but not only – done in those who actually had lung cancer. In the NLST study, eight of the 10,000 persons from the LDCT screening group died within the two months after the diagnostic evaluation, and five of the 10,000 from the conventional X-ray group. Of those that were followed up only with a diagnostic PET or CT scan, 1.9 and 1.5 of 10,000 persons died within two months after the screening. An LDCT screening exposes a patient to approx. 1.5 mSv of radiation. Prof. Bach and his colleagues have calculated that each participant in the NLST study was exposed to about 8 mSv of radiation, with possible follow up examinations added in. Probably about one in 2,500 study participants will die of cancer as a result 10 to 20 years later.

### The recommendations from the American College of Chest Physicians and the American Society of Clinical Oncology (quoted from JAMA, Vol 307, Pg. 2427):

**Recommendation 1:** For smokers and former smokers aged 55 to 74 years who have smoked for 30 pack-years or more and either continue to smoke or have quit within the past 15 years, we suggest that annual screening with low dose computed tomography LDCT should be offered over both annual screening with chest radiograph or no screening, but only in settings that can deliver the comprehensive care provided to National Lung Screening Trial (NLST) participants. (Grade of recommendation: 2B)

**Recommendation 2:** For individuals who have accumulated fewer than 30 pack-years of smoking or are either younger than 55 years or older than 74 years, or individuals who quit smoking more than 15 years ago, and for individuals with severe comorbidities that would preclude potentially curative treatment, limit life expectancy, or both, we suggest that CT screening should not be performed. (Grade of recommendation: 2C)

## Interventional Image Guidance in Video-Assisted Thoracoscopic Surgery (VATS) at Saga University Hospital

### Experience from Japan

At Saga University Hospital in Japan, Tohru Sakuragi, M.D., has been accumulating experience for over a year using the Artis zeego for interventional imaging during VATS. In the meantime, over twenty patients have undergone surgery. They had either early stage tumors, ground glass opaque tumors or pulmonary metastatic tumors. Most of the patients were in a supine or decubitus position (fig. 1) throughout the procedure with

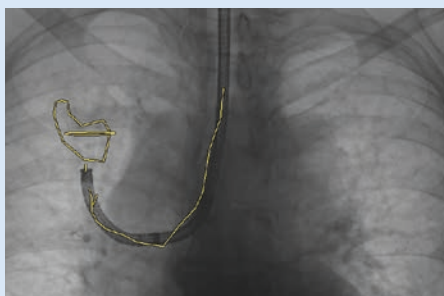
their arms stretched overhead. First the lesions were localized using *syngo* DynaCT (fig. 2). The *syngo* DynaCT volume was also used to plan the optimal port placement, so that the instruments could easily reach the nodule. A dedicated software program, *syngo* iGuide, indicates with a cross-hair laser light attached to the detector the skin entry point for the port as well as the trajectory (fig. 3). In the next step, needles were placed on the lung surface close to the assumed

position of the tumor as identified in the *syngo* DynaCT run (fig. 4). They served as landmarks, clearly visible in fluoroscopy and intra-operative 3D images. Another *syngo* DynaCT run was performed to determine the exact relationship between the needle markers and the tumor (fig. 5). In the last step a minimally invasive excision of the tumor under videoscopic and fluoroscopic control was done (fig. 6).

“This workflow with perioperative *syngo* DynaCT imaging has a lot of clinical benefit and potential for thoracoscopic surgery too. I am sure this procedure will be the general standard once all doctors know about the clinical benefit.”

Tohru Sakuragi, M.D., Department for Thoracic and Cardiovascular Surgery, Saga University Hospital in Japan

## *syngo* DynaCT for Navigating the Bronchial Tree



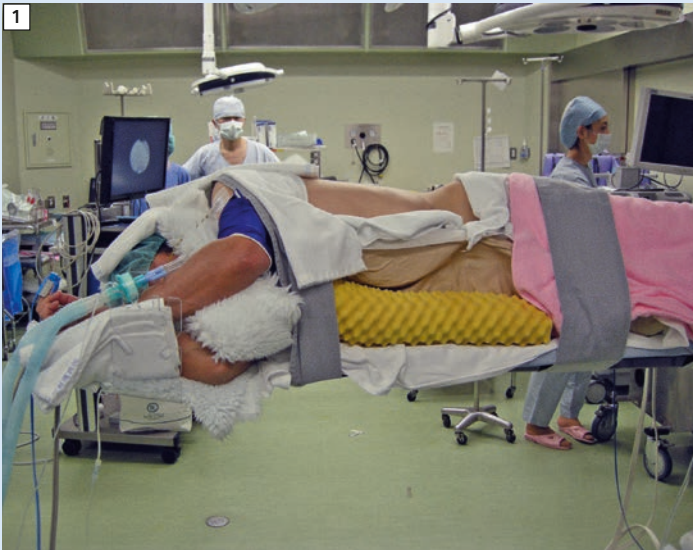
Wolfgang Hohenforst-Schmidt, M.D., of the Coburg Hospital uses the three-dimensional dataset from *syngo* DynaCT to navigate through the bronchial tree. The advantage: The dataset is acquired and the fluoroscopy-assisted bronchos-

copy is performed at the same time, at the same place, and with the diaphragm in the same position. This means that the information out of the 3D dataset matches the anatomy of the lung periphery. Electromagnetic navigation as an alternative method requires a CT scan which is acquired in the radiology department and transferred via a joint computer system to the bronchoscopy lab. Patient transfer to another room, repositioning, plus the respiratory movement of the lungs markedly lowers the accuracy of the tissue excision during biopsy. Dr. Hohenforst-Schmidt has removed bronchial tissue from more

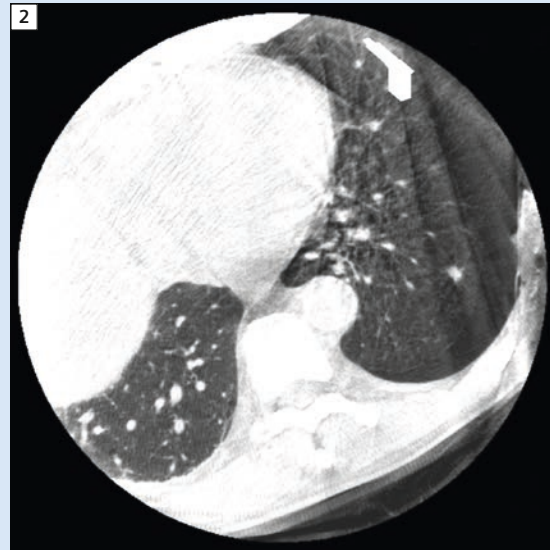
than 70 patients using navigation supported by *syngo* DynaCT. The minimum size of the lesions was 10 mm. The method described above combined with a transthoracic approach (with the help of the *syngo* iGuide software) allows for a success rate of over 90%. Dr. Hohenforst-Schmidt has also shown that small lesions can be dyed to make them easier to see and remove during later surgery.

For more details please see “*syngo* DynaCT – A New Tool for Onsite Navigation in the Lung.” AXIOM Innovations, June 2011, pg. 41; Abstract in Am J Respir Crit Care Med 185;2012:A1111).

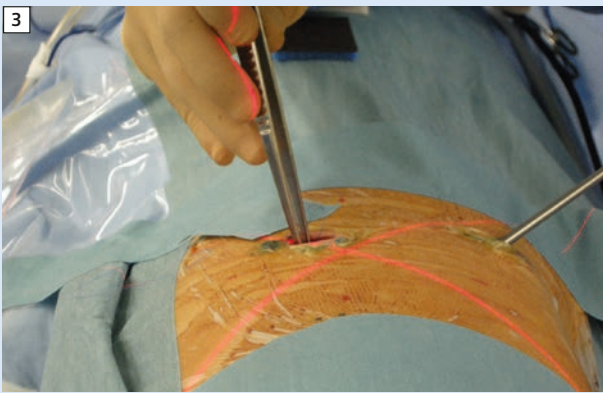




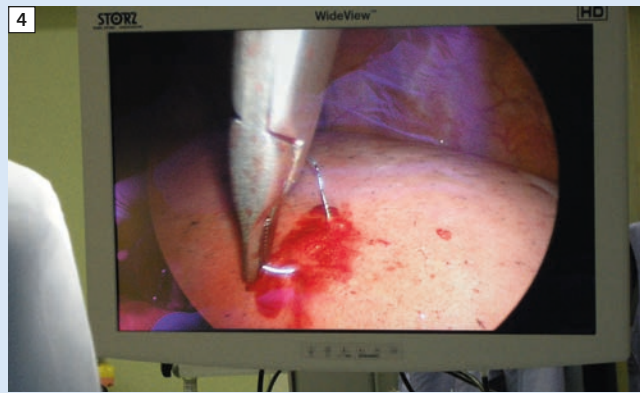**1** Patient preparation in a decubitus position.



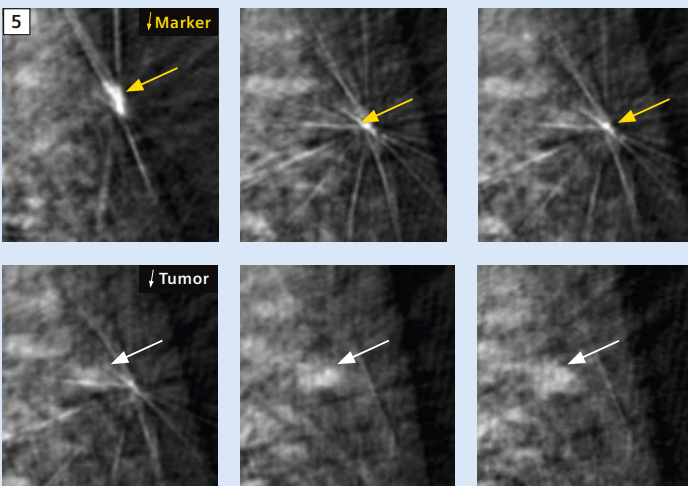
**2** Localization of lesions with *syngo* DynaCT.



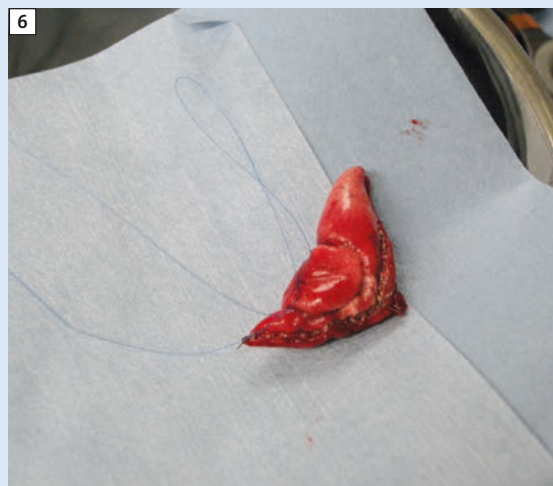**3** Port placement with *syngo* iGuide software.



**4** Needle placement.



**5** Second *syngo* DynaCT for the determination of the relationship between needle markers and tumor.



**6** Excision of tumor under fluoroscopic and videoscopic guidance.

# Going Hybrid for Cardiac Procedures

## Surgical Repair of Post-Myocardial Infarction Ventricular Septal Defect

Courtesy of Purushottam K. Deshpande, M.D., Vikas V. Bisne, M.D., Dilip V. Gupta, M.D., Sandeep D. Khanzode, M.D., Mukund K. Deshpande, M.D., Avantika A. Jaiswal, M.D., and Irshad Ahmed  
K G Deshpande Memorial Hospital, Nagpur, India

Post-MI VSD is a known complication in 0.2% of cases and requires urgent surgical closure. A scarred anterolateral myocardial wall with LV aneurysm is routinely found, making it ineligible for LAD artery area revascularization. In view of acute inflammatory reaction, fibrinous pericarditis leads to difficult access to the target lesions, and issues of competent flow into the target lesions makes treatment very challenging.

Surgical repair of post-myocardial infarction (MI) ventricular septal defect (VSD) has been a challenging procedure. Anterior or apical VSDs are seen in 60% of patients with post MI VSD. Post infarction VSD is generally associated with complete obstruction of the coronary artery, usually the LAD (left anterior descending coronary artery). Severe stenosis may coexist in the right coronary artery.

Since most of these patients are critically ill, management and surgical correction is a challenge. We present a similar case of post MI VSD with LV (left ventricular) aneurysm (fig. 1)

which underwent a hybrid procedure at K G Deshpande Memorial Hospital in Nagpur, India.

The following case is a difficult, high-risk procedure. It shows what is possible in a hybrid operating room from a technical and clinical perspective. It's also an excellent example to show how surgeons and cardiologists can successfully work together to treat the patient effectively in a single procedure.

The unique and innovative platform of Artis zee systems greatly improves the comfort level of cardiothoracic surgeons and cardiologists as well as interventional radiologists through excellent image quality, advanced 3D applications and comfortable park positions.

### Patient history

A 57-year-old male suffered from acute MI with CCF (congestive cardiac failure).

### Diagnosis

Post MI apical VSD with LV aneurysm (fig. 1, arrow) and LVEF of 30%. ECG showed a large anterior wall MI. Chest radiograph showed cardiomegaly with

pulmonary plethora and right pleural effusion. 2D echocardiography showed multiple apical VSD with L R shunts. He had a PA (pulmonary artery) pressure of 60 mm Hg. The coronary angiogram showed a left dominant circulation with LAD proximal 70% discrete lesion.

### Treatment

Patient presented to us at two weeks of MI with above findings. He was medically optimized and taken for a planned hybrid procedure to dominant LCX (left circumflex artery) three weeks after acute MI.

Bilateral femoral artery access was taken for coronary intervention and possible need of intraaortic balloon pump/IABP. Intraoperatively there was pericardial pericardial effusion with large peel over the pericardium as well as the heart, which was dissected from pericardial adhesions.

There was a large LV aneurysm. Patient was put on CPB with ascending and bicaval cannulation and antegrade cardioplastic arrest was achieved and patient cooled to 32 degrees.



I went to China in 2008 for a conference on 'Hybrid approach to cardiac diseases'

To my surprise there were over 200 papers for hybrid management. It was then I

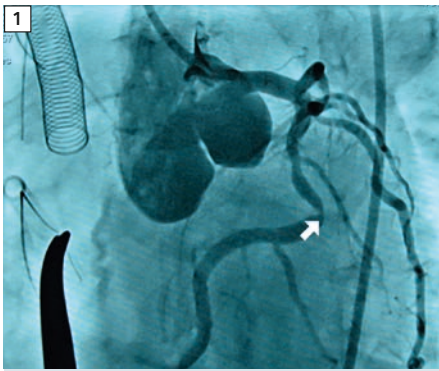
realized that the hybrid OR is the future in cardiac surgery in treating the patient in one sitting, so that the procedures are economical, the intra- and post-operative morbidity is lower, and clinical

outcomes for the patient are improved.

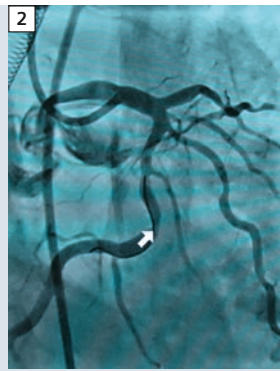There are plenty of medical emergencies in which patient needs to be rushed from the cath lab to the OR, e.g., perforation of RV/RA

in pacemaker implantation. LAD obstructions are best treated by LIMA (left internal mammary artery) to LAD through MIDCAB (minimally invasive direct coronary artery bypass) procedure.

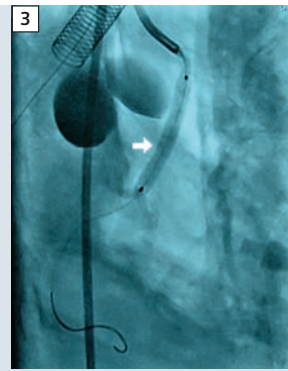




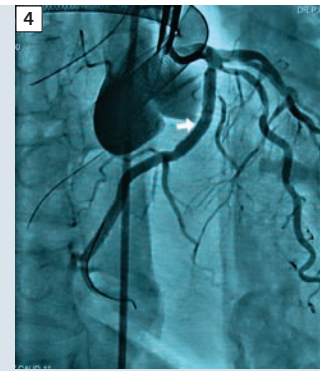
**1** Myocardial infarction associated with obstruction of the coronary artery.



**2** Insertion of the guidewire via right transfemoral approach.



**3** Inflation of the balloon for placing the stent.



**4** Visualization after stenting of the LCX shows good results.

The VSD was closed by double patch technique by biventricular approach using interrupted pledgeted sutures over the teflon felt on LV side. LV aneurysmectomy was performed, right and left ventriculotomy were closed by Batista technique. After deaeration, the aortic cross clamp was removed and the patient could be rewarmed. The cardiologist used

a right transfemoral approach for the PTCA with stenting of the LCX using 3.5 x 24 mm driver stent (Medtronic) with good result (fig. 4).

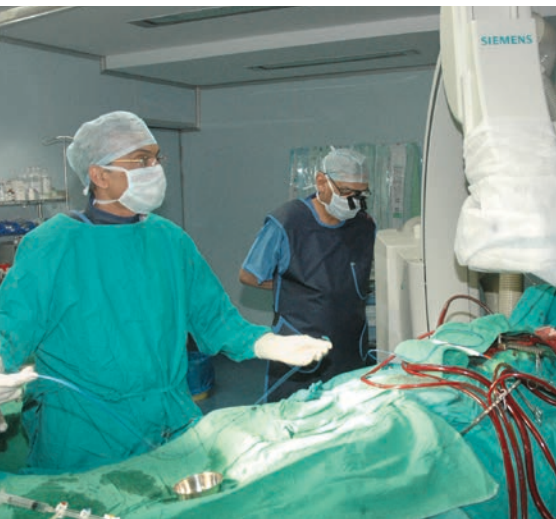The patient was weaned off CPB and on moderate isotropic support without IABP and had an uneventful postoperative course.

Post-operative echo showed a tiny residual VSD on day three and no VSD on day

nine after the surgery. Angiography on day seven showed a fully patent LCX stent and LV angiography did not reveal any residual VSD and the LVEF was 45%.

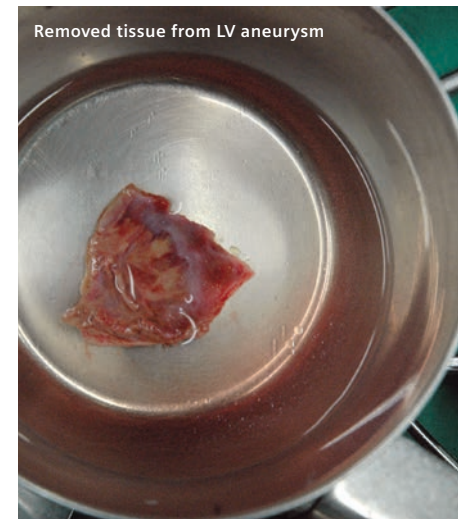
**Contact**

rohan.sonawane@siemens.com



“I see that in the next few years, most of the cardiac ORs will be hybrid ORs.”

Purushottam K Deshpande, M.D.,  
cardiothoracic surgeon, Dr. KG Deshpande Memorial Hospital, Nagpur, India



LCX on the other hand can be treated with angioplasty. These cases can be treated in hybrid OR itself without shifting patient. In children with large collaterals in cyanotic conditions,

collaterals can be blocked, and then corrective procedures can be performed. Septal defects can also be effectively treated in the hybrid OR. AAA/TAA (abdominal aortic

aneurysm / thoracic aortic aneurysm) cases need access of femoral artery for minimally invasive endovascular repair, which are supported by applications like *syngo DynaCT* in the hybrid OR.

**Purushottam K Deshpande, M.D.,**  
cardiothoracic surgeon,  
Dr. K G Deshpande Memorial Hospital,  
Nagpur, India





# Artis zeego – Indispensable Tool for Routine Work

Professor Xin-Wei Han, M.D., and Jiao DeChao, M.D.,  
Zhengzhou University Affiliated Number 1 Hospital, Zhengzhou China

Biggest hospital in the world commonly performs needle procedures with *syngo iGuide* and *Artis zeego*. A recommendation from Professor Xin-Wei Han, M.D., and Jiao DeChao, M.D., Zhengzhou University Affiliated Number 1 Hospital in China describes the workflow for treatment of HCC.

Zhengzhou University Affiliated Number 1 Hospital in China is the largest hospital in the world with 9,380 beds. 208 of those are dedicated

to interventional radiology patients. The *Artis zeego* regularly images ten to twelve patients per day with the majority of them being interventional

oncology cases. The physicians here are excellent *syngo iGuide* users as they use this in combination with *syngo DynaCT* for almost every case.



Professor Han (middle), surrounded by Dr. Hong, Penny Vos from the *Artis zeego* Club team, Su-jin and Su-yu (from left).

“Because we use *iGuide* for every case, we are very familiar with the workflow. It ensures accuracy with complex and simple needle insertion cases. *syngo iGuide* has helped us speed up our interventional oncology cases.”

Jiao DeChao, M.D., Interventional Radiologist,  
Zhengzhou University Affiliated Number 1 Hospital, Zhengzhou, China

## Patient history

Patient presented with lack of appetite and involuntary weight loss. CT revealed liver tumor 3 x 4 x 2.5 cm. Hepatectomy performed July 2012. Post surgical CT revealed liver tumors with metastasis to celiac (retroperitoneal).

## Diagnosis

Hepatocellular carcinoma (HCC).

## Treatment

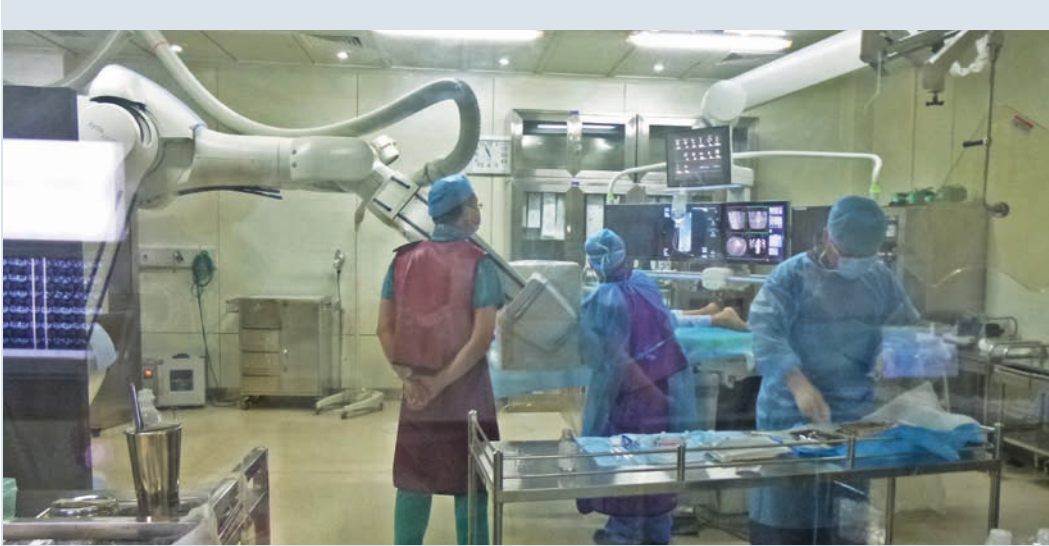Selective internal radiation therapy (SIRT).

## Workflow with *syngo iGuide*

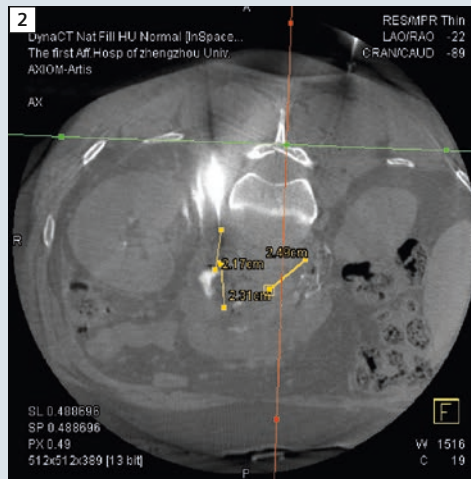
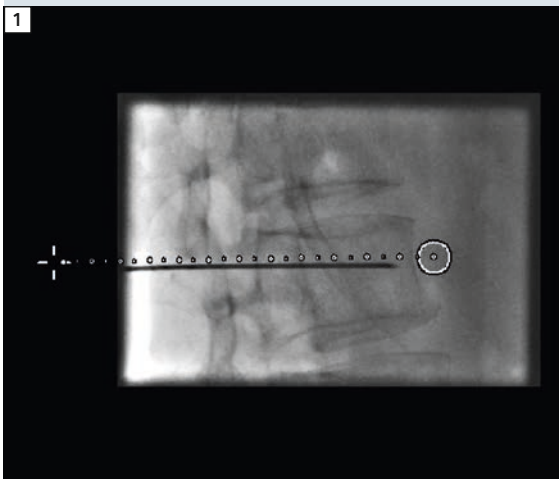
- 1 Perform initial *syngo DynaCT*
- 2 Plan path on 3D dataset using *syngo iGuide*
- 3 Insert needle(s) with the assistance of graphic overlay on fluoro
- 4 Check needle tip position and measure to determine depth of insertion of SIRT beads
- 5 Insert SIRT beads
- 6 Perform a final *syngo DynaCT* to check position of beads

## Contact

penny.vos@siemens.com



Dr. DeChao brings the Artis zeego into a lateral position to insert the needles into the tumors using fluoroscopy and the syngo iGuide graphic overlay for guidance (photo taken from control room).

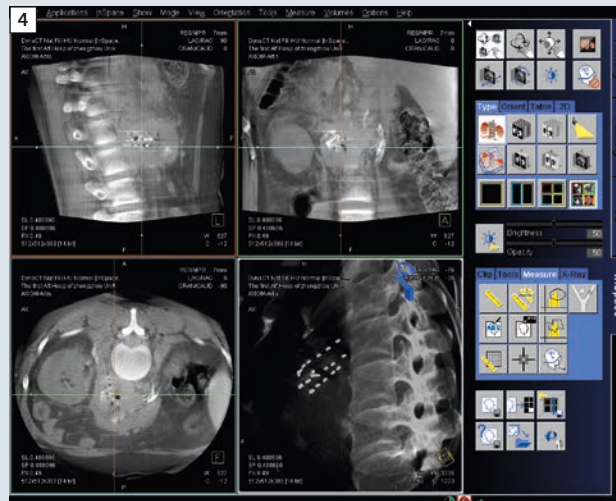
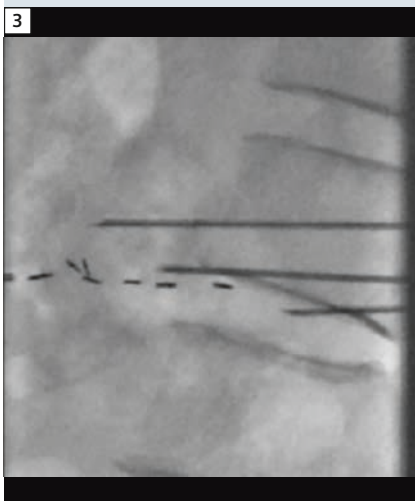


**1** The needle path was planned on the first syngo DynaCT and the needle path graphic overlay is displayed on the live fluoro.

**2** The distance from the needle tip to the target point is measured on the axial view of a second syngo DynaCT.

**3** The SIRT beads are inserted under fluoroscopy.

**4** A third syngo DynaCT to evaluate the final position of the SIRT beads.





# Continual Learning Experience Through Innovation



This group of interventional cardiologists took part in the latest hands-on training offered in collaboration between the National University Heart Centre in Singapore, and Siemens.



The Introductory Course in Interventional Cardiology has been conducted since 2006. This was a Siemens initiative to collaborate with the National University Heart Centre, Singapore and is open to both local and international participants. To date, more than 200 participants have benefited from these courses, which not only provide lectures but also hands-on training with vascular models, making the training more realistic and fun.

### **CATHI Simulation system**

enabled the participants to apply usage of different angiographic views, like catheter, guidewire, balloon and stent selection.

### **Terumo Simulator**

allowed participants to have a feel of doing intervention via trans-radial approach.

### **CoroSim Pulsatile Simulation**

was situated in the cath lab and gave participants the feel of the atmosphere of the fully equipped Siemens biplane angiography unit and practice a technique for coronary intervention on a pulsating heart.

Further information  
[axiom.educate.healthcare@siemens.com](mailto:axiom.educate.healthcare@siemens.com)

The National University Hospital (NUH) is one of the main teaching hospitals in Singapore. It has three cardiac catheterization labs, fully equipped with Siemens Artis systems. A hybrid OR with an Artis zeego was recently installed in December 2011. Since 2006, Siemens has collaborated with NUH to run the "Introductory Course in Interventional Cardiology," within the scope of the AXIOM Educate program and Continuing Medical Education (CME) points were accredited upon completion of the course. To date more than 200 participants from the region as well as abroad, have benefited from this course. This year there were 24 participants, including Leonardo Pinto De Carvalho, M.D., from Brazil and currently a research fellow at the National University Hospital, Singapore. This course not only attracts interventional cardiologists, but also interventional radiologists, interventional neurologists and device vendors who took the opportunity to learn more about cardiac interventions.

Prof. Tan Huey Cheem, M.D., senior consultant cardiologist, and his team from the National University Heart Centre Singapore (NUHCS) have been spearheading this course for the past six

years. The success of each course drives the team to deliver a similar if not better, program year after year. The course covers a wide range of useful lectures like angiographic projections, correct selection of guidewires, catheters, balloons and stents, vascular access and after-care, coronary anomalies as well as case studies. Participants took this opportunity to share their experiences and best practices adopted in their workplace. Based on feedback from the previous course, this year a product specialist from Volcano Corp. was invited to present a topic on basic intravascular ultrasound (IVUS).

Lectures on coronary quantification and strategies to reduce radiation dose exposure were conducted by the Siemens applications team. Participants enjoyed hands-on sessions in small groups guided by the team of experienced cardiologists from NUH. The feedback from all the participants was excellent, with many trainees benefiting greatly from this know-how.

### **Contact**

[xinquan.chen@siemens.com](mailto:xinquan.chen@siemens.com)  
[vera.juennemann@siemens.com](mailto:vera.juennemann@siemens.com)

# Upcoming Congresses 2013

We always would like to give you the opportunity to get in “touch” with the real system and learn more about system handling to keep you in step with

the latest technological advances. You will have the chance to experience our technology at international congresses, trade fairs, and workshops. In the list

below you will find information on various events where we offer you the opportunity to meet AX.

Title	Location	Short Description	Date	Contact
Boston AF	Boston, USA	Annual International Boston Atrial Fibrillation Symposium	Jan 17 - 19	<a href="http://www.afsymposium.com">www.afsymposium.com</a>
LINC Leipzig	Leipzig	Live Course, The Leipzig Interventional Course	Jan 23 - 26	<a href="http://www.leipzig-interventional-course.de">www.leipzig-interventional-course.de</a>
AsiaPCR/SingLIVE	Singapore	International Symposium	Jan 24 - 26	<a href="http://www.asiapcr.com">www.asiapcr.com</a>
STS	Los Angeles, USA	Annual Meeting, The Society of Thoracic Surgeons	Jan 26 - 30	<a href="http://www.sts.org/education-meetings/sts-annual-meeting">www.sts.org/education-meetings/sts-annual-meeting</a>
Arab Health	Dubai, UAE	Healthcare Exhibition & Congress	Jan 28 - 31	<a href="http://www.arabhealthonline.com">www.arabhealthonline.com</a>
DGHTG	Freiburg, Germany	Annual Conference, German Society for Thoracic and Cardiovascular Surgery	Feb 17 - 20	<a href="http://www.dgthg.de">www.dgthg.de</a>
IOIS	St. Louis, USA	Intraoperative Imaging Society	Feb 24 - 27	<a href="http://www.intraopimaging.org">www.intraopimaging.org</a>
ECR	Vienna, Austria	Annual Meeting, European Society of Radiology	Mar 7 - 11	<a href="http://www.myesr.org">www.myesr.org</a>
ACC	San Francisco, USA	Annual Scientific Session & Expo, American College of Cardiology	Mar 9 - 11	<a href="http://www.acc.org">www.acc.org</a>
EVC	Maastricht, Netherlands	European Vascular Course	Mar 10 - 12	<a href="http://www.vascular-course.com/european-vascular-course">www.vascular-course.com/european-vascular-course</a>
EAU	Milan, Italy	Annual Congress, European Association of Urology	Mar 15 - 19	<a href="http://www.eaumilan2013.org">www.eaumilan2013.org</a>
AAOS	Chicago, USA	American Academy of Orthopedic Surgeons	Mar 19 - 23	<a href="http://www.aaos.org/education/anmeet/anmeet.asp">www.aaos.org/education/anmeet/anmeet.asp</a>
CIT	Beijing, China	China Interventional Therapeutics Conference	Mar 20 - 23	<a href="http://www.citmd.com">www.citmd.com</a>
China Med	Beijing, China	International Medical Instruments & Equipment Exhibition	Mar 28 - 30	<a href="http://www.eventseye.com/fairs/f-china-med-3391-1.html">http://www.eventseye.com/fairs/f-china-med-3391-1.html</a>
DGK	Mannheim, Germany	Annual Conference, Deutsche Gesellschaft für Kardiologie -Herz- und Kreislaufforschung e.V.	Apr 3 - 6	<a href="http://www.dgk.org">www.dgk.org</a>
Spine	Hong Kong	Global Spine Congress	Apr 4 - 6	<a href="http://www.globalspinecongress.org">www.globalspinecongress.org</a>
ASCVTS	Kobe, Japan	Annual Meeting, Asian Society for Cardiovascular and Thoracic Surgery	Apr 4 - 7	<a href="http://www.ascvts2013.com">www.ascvts2013.com</a>
Charing Cross	London, UK	Vascular & Endovascular Consensus Update	Apr 6 - 9	<a href="http://www.cxsymposium.com">www.cxsymposium.com</a>
SIR	New Orleans, USA	Annual Scientific Meeting, Society of Interventional Radiology	Apr 13 - 18	<a href="http://www.sirmeeting.org">www.sirmeeting.org</a>

Title	Location	Short Description	Date	Contact
AANS	New Orleans, USA	Annual Meeting, American Association of Neurological Surgeons	Apr 27 - May 1	<a href="http://www.aans.org">www.aans.org</a>
CMEF	Shenzhen, China	China International Medical Equipment Fair	Apr 16 - 20	<a href="http://en.cmef.com.cn">http://en.cmef.com.cn</a>
TCTAP	Seoul, South Korea	Angioplasty Summit, Transcatheter Cardiovascular Therapeutics Asia Pacific	Apr 23 - 26	<a href="http://www.summit-tctap.com">www.summit-tctap.com</a>
GEST	Prague, Czech Republic	Global Embolization Symposium and Technologies	May 1 - 4	<a href="http://www.gestweb.org">www.gestweb.org</a>
AATS	Minneapolis, USA	Annual Meeting, American Association for Thoracic Surgery	May 4 - 5	<a href="http://www.aats.org">www.aats.org</a>
HRS	Denver, USA	Annual Scientific Sessions, Heart Rhythm Society	May 8 - 11	<a href="http://www.hrsonline.org">www.hrsonline.org</a>
WCIO	New York, USA	World Conference on Interventional Oncology	May 16 - 19	<a href="http://wcio2012.com">http://wcio2012.com</a>
EuroPCR	Paris, France	Cardiovascular Course	May 21 - 24	<a href="http://www.europcr.com">www.europcr.com</a>
AEPC	London, UK	Annual Meeting, Association for European Paediatric and Congenital Cardiology	May 22 - 25	<a href="http://www.aepc-2013.org">www.aepc-2013.org</a>
ESTS	Birmingham, UK	European Conference, European Society of Thoracic Surgeons	May 26 - 29	<a href="http://www.estsmeetings.org/2013">www.estsmeetings.org/2013</a>
European Stroke	London, UK	European Stroke Conference	May 28 - 31	<a href="http://www.eurostroke.eu/">www.eurostroke.eu/</a>
ACINR	Istanbul, Turkey	Anatolian Course of Interventional Neuroradiology	May 29 - 31	<a href="http://www.acinr2012.org">www.acinr2012.org</a>
Deutscher Röntgenkongress	Hamburg, Germany	Congress, Deutsche Röntgengesellschaft	May 29 - June 1	<a href="http://www.roentgenkongress.de">www.roentgenkongress.de</a>
SVS	San Francisco, USA	Vascular Annual Meeting, Society for Vascular Surgery	May 30 - June 1	<a href="http://www.vascularweb.org">www.vascularweb.org</a>
UKRC	Liverpool, UK	UK Radiological Congress	Jun 10 - 12	<a href="http://www.ukrc.org.uk">www.ukrc.org.uk</a>
ECIO	Budapest, Hungary	Conference on Interventional Oncology (Organized by CIRSE)	Jun 19 - 22	<a href="http://www.ecio.org/">www.ecio.org/</a>
EHRA Europace	Athens, Greece	European Society of Cardiology	Jun 23 - 26	<a href="http://www.escardio.org/congresses/ehra-europace-2013">www.escardio.org/congresses/ehra-europace-2013</a>

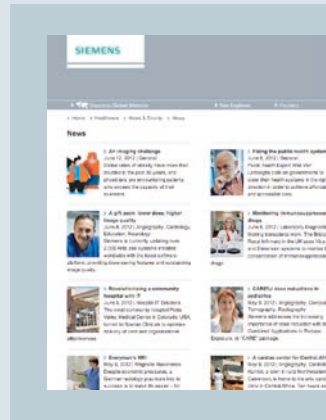


# Siemens Healthcare Publications

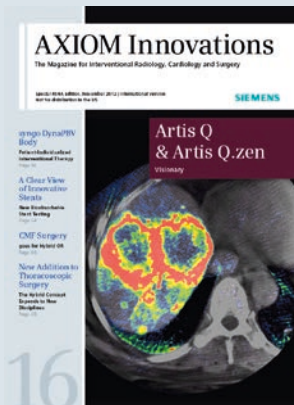Our customer magazine family offers the latest information and background for every healthcare field. From the hospital director to the radiological assistant – here, you can quickly find information relevant to your needs.



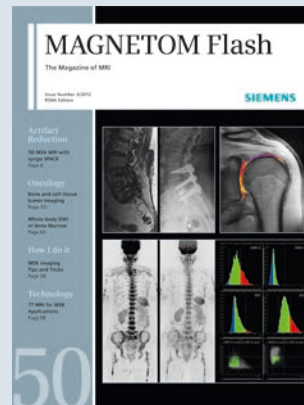**Medical Solutions**  
 Innovation and trends in healthcare. The magazine, published three times a year, is designed especially for members of hospital management, administration personnel, and heads of medical departments.



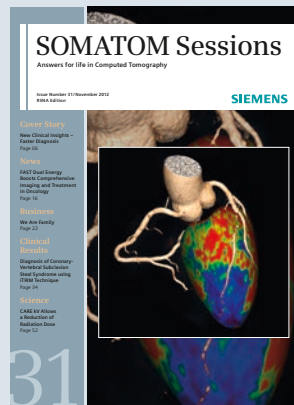**eNews**  
 Our latest topics such as product news, reference stories, reports, and general interest topics are always available at: [www.siemens.com/healthcare-news](http://www.siemens.com/healthcare-news)



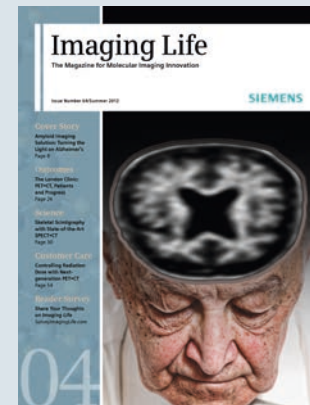**AXIOM Innovations**  
 Everything from the world of interventional radiology, interventional cardiology, and surgery. This semi-annual magazine is primarily designed for physicians, physicists, researchers, and technical personnel.



**MAGNETOM Flash**  
 Everything from the world of magnetic resonance imaging. The magazine presents case reports, technology, product news, and how-tos. It is primarily designed for physicians, physicists, and technical personnel.



**SOMATOM Sessions**  
 Everything from the world of computed tomography. With its innovations, clinical applications, and vision, this semiannual magazine is primarily designed for physicians, physicists, researchers, and technical personnel.



**Imaging Life**  
 Everything from the world of molecular imaging innovations. This bi-annual magazine presents clinical case reports, customer experiences, and product news, and is primarily designed for physicians, hospital management and researchers.

For current and past issues and to order the magazines, please visit [www.siemens.com/healthcare-magazine](http://www.siemens.com/healthcare-magazine).

# AXIOM Innovations

© 2012 by Siemens AG, Berlin and Munich, All Rights Reserved

## Publisher

Siemens AG  
Medical Solutions  
Angiography & Interventional  
X-Ray Systems  
Siemensstr. 1,  
91301 Forchheim, Germany

## Responsible for contents

Heinrich Kolem, Ph.D.

## Chief editor

Nadine Meru, Ph.D.  
nadine.meru@siemens.com

## Co-editor

Sabine Wich  
sabine.wich@siemens.com

## Editorial board

Anne Figel, Vera Jünnemann, Dirk  
Sunderbrink, Thomas Hartkens, Ina  
Schwablenland, Hanno Herrmann, Mariana  
Aquino, Janina Beilner, Simone Henrichs,  
Kerstin Raber, Yiannis Kyriakou, Martin  
von Roden, Ryan Forth, Rohan Sonawane,  
Xinquan Chen, Dietrich Till

Alexandre Abizaid, M.D.,  
Dante Pazzanese Cardiology Institute,  
São Paulo, Brazil

Alexander Bock, M.D.,  
Department of Clinical and  
Interventional Neuroradiology  
Andreas Jödicke, M.D.,  
Department of Neurosurgery, Vivantes  
Klinikum Neukölln, Berlin, Germany.

Purushottam K. Deshpande, M.D.,  
Cardiothoracic Surgery Department,  
Dr. K G Deshpande Memorial Hospital,  
Nagpur, India.

Johannes Gahlen, M.D.,  
Wilko Staiger, M.D., Ludwigsburg Hospital,  
Ludwigsburg, Germany

Note in accordance with § 33 Para. 1 of the  
Federal Data Protection Law: Dispatch is made  
using an address file which is maintained with  
the aid of an automated data processing sys-  
tem. We remind our readers that, when printed,  
X-ray films never disclose all the information  
content of the original. Artifacts in X-ray, CT,  
MR and ultrasound images are recognizable  
by their typical features and are generally

Thomas Gaspar, M.D.,  
Department of Electrophysiology  
and Rhythmology, Heart Center of Leipzig  
University, Leipzig, Germany

Jianping Gu, M.D.  
Wensheng Lou, M.D.,  
Department of Interventional Radiology,  
Nanjing. No.1 Hospital, China

Xin-Wei Han, M.D.,  
DeChao, M.D.,  
Zhengzhou University Affiliated Number 1  
Hospital, Zhengzhou, China.

Helmut Isringhaus, M.D.,  
Clinic for Cardiothoracic Surgery,  
SHG Hospital, Völklingen, Germany

Tobias F. Jakobs, M.D.,  
Department of Diagnostic and Interventional  
Radiology, Barmherzige Brüder Hospital,  
Munich, Germany

Xu Jianrong, M.D.,  
Department of Radiology,  
Renji Hospital, China

Lieven Maene, M.D.,  
Aalst Hospital, Aalst, Belgium

Nishita Kothary, M.D.,  
Department of Radiology,  
Stanford University School of Medicine,  
Stanford, CA, USA

Beat Müller, M.D.  
Department of Visceral and Oncologic Surgery,  
University Hospital of Heidelberg,  
Heidelberg, Germany

Jianmin Liu, M.D.,  
Department of Neurosurgery, Shanghai  
Changhai Hospital, Shanghai, China

Philippe L. Pereira, M.D., PhD, EIBIR,  
Kristina Krüger, Department of Radiology,  
Minimally Invasive Therapies and Nuclear  
Medicine, SLK-Kliniken GmbH, Heilbronn,  
Germany

distinguishable from existing pathology. As  
referenced above, healthcare practitioners are  
expected to utilize their own learning, training  
and expertise in evaluating images.  
Partial reproduction in printed form of indi-  
vidual contributions is permitted, provided  
the customary bibliographical data such as  
author's name and title of the contribution as  
well as date and pages of "AXIOM Innovations"

Bora Peynircioğlu, M.D.,  
Department of Radiology, Hacettepe University  
Hospital, Ankara, Turkey

Evelyn Regar, M.D.,  
Thorax Center, Department of Cardiology,  
Erasmus Medical Center, Rotterdam,  
Rotterdam, The Netherlands

Peter Ashley Robless, M.D.,  
Department of Cardiac, Thoracic  
and Vascular Surgery, National University  
Hospital, Singapore, Singapore

Tohru Sakuragi, M.D.,  
Department for Cardiothoracic Surgery,  
Saga University Hospital, Japan

Alexander Schramm, M.D., D.M.D.,  
Department of Cranio-Maxillary-Facial Surgery,  
Army Hospital Ulm, Ulm, Germany.

PD Tobias Struffert, M.D.  
Department of Neuroradiology, University of  
Erlangen, Erlangen, Germany

Thomas Vogl, M.D.,  
Department of Diagnostic and Interventional  
Radiology, University of Frankfurt, Germany

## Production

Michael Brumme, Siemens Healthcare,  
Erlangen, Germany

## Layout and editorial staff

Satzwerker – Jäger & Tuppi  
Karlsruhe, Germany

## Printer

G. Peschke, Druckerei GmbH  
Schatzbogen 35  
81829 München

AXIOM Innovations on the net:  
[www.siemens.com/healthcare-magazine](http://www.siemens.com/healthcare-magazine)

are cited. The editors request that two copies  
be sent to their attention. The consent of the  
authors and editors is required for the complete  
reprint of an article. Manuscripts submitted  
without prior agreement as well as suggestions,  
proposals and information are always welcome;  
they will be carefully assessed and submitted to  
the editorial board for review.

**Global Siemens Headquarters**

Siemens AG  
Wittelsbacherplatz 2  
80333 Muenchen  
Germany

**Global Siemens**

**Healthcare Headquarters**  
Siemens AG  
Healthcare Sector  
Henkestr. 127  
91052 Erlangen  
Germany  
Phone: +49 9131 84-0  
[www.siemens.com/healthcare](http://www.siemens.com/healthcare)

**Legal Manufacturer**

Siemens AG  
Wittelsbacherplatz 2  
DE-80333 Muenchen  
Germany

[www.siemens.com/healthcare-magazine](http://www.siemens.com/healthcare-magazine)

Order No. A91AX-81101-17C1-7600 | Printed in Germany | CC AX 847 121220. | © 12.2012, Siemens AG

On account of certain regional limitations of sales rights and service availability, we cannot guarantee that all products included in this brochure are available through the Siemens sales organization worldwide. Availability and packaging may vary by country and are subject to change without prior notice. Some / All of the features and products described herein may not be available in the United States or other countries.

The information in this document contains general technical descriptions of specifications and options as well as standard and optional features that do not always have to be present in individual cases.

Siemens reserves the right to modify the design, packaging, specifications and options described herein without prior notice. Please contact your local Siemens sales representative for the most current information.

In the interest of complying with legal requirements concerning the environmental compatibility of our products (protection of natural resources and waste conservation), we recycle certain components. Using the same extensive quality assurance measures as for factory-new components, we guarantee the quality of these recycled components.

Note: Any technical data contained in this document may vary within defined tolerances. Original images always lose a certain amount of detail when reproduced.

For product accessories see:

**[www.siemens.com/medical-accessories](http://www.siemens.com/medical-accessories)**

The statement by Siemens' customers described herein are based on results that were achieved in the customer's unique setting. Since there is no "typical" hospital and many variables exist (e.g., hospital size, case mix, level of IT adoption) there can be no guarantee that other customers will achieve the same results.

**Global Business Unit Address**

Siemens AG, Medical Solutions  
Angiography & Interventional X-Ray Systems  
Siemensstr. 1  
DE-91301 Forchheim  
Germany  
Phone: +49 9191 18-0  
[www.siemens.com/healthcare](http://www.siemens.com/healthcare)

**Local Contact Information****Asia/Pacific:**

Siemens Medical Solutions  
Asia Pacific Headquarters  
The Siemens Center  
60 MacPherson Road  
Singapore 348615  
Phone: +65 9622-2026  
[www.siemens.com/healthcare](http://www.siemens.com/healthcare)

**Canada:**

Siemens Canada Limited  
Medical Solutions  
2185 Derry Road West  
Mississauga ON L5N 7A6  
Canada  
Phone: +1 905 819-5800  
[www.siemens.com/healthcare](http://www.siemens.com/healthcare)

**Europe/Africa/Middle East:**

Siemens AG, Medical Solutions  
Henkestr. 127,  
DE-91052 Erlangen  
Germany  
Phone: +49 9131 84-0  
[www.siemens.com/healthcare](http://www.siemens.com/healthcare)

**Latin America:**

Siemens S.A., Medical Solutions  
Avenida de Pte. Julio A. Roca No 516, Piso 7  
C1067ABN Buenos Aires  
Argentina  
Phone: +54 11 4340 8400  
[www.siemens.com/healthcare](http://www.siemens.com/healthcare)

**USA:**

Siemens Medical Solutions U.S.A., Inc.  
51 Valley Stream Parkway  
Malvern, PA 19355-1406  
USA  
Phone: +1-888-826-9702  
[www.siemens.com/healthcare](http://www.siemens.com/healthcare)