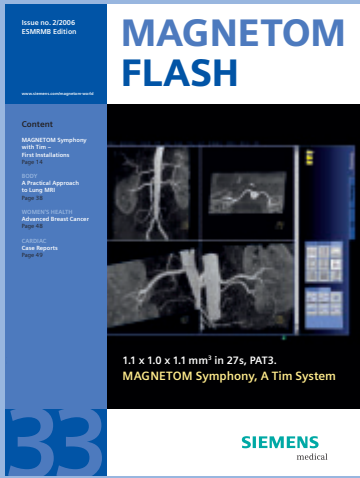



SUBSCRIBE NOW!

– and get your free copy of future MAGNETOM Flash! Interesting information from the world of magnetic resonance – gratis to your desk. Send us this postcard, or subscribe online at www.siemens.com/MAGNETOM-World

Siemens AG
Medical Solutions
Magnetic Resonance
Marketing
P.O. Box 3260

D-91050 Erlangen
Germany

Please print clearly!

Institution	_____
Title	_____
Name*	_____
Street/P.O. Box*	_____
Zip/Postal Code*	_____
City*	_____
State/Province*	_____
Country*	_____
E-mail	_____

☐ Yes, I consent to the above information being used for future contact regarding product updates and other important news from Siemens MR.

The information in this document contains general descriptions of the technical options available, which do not always have to be present in individual cases.

The required features should therefore be specified in each individual case at the time of closing the contract.

Siemens reserves the right to modify the design and specifications contained herein without prior notice. Please contact your local Siemens sales representative for the most current information.

Original images always lose a certain amount of detail when reproduced.

This brochure refers to both standard and optional features. Availability and packaging of options varies by country and is subject to change without notice. Some of the features described are not available for commercial distribution in the US.

Siemens AG
Wittelsbacherplatz 2
D-80333 Muenchen
Germany

Headquarters
Siemens AG, Medical Solutions
Henkestr. 127, D-91052 Erlangen
Germany
Telephone: +49 9131 84-0
www.siemens.com/medical

Contact Addresses

In the USA
Siemens Medical Solutions USA, Inc.
51 Valley Stream Parkway
Malvern, PA 19355
Telephone: +1 888-826-9702
Telephone: +1 610-448-4500
Telefax: +1 610-448-2254

In Japan
Siemens-Asahi
Medical Technologies Ltd.
Takanawa Park Tower 14F
20-14, Higashi-Gotanda 3-chome
Shinagawa-ku
Tokyo 141-8644
Telephone: +81 3 5423 8411

In Asia
Siemens Medical Solutions
Asia Pacific Headquarters
The Siemens Center
60 MacPherson Road
Singapore 348615
Telephone: +65 6490-6000
Telefax: +65 6490-6001

In Germany
Siemens AG, Medical Solutions
Magnetic Resonance
Henkestr. 127, D-91052 Erlangen
Germany
Telephone: +49 9131 84-0

Siemens **Medical Solutions** that help

© 10.2006, Siemens AG
Order No. A91MR-1000-11A-7600
Printed in Germany
CC MR 66214 WS 100620.

SIEMENS

MAGNETOM FLASH

Issue no. 2/2006

Issue no. 2/2006
ESMRMB Edition

www.siemens.com/magnetom-world

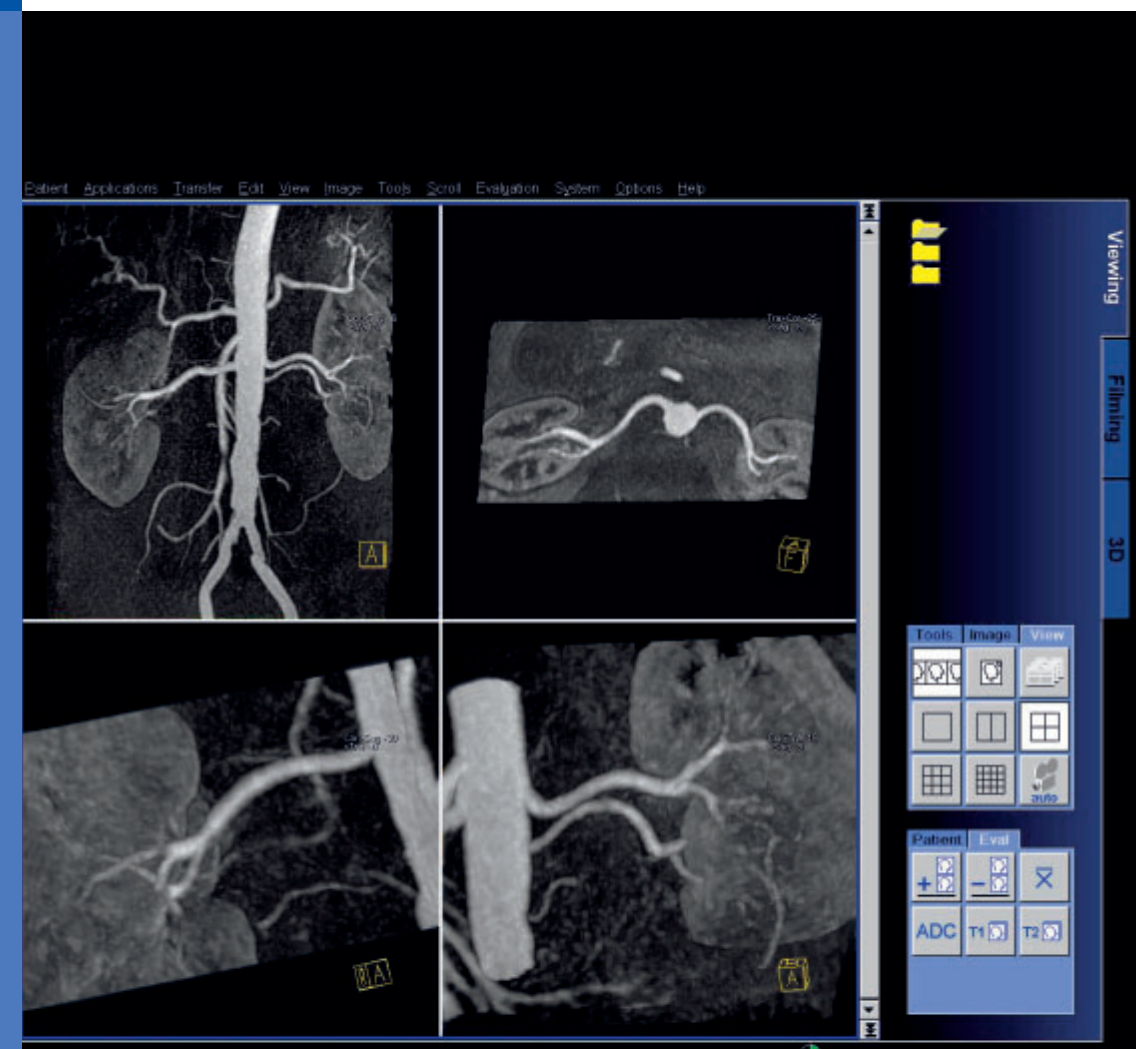Content

MAGNETOM Symphony with Tim – First Installations
Page 14

BODY A Practical Approach to Lung MRI
Page 38

WOMEN'S HEALTH Advanced Breast Cancer
Page 48

CARDIAC Case Reports
Page 49



1.1 x 1.0 x 1.1 mm³ in 27s, PAT3.
MAGNETOM Symphony, A Tim System

SIEMENS
medical

Dear MAGNETOM User,

"Although Tim stands for Total imaging matrix, after experiencing the **MAGNETOM Symphony with Tim** myself I have decided that Tim stands for Total improvement." Dr. Johan Dehem from VZW Regionaal Ziekenhuis Jan Yperman, Belgium is excited about his upgrade to Tim Technology.

From head to toe, from routine imaging to advanced applications, from gradient system to RF coils, MAGNETOM Symphony with Tim feels like a totally new system. Adding Tim and top applications such as GRAPPA, SWI (susceptibility-weighted imaging) and REVEAL (diffusion-weighted imaging) MAGNETOM users are able to see more and work faster with their systems.

When thinking about an upgrade the main concerns most likely are:

- Total cost compared to a new system
- New technologies that come with the upgrade
- Clinical advantages of the upgrade
- Total downtime to install the upgrade
- Throughput after the upgrade

This issue of MAGNETOM Flash magazine addresses these topics. We show examples with different business models and different needs from the more than 70 Tim upgrade installations worldwide in less than 1 year. Let us take you to France, Belgium, Australia, and the US for a glimpse into the routine work with **MAGNETOM Symphony, A Tim System**.

Enjoy this MAGNETOM Flash and the advantages of the Tim Upgrade,



Gustavo Ribeiro

MAGNETOM Flash is part of Life, Siemens' unique customer care solution that helps you get the most from your investment. With its programs and services Life sharpens your skills so you can see optimal clinical value. It provides the support you need to maximize productivity and it assures that as technology changes, you will always be at the cutting edge.



2nd Annual Clinical 3T MRI 2007

Wynn LAS VEGAS
Las Vegas, Nevada
January 26 - 27, 2007

13.25 AMA PRA Category 1 Credits™



Educational Symposia
5620 West Sligh Ave.
Tampa, FL 33634-4490

Issue no. 2/2006
ESMRMB Edition

www.siemens.com/magnetom-world

Content

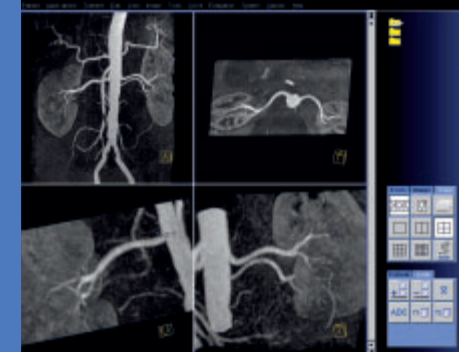
MAGNETOM Symphony
with Tim –
First Installations
Page 14

BODY
A Practical Approach
to Lung MRI
Page 36

WOMEN'S HEALTH
Advanced Breast Cancer
Page 48

CARDIAC
Case Reports
Page 49

MAGNETOM FLASH



1.1 x 1.0 x 1.1 mm³ in 27s, PAT3.
MAGNETOM Symphony, A Tim System



SIEMENS
medical

MAGNETOM FLASH offers product news, clinical methods, application tips, MR technology and information on Life.

The Editorial Team

We appreciate your comments.

Please contact us at magnetomworld.med@siemens.com



*Lisa Reid,
US Installed Base Manager,
Malvern, PA, USA*



*Dagmar Thomsik-Schröpfer, Ph.D.
MR Marketing-Products, Erlangen*



*Antje Hellwich
Associate Editor*



*A. Nejat Bengi, M.D.
Editor in Chief*



*Heike Weh,
Clinical Data Manager,
Erlangen*



*Bernhard Baden,
Clinical Data Manager,
Erlangen*



*Tony Enright, Ph.D.
Asia Pacific Collaborations,
Australia*



*Milind Dhamankar, M.D.
Manager Clinical MR
Research Collaborations, USA*



*Peter Kreisler, Ph.D.
Collaborations & Applications,
Erlangen*



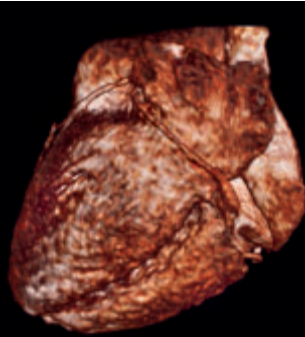
*Gary R. McNeal, MS (BME)
Advanced Application Specialist,
Cardiovascular MR Imaging
Siemens Medical Solutions USA*



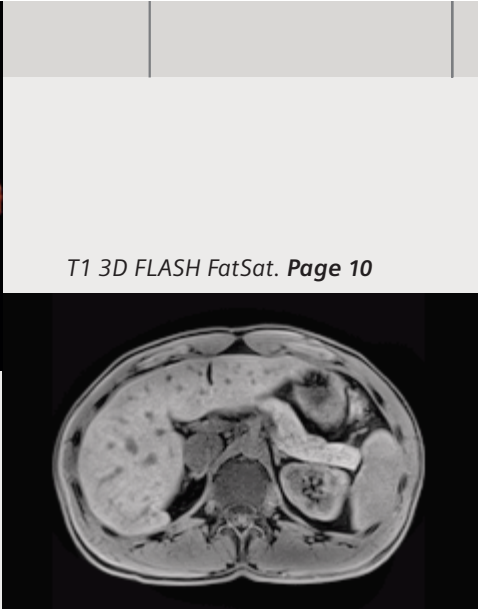
*Cécile Mohr, Ph.D
Head of Market Segment
Management, Erlangen*



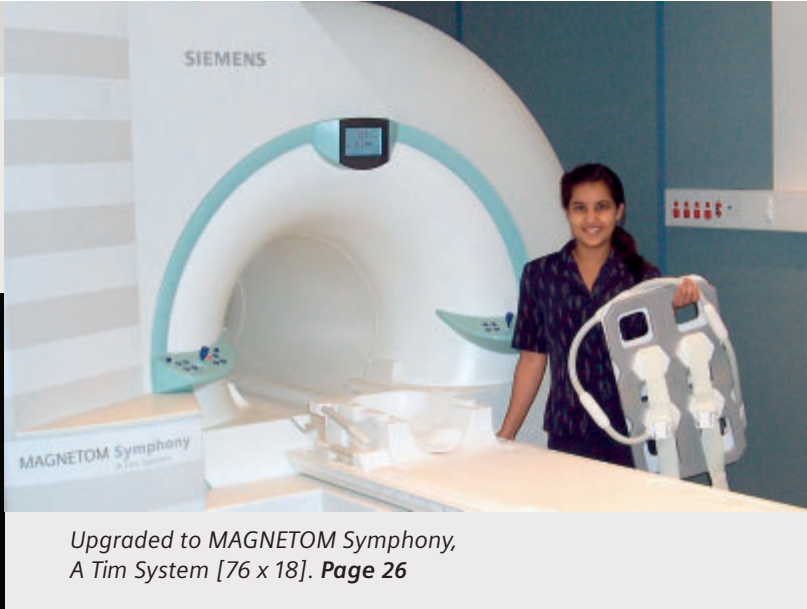*Dr. Sunil Kumar S.L. Manager
Applications MRI, Siemens
Medical Solutions, India*



3D TrueFISP segmented FatSat. **Page 9**



T1 3D FLASH FatSat. **Page 10**



Upgraded to MAGNETOM Symphony, A Tim System [76 x 18]. **Page 26**

- 6 PRODUCT NEWS**
MAGNETOM Symphony, A Tim System

IMAGE GALLERY

- 8 MAGNETOM SYMPHONY, A Tim SYSTEM**

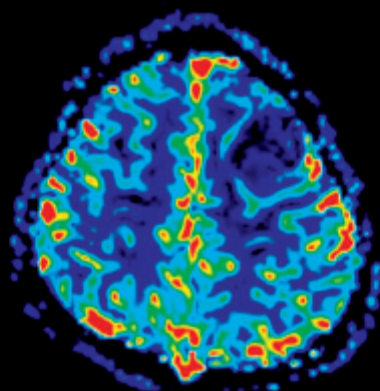
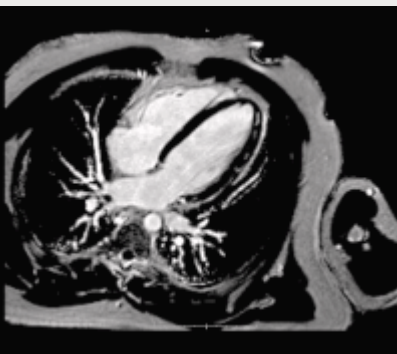
TECHNOLOGY

- 14 Tim UPGRADES**
First Experiences with Tim Upgrades in France
- 18 Tim UPGRADES**
Image Quality Improvements after MAGNETOM Symphony Tim Upgrade
- 26 Tim UPGRADES**
MAGNETOM Symphony Maestro Class Upgraded to MAGNETOM Symphony, A Tim System [76 x 18]
- 28 Tim UPGRADES**
MAGNETOM Symphony Maestro Class Upgraded to MAGNETOM Symphony, A Tim System [76 / 18]
- 31 Tim UPGRADES**
Tim Trio Upgrade Benefits

CLINICAL

- 34 BODY**
Dynamic Contrast Enhanced MRI
- 38 BODY**
A Practical Approach to Lung MRI at 1.5T
- 44 WOMEN'S HEALTH**
MAGNETOM Avanto, Advanced Breast Cancer
- 47 WOMEN'S HEALTH**
Soft Tissue Motion Correction for MR Mammography (BRACE)
- 49 CARDIAC**
Case 1: Acute Myocardial Infarction
- 50 CARDIAC**
Case 2: Myocarditis
- 51 CARDIAC**
Case 3: Apical Thrombus

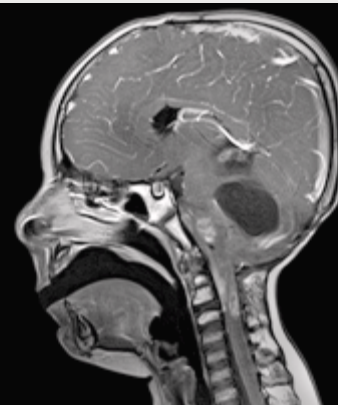
Tissue characterization
4-chamber view. **Page 61**



Dynamic Contrast Enhanced MRI. **Page 35**

CONTENT

MAGNETOM Symphony T1 SE sagittal,
post contrast. **Page 74**



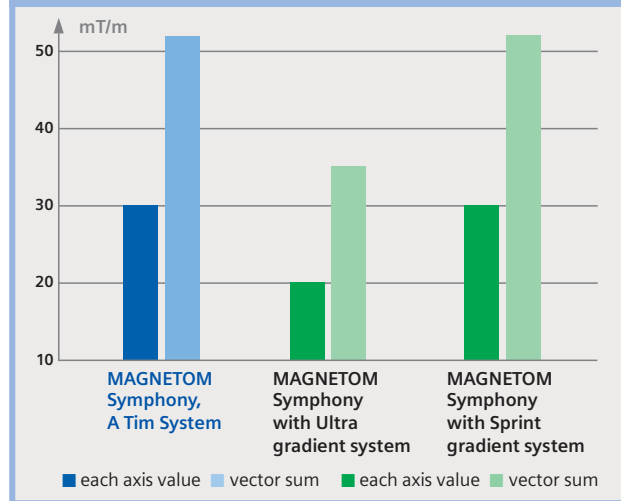
52	CARDIAC Case 4: Aortic Stenosis
53	CARDIAC Case 5: Osteosarcoma Metastases
54	CARDIAC Case 6: Acute Infarction
56	CARDIAC Case Report MAGNETOM Espree: Whole-body MRA
58	CARDIAC Case Report MAGNETOM Avanto: Aorta Coarctation
60	CARDIAC Case Report MAGNETOM Avanto: Myocarditis
62	CARDIAC Case Report MAGNETOM Sonata: Hypertrophic Cardiomyopathy
64	CARDIAC Case Report MAGNETOM Sonata: Artery Occlusion
66	Special offer Cardiovascular
SAFETY	
68	NEW TERMINOLOGY MRI: New Terminology for Implants and Devices
70	CORONARY STENTS MR Safety at 3 Tesla: Bare Metal and Drug Eluting Coronary Stents
LIFE	
72	PEDIATRIC MEETING 2 nd MAGNETOM World Pediatric User Meeting, February 17–19, 2006
76	IMPRINT

The information presented in MAGNETOM Flash is for illustration only and is not intended to be relied upon by the reader for instruction as to the practice of medicine. Any health care practitioner reading this information is reminded that they must use their own learning, training and expertise in dealing with their individual patients. This material does not substitute for that duty and is not intended by Siemens Medical Solutions to be used for any purpose in that regard. The drugs and doses mentioned in MAGNETOM Flash are consistent with the approval labeling for uses and/or indications of the drug. The treating physician bears the sole responsibility for the diagnosis and treatment of patients, including drugs and doses prescribed in connection with such use. The Operating Instructions must always be strictly followed when operating the MR System. The source for the technical data is the corresponding data sheets.

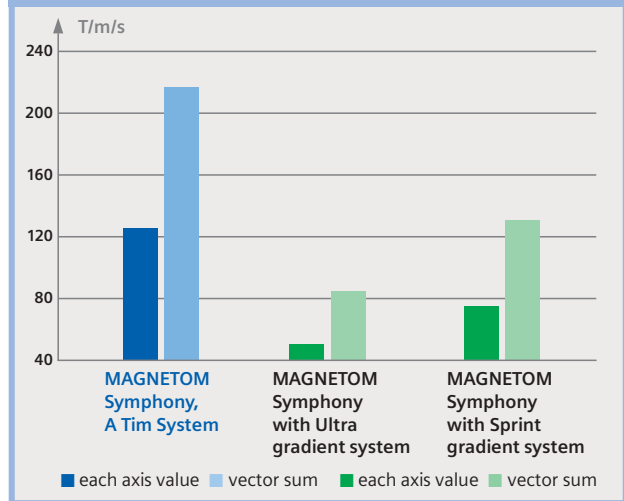
MAGNETOM Symphony, A Tim System

The upgrade from MAGNETOM Symphony to Tim will bring remarkable clinical advantages to your routine MR applications. The technical comparison shows the improvements ranging from coil technology to gradients and parallel imaging techniques.

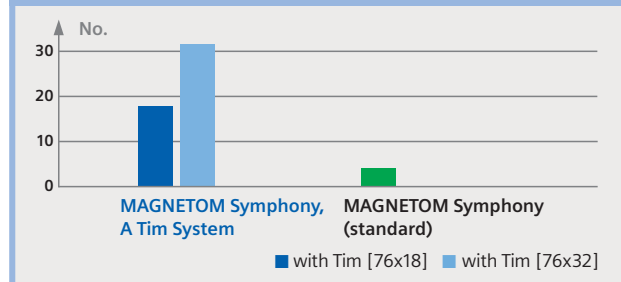
Gradient Strength



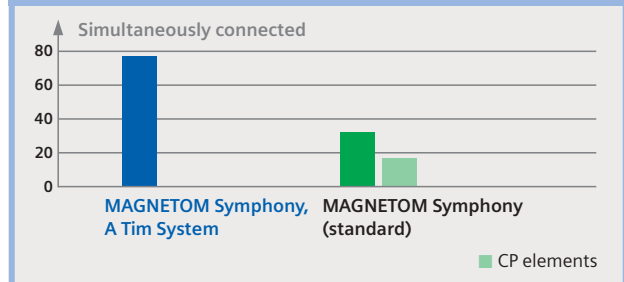
Slew Rate



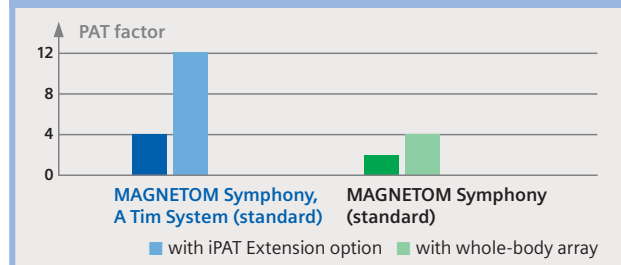
Independent Digital RF Channels



Coil Elements



Max. PAT Factor



New Integrated CP Body Coil

- No-tune transmit / receive coil
- Circularly polarized (CP)
- Optimized RF efficiency and signal-to-noise ratio (SNR)

MAGNETOM Symphony, A Tim System: Tim Matrix coils

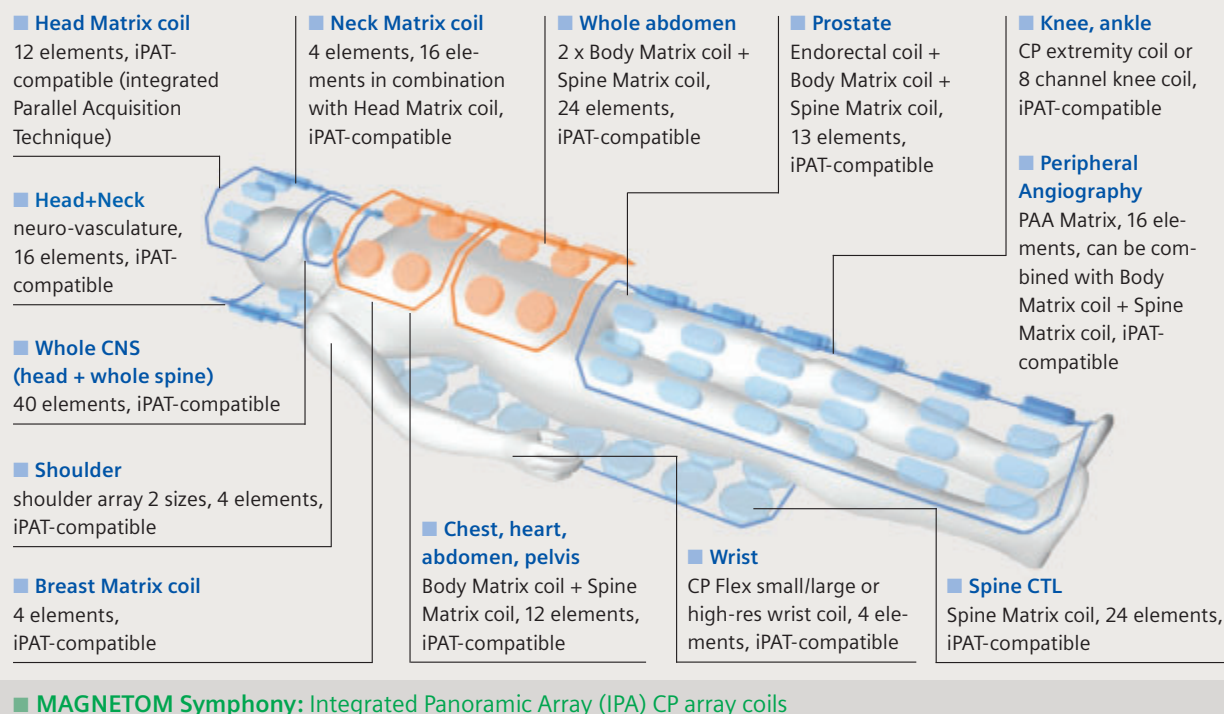


Image Processor

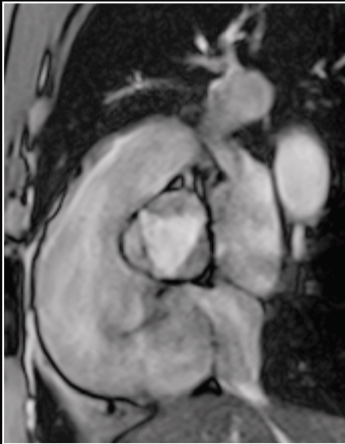	MAGNETOM Symphony, A Tim System	MAGNETOM Symphony
Processor	AMD Opteron 2 CPUs, 2.6 GHz; 8 GB RAM	Pentium 4 Xeon 1 GB RAM; 2 GB RAM (with whole-body array option)
Reconstruction speed	1002 recons/sec for 256 x 256 matrix	355 recons/sec for 256 x 256 matrix
Reconstruction speed with RecFoV	8694 recons/sec for 256 x 256 matrix with 25% RecFoV	3226 recons/sec for 256 x 256 matrix with 25% RecFoV
Parallel scan and reconstruction	possible with up to 12 data sets	possible with up to 4 data sets in parallel

Applications

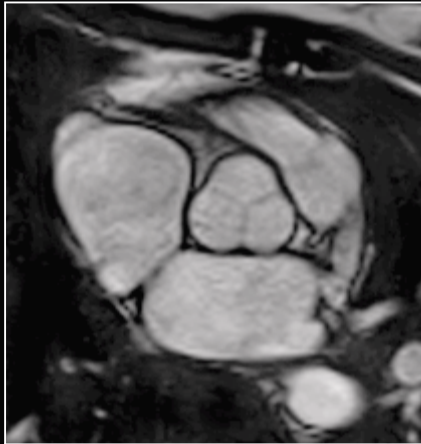
MAGNETOM Symphony, A Tim System

- All advanced applications including diffusion tensor imaging with up to 256 diffusion directions
- prostate and breast 3D spectroscopy
- mSENSE and GRAPPA
- up to 200 cm whole-body scan
- real-time 3D BOLD imaging
- Coronary Artery Imaging, SWI, REVEAL, SPACE, BEAT, BLADE
- ✚ All future applications developed for Tim systems

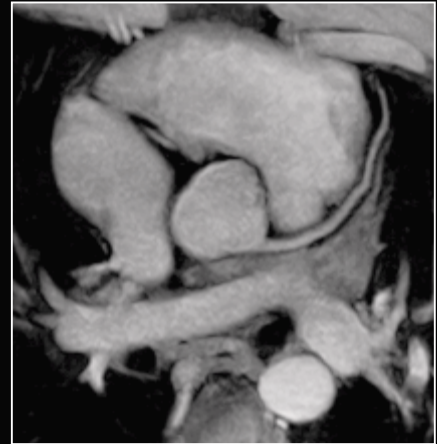Cardiac



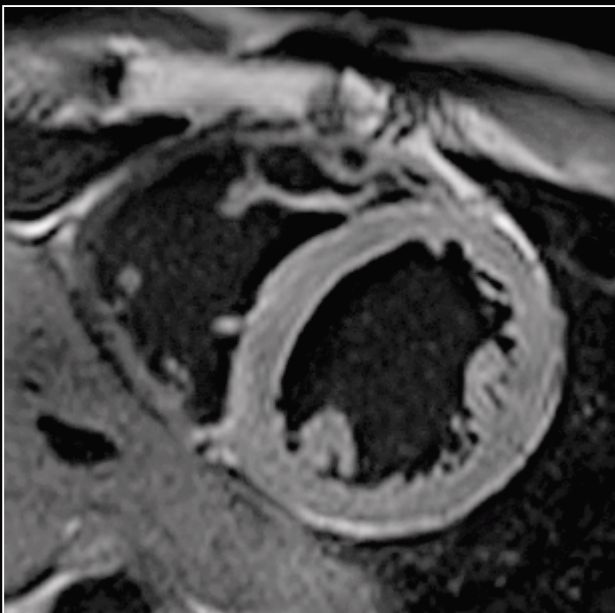
[Aortic Valve 01] T1 FLASH
cine retro / TR/TE 52.2/2.4
TA 45s / SL 5 mm / slices 25
FoV 320 mm / matrix 384



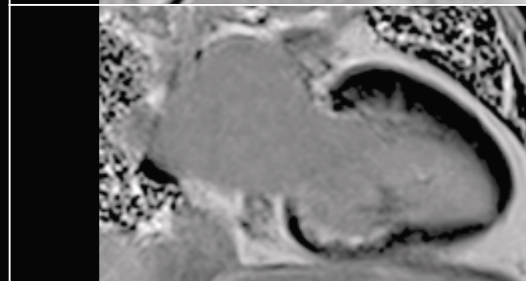
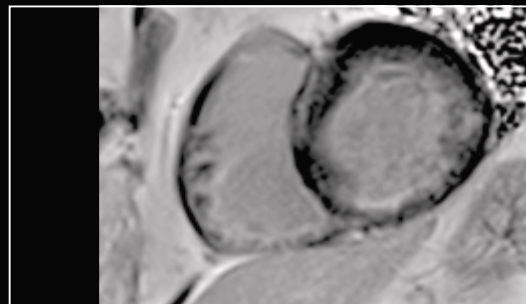
[Aortic Valve 02] TrueFISP cine
retro, GRAPPA 2 / TR/E 42.4/1.4
TA 8 s / SL 6 mm / slices 20
FoV 280 mm / matrix 192



[Coronary] T1 3D FLASH
FatSat / TR/TE 233.2/2.5 / TA 3:31min
eff. SL 1.5 mm / partitions 18
FoV 340 mm / matrix 768



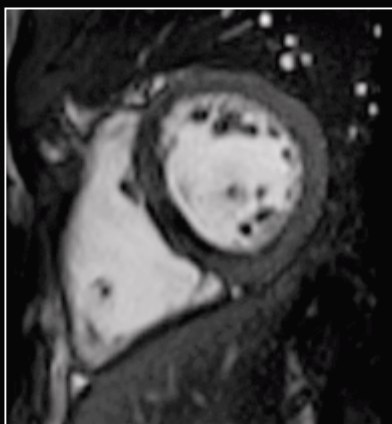
[DarkBlood] T2 TSE FatSat Dark Blood
TR/TE 1542.5/66 / TA 7.83 s / SL 5 mm / slice 1
FoV 200 mm / matrix 256



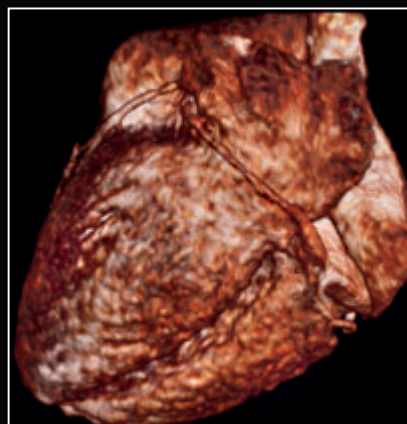
[Late Enhancement] FLASH IR OS recon image
post contrast TR/TE 700/3.5 / TI 310, TA 16 s / SL 8 mm
slice 1 / FoV 370 mm / matrix 256
Courtesy of Klinikum St. Marien, Amberg, Germany



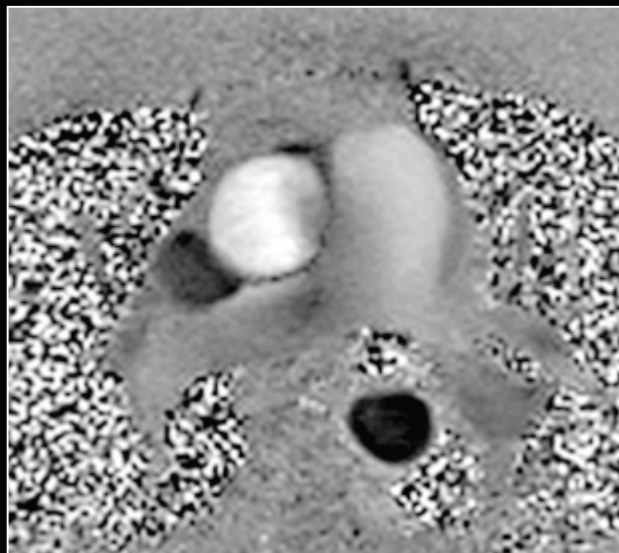
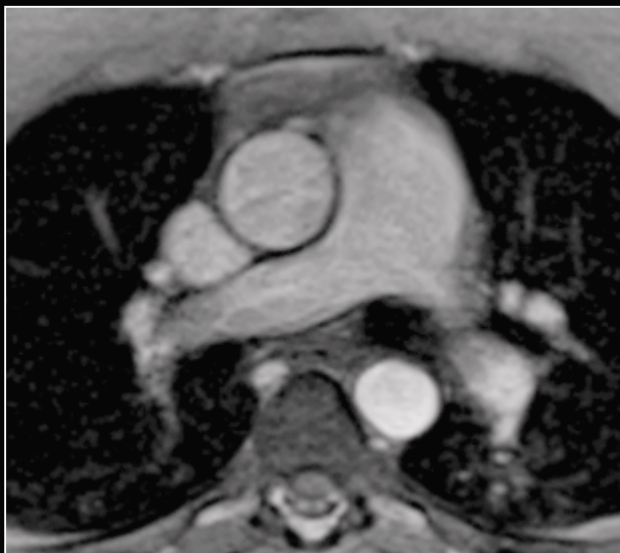[Grid] T1 FLASH cine
TR/TE 42.7/4.2 / TA 13.6 s
SL 6 mm / slices 15 / FoV 350 mm
matrix 256



**[Radial] TrueFISP cine retro
radial, GRAPPA 2** / TR/TE 39.6/1.3
TA 6.62 s / SL 6 mm / slices 25
FoV 340 mm / matrix 192

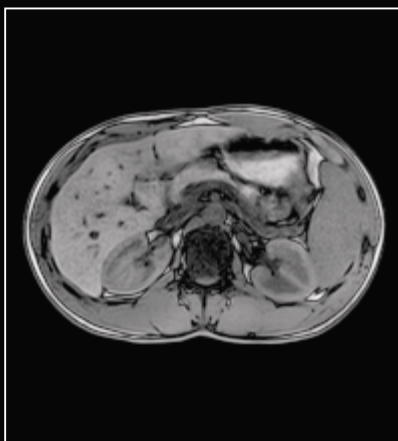


**[WholeHeart] 3D TrueFISP
segmented FatSat, GRAPPA 2**
TR/TE 260/1.6 / TA 15:02 min
eff. SL 1 mm / partitions 120
FoV 260 mm / matrix 256

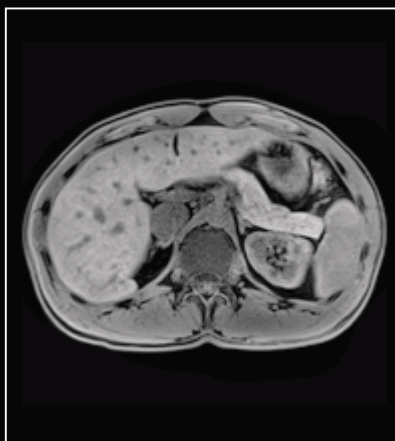


[Flow 01 + Flow 02] T1 FLASH cine retro
TR/TE 46/3.8 / TA 3:18 min / SL 5 mm / slices 30 / FoV 320 mm / matrix 256

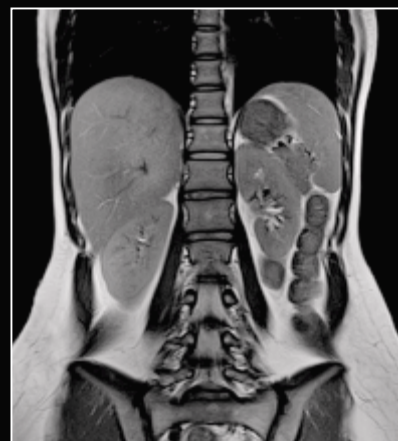Abdomen and Pelvis



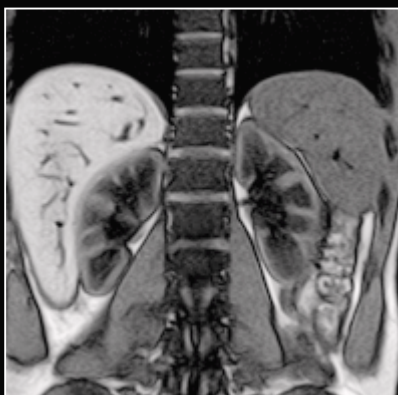[Abdomen FLASH outphase]
T1 FLASH out of phase,
GRAPPA 2 / TR/TE 100/2.4
TA 26.7 s / SL 6 mm / slices 2 x 20
(in and out of phase)
FoV 350 mm



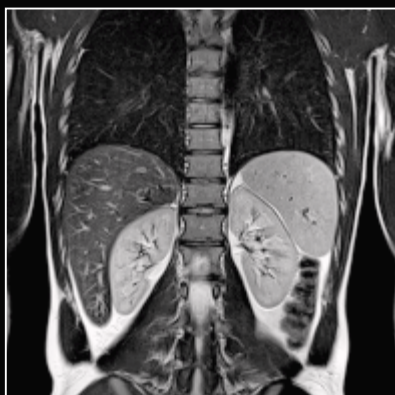
[Liver VIBE] T1 3D FLASH
FatSat, GRAPPA 2
TR/TE 5.8/2.8 / TA 22.5 s
eff. SL 2.5 mm / partitions 60
FoV 350 mm / matrix 256



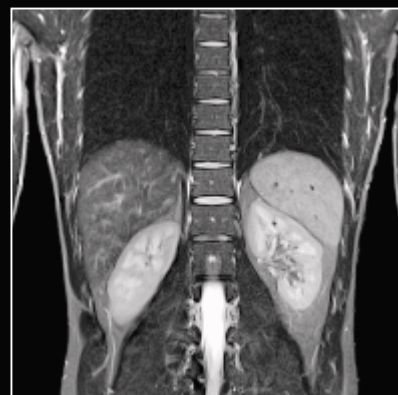
[T1 cor] T1 TSE, GRAPPA 2
TR/TE 3505.1/6.6 / TA 1:34 min
SL 6 mm / slices 9 / FoV 380 mm
matrix 320



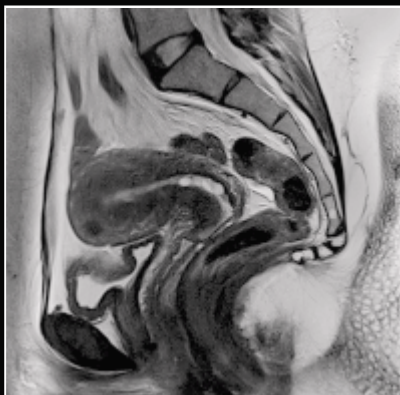[Cor T1] T1 TurboFLASH, n
GRAPPA 2 / TR/TE 59487.5/3
TI 900 / TA 1:14 min / SL 7 mm
slices 20 / FoV 400 mm
matrix 512



[Abdomen T2 cor] T2 TSE,
GRAPPA 2 / TR/TE 4288/59
TA 1:40 min / SL 6 mm / slices 25
FoV 450 mm / matrix 384

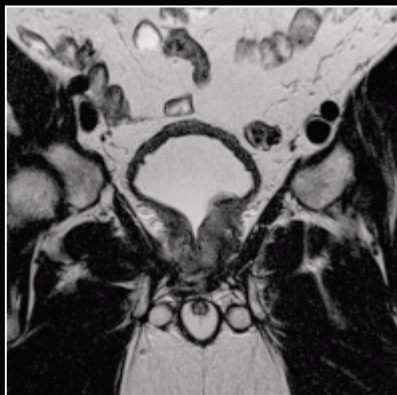

[Abdomen TIRM] T2 TIRM,
GRAPPA 2 / TR/TE 9000/91
TI 130 / TA 4:40 min / SL 5 mm
slices 25 / FoV 480 mm
matrix 448

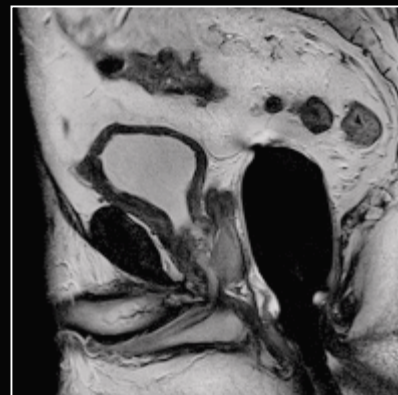


[Pelvis] T2 TSE, GRAPPA 2
TR/TE 4640/92 / TA 3:57 min
SL 4 mm / slices 25 / FoV 230 mm
matrix 384

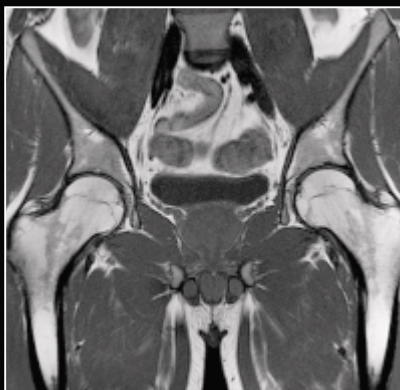Courtesy of H. Lee Moffitt Cancer
Institut, Tampa, USA



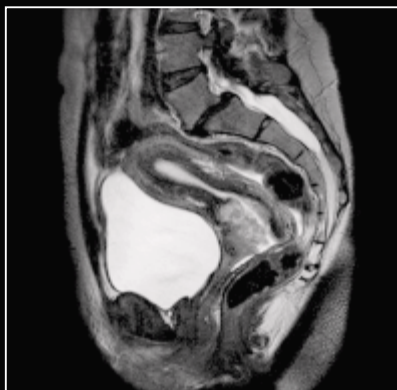
[Pelvis cor] T2 TSE
TR/TE 5800/107 / TA 2:92 min
SL 3 mm / slices 21 / FoV 200 mm
matrix 512



[Pelvis sag] T2 TSE
TR/TE 5900/107 / TA 2:04 min
SL 3 mm / slices 21 / FoV 200 mm
matrix 512

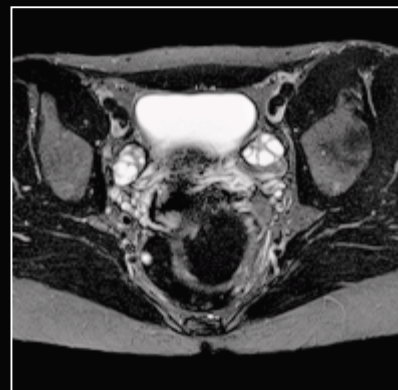

[Pelvis T1] T1 TSE, GRAPPA 2
TR/TE 582/14 / TA 3:07 min
SL 4 mm / slices 11 / FoV 400 mm
matrix 512



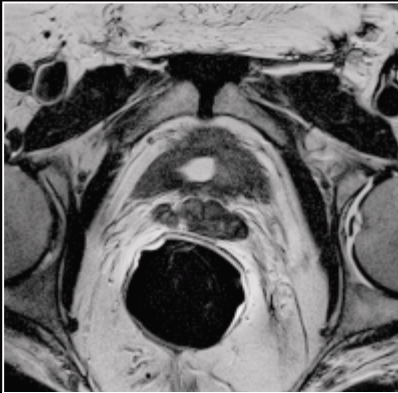
[Pelvis T2 sag] T2 TSE, GRAPPA 2 / TR/TE 8620/88
TA 2:53 min / SL 4 mm / slices 20
FoV 380 mm / matrix 448

Courtesy of Klinikum St. Marien,
Amberg, Germany

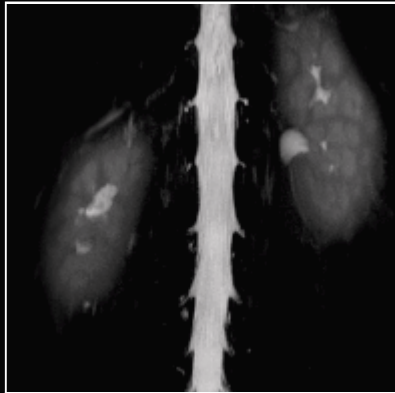


[Pelvis TIRM] T2 TIRM, GRAPPA 2 / TR/TE 6000/118
TI 150 / TA 4:07 min / SL 3 mm
slices 15 / FoV 240 mm
matrix 320

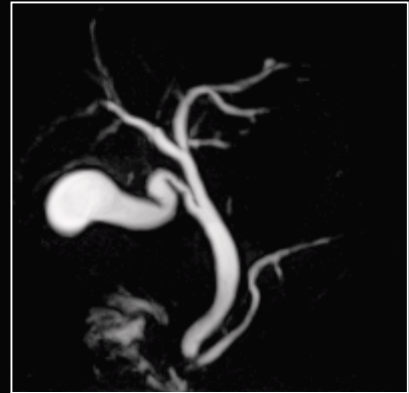
Abdomen and Pelvis



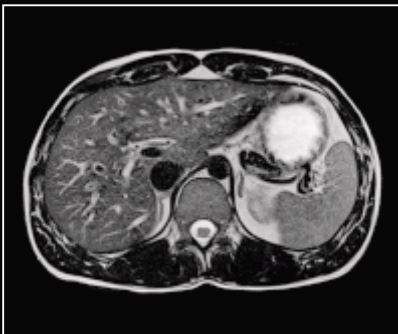
[Pelvis tra] T2 TSE
TR/TE 6360/104 / TA 5:18 min
SL 3 mm / slices 30 / FoV 160
matrix 512



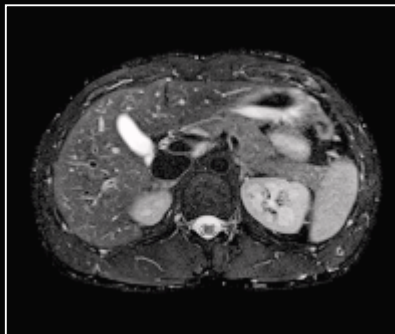
[Myelography] T2 3D HASTE
TR/TE 8000/273 / TA 5:48 min
eff. SL 0.9 mm / partitions 44
FoV 230 mm / matrix 256
Courtesy of H. Lee Moffitt Cancer Institut,
Tampa, USA



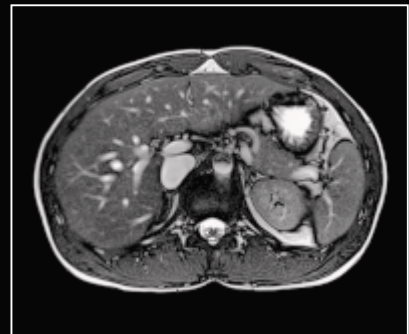**[MRCP] T2 3D TSE Restore,
GRAPPA 2** / TR/TE 3773.6/678
TA 3:43 min / eff. SL 1.5 mm
partitions 40 / FoV 380 mm
matrix 384
Courtesy of Klinikum St. Marien,
Amberg, Germany



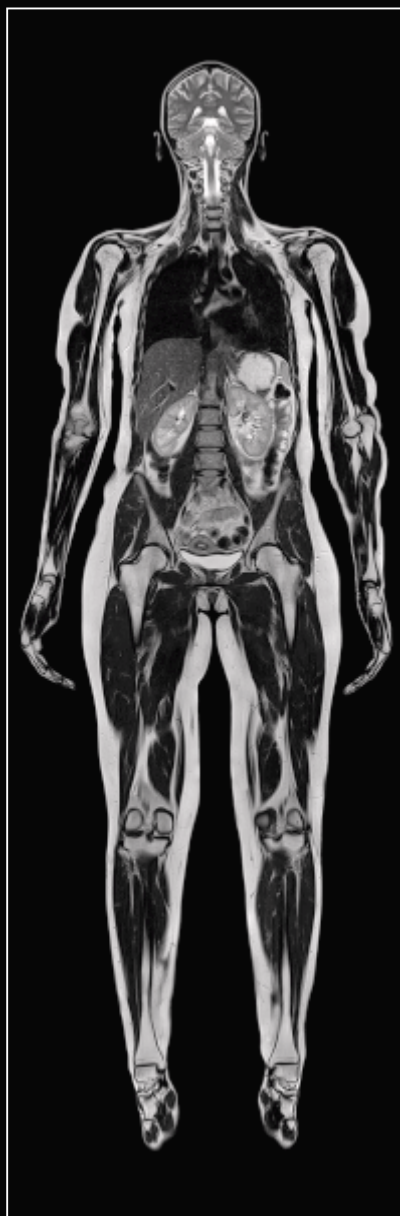[T2 TSE] T2 TSE, GRAPPA 2
TR/TE 6734.8/81 / TA 3 x 3:07 min
SL 4 mm / slices 30 / FoV 360 mm
matrix 512



**[T2 TSE FatSat] T2 TSE
FatSat, GRAPPA 2**
TR/TE 5898.9/72 / TA 3 x 2:49 min
SL 4 mm / slices 30 / FoV 360 mm
matrix 512



**[TrueFISP] T2 TrueFISP,
GRAPPA 2** / TR/TE 4.5/2.3
TA 13 s / SL 4 mm / slices 9
FoV 370 mm / matrix 384

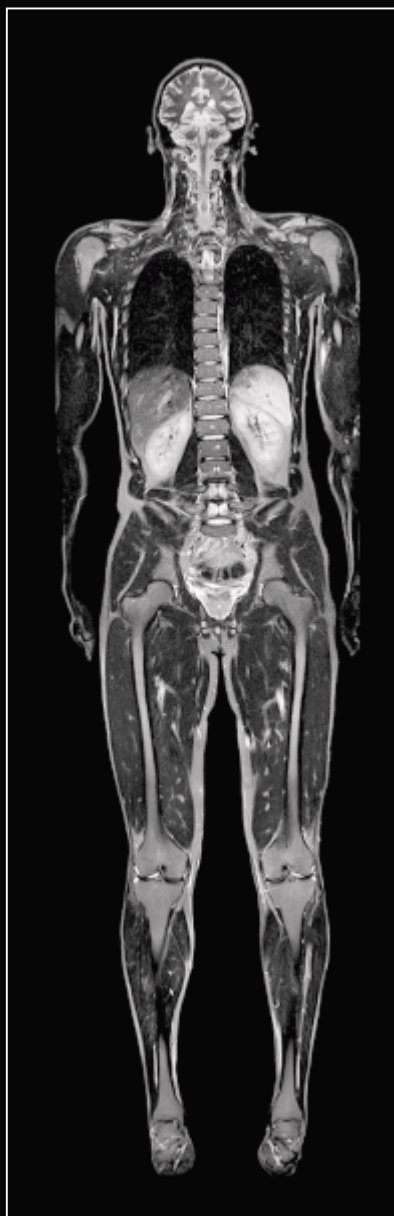

[WholeBody T2]

T2 TSE, GRAPPA 2, 6 steps

TR/TE 5430/78 / TA 6 x 1:43 min

SL 5 mm / slices 21 / FoV 1826 mm
matrix 512

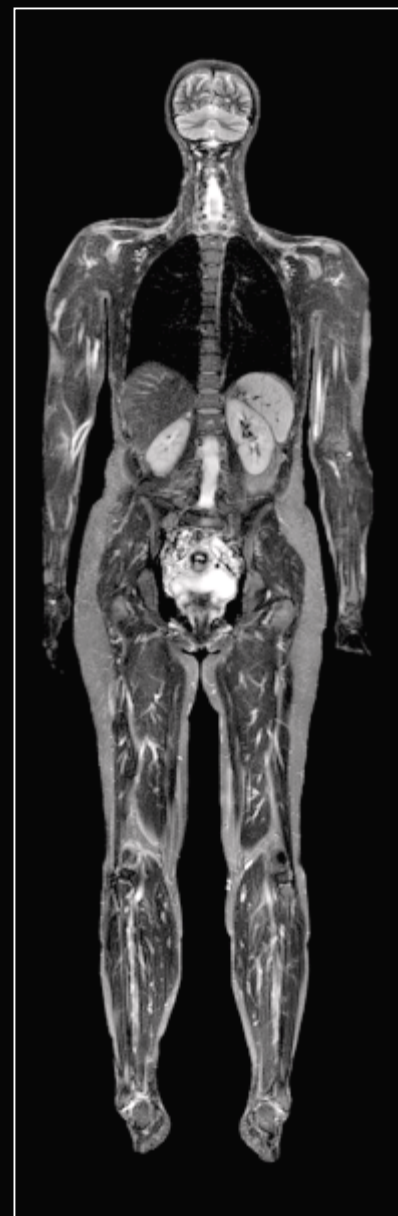


[WholeBody TIRM]

T2 TIRM, GRAPPA 2, 6 steps

TR/TE 9000/85 / TI 130

TA 2 x 2:15 min / SL 5 mm
slices 15 / FoV 1881 mm
matrix 384



[WholeBody TIRM cor]

T2 TIRM, GRAPPA 2, 6 steps

TR/TE 2670/101 / TI 150

TA 6 x 2:58 min / SL 7 mm
slices 18 / FoV 1876 mm
matrix 512

Courtesy of Klinikum St. Marien,
Amberg, Germany

Tim UPGRADES IN FRANCE

First Experiences with Tim Upgrades in France

Eric de Kerviler, M.D.¹, Bruno Boyer, M.D.²

¹Imaging Department, APHP Saint Louis Hospital, Paris, France

²Radiology Department, Begin Military Hospital, Paris, France

Introduction

Since the introduction of the MAGNETOM Avanto, the first Tim system, we have frequently been told: "Tim is extremely interesting; is it possible to have this functionality with my Symphony?"

The answer to the question is "yes". In France, the Saint Louis Hospital's and the Begin Military Hospital's MAGNETOM Symphonies were both upgraded to Tim (Total imaging matrix) in November 2005.

The Saint Louis Hospital has been working with a MAGNETOM Symphony since 1999. The activities of the department are diverse, with a strong orientation toward oncology and abdominal imaging. Caring for fragile patients requires working fast and being able to rapidly examine various regions of the anatomy. In 2002, the system had already benefited from the Maestro Class Quantum iPAT gold upgrade to make use of multiple element coils and Parallel Acquisition Techniques, and as such improve system performances for key applications of the department.

Since 1999, Begin Military Hospital has been working with a MAGNETOM Symphony. Activities are general in nature. Despite being a military hospital, the department is open to

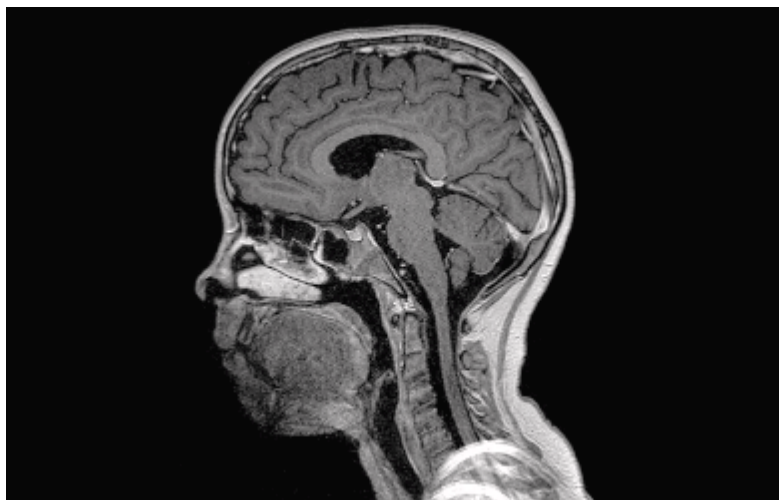the public. The system has been upgraded on a regular basis. After 6 months' experience with the MAGNETOM Symphony Tim upgrades, we would like to present a report of the experiences of these two hospitals.

The French context

Whilst MRI activity has greatly advanced these last few years, the number of MRI systems per inhabitant in France remains small. Moreover, the renewal of systems in a hospital setting is taking longer and longer. Consequently, it is important for these teams to keep their systems maintained and to operate them at peak levels. The upgrade is a very appropriate response.

Why did the hospitals decide to upgrade their MAGNETOM Symphony?

For Saint Louis Hospital, Tim technology seemed to be the tool to enable them to make huge progress by breaking through the present restrictions in gastrointestinal and functional applications and to develop extensive imaging, thanks to signal gain and Parallel Acquisition Techniques. The upgrade



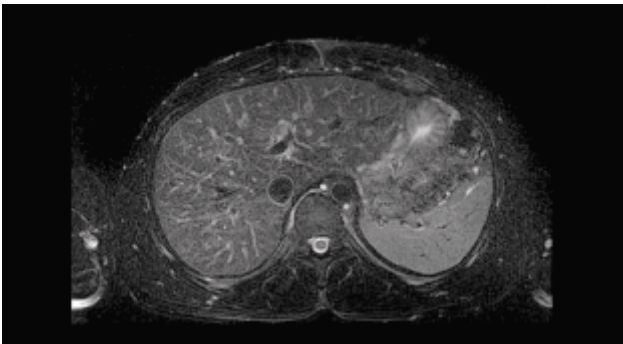
[Figure 1] 10-year-old child, T1-weighted 3D SPACE

PAT	2
matrix	512
SL	1.2
slices	128
TA	4:34
images	102

Combined use of the 12-channel Head Matrix coil and the C-spine coil.

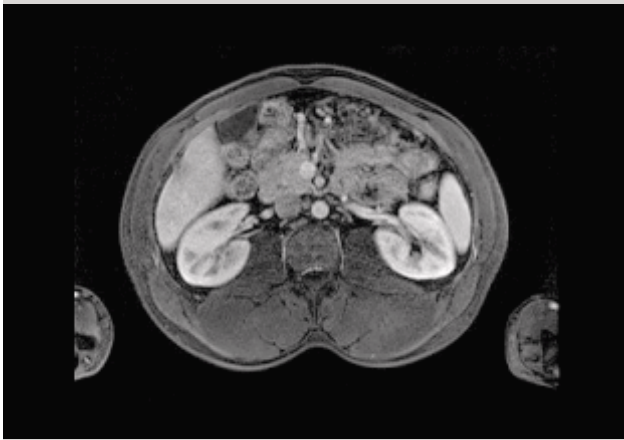
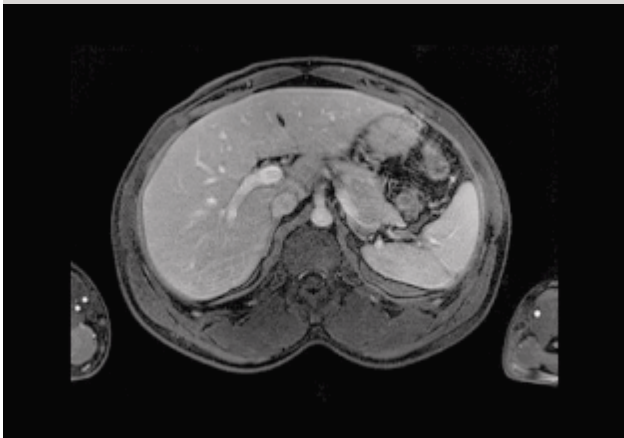
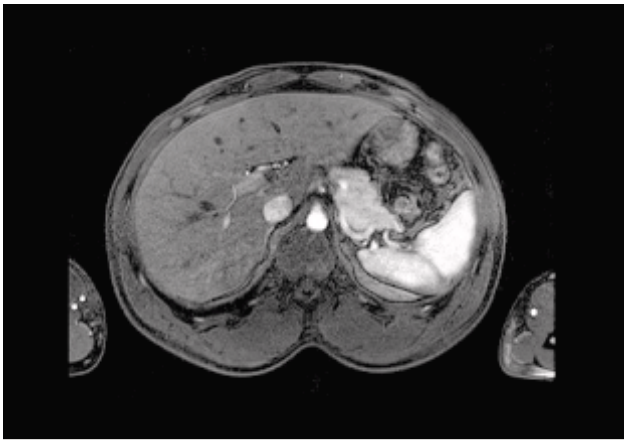
Courtesy of Saint Louis Hospital.

Patient follow-up in a liver pathology case



[Figure 2] Free-breathing TSE T2-weighted sequence with fat saturation using PACE and the Body Matrix coil.

matrix	384
SL	7
slices	20
TA 2*	53.93



[Figure 3] FLASH 2D IN OPP sequence.

PAT	2
matrix	320
SL	7
slices	40
TA 2*	12.55

[Figure 4] 3D VIBE

PAT	2
matrix	384
SL	2.7
slices	60
TA	16.48

would also reduce lead times thanks to increased throughput. Begin Hospital considered Tim technology particularly suited to develop specific female pelvic exams because of the developments in 3D imaging.

This upgrade also allows the hospitals to incorporate new 3D applications such as *syngo* SPACE and *syngo* SWI (Susceptibility-Weighted Imaging).

Experience after 6 months

Practical aspects:

The departments were already familiar with MAGNETOM Symphony's IPA (Integrated Panoramic Array) system that allows the combination of several coils in a phased array. With Tim, however, extended coil combinations are available with the 10 sockets of the examination table and thereby make the use of coils even easier. There are now new possibilities to combine more coils with the new Matrix technology that offers a higher number of channels. As a further benefit, the Tim "Matrix" coils are lighter.

Total integration of the coils has really changed lives. Now, it is sufficient to add the Body Matrix for abdominal-pelvic exams. There is no compromise between quality and coverage.

The sites gained in utilization flexibility as well. For instance, the use of 2 Body Matrix coils side-by-side (left-right) enables straight-forward handling of heavy patients with a large waist size.

In cardiology, the new Bluetooth system (wireless ECG leads) is very easy to use: no wires, great reliability, optimized reproducibility of the exams.

The interface is even clearer, thanks to Tim. The position of the anterior coils, for example, is precisely identified and viewed on the console.

The Phoenix tool – which by simple drag and drop reproduces all the parameters of a previously acquired image – enables very quick implementation of new sequences used on the MAGNETOM Avanto.

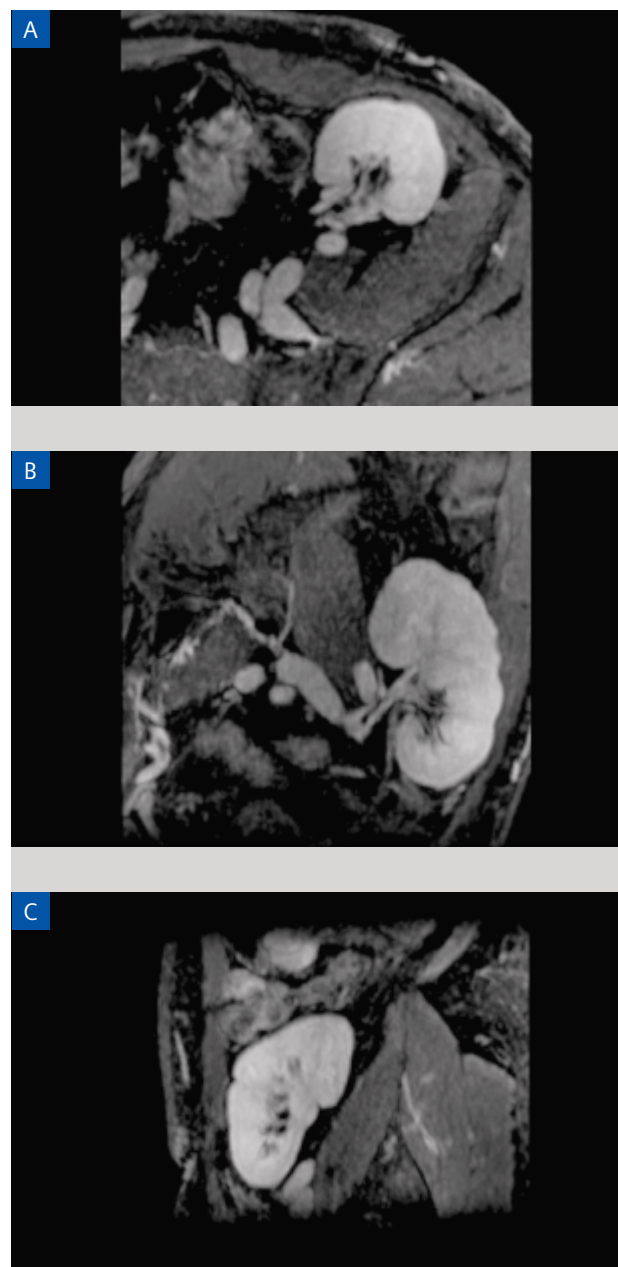
Clinical aspects:

Tim promised signal gain. Users were able to observe this regardless of the type of application, thereby increasing resolution while reducing acquisition times.

On the one hand, the combination of the Tim Head and Neck Matrix Coils, by offering more elements (16) and thus, signal, enables coverage up to the cervical vertebra, or even an analysis extended to the complete spine when required by the pathology.

On the other hand, the 3D sequences such as the SPACE sequences which are very useful for diagnosis – are much easier to use. "We cannot do without them any longer" says

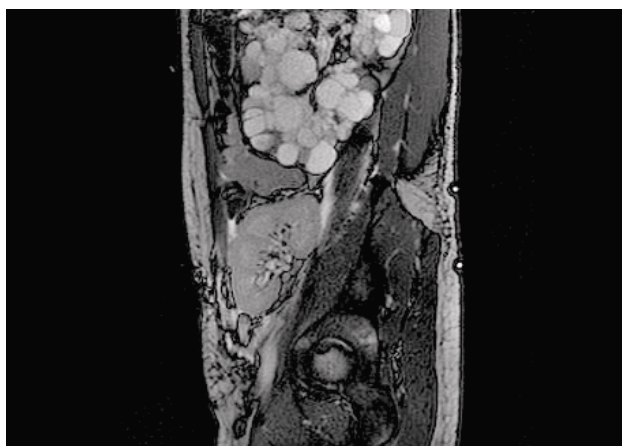
Renal transplant evaluation at day one:



[Figure 5] 3D VIBE isotropic

PAT	2
matrix	320
FoV	247*380
SL	1.6
slices	120
TA	26.03

MPR isotropic VIBE allows an optimal assessment of vessels and renal transplants.



[Figure 6] Sagittal 2D TrueFISP

PAT	2
matrix	256
SL	4
slices	20
TA	00.67 per slice

Professor Boyer. It seems therefore to be a win-win situation. For abdominal exploration, Saint Louis Hospital has been using 12 element anterior and posterior body coils; Tim has ensured equivalent element density and improved signal. This has permitted development of the use of isotropic sequences such as the 3D VIBE sequence (Volume interpolated breath-hold examination). Thanks to a better fat saturation and to PACE (for free-breathing abdominal examinations), the T2-weighted fat saturated sequences are of excellent quality.

Conclusion

These first results of MAGNETOM Symphony Tim upgrades have been very positive and the users are very satisfied.

Quoting Professor Eric de Kerviler: "We truly had the impression that we were working with a completely new system. It would be difficult to go back now."

The MAGNETOM Symphony, A Tim System holds true to its promises in terms of ergonomics and image quality.

The users of the Symphony Tim are therefore eagerly anticipating the arrival of new applications in the future.

Feedback from Saint Louis Hospital

"A few months have passed since we upgraded our MAGNETOM Symphony to Tim. The first step after the upgrade consisted of using the same imaging protocols as before. We noticed an immediate and dramatic improvement in image quality due to the new Matrix coils, using a larger number of elements. The second step was to speed up the sequences or increase the spatial resolution without having to trade in image quality. This was easy and most of our examination protocols have now been redesigned. As a result, we obtain better images faster. The last step was to take advantage of the coil matrix. This has been a major change in the way we work. Adding a coil in the field of view is now performed with a single mouse click. The system, which allowed us to plug in a large number of coils at the beginning of the examination, provides us now with the possibility of combining coils. This prevents signal loss at the margins of the field of view and offers us great flexibility for studies requiring table offset/movement. After 6 months, our feedback of the MAGNETOM Symphony Tim upgrade is very positive."

Prof. Eric de Kerviler

Scanner model used:

Saint Louis Hospital: MAGNETOM Symphony, A Tim System [76x32]

Begin Military Hospital: MAGNETOM Symphony, A Tim System [76x18]

Image Quality Improvements after MAGNETOM Symphony Tim Upgrade

J. Dehem, M.D.

Jan Yperman Ziekenhuis, Ieper, Belgium

Our MAGNETOM Symphony, installed since 2000, was upgraded to a MAGNETOM Symphony, A Tim System in February 2006.

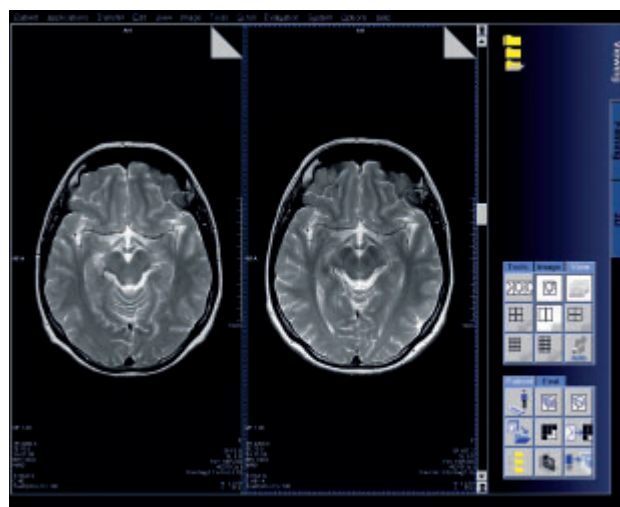
With the Tim (Total imaging matrix) platform implementation, we have raised our 6-year-old system to the level of the recent generation of MR-systems, offering up-to-date technology and service to our patients. Immediately, three major improvements become clear:

- 1. Image quality improved:** comparing data of the same patients, taken before and after the upgrade with the same parameter setting, shows a more homogeneous image and an improved fat saturation (fatsat) due to the renewed body RF coil and completely new RF system.
- 2. Patient positioning is easier and patient comfort has improved:** head, neck, spine and body array coils were exchanged for Matrix coils, containing multiple "clusters" of 3 coil elements. Several plug-ins on the table allow multiple coil combinations and allow to position the patient in head-first or feet-first direction. These coil combinations are indeed 'seamless' and have major advantages in orthopedic and angiographic imaging as illustrated in the following chapters. The Body Matrix coil is especially appreciated by the patient, because of its light weight. It is also easier to fix the coil around the patient, improving patient comfort.
- 3. Multiple coil combinations allow extensive use of iPAT (Integrated Parallel Acquisition Technique):** As the patient is covered by multiple coil elements, iPAT is used in all 3 directions. In 3D imaging, combination of iPAT in phase and slice direction is possible (iPAT²). We routinely use higher PAT factors (PAT3) and combined iPAT imaging (PAT2 x PAT2 = PAT4).

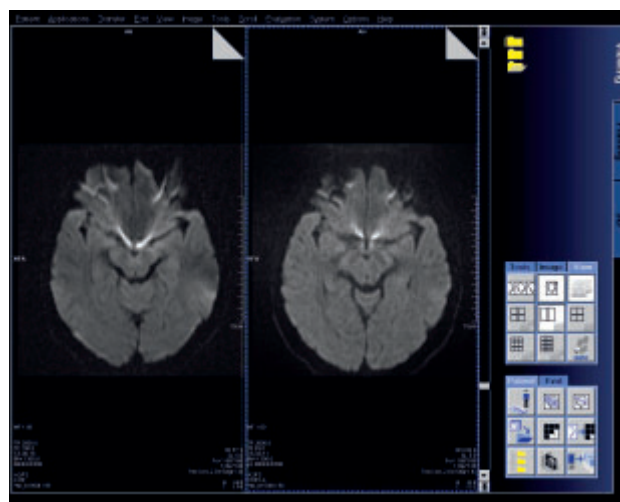
As we do not have the Tim Whole Body Suite, we only comment on 'local' exams in different clinical applications.

1. Head and Head/Neck imaging

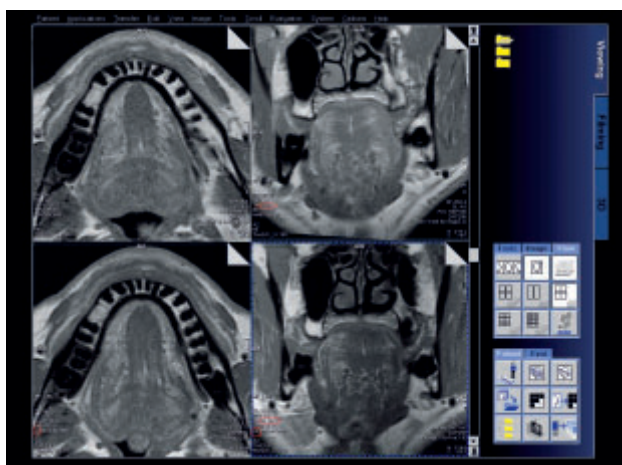
In our experience, overall image quality has improved compared to the former CP head coil. Introduction of Tim meant introduction of iPAT in all 3 directions in neuro head applications. The major improvement we see in the use of iPAT in



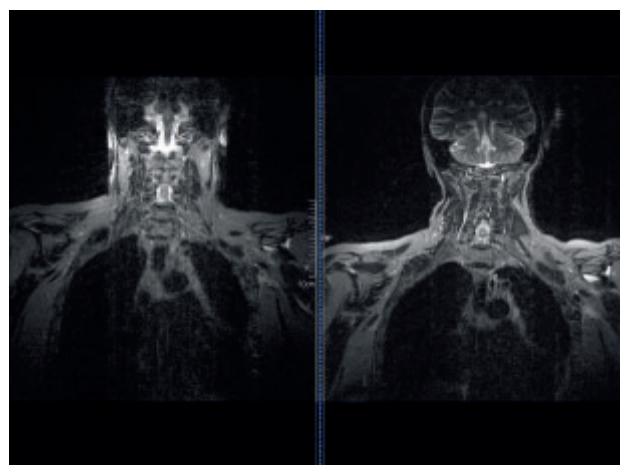
[Figure 1A] Comparison between CP head (left) and Head Matrix coil (right), both on MAGNETOM Symphony, A Tim System, on the same patient and with the same protocol. The Head Matrix coil reveals more anatomical detail e.g. substantia nigra and nucleus ruber.



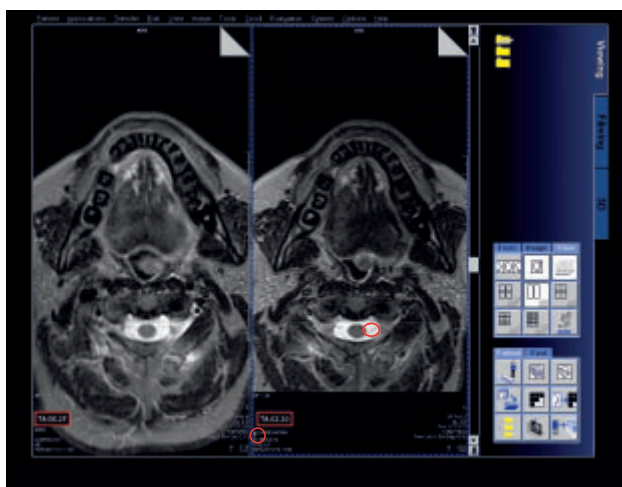
[Figure 1B] Use of iPAT in the Head Matrix coil reduces susceptibility artifacts in EPI imaging.



[Figure 2A] Comparison of the same patient before and after the Tim upgrade (same sequence parameters). Note the fine detail of the fat between tongue muscles, in the skin and delineation of the mucosa.



[Figure 3] Comparison of the same patient before and after the Tim upgrade. Overall more signal to noise (S/N), especially in the peripheral region. Homogeneous signal distribution results in better depiction of e.g. AC joints (acromioclavicular joints).



[Figure 2B] Comparison of the same patient before and after the Tim upgrade. T2-weighted TIRM (Turbo Inversion Recovery Magnitude) optimized sequence after Tim upgrade. Improved resolution and better signal is obtained in a faster time.

head imaging is in the use of EPI (echo planar imaging) sequences (diffusion, perfusion, EPI_hemo sequence) which decreases distortion. iPAT is extensively used in our 3D TOF (Time of Flight) to obtain high resolution and high coverage in a reasonable time.

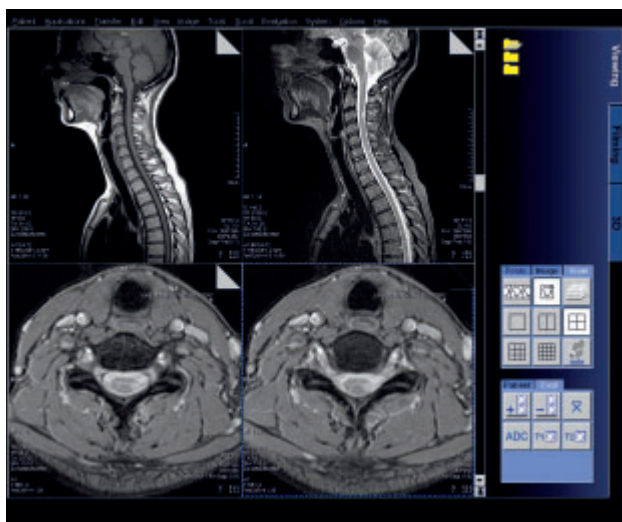
Tim implementation will allow us to follow the most recent MR techniques (BLADE, SWI (susceptibility-weighted imaging), SPACE) available on the last generation machines, as our software platform is common.

The high Signal-to-Noise 12-element Head Matrix coil gives good quality images for TMJ (Temporo-Mandibular Joint) imaging.

The seamless combination with the Neck Matrix coil and the good fatsat in this region are welcomed for head and neck, spine and plexus imaging.

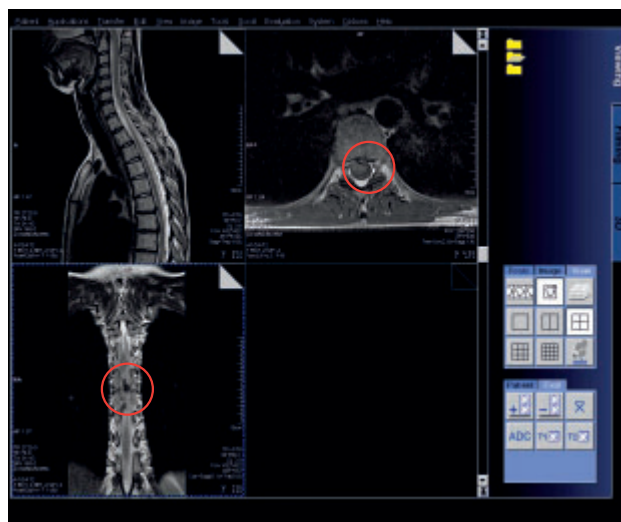2. Spine imaging

We routinely use iPAT on MAGNETOM Symphony for all spine imaging. Tim allows additional use of iPAT in the coronal direction with Left-Right (LR) phase encoding, thanks to the new 24-element Spine Matrix coil with LR orientation of the clusters. An iPAT factor of 3 can be obtained.



[Figure 4] Clear visualization of MS plaque. High signal to noise allows for thin slices easily depicting pathology of the cervical cord, iPAT ensures short examination times.

We routinely use a combination of Spine Matrix with the Body Matrix coil (thoraco-lumbar spine) which allows us to use iPAT in transverse orientation, too. In C-spine using the Neck Matrix coil, iPAT is always activated in all orientations. High S/N allows us to use iPAT routinely in all spine applications.



[Figure 5] Depiction of a cervical disc herniation in the coronal plane. Coronal plane no longer poses a challenge for "patting". Consistent image quality in dorsal spine in all directions.

3. Musculoskeletal applications

In this section we want to focus on the clinical applications with the standard Tim upgrade coils and the improvements we see. Since we had acquired the 8-channel Invivo shoulder and wrist coil, we continue to use these coils on MAGNETOM Symphony, A Tim System, but these are not further discussed in this report.

The former extremity coil is re-used on MAGNETOM Symphony, A Tim System, but needs an additional connector to plug into the new table. We routinely use the Invivo knee coil for knee imaging as it offers iPAT capabilities. The quality enhancements pre-post Tim that we comment on here with the Invivo knee coil are similar to what we see with the CP extremity coil or the other Invivo coils. These are:

1. Larger range of RF and improved RF-homogeneity.
2. Better anatomical delineation.
3. Improved fat saturation.

The CP extremity coil is used for very large, fatty knees and for ankle examinations. We admit that we also often use the Head Matrix coil for upper and lower extremities e.g. foot, toe, hand and finger, which can successfully be imaged in the Head Matrix coil. No rebuilding of the patient table is needed, patient positioning is quick and easy, and the coil allows use of iPAT, increasing patient throughput.

For hip imaging we upgraded from a 6 element spine array coil to a 3 x 8 element Spine Matrix coil. This allows:

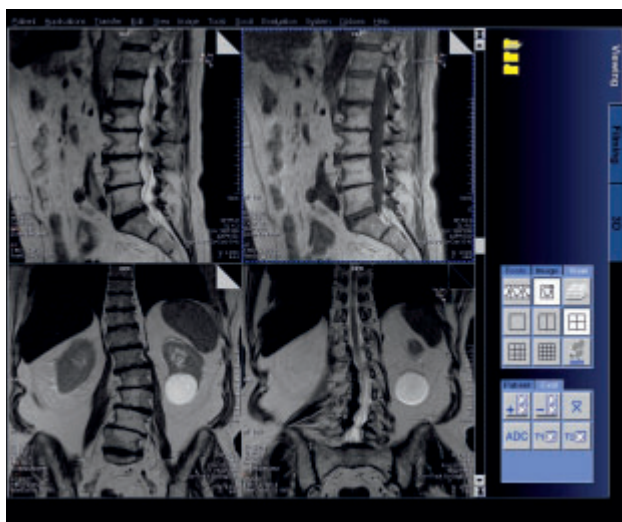
1. A larger RF range in the hip and upper leg region for tall patients, registered head first.
2. Combination with the Body Matrix coil in all directions, especially in the coronal plane, often used in the hip. We use routinely a PAT factor 3 in LR encoding. For higher PAT factors in coronal orientations (often large field of view (FoV), consequently high S/N), gradients can be swapped to HF phase encoding and PAT4 can be used.

An inventive way to use the Tim platform is to use the Spine and Body Matrix for elbow imaging. There are several benefits:

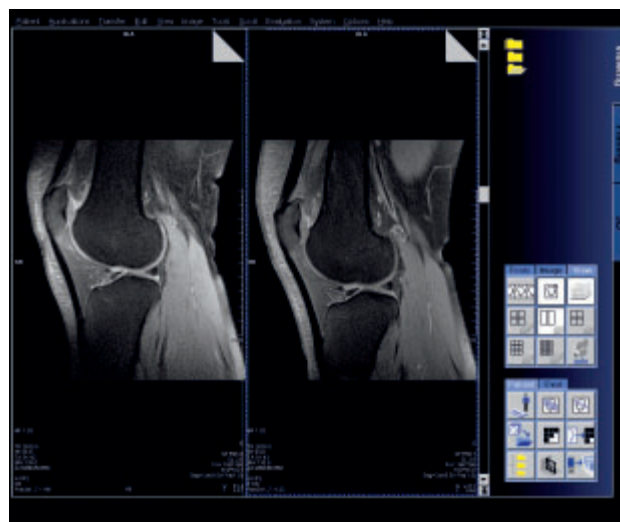
1. Fast patient positioning.
2. Patient comfort.

3. Use of iPAT in all directions, reducing scan time. Total scan time is reduced from 20 to 13 minutes.

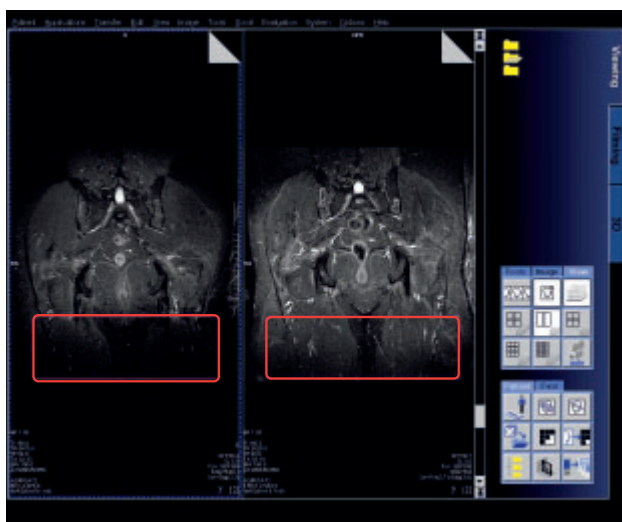
4. Offering better image quality than with the use of flex coils, where iPAT can not be used.



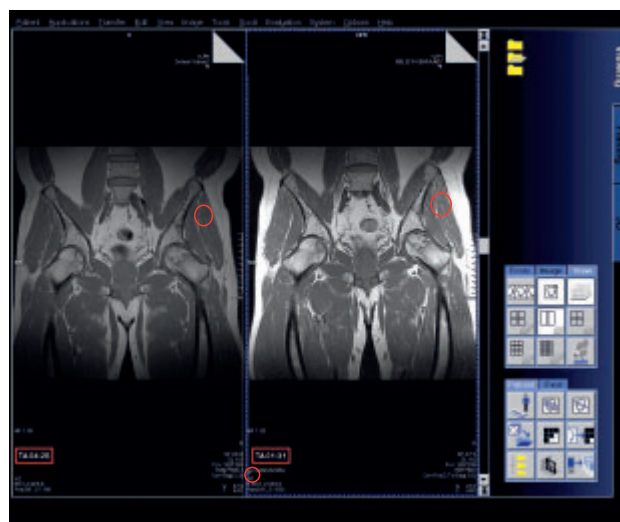
[Figure 6] Consistent image quality in lumbar spine with extensive use of iPAT in all directions – even in coronal plane L-R encoding, PAT3 – with clear, sharp images.



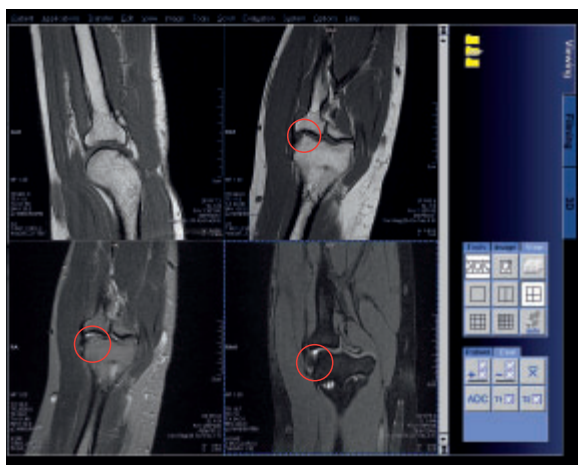
[Figure 7] Comparison of the same patient before and after the Tim upgrade with the Invivo knee coil. We observe here an extension of the RF range, improved fat saturation and high anatomical detail.



[Figure 8A] Comparison of the same patient before and after the Tim upgrade. Note the greater signal in the peripheral zone due to more spine elements.



[Figure 8B] Higher signal, same high resolution and less time, thanks to iPAT in coronal direction.



[Figure 9] Patient with tendinosis. Use of combination of Body and Spine Matrix coils. Easy patient positioning. Total imaging time 13 minutes. This protocol includes a 3D DESS (Dual Echo Steady State) high resolution scan ($0.7 \times 0.6 \times 0.8 \text{ mm}^3$) of 3 minutes. iPAT is used in all 3 dimensions.

4. Breast imaging

In MR-mammography, Tim allows more combinations of coils. We always removed the spine coil in breast examinations: using our MAGNETOM Symphony it was impossible to combine the body phased array with the breast coil, as the plug for the body part was on the spine array coil. On MAGNETOM Symphony, A Tim System, however, both Breast and Body Matrix coil can be plugged in simultaneously which is a great

advantage. This improves the S/N in both breasts and even more important, in the axillae.

With this large S/N, we optimized our dynamic protocol to a spatial resolution of ($0.9 \times 0.9 \times 1.1 \text{ mm}^3$) within the same time resolution (1 min). Fatsat has improved. We look deep into the pectoral and axillary region.

5. Abdominal and pelvic applications

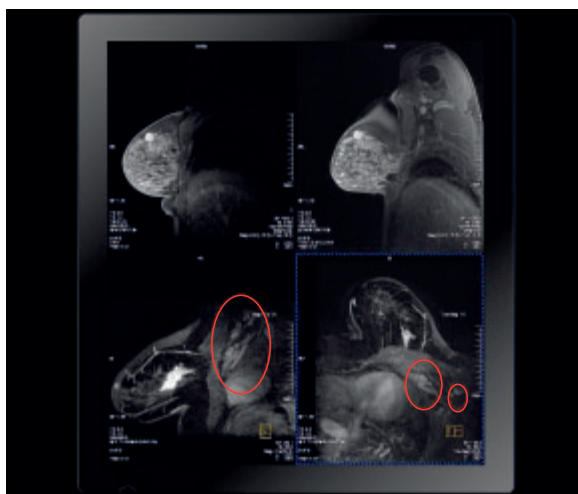
We see the following improvements in abdominal and pelvic imaging:

1. The Body Matrix coil offers more comfort due to its light weight and it fits well around the patient.
2. S/N increase allows us to use thinner slices (5 mm in 2D, 2 mm in 3D VIBE (Volume Interpolated Breathhold Examination)) and/or higher resolution scans (use of 320 resolution instead of 256).

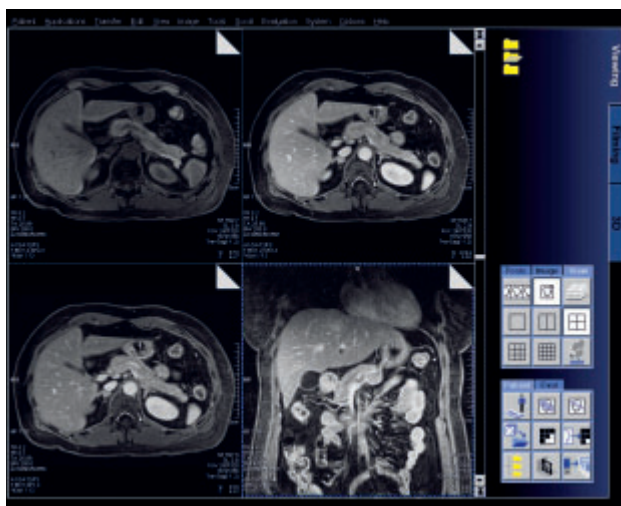
3. Multiple plugs allow the imaging of body or pelvis in head first or feet first position.

4. PAT2 is routinely used for almost all exams, mostly to shorten breathholds.

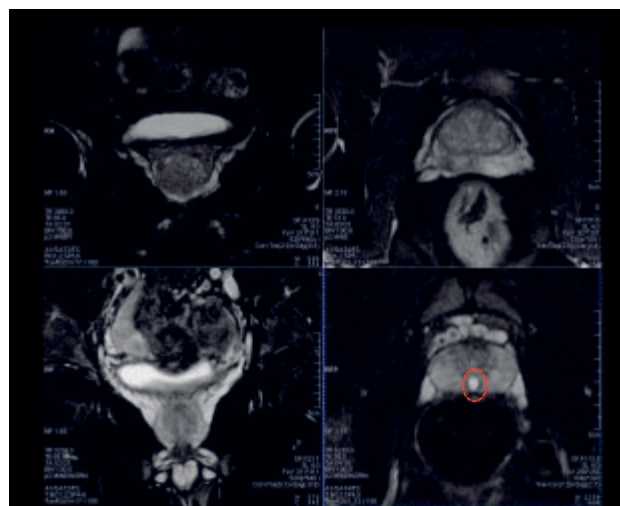
5. Very homogeneous fat saturation is obtained in abdomen and pelvis.



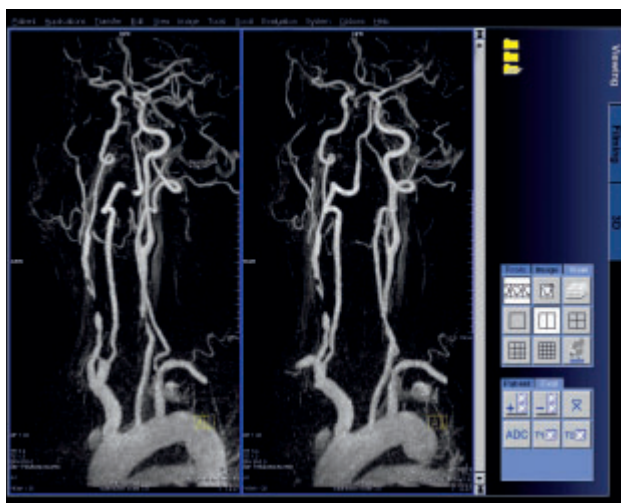
[Figure 10] Comparison of the same patient before (upper left) and after (upper right) the Tim upgrade in a fatsat T2-weighted high-resolution scan. Better delineation of the lesion with MAGNETOM Symphony, A Tim System. Lower segment depicts thin MIP reconstructions of the subtraction dataset on the axillary lymph nodes on MAGNETOM Symphony, A Tim System. Note the visualization of the mediastinum and axillae when both Breast and Body Matrix coil are combined.



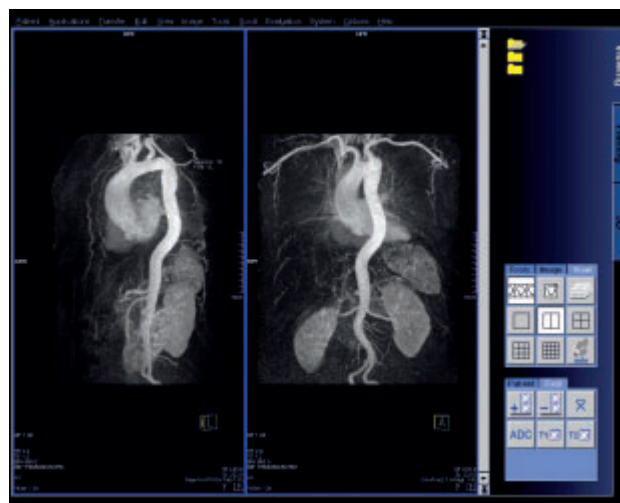[Figure 11] Pre- and post-gadolinium 3D VIBE on MAGNETOM Symphony, A Tim System. Our standard protocol in transverse orientation is a 96 partition scan of 25 s with a resolution of $(1.4 \times 1.3 \times 2.0 \text{ mm}^3)$. Late enhanced coronal scan with 72 partitions in 22 s with a resolution of $(2.0 \times 1.4 \times 2.0 \text{ mm}^3)$. PAT2 is used in transverse and coronal orientation.



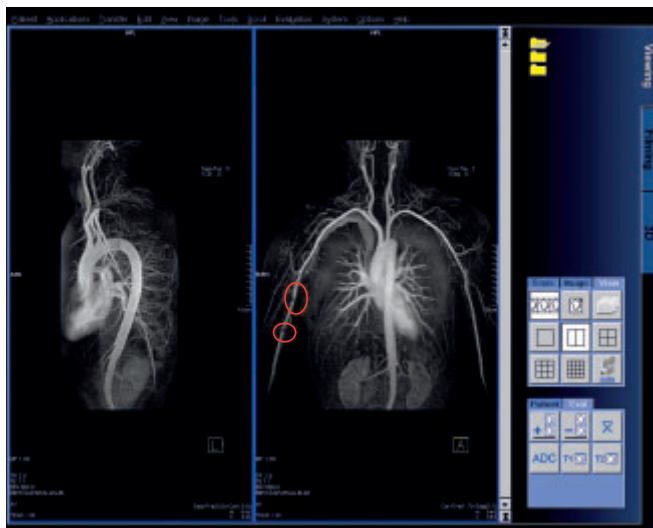
[Figure 12] T2_tse_FS in the prostate in 2 different patients. Upper segments (pre-Tim): coronal plane with resolution of $1.0 \times 1.0 \times 4.0 \text{ mm}^3$ in 2 minutes (left), transverse plane in $0.8 \times 0.8 \times 4.0 \text{ mm}^3$ in 3 minutes (right) (no. of slices = 14, TR = 3530 ms). Lower segments show the quality of MAGNETOM Symphony, A Tim System: coronal plane with resolution of $1.0 \times 1.0 \times 4.0 \text{ mm}^3$ in 2 minutes (left), transverse plane in resolution $0.8 \times 0.8 \times 4.0 \text{ mm}^3$ in 4 minutes (no. of slices = 25, TR = 6230 ms).



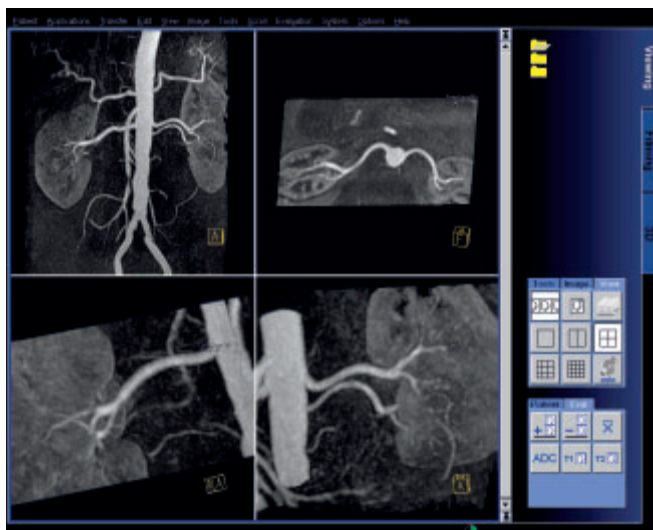
[Figure 13] Homogeneous signal from aorta to ICV (intracranial vessels) through use of a seamless combination of Head, Neck and Spine Matrix coil. We use 176 partitions of 1.1 mm, resulting in coverage of the complete anatomy in A-P direction. Resolution of $(0.8 \times 0.7 \times 0.8 \text{ mm}^3)$ in 38 s. High PAT factor (PAT2 x PAT2) in phase encoding and slice direction are used to keep acquisition time short.



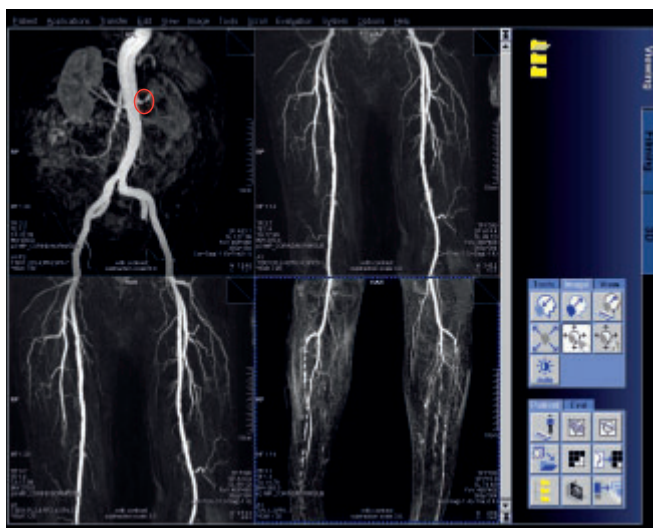
[Figure 14] Large coverage from the subclavian to iliac vessels through a seamless combination of 3 spine clusters, Neck and Body Matrix coil. We use 176 partitions of 1.1 mm ($1.1 \times 0.9 \times 1.1 \text{ mm}^3$) in 24 s. High PAT factor (PAT2 x PAT2) in phase encoding and slice direction.



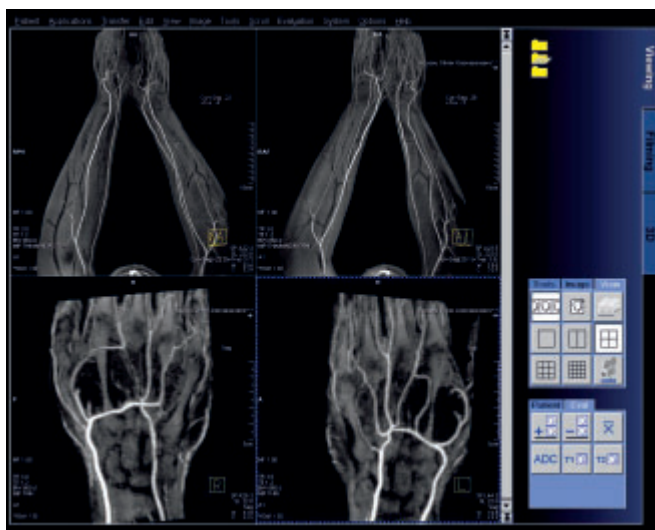
[Figure 15] Coverage from above the carotid bifurcation, the subclavia and thoracic aorta until renals through combined use of Head, Neck, 2 spine clusters and Body Matrix coil. We use 192 partitions with an isotropic resolution of 1 mm ($1.0 \times 1.0 \times 1.0 \text{ mm}^3$) in 24 s. High PAT factor (PAT2 x PAT2) in phase encoding and slice direction. Note the better visualization of the peripheral regions, which is improved by the new body send coil.



[Figure 16] In renals, a large coverage is less important. Small pixel size is important here, to reduce dephasing as much as possible. We use a combination of Body Matrix coil with 3 spine clusters. We use 96 partitions with a resolution of $1.1 \times 1.0 \times 1.1 \text{ mm}^3$ in 27 s, PAT3.



[Figure 17] Aorto-iliac 64 partitions of $1.2 \times 1.1 \times 1.8 \text{ mm}^3$ in 23 s, PAT3 Iliaco-femoral 56 partitions of $1.2 \times 1.1 \times 1.8 \text{ mm}^3$ in 19 s, PAT3. Lower legs 56 partitions of $1.2 \times 1.1 \times 1.3 \text{ mm}^3$ in 16 s, PAT2.



[Figure 18] Imaging of both left and right elbow, forearm and hand with combined Head, Neck posterior part, Spine and Body Matrix coil. Patient is positioned prone. 144 partitions of $0.9 \times 0.9 \times 0.9 \text{ mm}^3$ in 38 s, PAT3. Image quality allows zoom on the same dataset to depict the arteries of the hand and fingers.

6. Contrast enhanced angiography

In angiographic applications, the major Tim improvements are:

1. Extensive use of iPAT (PAT3, PAT2) which allows higher resolution and/or larger coverage for the same acquisition time.
2. Use of maximum FoV with high S/N with seamless combination of coils.

Use of both allows us to obtain a very high resolution of our angiographies in an acceptable breathhold time. High concentration Gadolinium compensates for the loss of S/N in these high resolution scans with high PAT factors.

In peripheral angiography, we use a robust technique covering the extremities from renals to toe.

The inguinal region is clearly depicted through the use of the Body Matrix coil, in combination with the spine elements and the Peripheral Angiography Matrix coil. Following the Tim upgrade, which extended our receiver circuit with 18 independent receiving channels, we are routinely applying iPAT in all ranges. We obtain high resolution and sufficient coverage in a short time and, consequently, a better delineation of the vessel.

The renal arteries are always included in the picture and can give additional information to the clinician.

In a creative way, the Head, Neck, Spine and Body Matrix coil can be combined to depict the vessels of both left and right lower arm and hand. Seamless combination of all coils elements gives a homogeneous overview.

This image quality and resolution makes magnification possible, with still sufficient diagnostic quality.

Conclusion

Tim (Total imaging matrix) has proven to be a Total improvement. The new RF body send coil and completely new RF system in combination with the new matrix coils offer a general improvement.

Tim allows higher quality (higher resolution, more S/N) and more patient comfort (lightweight coils, easy positioning and shorter breathholds). The overall scan time is diminished, resulting in a higher patient throughput and shorter waiting lists. Tim brings your system in line with the latest MR technology.

„Although Siemens launched Tim as the Total imaging matrix, Tim means to me Total improvement.“

J. Dehem, M.D., Jan Yperman Ziekenhuis, Ieper, Belgium

MAGNETOM Symphony Maestro Class Upgraded to MAGNETOM Symphony, A Tim System [76 x 18]

David Forrest

Siemens Medical Solutions, Macquarie Park, NSW, Australia

In May 2006, Westmead private Hospital became the first radiology facility in Australia to undertake a MAGNETOM Symphony Tim Upgrade. We asked Dr. David Ho, lead radiologist, Mrs. Francis Gray, lead MR technologist, and Ms. Kumaransi Silva, MR technologist, to comment on the difference this technology has made.

Ergonomics

The technologists are very excited about the coil concept provided with Tim. The ability to have multiple coil elements plugged in at once and to be able to use various flexible combinations of these coils simultaneously has had a major impact on both workflow and patient comfort. No longer is it necessary to re-enter the scan room and reposition the patient or coils when scanning multiple body regions. The coil set up is easy and quickly adaptable for patients with var-

ious different body habitus. The patients love the light weight nature of the matrix coils and the unique modular nature means that anatomical and pathological coverage is no longer limited by individual coil design. The "Intelligent Coil Control" provides a quick and easy way to visualize the "active coil elements" on the monitor, thereby helping to optimize image quality and saving sequence planning time. As the practice gets busy these factors become more important and assist in reducing the pressure on staff.

Image quality

Having used a MAGNETOM Avanto previously, Dr. Ho has been very impressed with the image quality on his MAGNETOM Symphony, A Tim System. He has found the fat suppression to be very uniform, even in hard to fat suppress areas such as the neck. The referrers have also been impressed by the carotid angiographies, the higher resolution now possible with the Tim Matrix coils playing a major part in this.

The Tim open architecture has created the opportunity to use a wide range of third party coils: e.g. specific musculoskeletal coils, resulting in beautiful orthopedic images.

Signal to noise has noticeably increased with the Tim Matrix coils, with examinations such as the head and angiographies being noticeably better. Larger matrixes and more slices, are now able to be used without extending the examination time, by using iPAT (integrated Parallel Acquisition Technique). The Body Matrix coils give greater clarity and coverage. If we see something peripherally it is easier to zoom in and examine the pathology in more detail.

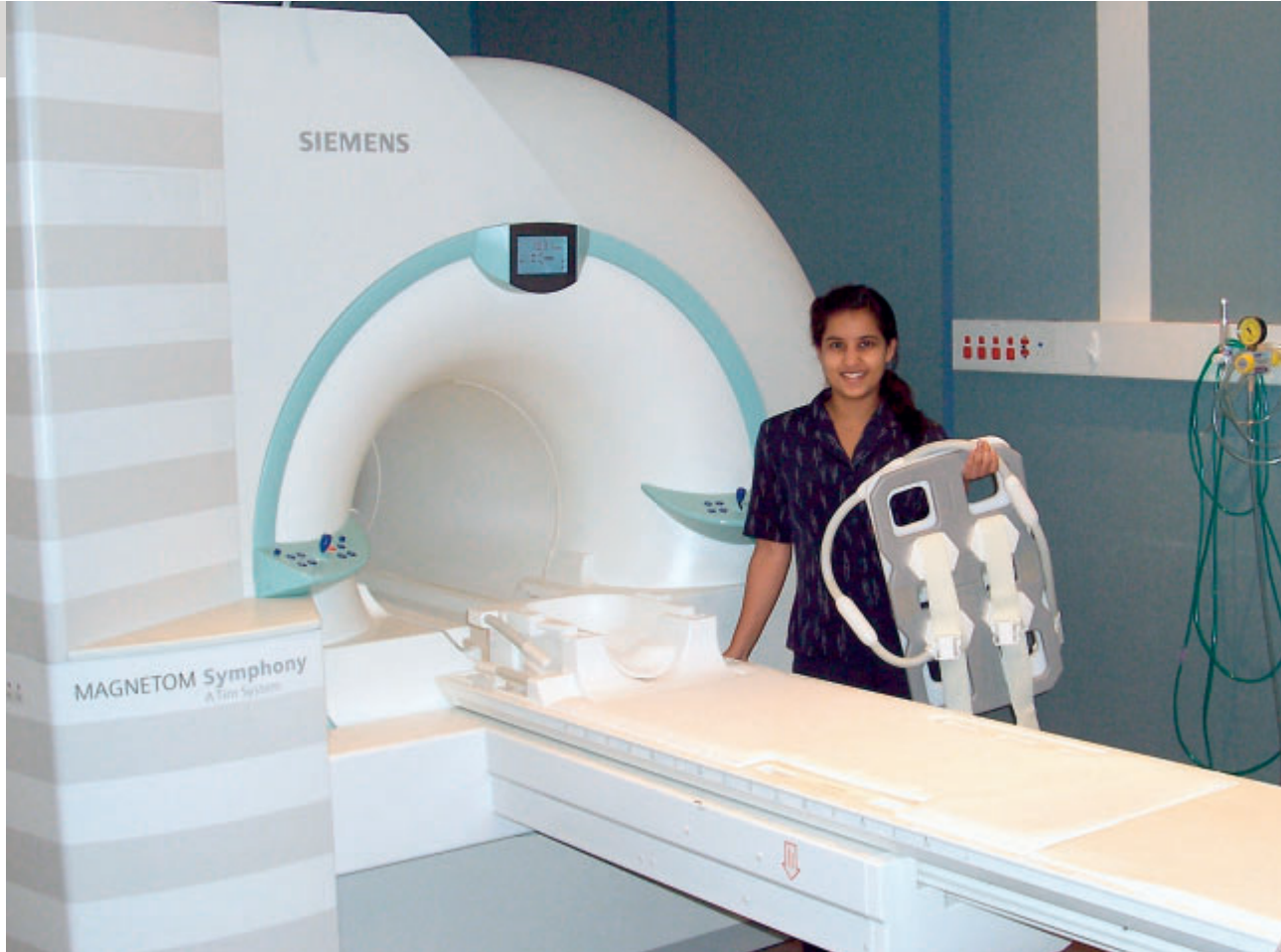Referring physicians and patients

As a private provider this site is in competition with other practices. The referring doctors may not understand technology, but they want their patients to have the best leading edge technology.

Of course our competitors used the fact that we had a 5 year old MR system against us. With the Tim Upgrade, referring doctors now know that we do have leading edge technology.



(Right to left) Ms. Kumaransi Silva, Dr. David Ho, Angela Tedesco, Key account manager, David Forrest, MR Business Manager.



Ms. Kumaransi Silva, with a light weight Tim Body Matrix coil.

Not only have they noticed an improvement in image quality, but have fallen in love with other aspects of the new technology, such as the composed spine images, which provide an additional visualization tool to standard image assessment. The surgeons also love these composite image representations, and use them in conjunction with the individual source images.

Trigeminal studies are also improved; 3D volumes have better flow compensation. The referrers know that for their patients there is greater comfort and faster examinations thanks to the better workflow attributable to Tim. Not having to change coils greatly affects patient comfort and some referrers have told us, that they were waiting until we had the Tim Upgrade before they would refer some cases.

We have found the Tim technology to be very useful in other ways, for example when there is a lesion at the Cervico-thoracic junction, I do not have to ask for the patient to be repositioned, I can just zoom in to get the detail. It is also a fact that the speed of the examination as a whole makes patient movement less likely and consequently we see less movement in the images.

Financial outcomes and productivity

After the Tim Upgrade, we have seen a 30% increase in the number of examinations performed compared to before. It should also be noted that the upgrade has reduced waiting

times. The financial impact is easy for us to see, this is due to an increase in patient volume which also translates to an improvement in cash flow.

Staff retention and development

There is a significant cost (both financial and clinical) associated with the loss and re-training of professional staff. It has been easy to attract staff and train them with this technology. There are fewer mistakes made and if there are any, they are much easier to recover from. In this environment, high levels of staff retention within radiology is very important.

Future developments

We believe that we will see other MR applications increasing in our practice now, for example an increase in the use of MR Angiography.

Conclusion

The initial business case developed in support of the Tim Upgrade for MAGNETOM Symphony has been proved so far, looking at the patient activity and financial results. Over the next year, we plan to introduce new techniques and expand the potential use of this technology. The Tim Upgrade has met and in many cases exceeded our high clinical and financial expectations.

MAGNETOM Symphony Maestro Class Upgraded to MAGNETOM Symphony, A Tim System [76 x 18]

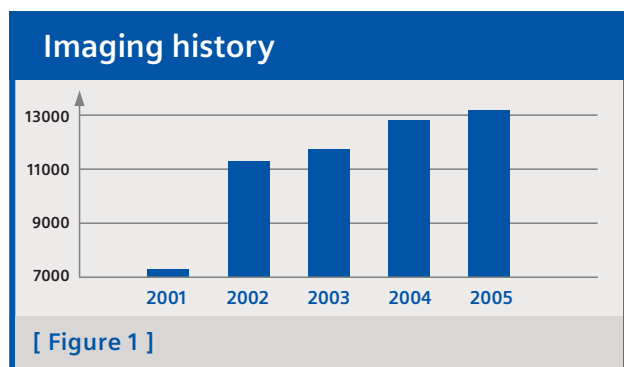
Michael J. Marra RT, Methodist Hospital, San Antonio, Texas, USA
Contributors: Martin Krebs RT, Fernando Nino RT, and Richard Finch

The MR story at Methodist Hospital

In 2001 we performed 7,270 MR procedures on an antiquated Siemens MAGNETOM SP 63 and a GE 5X. It was the consensus of the Radiologists and Administration that both systems be replaced with new technology to provide superior MR imaging. The MAGNETOM Symphony and MAGNETOM Sonata systems were chosen due to superior body, vascular, neuro and new cardiac capabilities.

The growth we experienced was unprecedented in our imaging history. In 2002 we performed 11,307 procedures, a 55.5 % increase, 51.9 % over projected growth. The majority of the growth was seen in body, vascular, neuro and cardiac. In 2003 we performed 11,745 procedures and began functional pre/post surgical planning. In 2004 we performed 12,811 procedures upgrading both MR systems to Maestro Class. In 2005 we performed 13,167 procedures (Fig. 1).

A system utilization report was generated and showed that a 99 % and 94 % capacity level had been achieved. It was felt that we had reached saturation, and that we could not provide the level of service that was expected by the clinicians and community. Siemens MR technology had advanced, and for Methodist Hospital to continue providing cutting edge imaging, the MAGNETOM Symphony Tim Upgrade was chosen.



Why was the MAGNETOM Symphony upgrade chosen?

The MRI department is two floors below ground level. It is very expensive to install or move a large piece of equipment. We did not want a long interruption in services. Therefore we felt that the upgrade would bring us to the next level of imaging without replacing an existing piece of equipment. The Tim platform provided the advanced template that could be upgraded in the future as technology advances.

Additional efficiency is what the MAGNETOM Symphony Tim upgrade added to our daily operations. The ease of moving from one body location to the next without repositioning patients or coils increased our patient throughput. We met our projected goal of 2 additional procedures a day in April 2006. In June 2006 we increased it to 3 procedures a day. We are on track to meet our projected goal of 4 procedures a day by August 2006. The projected 2006 procedure increase due to Tim is 618–738 exams.

Benefits of the MAGNETOM Symphony Tim upgrade

The new Tim Spine Matrix coil is larger and provides additional coverage, this gives technicians flexibility in positioning patients. The Tim Spine Matrix coil (Fig. 2A) also has 24 coil elements compared to the 6 coil elements on the MAGNETOM Symphony Maestro Class systems. This allows for easier positioning of the patients head or feet first.

The Tim Body Matrix coil is one of the advances the technicians commented about right away. The coil covers a larger area, has greater flexibility, built-in straps and a longer cable for easier positioning (Fig. 2B).

The 12-channel Head Matrix coil can reduce imaging time by 20–30 % with minimal decrease in quality. A 10 % increase in signal to noise across the board when switching from CP mode to 12 channels with no noticeable shading.

Coil set up

The coil locations are displayed anatomically on the display monitor, including the anterior coil location; this is not available on Maestro Class systems. The automatic coil selection indicates visually which coils are turned on. This reduces repeated scans by technicians who forgot to turn the anterior coils on. This also allows the technicians to see anterior coil placement and make adjustments if needed (Fig. 3A, 3B).

Maestro Class vs. Tim

Wireless Gating (Fig. 2C) reduces the patient positioning time on the table. Less set up time equals greater efficiency. Specific electrodes are needed to get proper contact. We found that the package that came with the upgrade worked the best. We purchased both types of electrodes from Siemens accessories.

Imaging benefits

Runoffs

Pre-upgrade Runoffs with coil setup and patient positioning were 60 minutes +/- . With MAGNETOM Symphony, A Tim System imaging time dropped to 35 minutes +/- with higher resolution on VIBE (Volume Interpolated Breathhold Examination) sequences and angiographies. We were able to increase the matrix on the VIBEs to 320 and to 384 on the angiographies.

Body

All Body work, including MRCP (MR cholangiopancreatography), renals and livers have a new HASTE (Half-Fourier Acquisition Single-Shot Turbo Spin Echo) sequence that is much sharper, with no time increase.

Spine, C, T & L

We were able to decrease our imaging time by 20 % on sagittal spine sequences and increase the resolution. We saw no change with axial spine imaging.

Neck

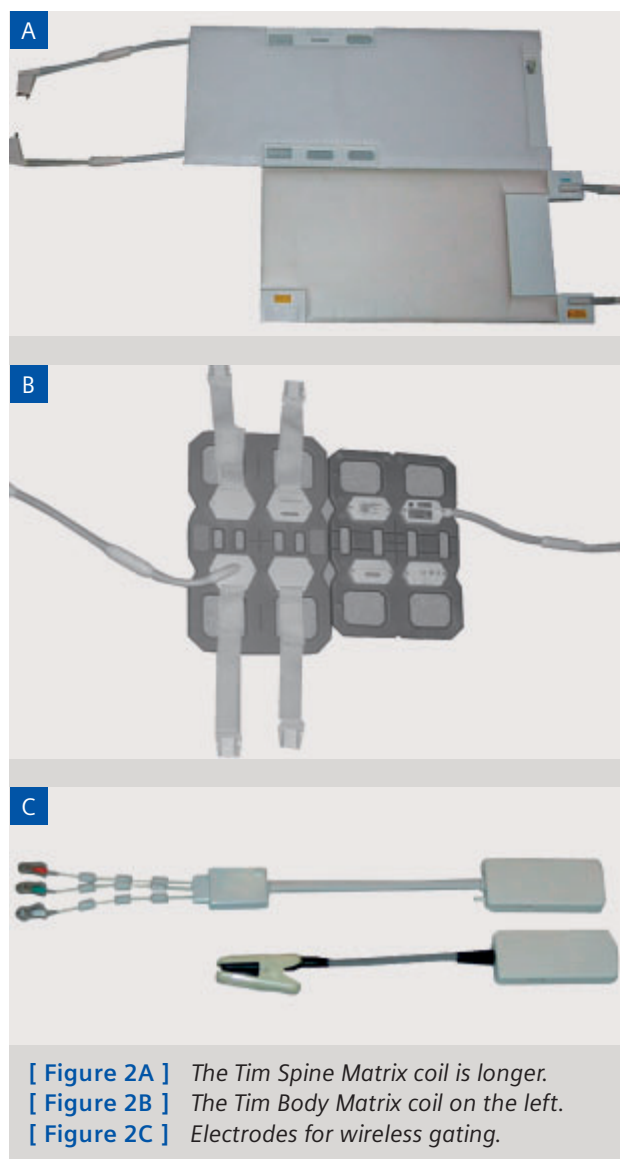
By utilizing iPAT (integrated Parallel Acquisition Technique) we were able to increase the number of slices by 30 % while maintaining the same time.

Heart

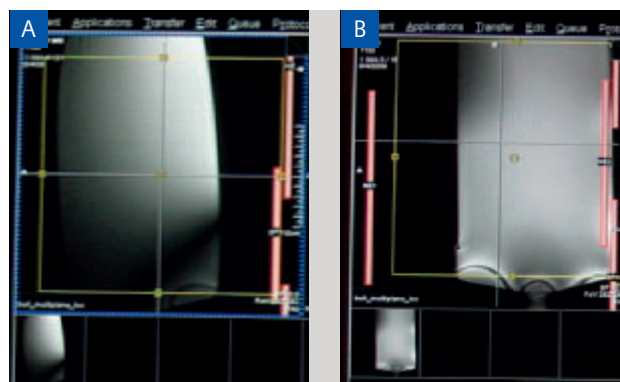
The Dark Blood HASTE sequence provides sharper images.

MPRAGE

We were able to reduce the time by 50 % when using iPAT. We choose to do this on difficult patients.



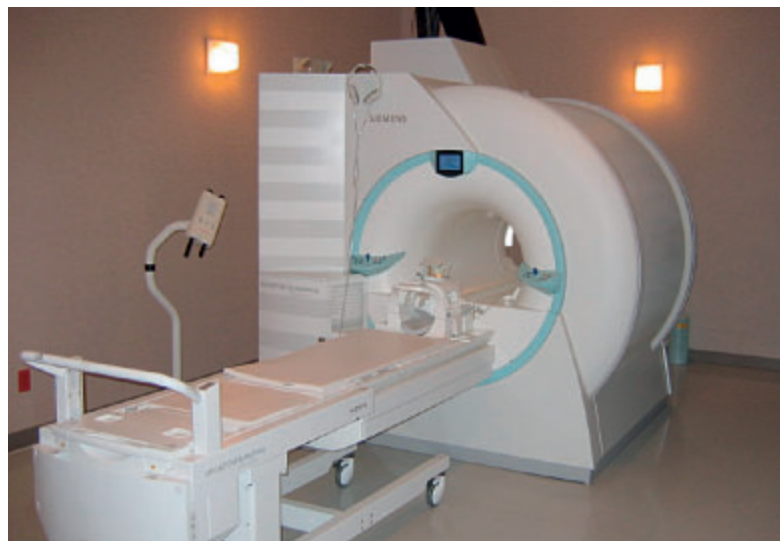[Figure 2A] The Tim Spine Matrix coil is longer.
[Figure 2B] The Tim Body Matrix coil on the left.
[Figure 2C] Electrodes for wireless gating.



[Figure 3A] Maestro Class
[Figure 3B] Tim (Total imaging matrix)



[Figure 4] *Methodist Hospital*



[Figure 5] *MAGNETOM Symphony, A Tim System in July 2006.*

Gadolinium-Bolus Carotids, Renals and Aorta

We had increased signal with coronal images while still maintaining the time using iPAT. We increased the aorta resolution from a 256 matrix to 384.

Radiologists' Comments

Neuro

Increased S/N utilizing the 12-channel Head Matrix coil in the 12-channel mode verses the CPU mode.

Image quality of MR Angiography (MRA) have increased with the 12-channel Head Matrix coil and the 8-channel Neck Matrix coil.

Body & Cardiac

MRCs are much sharper, greater coverage with the Tim Body Matrix coil.

Cardiac quality of the images on the MAGNETOM Symphony, A Tim System is equal to the 8-channel MAGNETOM Sonata Maestro Class scanner.

Upgrade time frame & Applications

The upgrade started on November 28th and was available for applications on December 15th, i.e. within 17 days. We were able to continue with only one scanner by reducing some of our outpatient scheduling slots during the week and increasing weekend availability.

Application training began on Thursday, December 15th and ended on Tuesday, December 20th.

The time it took for staff, 6 technicians, to feel comfortable and take advantage of the new capabilities consistently was on January 9, i.e. within 19 calendar days.

MAGNETOM Symphony, A Tim System, July, 2006

To date we are very happy with our decision to upgrade the MAGNETOM Symphony to Tim. We are still able to utilize the MRI Devices coils that we have invested in over the years. The technicians favor the MAGNETOM Symphony, A Tim System over the MAGNETOM Sonata, especially when multiple areas need to be imaged. This upgrade has extended the life of the MAGNETOM Symphony system (Fig. 4, 5).

Purchasing and installing the upgrade prior to the installation of our third scanner in June 2006 allowed for accelerated training on the new 3T MAGNETOM Trio, A Tim System.

Looking to the future

We would consider a similar upgrade for the MAGNETOM Sonata if Siemens moves in that direction.

Editor's remark:

An upgrade of MAGNETOM Sonata to MAGNETOM Symphony, A Tim System is now available.

*Results may vary. Data on file.

Tim Trio Upgrade Benefits

Jeff Zimmers RT, (R, MR) ARRT¹, Karen Ziadie, RT (R) ARRT²

¹Advanced Education Specialist, Siemens Medical Solutions, Inc., USA

²MR Clinical Specialist, Baptist Hospital MRI Department, Baptist Health South Florida, USA

In the recent months there has truly been a revolution for Siemens 3T users. 3T has moved from a “research only” environment to mainstream clinical MR imaging. This is possible due to the improvements and developments with the Siemens unique Tim technology, now available on MAGNETOM Trio, A Tim System and available for existing MAGNETOM Trio systems. Many Siemens customers have already upgraded to the Tim technology and their testimonies offer proof to the benefits of Tim.

Karen Ziadie is an MR Clinical Specialist from Baptist Hospital in South Florida and she offers the following insight:

Our upgrade experience

“In February 2006, we received the Tim upgrade on our MAGNETOM Trio” Karen states. “We were one of the first Trio systems to receive the Tim upgrade so a team of engineers (some from Germany along with our local service personnel) descended on our site and set to work. We had been informed that the upgrade would take three full weeks. We wondered why an upgrade would take that amount of time, we soon found out why. The engineers literally stripped the system of everything except the magnet. Every component was replaced, including the gradients, the rf transmitter, table, surface coils, even the computer.”

With Tim capabilities are expanded

The gradients and rf systems bring dramatic changes to the performance available at 3T. The TQ Engine gradients have similar peak and slewrate, however the gradient linearity improves to the best in the industry at 1.7% across 50cm, and the audio comfort of the Tim system reduces noise by up to 90%.

Previously the body coil limited the field of view to 40 cm, now with a full 50 cm field of view many users are able to scan the same protocols between their 1.5T Siemens scanners and the MAGNETOM Trio, A Tim System.

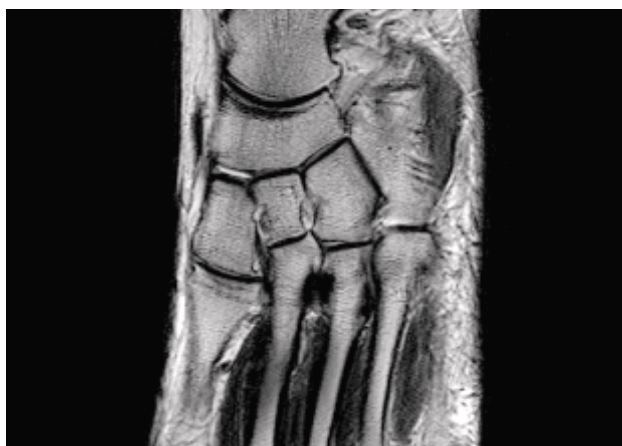Tim brings Matrix coils, as the MAGNETOM Trio before Tim relied solely on third party coils, and as a result was not able to be integrated to a level that allowed syngo GRAPPA to be implemented outside of the brain and 8-channel body coil.

New look

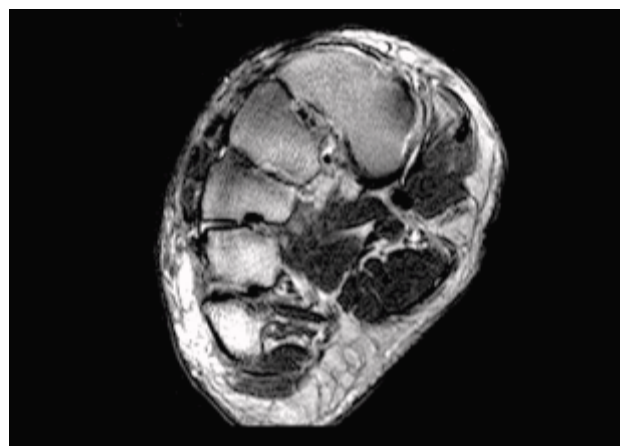
Oh what a difference! Our „new“ 3.0T Trio looks awesome! Now it looks like the high tech imaging machine that it is. In addition to the new high tech look, the magnet bore is also much shorter and therefore much more patient friendly.

Coils

With the Tim Matrix coils we can quickly and efficiently do multiple studies without taking the patient off the table and



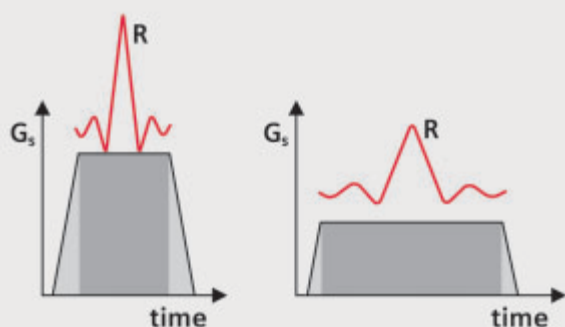
[Figure 1] T2-weighted Turbo Spin Echo (TSE) using the Body Matrix coil.



[Figure 2] T1-weighted Spin Echo using the Body Matrix coil.

VERSE Basics

Standard RF



Fast/high Power or Slow/low Power

without changing the coil configuration. Many of our patients have orders for brain, cervical, thoracic and lumbar spines, and sometimes hips. With the Matrix coils we can do all five studies without moving the patient and changing the coils. In addition, we can now use iPAT (integrated Parallel Acquisition Technique) with every coil.

The coils are also flexible. These high resolution foot images were acquired using the Body Matrix coil. Imaging times are very short and iPAT is used exclusively.

The images

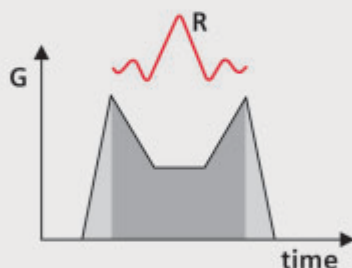
We immediately noticed how much nicer the images looked. The images now have more signal to noise than before Tim. We are able to take advantage of this increased signal by utilizing iPAT, thinner slices, and higher resolution factors.

We now routinely use 2 mm and 3 mm slice thicknesses for our brain and orthopedic studies. Many abdomen studies now employ a 3 mm or 4 mm slice thickness.

This knee scan was acquired using DESS (Dual Echo Steady State) and an isotropic voxel size of 0.6 mm. iPAT and high signal to noise allowed this scan to be acquired in just over four minutes. High resolution allows multiplanar reconstruction with no loss of resolution.

VERSE

VERSE RF pulse



Fast and low Power

Special Absorption Rate (SAR)

One of the big challenges with 3.0T imaging was SAR. Almost every protocol required the technologist to adjust the parameters as not to exceed the SAR limitations.

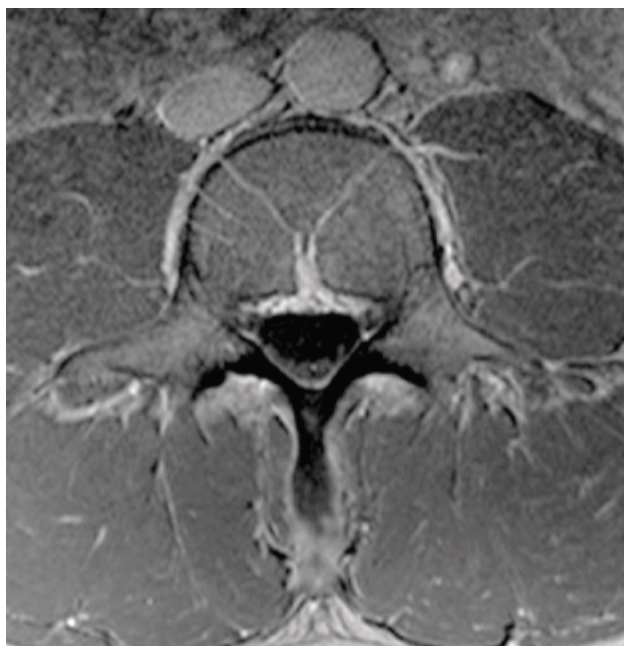
The Tim upgrade has reduced the challenge of SAR at 3T. We are able to achieve lower TR values without exceeding the SAR limitations, resulting in reduced scan times and protocols that run smoothly without technologist adjustments required. With the new operating system also comes an increase to the number of SAR reduction methods. In addition to Hyper Echo, GRAPPA, and SPACE there are now low SAR pulses for ceMRA, VERSE is available, which through a different gradient pulse shape dramatically lowers rf power.

T1 contrast

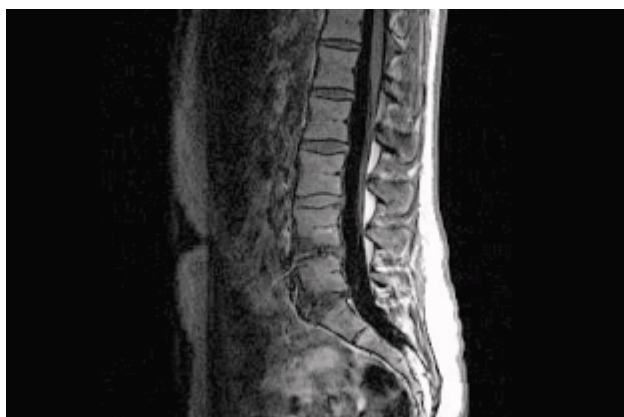
The upgrade has provided greatly improved T1 contrast abilities. As a result of reduced SAR we are able to utilize TSE-T1 pulse sequences for spine imaging and we consistently obtain good T1 contrast in the spine.

The Spine Matrix coil provides a major improvement in signal to noise and iPAT imaging. The previous coil did not offer iPAT capabilities.

T1 DarkFluid imaging as well as VIBE sequences (Volume Interpolated Breathhold Examination) demonstrate excellent T1 contrast and very high signal to noise. High resolution spine imaging has now become reliable and very fast for clinical imaging.



[Figure 3] T1 3D VIBE .3 x .3 x 1 mm resolution.



[Figure 4] T1 TIRM DarkFluid.

Abdomen examinations

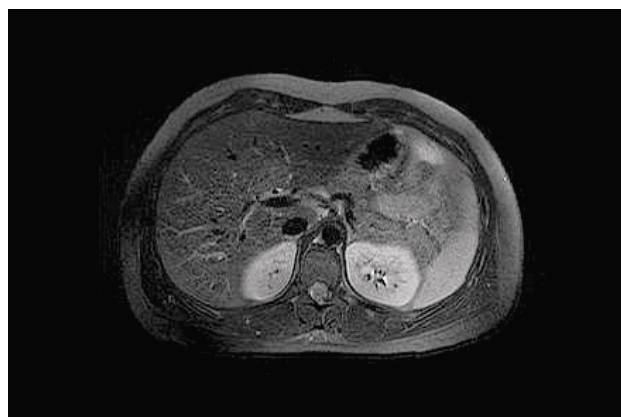„Abdominal studies have been difficult on the 3.0T. We were very pleasantly surprised by the quality of the abdominal images after the upgrade, they were excellent. Breathholds are shorter and we are now able to take advantage of the extra signal 3T provides by using higher resolution factors. Additionally, the T1 contrast improved, and we have seen dielectric shading substantially reduced.

Our radiologists liked the images so much we now routinely do abdomen studies on our 3.0T. In fact, there are some body studies that our radiologists definitely prefer to be done on the 3.0T such as adrenal, urography and prostate studies.” says Karen Ziadie.

„Sequence development and Tim have improved signal to noise, and reduced artifacts since the upgrade was completed. “

This upgrade is, all in all, the best upgrade that we have ever received. Image quality, scan times and throughput on the MAGNETOM Trio, A Tim System are greatly improved and we routinely obtain spectacular images. The 3.0T is now a fully functional clinical system.”

Karen and I had a great experience with the Tim Trio upgrade. Many other sites have as well. Similar results have been experienced on the Symphony Tim upgrades, too. The very reliable MAGNETOM Symphony is now a cutting edge system with the Tim upgrade.



[Figure 5] T2 TSE RESTORE with PACE (Prospective Acquisition CorrEction).

BODY

Dynamic Contrast Enhanced MRI*

Smita Kori, Bhavin Jankharia M.D.

Jankharia Imaging, Mumbai, India

Variations in microvascular structure and pathophysiology give rise to temporospatial variation in enhancement pattern, which provides valuable information on tissue characteristics. Dynamic contrast enhanced MRI (DCE-MRI) is widely used nowadays for lesion characterization. It is also used for monitoring therapy and for detection of residual or recurrent tumor.

Pathophysiology of the contrast enhancement

Malignant tumors enhance faster than normal tissue. The enhancement of a lesion depends on the microvascular density, endothelial permeability and extravascular space size. In tumors, development of neovasculature results from angiogenesis. The multifunctional cytokine vascular endothelial growth factor (VEGF), also known as vascular permeability factor (VPF), induces angiogenesis and strongly increases the microvascular permeability.

Release of the promotor substance stimulates sprouting of endothelial cells from the walls of pre-existing small vessels, till the sprouts encounter another vessel with which they connect, allowing blood to circulate. The vesiculo-vascular organelles (VVO) are grape-like clusters that span the entire thickness of the vascular endothelium connecting between the vascular lumen and the extravascular space [1]. The number of VVOs and leakage rate are regulated by VEGF. The VVOs might be an important pathway for Gadolinium-chelate MRI contrast agent leakage [2]. The morphology of the malignant tumors is bizarre and the capillaries are coarse, irregularly constricted/dilated and distorted. The capillary walls have numerous openings, widened inter-endothelial junction and discontinuous or absent basement membranes. These defects make tumor capillaries leaky. Slow growing benign tumors on the other hand, show regular vascular morphology.

In many tumor types including breast, lung, prostate and head and neck cancers, measurements of microvasculature density (MVD) on histopathological samples correlate with clinical stage and act as prognostic value. On this basis, it has been suggested that DCE-MRI may also be able to provide independent indices of angiogenic activity and therefore act as a prognostic indicator.

Technique

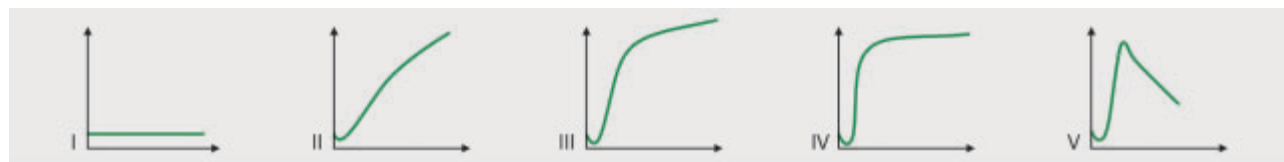
Contrast is administered through a peripheral vein – preferably the antecubital vein on the right side. A single dose of contrast (0.1 mmol/kg) of a standard Gd-chelate is administered at a rate of 4 ml/sec, using a pressure injector, followed by a chaser injection of 20–30 ml of saline at the same flow rate to empty the draining vein.

Data acquisition

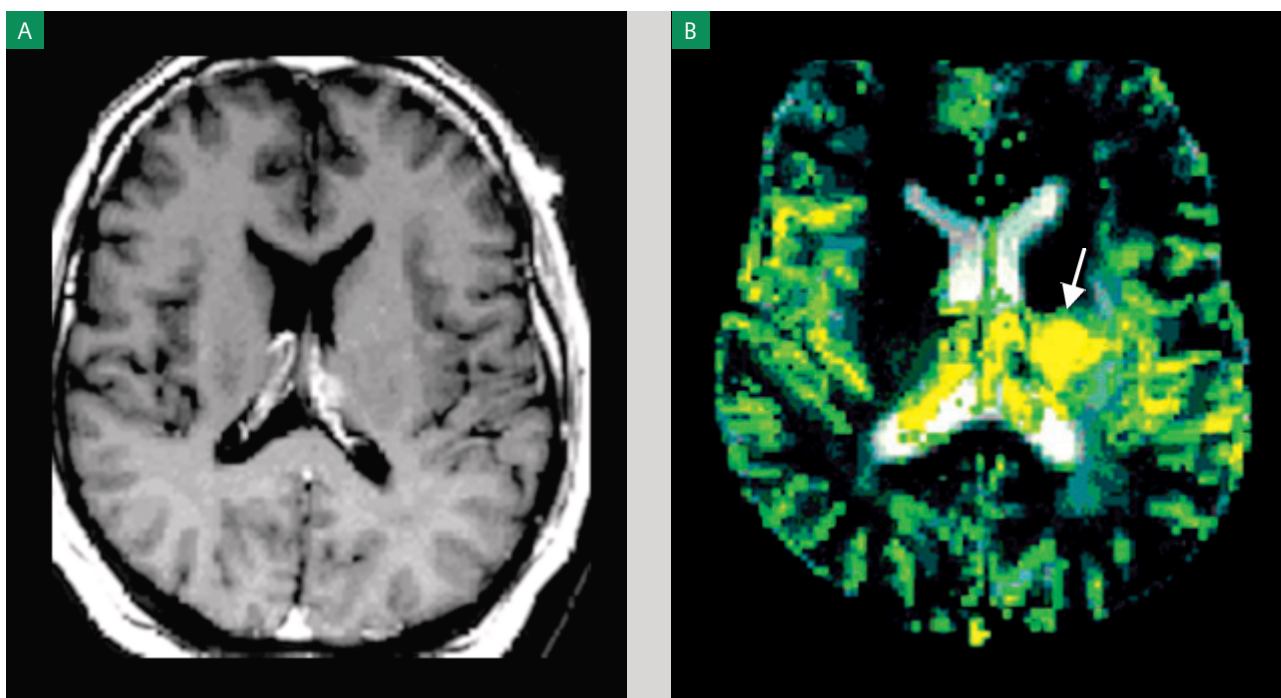
While analyzing the lesion, it is important to include the entire volume of the tumor in the region of interest. An artery should also be included in the region of interest for comparison of the signal intensity in the plasma to the signal intensity in the lesion, which in turn depends on the density of the microvasculature, capillary permeability and size of the extravascular space.

There are two generic approaches for data acquisition

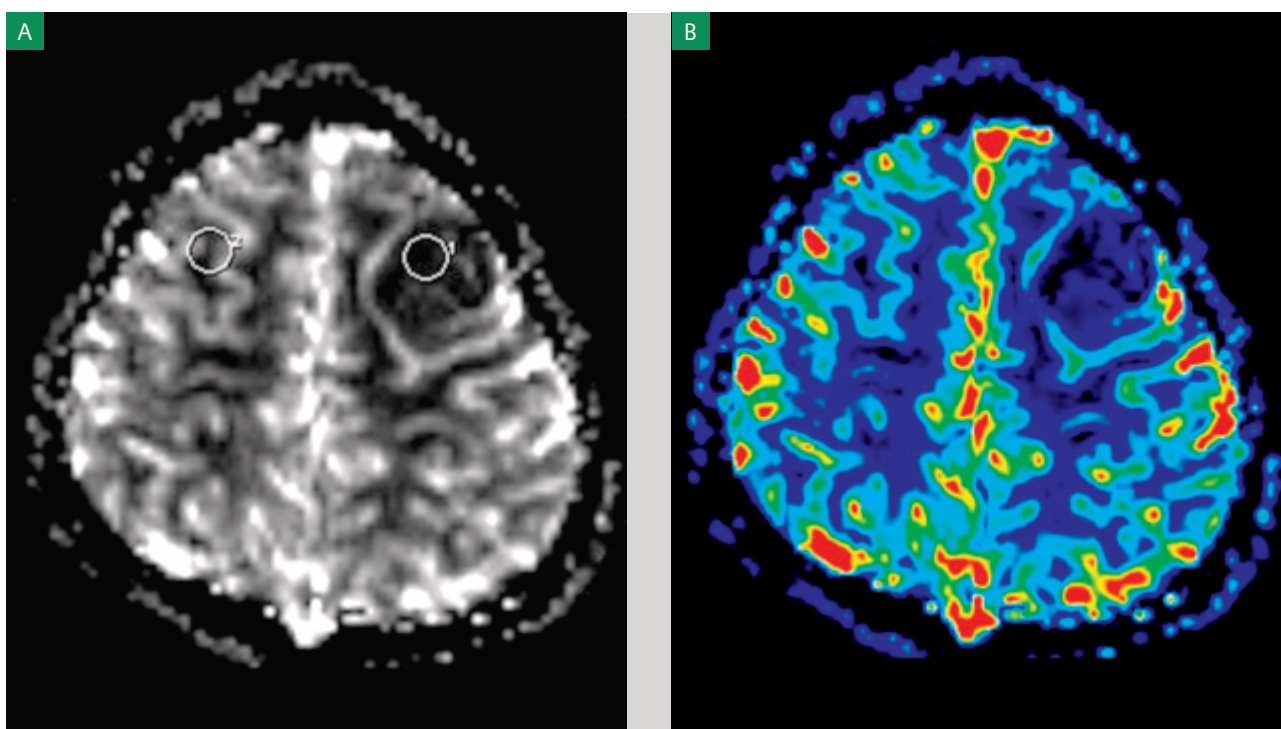
1. Susceptibility based techniques use T_2/T_2^* sequences. When the bolus of exogenous contrast is injected, its paramagnetic property introduces a decrease in the T_2/T_2^* relaxation properties by dephasing. Associated with susceptibility induced gradients surrounding the paramagnetic contrast agents, the effect is significant where the contrast is compartmentalized. It has important applications in brain perfusion due to the blood brain barrier.



[Figure 1] Mean curves. Type I, II, III, IV and V curves are well-seen.



[Figure 2 A, B] **Glioblastoma multiforme.** The contrast enhanced T1-weighted axial image (A) shows a focal lesion (arrow) in the left corona radiata, which does not enhance. However the RCBV map (B) revealed elevated CBV (arrow), suggesting malignancy. A targeted biopsy revealed a glioblastoma multiforme.



[Figure 3 A, B] **Low-grade glioma.** A left frontal lesion is seen (A), which shows a maximum normalised CBV ratio (B) of 0.19, compared with the contralateral white matter, suggesting a low-grade tumor.

- Dynamic relaxivity contrast enhanced MRI uses T1-weighted images to detect the relaxivity effects of the contrast agent. Thus the intra and extravascular contrast will raise signal intensity.

Sequences used:

For brain perfusion: 60 measurements over a period of 1.35 min at TR/TE: 1490/40, slice thickness: 5 mm, field of view (FoV): 230, matrix: 128 x 128, EPI (echo planar imaging) factor: 128, bandwidth: 1502.

Dynamic contrast enhanced tumor protocol for the rest of the tissues: 20 measurements over 5 min, at TR/TE: 3.13/1.13, slice thickness of 1.2–2 mm, FoV: 280, slab thickness 64, matrix: 256 x 140, bandwidth: 420.

Evaluation of the data

Postprocessing is done using dedicated software for image subtraction, multiplanar reconstruction (MPR), maximum intensity projection (MIP), signal intensity-time curve analysis from relaxivity based T1-weighted sequences and mapping rCBV (relative cerebral blood volume), rCBF (relative cerebral

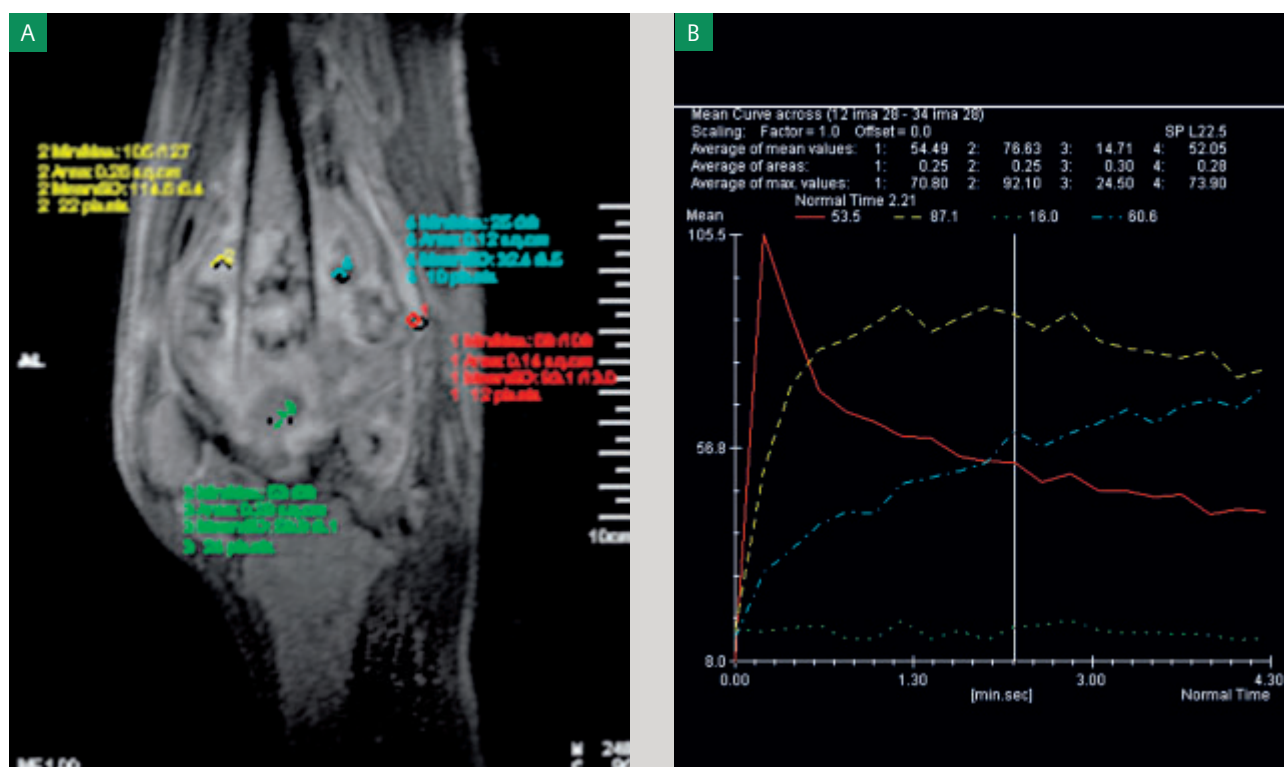
blood flow), MTT (mean transit time) from susceptibility-weighted T2/T2* sequences. Whichever the approach selected, careful inspection of the original dynamic contrast series images is important. The signal intensity-time curve contains information in terms of amplitude and time of arrival of the contrast and curve slope. It is a semiquantitative method of analyzing the vascular density, permeability of vessels and size of the extravascular space. The various patterns have been classified into 5 basic types (Fig. 1).

Indications

Brain tumors

In gliomas, tumor capillary blood volumes measured by DCE-MRI have shown to correlate with and predict tumor grade [3]. The rCBV maps identify the areas of malignant transformation or tumor dedifferentiation. This also helps to more accurately target stereotactic biopsy (Fig. 2).

The rCBV measurements help in differentiating high grade from low grade glioma. The ratio of rCBV (tumor / rCBV in normal white matter) in high grade gliomas is 3.33 while for low grade gliomas is 1.51 (Fig. 3).



[Figure 4 A, B] **Osteosarcoma.** A mid-sagittal T1-weighted contrast-enhanced image (A) was chosen for analysis. The heterogeneity is well seen. The red curve is the arterial curve obtained through the popliteal artery for reference. The yellow and blue curves are through solid tissue, showing type V and type III patterns of enhancement. Areas of necrosis are also seen, as shown by the green curve, which is flat.

The rCBV measurements also help to differentiate between primary gliomas and a solitary cerebral metastasis depending on the difference in peritumoral rCBV measurements. In metastases, the peritumoral vasogenic edema is due to extravasation of the contrast while in high grade gliomas, there is peritumoral edema and tumor cell infiltration.

DCE-MRI helps to differentiate between extra-axial tumors and intra-axial tumors as extra-axial tumors have increased rCBV. Absence of neovascularization in malignant lymphoma leads to decreased rCBV thus helping in differentiating it from glioma.

The rCBV values for tumefactive demyelinating disease are low, ranging from 0.22–1.79 (n=12), with a mean of 0.88 \pm 0.46, compared to intracranial glioma with rCBV values of 1.55–19.22 (n=11) with a mean of 6.47–6.56 [4].

Bone and soft tissue tumors

The diagnosis of a bone tumor is made on the plain radiographs. On MRI, the radiologist is required to report on the staging, response to therapy and in the detection of recurrent / residual tumor.

Osteosarcoma is the most common childhood tumor. Pre-operative chemotherapy has produced dramatic improvement in the prognosis of the disease. Response to chemotherapy is considered good if there is at least 90% tumor cell necrosis. Mean curve analysis from T1-weighted dynamic sequences in the region of interest are helpful in characterization of primary soft tissue tumors by defining the enhancement pattern of the tumor and in approximately defining the percentage of necrotic tissue for bone tumors [6]. Mean curve analysis helps to evaluate the response to initial chemotherapy after 2 cycles, as with good response, the size of the tumor will

decrease and the area of necrosis will increase. The rapidly proliferating areas show a type V curve, viable soft tissue with an increase in the extravascular space, type III, viable marrow with stable micro-circulation type IV and necrosis, a type I curve (Fig. 4). The mean curve analysis also helps to evaluate residual / recurrent tumor tissue which will show a type V/IV curve.

The percentage of tumor necrosis following pre-operative chemotherapy has predictive value of disease free survival. This is especially important with Ewing's sarcoma/PNET and osteosarcoma.

Other Tumors

Various studies have been performed to evaluate the application of mean curve analysis in the liver, bladder, prostate and bone and joint pathologies.

A study was conducted by Workie [7] to quantify dynamic contrast enhanced MR imaging of the knee in children with juvenile arthritis based on pharmacokinetic modeling. This helped to monitor the degree of inflammation and therapeutic response during the early phase. This method can also be applied to adults with rheumatoid arthritis. In bladder tumors, DCE-MRI helps in staging and predicting tumor response [8]. Using DCE-MRI, analysis of microvascular density and evaluation of the vascular characteristics can be done pre-operatively in cases of carcinoma of the prostate [9].

DCE-MRI studies were also performed to analyze perfusion changes in advanced hepatocellular carcinoma treated with antiangiogenic agents [10].

*The information about this product is preliminary.

The product is under development and not commercially available in the US, and its future availability cannot be ensured.

References

- [1] Carmeliet P, Jain RK. Angiogenesis in cancer and other diseases. *Nature* 2000; 407: 249–257.
- [2] Dvorak AM, Kohn S, Morgan ES, Fox P, Nagy JA, Dvorak HF. The vesiculo-vacuolar organelle (VVO): a distinct endothelial cell structure that provides a trans cellular pathway for macromolecular extravasation. *J Leukoc Biol* 1996; 59: 100–115.
- [3] Aronen HJ, Gazit IE, Louis DN et al. Cerebral blood volume maps of gliomas: comparison with tumor grade and histological findings. *Radiology* 1994; 191: 41–51.
- [4] Frazzini et al Dynamic contrast enhanced T2*-weighted echo-planar perfusion MR imaging of primary CNS lymphoma and glioblastoma multiforme. Proceedings of 37th annual meeting of American society of Neuroradiology, American society of Neuroradiology, San Deigo, p 185.
- [5] Daniel BL, Yen YF, Glover GH, Ikeda DM, Birdwell RL, Sarwer-Glover AM, Black SK, Jeffery SS, Herfkens R.. Breast disease: Dynamic spiral MR imaging. *Radiology* 1998; 209: 499–509.
- [6] Dyke JP, Panicek DM, Healey JH et al. Osteogenic and Ewing sarcomas: estimation of necrotic fraction during induction chemotherapy with dynamic contrast-enhanced MR imaging. *Radiology* 2003; 228: 271–278.
- [7] Workie DW, Dardzinski BJ. Quantifying dynamic contrast-enhanced MRI of the knee in children with juvenile rheumatoid arthritis using an arterial input function (AIF) extracted from popliteal artery enhancement, and the effect of the choice of the AIF on the kinetic parameters. *Magn Reson Med* 2005; 54: 560–568.
- [8] Tekes A, Kamel I, Szarf G, Schoenberg M, Nasir K, Thompson R, Bluemke D. Dynamic MRI of bladder cancer: evaluation of staging accuracy. *AJR* 2005; 184: 121–127.
- [9] Schlemmer HP, Merkle J, Grobholz R, Jaeger T, Michel MS, Werner A, Rabe J, van Kaick G. Can pre-operative contrast-enhanced dynamic MR imaging for prostate cancer predict microvessel density in prostatectomy specimens? *Eur Radiol* 2004; 14: 309–317.
- [10] Wang J, Chen LT, Tsang YM, Liv TW, Shih TT. Dynamic contrast-enhanced MRI analysis of perfusion changes in advanced hepatocellular carcinoma treated with an antiangiogenic agent: a preliminary study. *AJR* 2004; 183: 713–719.

A Practical Approach to Lung MRI at 1.5T

Jürgen Biederer, M.D.^{1,2}; Michael Puderbach, M.D.²; Christian Hintze, M.D.²

¹University Hospital Schleswig-Holstein Campus Kiel (UKSH), Department of Diagnostic Radiology, Kiel, Germany

²German Cancer Research Center (DKFZ), Department of Radiology, Heidelberg, Germany

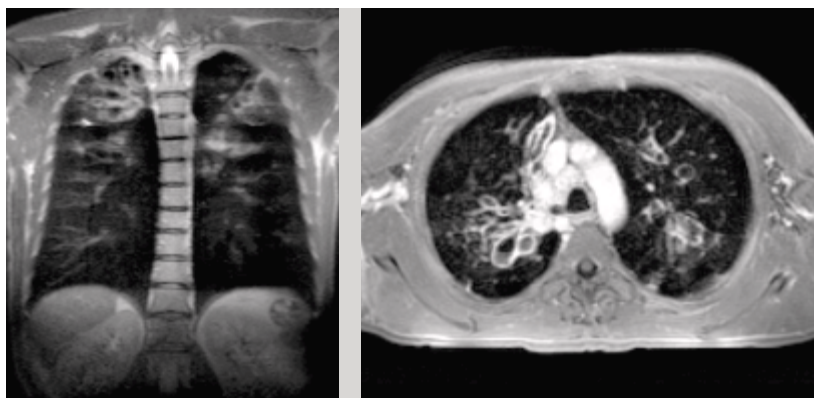
Introduction

The value of MRI in imaging cardiac and large vessel disease is widely accepted, but the largest organ of the thorax, the lung, is usually investigated with X-ray and CT. MRI suffers from well-known limitations such as constant artifacts from heart pulsation or respiration and the low signal intensity of the aerated lung. This results from low overall proton density in combination with high susceptibility artifacts at air-tissue interfaces. The broadly accepted routine indications for MRI of the chest are instead focused on soft tissue processes such as chest wall masses or tumors of the mediastinum. The excellent contrast and the capacity of MR to produce cross sectional images or three-dimensional data sets in any orientation designate it as the ideal tool for this purpose. However, X-ray and CT are constantly criticized for the associated radiation exposure, in particular where applied for frequent follow-up examinations of children, or during pregnancy. A non-invasive method for follow-up of lung diseases during clinical trials or for physiologic research is therefore highly desirable. Since the recent technical developments in the field have contributed to overcome the well-known limitations of lung MRI, we can now recommend a comprehensive routine imaging protocol for the whole chest including lung parenchyma diseases.

Clinical method description

To match the criteria of a comprehensive imaging protocol for clinical routine, the recommended protocol needs to keep within a reasonable time frame of 15 to 30 minutes. It uses fast sequences for single- or multiple breathhold imaging and does not require cardiac or respiratory triggering. This facilitates patient positioning and shortens the room time. Limited information on cardiac pathology is provided with the single shot T2-HASTE and the free-breathing TrueFISP. If further cardiac imaging is planned, ECG-triggering would be needed. The key to high image quality without respiratory motion artifacts is appropriate instruction of the patient. Nevertheless, the T2-HASTE as well as the free breathing TrueFISP are robust against breathing motion and can therefore be applied even with completely uncooperative patients. The vessel imaging capacity of the TrueFISP will even allow detection of large central pulmonary emboli in dyspneic patients. Only one sequence – the optional high-resolution – T2-TSE uses a navigator.

We present below a basic protocol for non contrast-enhanced MRI of the lung, followed by recommendations for additional contrast-enhanced and functional imaging (table 1). This would be applicable to children from 8–10 years and adults. For younger children, spatial resolution and Field of View



[Figure 1] 45-year-old male with cystic fibrosis of the lung. Bronchiectases in both upper lung lobes with mucous plugging being represented by bright signal on the T2-weighted HASTE (left image) and intermediate signal of the mucus within the bright signal of the contrast-enhanced bronchus walls in the transverse 3D-GRE (VIBE) sequence. For recommended sequence parameters see table 1.

(FoV) would need to be adjusted. All components are based on common MR sequence components of current standard installations. In detail, they refer to 1.5T MAGNETOM Avanto protocols and a Body Matrix coil for thoracic imaging, but they would also be applicable to MAGNETOM Sonata and MAGNETOM Symphony installations with minimal adjustments. Where parallel acquisition techniques are not available, multi-breathhold acquisitions can be used instead. If a navigator is not available, a respiration belt could be used instead. For all coronal sequences (except for perfusion and angiography to save reconstruction time), distortion correction ("large FoV") is activated and excitation order is interleaved, where appropriate.

Basic protocol for non-contrast enhanced MRI of the lung

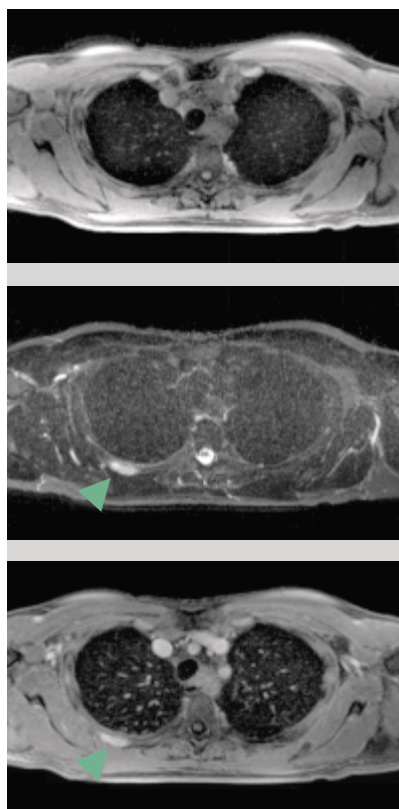
The imaging protocol starts with a gradient echo localizer in inspiration. The first sequences are acquired in breathhold, usually starting with the coronal T2-HASTE followed by the transverse T1-weighted 3D-GRE (VIBE). After this the first set of coronal SS-GRE sequences is acquired in free breathing, giving the patient some time to recover from the breathhold maneuvers. This is followed by the T2-TIRM image series, which is acquired with multiple breathholds. Anatomic cov-

Indications for the basic protocol

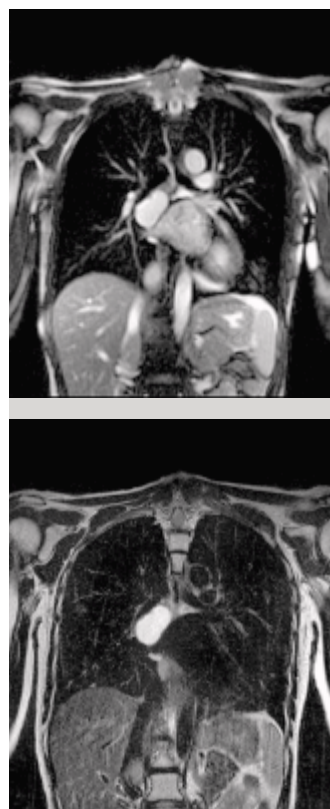- pneumonia (T2-HASTE, TrueFISP)
- atelectasis (all sequences)
- cystic fibrosis (T2-HASTE, VIBE)
- tuberculosis (T2-HASTE, TrueFISP)
- nodule detection (TIRM, T2-HASTE, VIBE)
- mediastinal masses (VIBE, T2-TIRM)
(lymphoma, goiter, cyst (Fig. 4), thymoma)
- interstitial lung disease (plus HR T2-TSE)
- diaphragmatic paralysis (TrueFISP)
- acute pulmonary embolism (TrueFISP)

erage should include the upper abdomen with liver and adrenal glands. This basic protocol may be completed with the single slice dynamic SS-GRE series for diaphragmatic function. For this series, the patient is instructed to breathe deeply. Total room time up to here will be approximately 15 minutes.

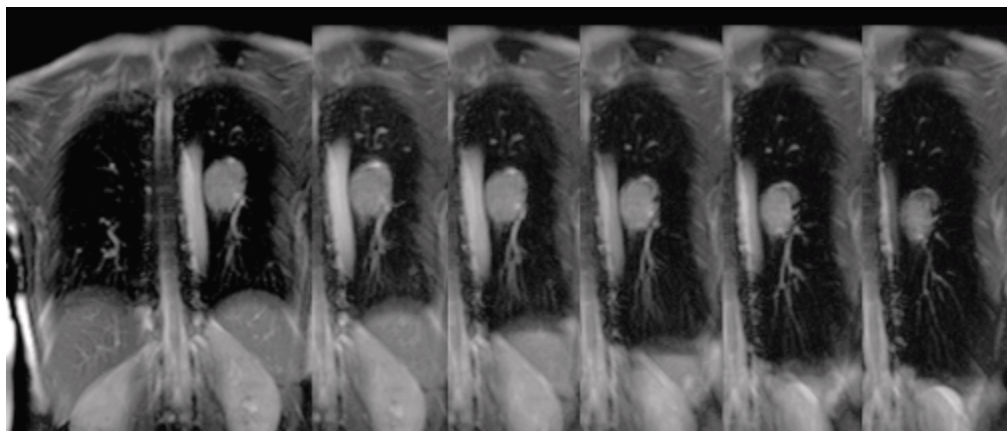
This basic protocol covers a range of routine indications, e.g. follow-up examinations in children with cystic fibrosis (Fig. 1) [1]. The sensitivity for lung nodules larger than 4 mm ranges



[Figure 2]
62-year-old male with suspected bronchial carcinoma. Bone metastasis of the third right rib hardly detectable on the non-contrast enhanced VIBE, but with high signal on T2-TIRM and intensive enhancement after i.v. administration of contrast material.



[Figure 3]
46-year-old female with suspected bronchial carcinoma after incidental detection of a hilar mass on chest x-ray. The single image of the coronal TrueFISP series (upper image) and the high resolution navigated T2-TSE image (lower image), both acquired during free breathing, show a well defined cystic formation in the lower part of the right hilus with water-equivalent signal of the content. Histology after surgical resection confirmed a bronchogenic cyst. For recommended sequence parameters see table 1.



[Figure 4]
48-year-old female with suspected lung cancer. The dynamic TrueFISP series in coronal position demonstrates tumor and diaphragm motion during a deep inspiration maneuver. (left to right). For recommended sequence parameters see table 1.

between 80 and 90% and reaches 100% for nodules larger than 8 mm [2, 3]. Depending on the water content, nodules can be detected either on the VIBE or on the HASTE and T2-TIRM images. Atelectasis and tumor can be well distinguished on T2-weighted sequences, especially if the high resolution T2-TSE is added. If MRI is applied for staging of lung malignancies with non-contrast enhanced images, T2-TIRM is an obligatory protocol component for the detection of bone metastases [4] (Fig. 2). The dynamic coronal TrueFISP acquisitions allow estimating diaphragmatic function and the mobility of intrathoracic masses (Fig. 3). This particular part provides additional functional information to the morphologic images and is one of the essential differences between lung MRI and any other common imaging modalities [5].

Basic protocol including contrast enhanced MRI of the lung

For routine purposes it might appear sufficient to conclude the study, if the non-enhanced scans show completely normal findings. Nevertheless, application of i.v. contrast material markedly improves the diagnostic yield of 3D-GRE imaging of the lung by the clearer depiction of vessels, hilar struc-

tures and pleural enhancement. Parenchymal disease and solid pathologies are also enhanced. Thus, a study to exclude pulmonary malignancies e.g. for staging purposes should usually comprise a contrast enhanced series, preferably with a fat-saturated 3D-GRE sequence. Contrast enhancement is also necessary for pleural processes (empyema, abscess, metastatic spread of carcinoma, mesothelioma) or for the further evaluation of solid masses, as well as for functional imaging or angiography. If it is intended to include a contrast-enhanced series, the 3D-GRE (VIBE) sequence in the pre-contrast series should be applied with fat-saturation to allow for a direct comparison of contrast uptake. Contrast material: 0.2 mmol/kg i.v. per hand or power injector. The contrast enhanced VIBE extends the range of indications for the protocol towards lung cancer and malignant and infectious pleural processes [6]. It is important to know that calcified nodules or masses may be invisible either on the non-contrast enhanced as well as on the contrast enhanced images. In most cases, this reflects benign findings but might be crucial e.g. for the staging of osteosarcoma.

Lung perfusion imaging

The basic principle of contrast-enhanced perfusion MRI is a dynamic MR image acquisition following an intravenous bolus injection of a paramagnetic contrast agent. Perfusion MRI of the lung requires a high temporal resolution in order to visualize the peak enhancement of the lung parenchyma. The recommended fast acquisition technique is based on iPAT (integrated Parallel Acquisition Techniques) and data sharing. It allows for a 3D data acquisition with a temporal resolution of 1.5 seconds per image [7]. The resulting 4D-data set can be displayed with the "Mean Curve" application, which allows one to scroll through the series in a single image position or to scroll through the images of a 3D data set obtained at a single time point. A quick, semi-quantita-

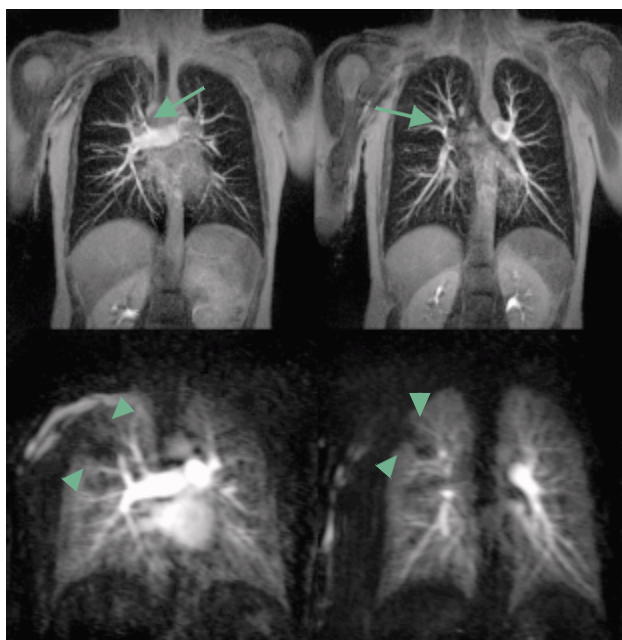
Indications for additional CE-VIBE

- lung cancer
- pleural spread of carcinoma
- pleural effusion of unknown origin
- mesothelioma
- neurogenic tumours of the mediastinum
- mediastinitis
- vasculitis (e.g. Wegener's disease)

Indications for perfusion MRI

- emphysema (indirectly)
- pulmonary hypertension
- acute and chronic pulmonary embolism

tive analysis of contrast-enhanced perfusion MRI data consists of the calculation of signal time curves, SNR and contrast-to-noise ratios (CNR) using region-of-interest (ROI) analysis of the signal of the lung tissue. For documentation, contrast-enhanced 3D perfusion MRI is usually processed by subtraction of mask image data acquired before contrast bolus arrival (Fig. 5). Since the acquisition time and diagnostic yield are at least the same as for a test bolus, the dynamic perfusion series may be used to prepare the angiogram. A disadvantage compared to the test bolus method is the additional time needed for image post-processing and the slightly



[Figure 5] 39-year-old female with suspected pulmonary artery hypertension. 10 mm MIP reconstruction of the coronal CE-MRA (3D-FLASH; upper pair of images) demonstrating small emboli in the right upper lobe artery as incidental finding (arrows). 20 mm MIP of the subtracted perfusion sequences (TREAT Perfusion, lower pair of images) show corresponding hypoperfusion in dependent parts of the right upper lung lobe (arrowheads). For recommended sequence parameters see table 1.

higher amount of contrast medium (0.07 mmol/kg patient weight). To allow for an exact calculation of the time points for the angiograms, injection speed and the volume of the bolus plus sodium chloride chaser should be the same as for the following angiogram.

Pulmonary angiography

Contrast-enhanced MRA uses a T1-weighted 3D-FLASH acquisition after intravenous injection of a paramagnetic MR contrast agent. A short TR allows for breathhold acquisitions and a short TE minimizes background signal and susceptibility artifacts. The flip angle of 25 degree produces a high contrast between lung tissue and the vessels. Adequate breathhold and exact timing of the contrast agent (0.1 mmol/kg at 5 ml/s followed by a 20 ml sodium chloride chaser, time to center 8.7 s) with an automatic power injector are essential prerequisites. Three acquisitions (non-contrast enhanced, centered on the peak signal of the pulmonary artery and centered on the peak signal of the aorta) are appreciated. For comprehensive viewing, we recommend use of the 3D-tool for multi planar reformation (MPR) or maximum intensity projections (MIP). The combination of 4D MRA perfusion and CE-MR angiography provides a useful alternative to perfusion scintigraphy and CT angiography, thus extending the range of indications for lung MRI by a considerable number of clinical conditions, e.g. suspected pulmonary embolism in pregnancy [8]:

Indications covered by lung CE-MRA

- pulmonary hypertension
- acute and chronic pulmonary embolism
- AV-malformation (e.g. M. Osler)
- pulmonary sequestration
- Swyer-James-Syndrom
- pulmonary artery aneurysms
- pulmonary vein anomalies
- masses of the hila
- tumour invasion a. pulmonalis /aorta

Respiration-triggered high resolution T2-TSE

Further options to extend the standard protocol are T1- and T2-weighted Spin Echo (SE) or Turbo Spin Echo (TSE) sequences with respiratory triggering (or gating). T1-weighted images are usually recommended for the detection of lymph nodes and tumor infiltration into the chest wall, but only the T2-weighted sequences contribute to the evaluation of lung

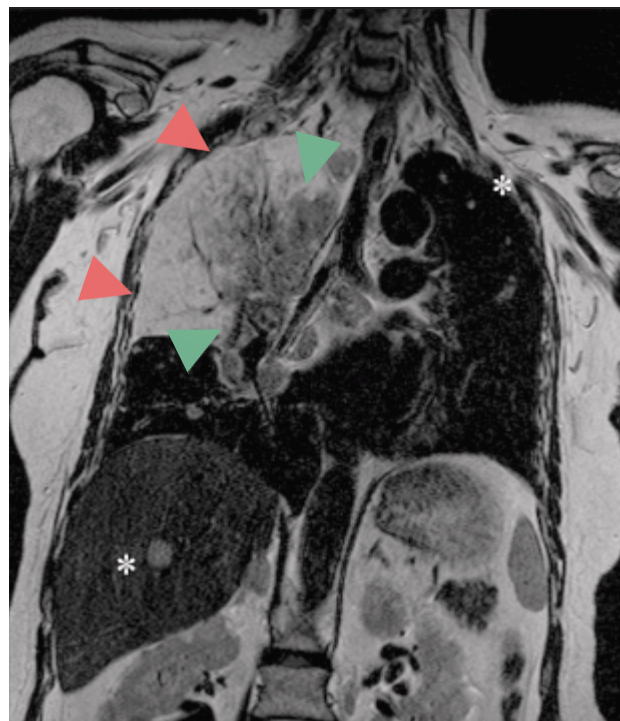
Indications to add HR-TSE

- interstitial lung disease
- lymphangitic spread of carcinoma
- differentiation of tumour/atelectasis
- masses with chest wall infiltration
- collateral findings (liver, adrenals)

parenchyma pathology and provide equal information about the chest wall and mediastinum. Since these triggered sequences are time-consuming, we recommend the inclusion of only one additional T2-TSE series into the protocol, since all aspects are covered by the previous sequences.

Conclusion

The proposed imaging protocol covers a wide range of clinical indications for lung imaging and may be used for routine purposes whenever it is mandatory to avoid radiation exposure as far as possible (e.g. in childhood and pregnancy). Moreover, its potential capacity to add functional information such as analysis of diaphragm motion and lung perfusion studies make it more than just a surrogate for chest x-ray and CT. The suggested sequences for lung MRI can be easily set up on state-of-the-art MR scanners by using the Phoenix sample files from www.siemens.com/MAGNETOM-World.



[Figure 6] 50-year-old female with large metastases from breast cancer. The T2-weighted respiration triggered TSE images show a clear difference of tumor (intermediate signal intensity on T2-weighted image green arrowheads) and atelectatic lung (high signal on T2-weighted image red arrowheads). Further pulmonary and hepatic metastases are indicated by stars. For recommended sequence parameters see table 1.

Abbreviations

CE	Contrast enhanced
GRE	Gradient echo
HASTE	A Turbo Spin Echo technique
HR	High resolution
MRA	MR Angiography
SS GRE	Single shot gradient echo
TIRM	Turbo Inversion Recovery Magnitude
TrueFISP	a gradient echo sequence that provides the highest signal of all steady state sequences. FISP: Fast Imaging with Steady Precession
TSE	Turbo spin echo
TWIST	Time resolved 3D MR angiography
VIBE	Volume Interpolated Breathhold Examination

Further Reading

- [1] Eichinger M, Puderbach M, Fink C, Gahr J, Ley S, Plathow C, Tuengerthal S, Zuna I, Muller FM, Kauczor HU. Contrast-enhanced 3D MRI of lung perfusion in children with cystic fibrosis-initial results. *Eur Radiol.* 2006 May 4; [Epub ahead of print].
- [2] Biederer J, Schoene A, Freitag S, Heller M. Simulated pulmonary nodules implanted in a dedicated porcine chest phantom: Sensitivity of MR imaging for detection. *Radiology* 2003; 227: 475–483.
- [3] Biederer J, Both M, Graessner J, Liess C, Jakob P, Reuter M, Heller M. Lung morphology: Fast MR imaging assessment with a volumetric interpolated breath-hold technique: Initial experience with Patients. *Radiology* 2003; 226: 242–249.
- [4] C. Hintze, J. Biederer, H. W. Wenz, R. Eberhardt, H. U. Kauczor. MRI in staging of lung cancer. *Radiologe.* 2006; 46: 251–259.
- [5] Plathow C, Klopp M, Fink C, Sandner A, Hof H, Puderbach M, Herth F, Schmahl A, Kauczor HU. Quantitative analysis of lung and tumour mobility: comparison of two time-resolved MRI sequences. *Br J Radiol.* 2005; 78: 836–840.
- [6] Both M, Schultze J, Reuter M, Bewig B, Hubner R, Bobis I, Noth R, Heller M, Biederer J. Fast T1- and T2-weighted pulmonary MR-imaging in patients with bronchial carcinoma. *Eur J Radiol.* 2005; 53: 478–488.
- [7] Fink C, Puderbach M, Bock M, Lodemann K, Zuna I, Schmaehl A, Delorme S, Kauczor H.-U. Regional Lung Perfusion: Assessment with Partially Parallel Three-dimensional MR Imaging. *Radiology* 2004; 231: 175–184.
- [8] Scarsbrook AF, Evans AL, Owen AR, Gleeson FV. Diagnosis of suspected venous thromboembolic disease in pregnancy. *Clin Radiol.* 2006 Jan; 61(1): 1–12.

Sequence parameters for MRI of the lung

	Non-CE lung MRI						Perf.	MRA	CE	T2-HR
Basic protocol 15'	x	x	x	x	x	x				(x)
Basic/CE 20'	x	x	x	x	x	x			x	(x)
Functional 30'	x	x	x	x	x	x	x	x	x	(x)
Siemens name	gre	haste	FI3d_vibe	tfiseg	tse	tfiseg	FI3d	FI3d_ce_ce_ff	FI3d_vibe	tse
Sequence	2D-Flash localizer	T2-HASTE	VIBE	True FISP	T2-TIRM	True FISP	4D MRA Perf.	3D-Flash Angio	VIBE	T2-TSE at
Respiratory phase	insp./bh.	insp./bh.	insp./bh	tidal	insp./bh	in./exp.	insp.	insp.	insp./bh	free
Slice orientation	c/t/s	cor	tra	cor	tra	cor	cor	cor	tra	cor
TA (min:s)	0:10	0:18	0:20	0:56	1:28	0:19	0:29	0:21	0:20	5:05+
Slices per acquisition	7	30	72	≤128	32x4	1	32x20	120	72	45
Preparation	A>P/R>L	R>L	A>P	R>L	A>P	R>L	R>L	R>L	A>P	R>L
FoV (mm)	500	450	400	450	400	400	500	500	400	500
[FoV phase %]	[100]	[100]	[87.5]	[100]	[75]	[100]	[100]	[83.3]	[87.5]	[79.7]
Base resolution	256	256	256	256	320	256	256	384	256	512
Phase resolution (%)	75	100	100	100	75	66	54	90	100	75
Slice thickness (mm)	10	8	4	4	6	10	5	1.6	4	4
Phase partial Fourier	6/8	4/8	off	off	off	off	6/8	6/8	off	5/8
Pixel size (mm)	2.6x2.0	1.8x1.8	1.6x1.6	1.8x1.8	1.7x1.3	2.4x1.6	3.6x2.0	1.2x1.0	1.6x1.6	1.3x1.0
Distance factor	50%	0%	20%	-50/0%	10%	n.a.	20%	20%	20%	10%
TR (ms)	8.9	600	3.15	437.2	3500	317.1	1.64	2.75	3.15	1700
TE (ms)	4.38	31	1.38	1.16	106	1.14	0.64	1.12	1.38	100
Flip-angle (degr.)	30°	180°	8°	80	150	67	40	25	8°	150
Band width (Hz/pixel)	180	610	500	1030	252	980	1220	384	500	195
iPAT [no. of ref. lines]	0	2 [14]	2 [35]	2 [25]	2 [66]	2 [24]	2 [24]	2 [24]	2 [35]	2 [46]
Large FoV (dist. corr.)	off	on	off	on	off	off	off	off	off	on
Comments	cor/sag A>P/tra. R>L	2 concatenations ("interleaved")	FatSat, if CE VIBE is planned	Distance factor -50% WIP-Package	TI 150 ms, 5 concatenations	60 measurements at 3/second	20 measurements 1.5 s each. Reduce FA, if SAR limit exceeded	To be run pre-contrast and pul./aortic phase (8.7 s time to center)	With FatSat activated Identical with 3	Navigator needed 5 concatenations

WOMEN'S HEALTH

Case Report MAGNETOM Avanto

Advanced Breast Cancer: MR Monitoring* of Neoadjuvant Chemotherapy

Bruce A. Porter, M.D., FACR

First Hill Diagnostic Imaging, Seattle, Washington, USA

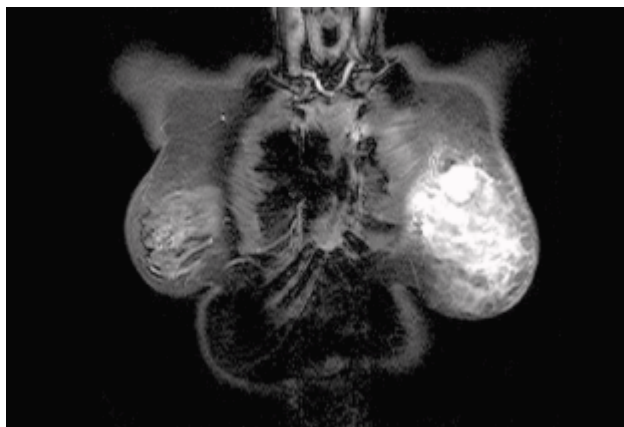Patient history

51-year-old marathon runner noted swelling, redness, and tenderness of her left breast that did not respond to antibiotics. Biopsy confirmed inflammatory infiltrating ductal cancer with associated high-grade ductal carcinoma in situ (DCIS). MR was requested for staging and to monitor neo-adjuvant chemotherapy of locally advanced breast cancer in a patient with mammographically dense breasts.

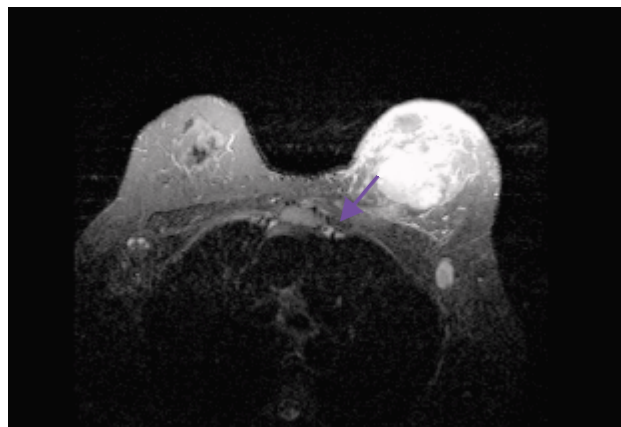
Imaging findings

The initial, baseline, MR exam documented inflammatory thickening of the skin, lymphedema, and malignant axillary adenopathy on pre-contrast STIR chest (Fig. 1A) and breast coil STIR images (Fig. 1B) (STIR: Short TI Inversion Recovery). An axial maximum intensity projection (MIP) of the first post-contrast DynamicVIEWS acquisition (Fig. 1C) demonstrates

the extreme vascularity of the large (5.6 cm) and partially necrotic primary tumor as well as numerous nodules of extensive DCIS and/or additional foci of invasive tumor. Three months later, a follow-up axial MIP (Fig. 2A) revealed not only lack of response to the initial chemotherapy, but also enlargement of the small foci of DCIS or invasive cancer. An axial, 60-second post-contrast subtraction image (Fig. 2C) and corresponding computer aided detection (CAD) color parametric image (Fig. 2B) graphically depict the extreme vascularity, rapid enhancement and wash-out of this still viable tumor. Sagittal thin section InterVIEWS image (Fig. 2D) confirms skin invasion. The axillary lymph nodes remained enlarged. As a result, anti-angiogenic therapy was begun in an attempt to control the growth of this aggressive tumor. At 5 months, after prolonged and intensive therapy, the tumor



[Figure 1A] Coronal STIR chest image shows intense edema of the left breast and skin as well as abnormal signal in the left first intercostal nodal space (arrow).



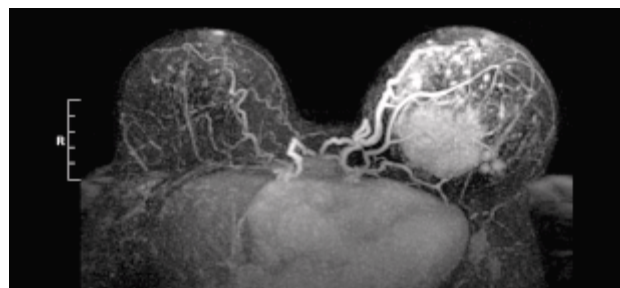
[Figure 1B] Axial STIR breast coil image reveals high-signal edema and thickening of the skin and parenchyma of the left breast as well as malignant axillary adenopathy; abnormal signal in the left parasternal region (arrow) confirms concern for internal mammary adenopathy.

felt somewhat softer on exam; however, although the sagittal InterVIEWS (Figs. 3A and 3B) documented some regression of the smaller tumors, the main mass is larger and has extended further into the skin. The malignant nature and unresponsiveness of this tumor are unfortunately made very clear with MR monitoring.

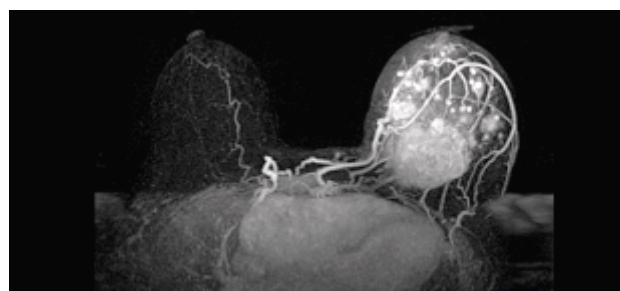
Discussion

Pre-operative (neoadjuvant) chemotherapy is increasingly used for larger, locally advanced but not metastatic, breast cancers. The intent is to shrink the tumor, establish tumor chemo-sensitivity, and to possibly allow breast conservation if a good response is achieved. However, monitoring of the effectiveness of treatment is notoriously inaccurate with physical exam, mammography, and ultrasound. MR has been shown to be quite an accurate method to assess treatment-related changes, which helps make decisions on therapy or surgery more tailored to the individual patient and tumor. Although PET-CT can also be used for neoadjuvant monitoring, MR has much better resolution for subtle breast findings; it is also much less expensive, more available, and does not expose the patient to additional radiation.

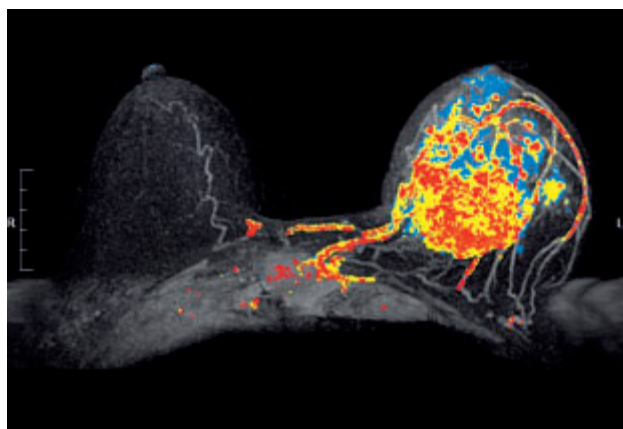
This case represents a particularly aggressive tumor, in which MR demonstrated rapid progression even during the most intense chemotherapy currently available. The prognosis for the patient is predicted by the MR findings and is poor.



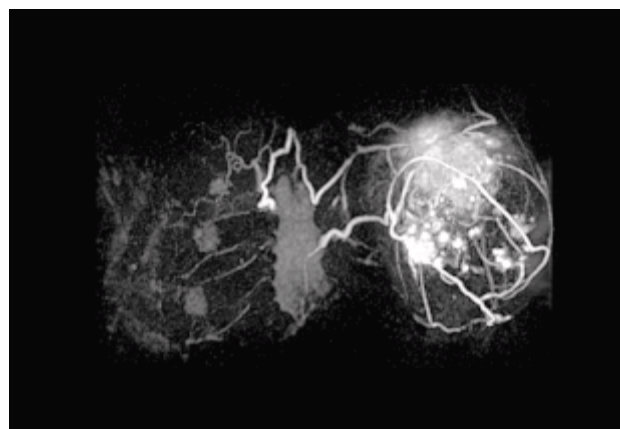
[Figure 1C] Axial full maximum intensity projection (MIP) from the 60-second data set shows a dominant mass posteriorly, multiple smaller nodules of malignant enhancement elsewhere, and markedly asymmetrical venous drainage.



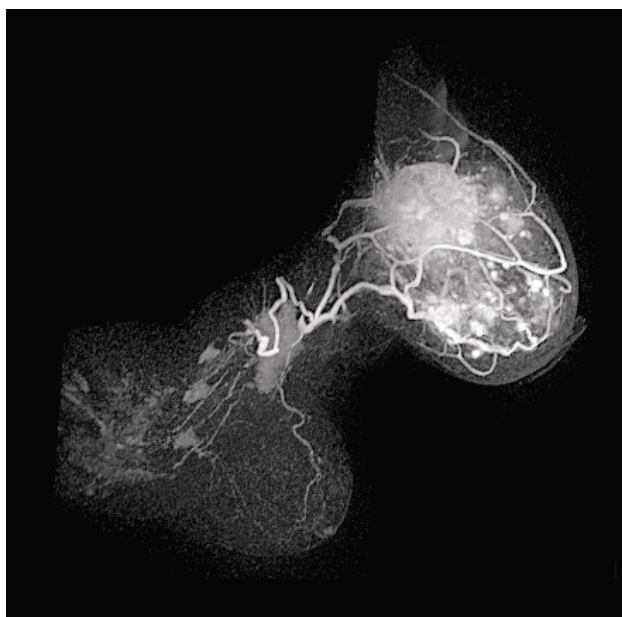[Figure 2A] Follow-up MR documented absence of significant response to therapy as well as progression and coalescence of the smaller nodules, though the adenopathy was somewhat improved.



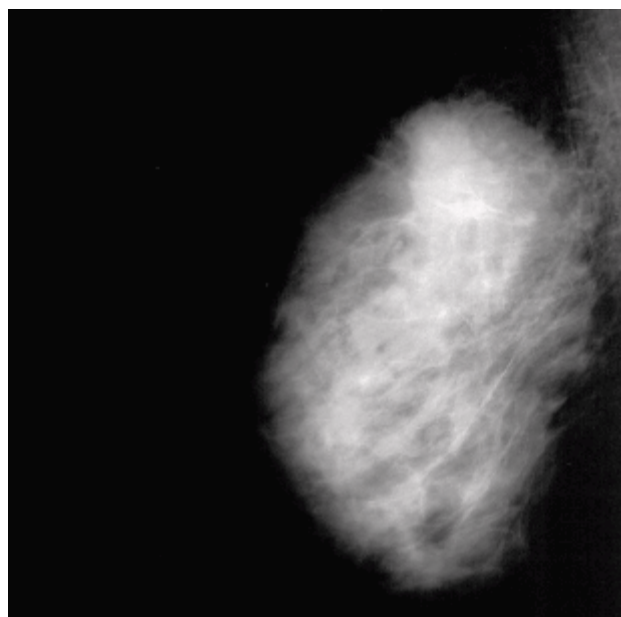
[Figure 2B] Corresponding CAD color overlay indicates heterogeneous, persistent malignant enhancement with a significant amount of wash-out kinetics (red voxels). Plateau type kinetics is portrayed as yellow and persistent enhancement as blue. The axillary node is not appreciably labeled. The right breast remains normal.



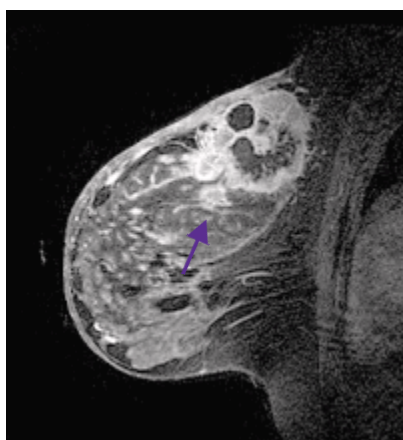
[Figure 2C] Coronal full MIP reconstructed from the axial 60-second data set is useful to localize and assess the full extent of the invasive malignancy and the ductal carcinoma in situ (DCIS) of the left breast. Note the contralateral venous drainage.



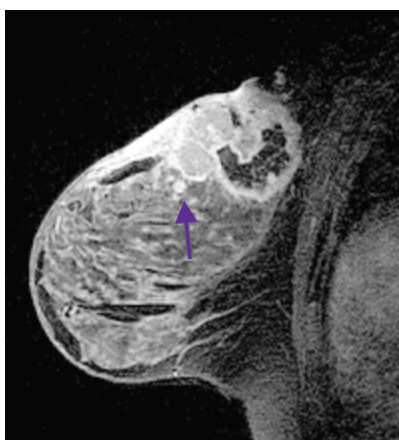
[Figure 2D] The thin (0.8 mm) slices and 0.7 x 1.0 mm in-plane resolution of the DynamicVIEWS bilateral subtraction images allow high quality oblique MIP images for direct comparison to mammography (Lt. MLO view).



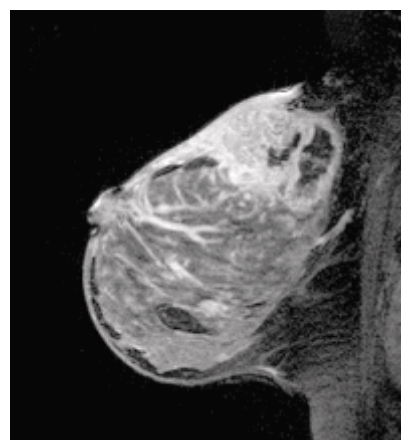
[Figure 2E] True lateral mammogram of the left breast (rotated to match Fig. 2F) illustrates the difficulty of assessing tumor size and extent in radiographically dense breasts.



[Figure 2F] Sagittal InterVIEWS at 2 min post-contrast with 0.64 mm slice thickness and 0.5 x 0.5 mm in-plane dimensions clearly shows both the centrally necrotic main tumor mass and a satellite nodule (arrow). Note the skin thickening and enhancement due to tumor infiltration (i.e. this is a T4 lesion).



[Figure 3A] Despite further chemotherapy and addition of anti-angiogenesis drugs, the sagittal InterVIEWS exam (when compared to Fig. 2F) readily documented progressive growth of the main tumor mass and further skin infiltration. However, the adjacent small satellite lesion (arrow) became smaller.



[Figure 3B] At the level of the nipple, ductal enlargement and a ductal enhancement pattern indicates residual DCIS and fluid.

*Works In Progress – The information about this product is preliminary.

The product is under development and not commercially available in the US, and its future availability can not be insured.

Soft Tissue Motion Correction for MR Mammography (BRACE)*

Melanie Schmitt

Siemens R&D, Erlangen, Germany

Introduction

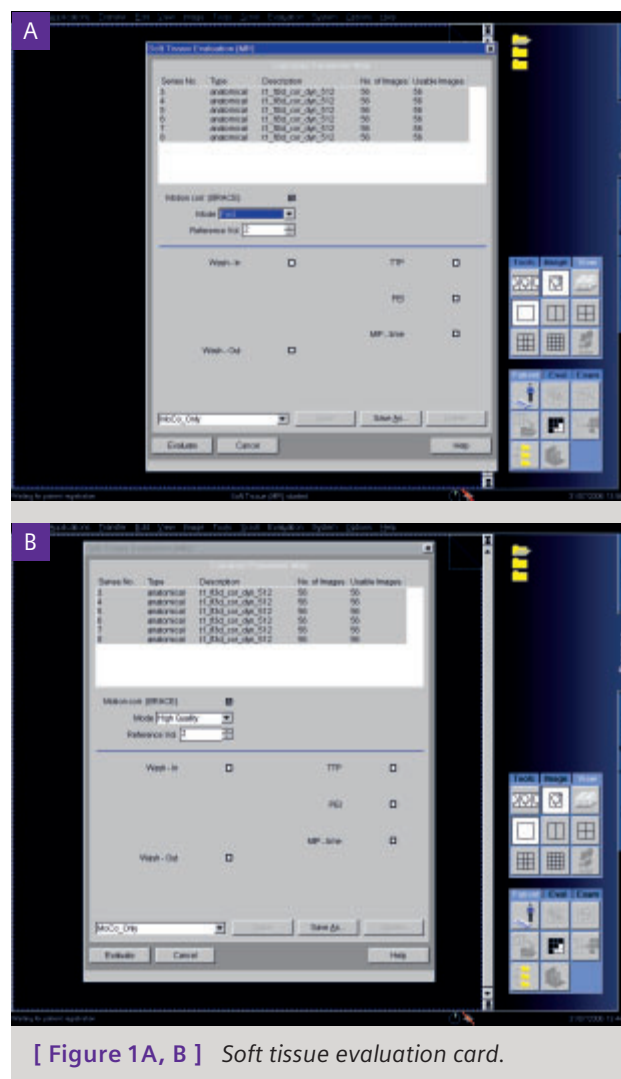
Dynamic imaging is an important and valuable diagnostic tool for the diagnosis of breast tissue lesions in MR mammography. Typically, fast T1-weighted CE imaging is used to monitor the concentration of a contrast agent during its passage through the tissue. The examination starts with a pre-contrast scan followed by the injection of the contrast agent and 6-8 post contrast examinations. To facilitate the detection of suspicious enhancing areas different post processing tools are used, including subtraction of post-contrast and pre-contrast images and evaluation of the signal time curves in suspicious lesions. Therefore it is essential that there are no changes in the patient's position during the entire measurement. However, because of the time duration of 6-8 min for the CE MRI examination, this requirement of no movement between measurements is often not met and may thus affect the interpretation of the images or make an accurate diagnosis even impossible.

Regardless of the many efforts undertaken to reduce or suppress motion artifacts, including optimized choice of MR sequences and protocols, instructions to the patients and fixation of body-parts, there still exists quite a substantial number of examinations which suffer from motion. Consequently registration algorithms are increasingly used to correct for these artifacts. But, image registration is particularly difficult in MR mammography because of the complex, non linear elastic behavior of breast tissue and the possibility of strong local movements.

This article describes a new motion correction, BRACE – developed by Siemens – that overcomes the limitations of existing methods in MR Mammography. BRACE (soft tissue motion correction package) will be available with the new software syngo MR B13.

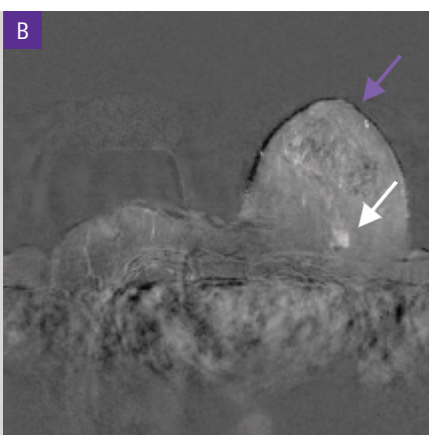
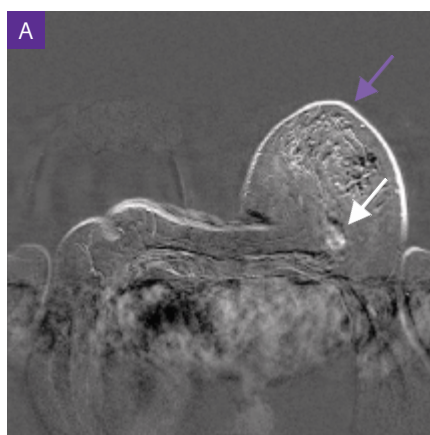
Motion correction

To compensate for patient motion during the CE MRI examination two different non-rigid registration algorithms of BRACE are now available. Both correction possibilities can compensate for patient motion in all directions in 2D and 3D



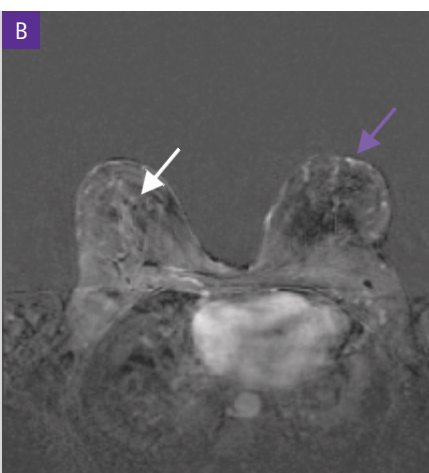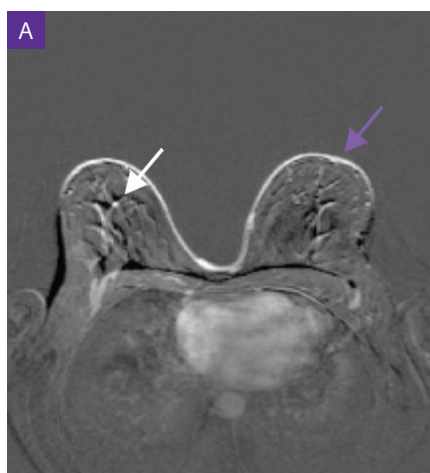[Figure 1A, B] Soft tissue evaluation card.

MR data sets. The first correction form is a Gaussian-weighted least mean square registration algorithm, which also takes into account the signal change due to the inflow of the contrast agent. The fast algorithm can perform motion correction of a 3D data set including 6 repetitions with 80 slices



[Figure 2A]
Original image

[Figure 2B] Corrected with
the fast BRACE algorithm.



[Figure 3A]
Original image

[Figure 3B] Corrected with
the high quality BRACE algorithm.

The uncorrected image in Fig. 3A shows a suspicious bright spot (white arrow). In the corrected image the suspicious area is gone and only vessels remain. The diffuse enhancement in the central glandular tissue was confirmed by the examination repeated 2 months later.

and a high in-plane resolution of 512 x 512 in less than 3 min. This algorithm is particularly suitable for small to moderate motions. For more severe motions another algorithm is available. For this high quality algorithm a conjugate gradient method is used to find the best possible set of motion parameters that maximizes the similarity measures across the entire volume. Both possibilities are available under the Soft Tissue Evaluation card (c.f. Figs. 1A and 1B).

Clinical applications

The new BRACE correction tools for dynamic breast MRI were used for different 2D and 3D patient data sets, in which motion of the patient was clearly visible. Fig. 2 shows the example of a patient data set, where the fast correction algorithm was used. The images were acquired with a 2D T1-weighted FLASH (Fast Low Angle Shot) sequence on a MAGNETOM Symphony scanner with the following parameters: TE / TR / flip angle = 4.76 ms / 113 ms / 80°, matrix 384 x 384, slice thickness 3 mm, iPAT (integrated Parallel Acquisition Technique) factor 2. In the corrected images the lesion is

much better delineable compared to the uncorrected case. Fig. 3 shows another example of a patient with motion artifacts. In this case the images were acquired with a 3D T1-weighted FLASH sequence on a MAGNETOM Sonata scanner with the following image parameters: TE/TR / flip angle = 6.7 ms / 113 ms / 15°, matrix 256 x 256, slice thickness 3 mm, iPAT factor 2.

Conclusion

A new motion correction BRACE has been developed and optimized for MR Mammography. This motion correction can handle large datasets acquired in breast MR and enables a higher diagnostic confidence when suspicious areas are under evaluation.

* The information about this product is preliminary. The product is under development and not commercially available in the US, and its future availability can not be insured.

CARDIAC

Case 1

Acute Myocardial Infarction*

Jeanette Schulz-Menger, M.D., Philipp Boye, M.D.

Franz Volhard Clinic, Charité Campus Buch, Berlin, Germany

Introduction

A 44-year-old man had complained of sudden chest pain 5 days previously. Acute myocardial infarction was indicated by ST-elevation in ECG and increased cardiac enzymes. The coronary angiography showed an occlusion of the RCA (right coronary artery) and also stenosis of the LCX (left circumflex artery). A PCI (percutaneous intervention) of both vessels was performed. Cardiac MRI was performed to assess the extent of myocardial damage.

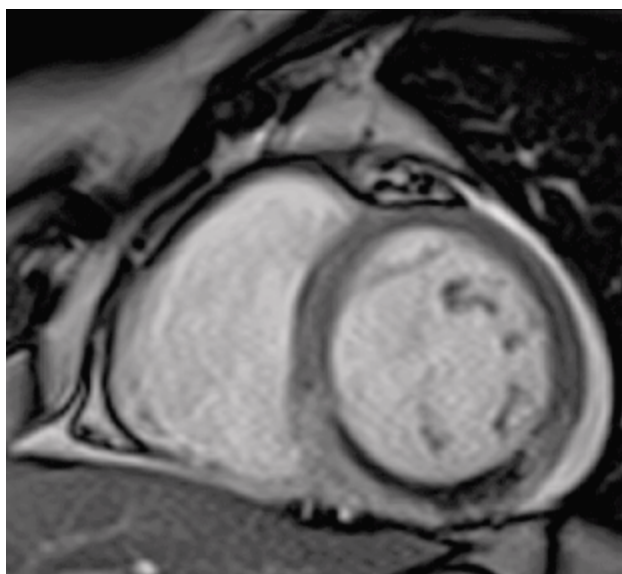
Image findings

The left ventricular dimensions are normal. There is impaired systolic function (ejection fraction: 34%) with regional wall motion abnormalities: akinesia of the inferior, septal, posterolateral wall and the apex. Tissue characterization imaging using PSIR (Phase-Sensitive Inversion-Recovery) sequence shows extensive transmural scar of the inferior wall including a large area of microvascular obstruction. A pericardial effusion is also seen (Figs. 1 and 2).

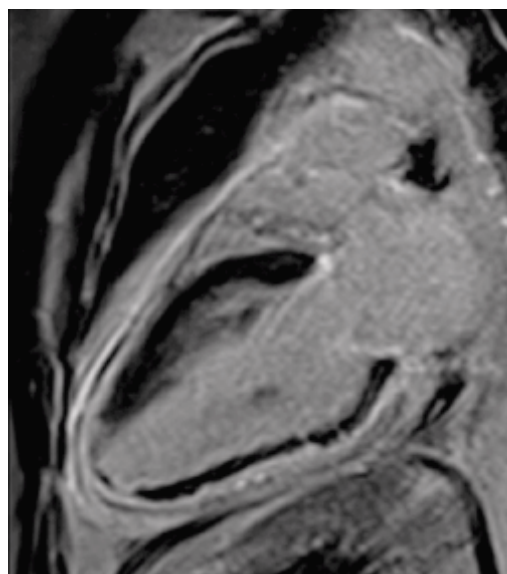
Results

Tissue characterization imaging can be used early after myocardial infarction to assess the extent of myocardial scar. This extent determines the prognosis with regard to functional recovery of regions with wall motion abnormality. In this patient, although PCI of the right coronary artery was performed, there would be no expectation of functional recovery in the inferior wall due to the transmural. Furthermore, the presence of microvascular obstruction is a risk factor for late remodeling. The single-shot PSIR sequence enables fast and accurate delayed tissue characterization imaging even under difficult patient conditions without the need of TI adjustment.

*Works In Progress – The information about this product is preliminary. The product is under development. It is not commercially available in the US and its future availability cannot be assured.



[Figure 1] TrueFISP cine retro, short axis, GRAPPA 2.



[Figure 2] TurboFLASH IR, 2 chamber view.

Case 2

Myocarditis*

Jeanette Schulz-Menger, M.D., Philipp Boye, M.D.

Franz Volhard Clinic, Charité Campus Buch, Berlin, Germany

Patient history

The patient suffered a respiratory infection a week before examination and since then has complained of repeated chest pain. The ECG was indicative of an inferolateral ST-elevation myocardial infarction (STEMI). However, coronary heart disease was ruled out with the help of coronary angiography. Cardiac MRI (CMR) was performed due to suspicion of myocarditis.

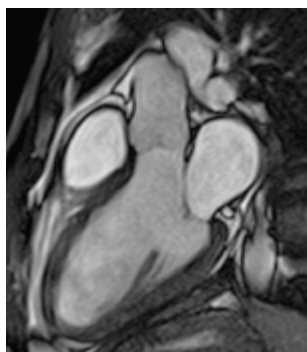MRI findings

The size and dimension of the left ventricle is within normal limits. There is hypokinesis in the inferolateral wall. IR Turbo FLASH 2D sequence shows multiple subepicardial foci of increased intensity after using tissue characterization imaging in the lateral and inferolateral wall (Fig. 2). TIRM (Turbo Inversion Recovery Magnitude) sequence acquired in the same orientations reveal edema in the inferolateral wall (Figs. 3 and 4).

Results and discussion

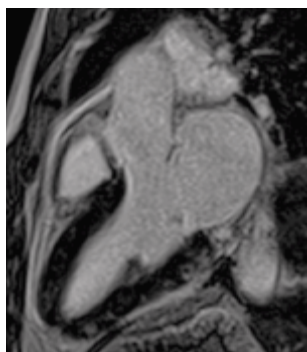
This patient shows patchy delayed enhancement in the inferolateral wall and edema demonstrated by TIRM to be in the same region: this is most probably due to myocarditis. CMR enables visualization of myocarditis in many cases by use of delayed enhancement and TIRM or TSE-T1-weighted imaging. In comparison to the pattern seen in patients with ischemic heart disease, hyperintensity after using tissue characterization imaging is distributed in a completely different way in patients with myocarditis: subepicardial or intramyocardial localization and more patchy and grayish appearance are typical findings. The pathology might be visible in one sequence only in some of the patients. Therefore, to ensure high sensitivity, the use of different sequences is recommended.

*The information about this product is preliminary. The product is under development. It is not commercially available in the US and its future availability cannot be assured.

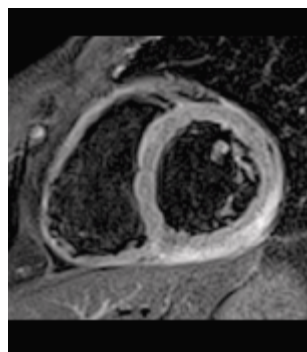


[Figure 1] Function, TrueFISP cine retro, LVOT, GRAPPA 2

TR/TE	20/1.2
TA	14.16 s
SL	8 mm
FoV	340 mm
matrix	256

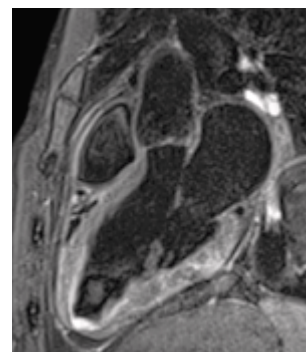


[Figure 2] Tissue characterization, Turbo FLASH IR, LVOT



[Figure 3] TIRM (Turbo Inversion Recovery Magnitude) Dark Blood, short axis, GRAPPA 2

TR/TE	2098.5/60
TI	170
TA	12.87 s
SL	8 mm
slice	1
FoV	340 mm
matrix	256



[Figure 4] TIRM Dark Blood, LVOT, GRAPPA 2

TR/TE	2652.5/60
TI	170
TA	15.64 s
SL	8 mm
slice	1
FoV	340 mm
matrix	256

Case 3

Apical Thrombus*

Jeanette Schulz-Menger, M.D., Philipp Boye, M.D.

Franz Volhard Clinic, Charité Campus Buch, Berlin, Germany

Patient history

This 72-year-old patient was referred to cardiology department with subacute myocardial infarction. The patient had had coronary artery bypass graft surgery in 1999 (grafts to right coronary artery and left anterior descending). One day prior to the MRI exam, a stent was placed in the coronary artery bypass graft to the LAD.

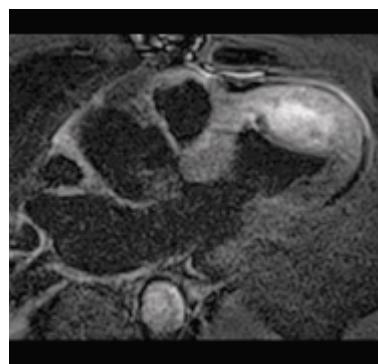
Image findings

Dilated, hypertrophic left ventricle with moderately reduced ejection fraction. Tissue characterization sequences show increased intensity in the anterior wall and basal inferior and posterior wall. The TIRM sequence shows edema in anterior wall but no edema in the basal inferior and posterior wall (Fig. 1). In LVOT orientation, an apical left ventricular thrombus with a liquid core can be seen. Follow-up investigation after 3 months of anticoagulation revealed complete resolution of the thrombus (Fig. 3).

Results and discussion

Cardiac MRI can be used for a comprehensive cardiac examination of patients with coronary artery disease. Beyond assessing global and regional wall motion abnormalities by use of cine-sequences, CMR reveals in this patient the presence of an apical thrombus, helps differentiating between acute and chronic infarction by use of a PSIR (Phase-Sensitive Inversion-Recovery) and TIRM (Turbo Inversion Recovery Magnitude) sequences. Both sequences used together improve the performance of CMR in the acute setting.

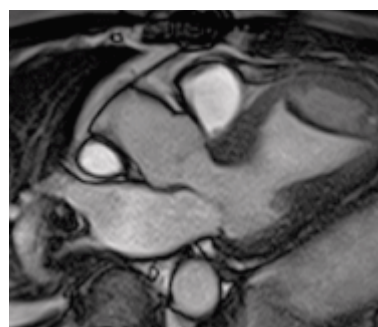
*The information about this product is preliminary. The product is under development. It is not commercially available in the US and its future availability cannot be assured.



[Figure 1]

TIRM (Turbo Inversion Recovery Magnitude) Dark Blood, LVOT, GRAPPA 2

TR/TE	1449.5/60
TI	170
TA	8.65 s
SL	8 mm
FoV	340 mm
matrix	256

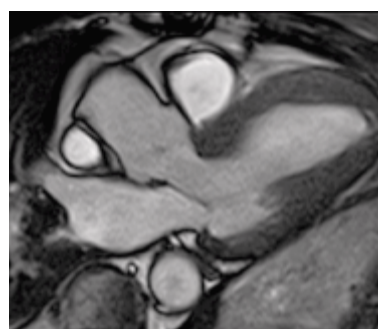


[Figure 2]

Function, TrueFISP cine retro, LVOT, GRAPPA 2

TR/TE	20/1.2
TA	9.28 s
SL	8 mm
FoV	340 mm
matrix	256

Apical left ventricular thrombus.



[Figure 3]

Function, TrueFISP cine retro, LVOT, GRAPPA 2

TR/TE	20/1.2
TA	13.71 s
SL	8 mm
FoV	340 mm
matrix	256

After thrombolysis.

Case 4

Aortic Stenosis

Jeanette Schulz-Menger, M.D., Philipp Boye, M.D.

Franz Volhard Clinic, Charité Campus Buch, Berlin, Germany

Patient history

65-year-old patient with dyspnea on exertion (NYHA III). There is no history of syncope coronary artery disease or heart failure. Echocardiography reveals aortic stenosis with a pressure gradient of 76 (max.) and 49 mmHg (mean), respectively. Coronary MR imaging (CMR) was performed to evaluate the aortic orifice area.

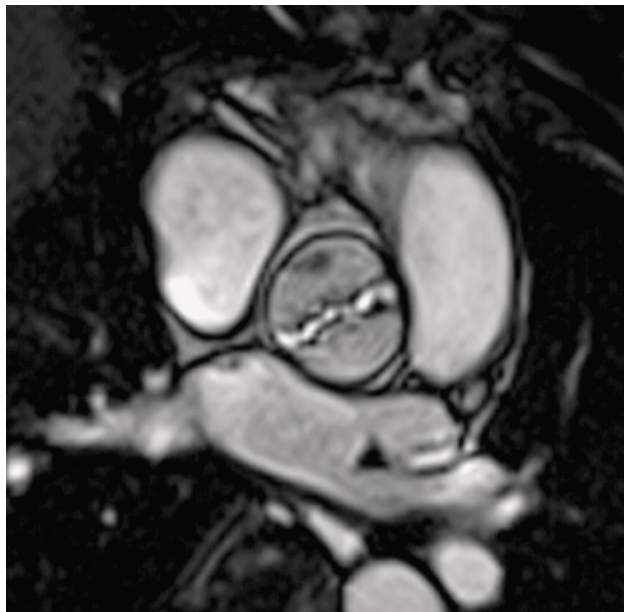
Image findings

The MR images show clearly a bicuspid aortic valve. No left ventricular hypertrophy is seen and there is normal left ventricular function. Planimetry using 2D TrueFISP cine sequence reveals an aortic orifice area of 0.6 cm^2 ($0.35 \text{ cm}^2/\text{m}^2$ normalized).

Results and discussion

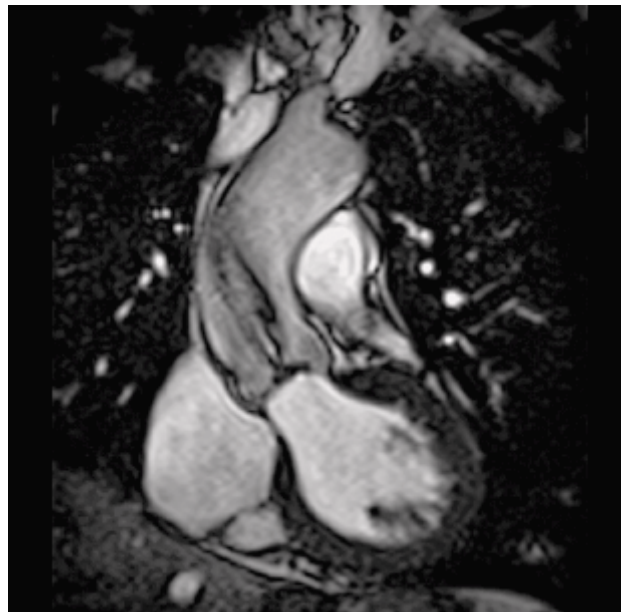
There was a moderate to severe aortic stenosis according to the pressure gradients only as assessed by echocardiography. CMR can be used additionally in patients with aortic stenosis to assess the aortic orifice area by planimetry. This helps to identify patients with indication for aortic valve replacement. In this patient the aortic orifice area is 0.6 cm^2 , which corresponds to a severe stenosis. Accordingly, this patient underwent surgery.

*The information about this product is preliminary. The product is under development. It is not commercially available in the US and its future availability cannot be assured.



[Figure 1] Function, TrueFISP cine retro, valve, GRAPPA 2

TR/TE	21/1.3
TA	13.74 s
SL	5 mm
FoV	340 mm
matrix	256



[Figure 2] Function, TrueFISP cine retro, coronal LVOT, GRAPPA 2

TR/TE	21/1.3
TA	12.75 s
SL	5 mm
FoV	340 mm
matrix	256

Case 5

Osteosarcoma Metastasis

Jeanette Schulz-Menger, M.D., Philipp Boye, M.D.

Franz Volhard Clinic, Charité Campus Buch, Berlin, Germany

Patient history

17-year-old man with osteosarcoma in the right lower leg. Pulmonary metastasis was seen. Cardiac MRI was performed due to abnormal finding in transthoracic echocardiography indicating an intracardiac mass in the right ventricle.

Image findings

Using cine sequences and T1-weighted Dark Blood images* in RVOT-orientation, two tumors in the right ventricular out-flow tract with extension into the pulmonary artery trunk can be visualized. In TrueFISP cine-sequence the tumors appear mobile. In the T1-weighted sequence the masses appear isointense. The right ventricle is enlarged.

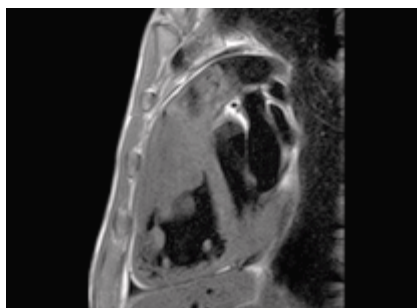
Results and discussion

This patient shows a cardiac metastasis of an osteosarcoma. In most reported cases the location of a cardiac metastasis of osteosarcoma is the right ventricle. Cardiac MRI allows the detection of cardiac tumors and intracardiac masses with high sensitivity. Using T1- and T2-weighted imaging and application of contrast agent, differentiation between thrombus and tumor and between different types of tumors can to some extent be achieved.

Differential diagnosis between thrombus and tumors

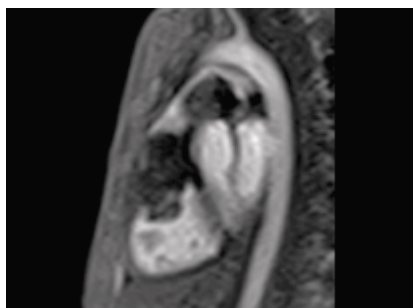Mass	T1-weighted MRI	T2-weighted MRI	Intensity increase after tissue characterization sequences
Thrombus	■	■	None
Myxoma	■/■	■	Mild/moderate
Fibroma	■/■	■/■	Rim
Rhabdomyoma	■	■	Mild/none
Hemangioma	■	■	High
Pheochromocytoma	■	Extreme ■	High
Lymphoma	■	■	■
Malignant fibrous histiocytoma (MFH)	■	■	Moderate
Angiosarcoma	■	■	■/high

■ Isointensity ■ Hyperintensity
■ Hypointensity ■ Heterogeneous intensity



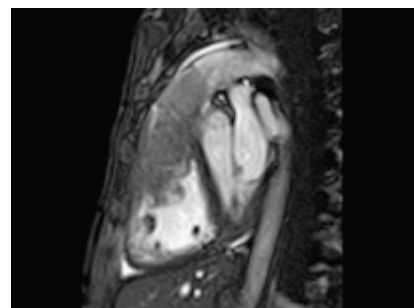
[Figure 1] Morphology, TSE Dark Blood, RVOT, GRAPPA 2

TR/TE	907.7/24	slice	1
TA	13.74 s	FoV	340 mm
SL	6 mm	matrix	640



[Figure 2] Turbo FLASH dynamic signal, RVOT, GRAPPA 2

TR/TE	172/1.3	SL	10 mm
TI	100	slices	180
TA	0.14 s/slice	FoV	380 mm
		matrix	192



[Figure 3] Function, TrueFISP cine retro, RVOT, GRAPPA 2

TR/TE	20.2/1.2	slices	30
TA	19.47 s	FoV	340 mm
SL	6 mm	matrix	256

*Works In Progress – The information about this product is preliminary.

The product is under development. It is not commercially available in the US and its future availability cannot be assured.

Case 6

Acute Infarction

Jeanette Schulz-Menger, M.D., Philipp Boye, M.D.

Franz Volhard Clinic, Charité Campus Buch, Berlin, Germany

Patient history

67-year-old patient suffered acute coronary syndrome with mild elevation of cardiac enzymes. History of myocardial infarction in 1983. Echocardiography showed wall motion abnormalities. Cardiac MRI* was performed to differentiate between chronic and acute infarction.

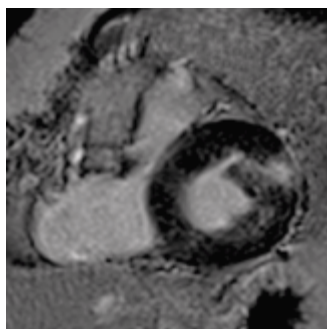
Image findings

Hypertrophic left ventricle with global systolic function in normal range but regional hypokinesia of apical septal and anterior wall as well as the apex.

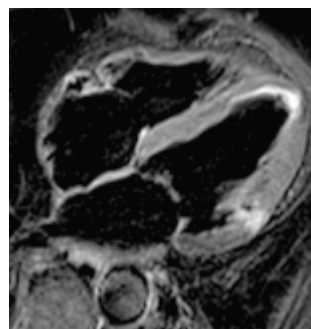
PSIR and IR Turbo FLASH 2D tissue characterization sequences show increased intensity in the apical region and circumscribed in the midventricular lateral wall, both with transmural extent. TIRM sequence shows high signal of the myocardium in the lateral wall but no high signal in the apex. The high signal apically in the left ventricular cavity in TIRM indicates "slow-flow" phenomenon.

Results and discussion

Delayed enhancement imaging using PSIR or IR FLASH sequences allows detection of myocardial infarction. To differentiate acute from chronic infarction, TIRM or T2-weighted sequences can be used in addition to delayed enhancement imaging. These sequences depict acute infarction by visualizing edema. In this patient, CMR using TIRM sequence helped to identify the region of acute infarction (lateral wall).

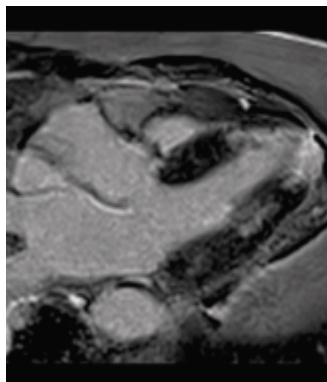


[Figure 1]
PSIR (Phase-Sensitive
Inversion-Recovery)
2D short axis

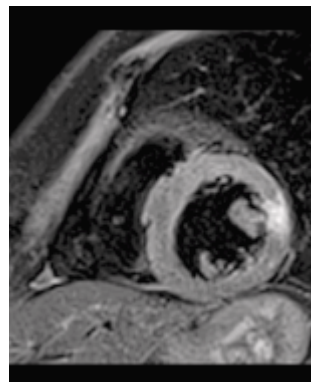


[Figure 4] TIRM Dark
Blood, 4 chamber, GRAPPA2

TR/TE	2377/60
TI	170
TA	14.4 s
SL	8 mm
slice	1
FoV	340 mm
matrix	256



[Figure 2]
PSIR 2D, LVOT




[Figure 5] TIRM (Turbo
Inversion Recovery Mag-
nitude) Dark Blood, short
axis, GRAPPA 2

TR/TE	2334.5/60
TI	170
TA	14.16 s
SL	8 mm
slice	1
FoV	340 mm
matrix	256

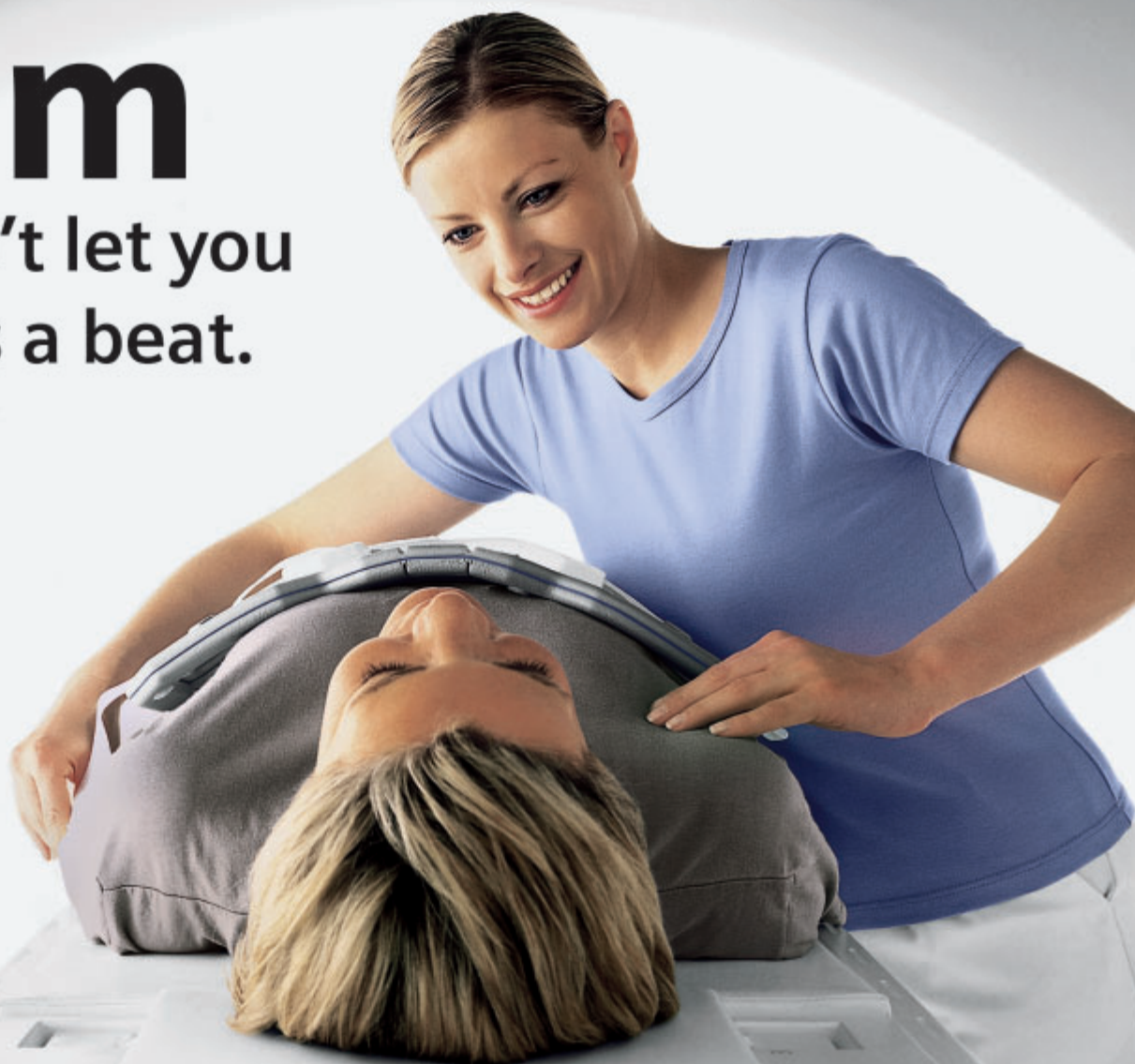*Works In Progress – The information about this product is preliminary.


The product is under development. It is not commercially available in the US and its future availability cannot be assured.

 We see a way to evaluate myocardial infarct and vascular disease within one exam without any patient repositioning

Tim

won't let you
miss a beat.



 We see a way to determine regional ventricular function in real time allowing free-breathing using 12 matrix coil elements

Proven Outcomes in Cardiology with Tim® (Total imaging matrix technology).

Tim offers unmatched MRI capabilities for all cardiovascular exams without repositioning the patient. Ideal not only in diagnosing subendocardial infarct and congenital heart disease, but also systemic diseases like diabetes and atherosclerosis. With its 76 matrix coil elements and up to 32 RF channels, you enjoy revolutionary acquisition speed with virtually unlimited Parallel Imaging even in double oblique slice orientations. Tim transforms workflow from an exam limited by the dimensions of local RF-coils to one determined by the disease. Tim. Very heart smart.

www.siemens.com/Tim

SIEMENS
medical

Case Report MAGNETOM Espree

Advanced Vascular Imaging: Whole-Body MR Angiography

Denis Szejnfeld, M.D., Paulo R. Schwartzman, M.D., Ph.D.

CURA – Centro de Ultrasonografia e Radiologia, São Paulo, Brazil

Patient history

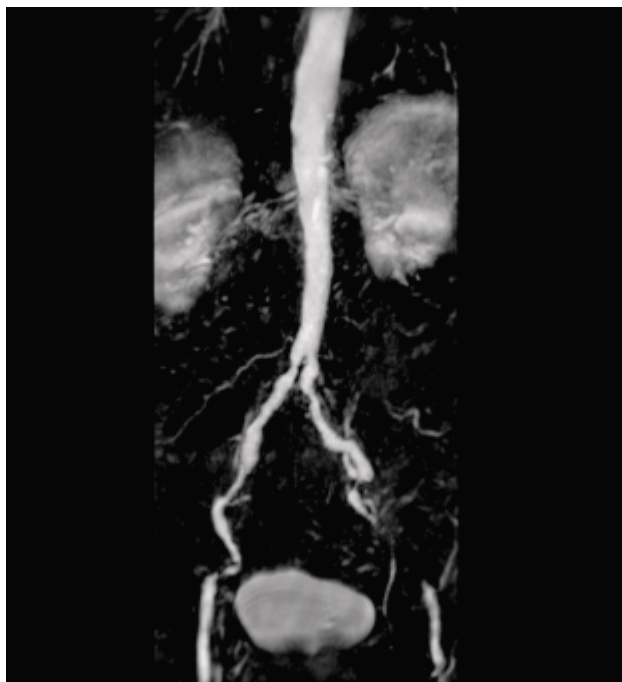A 64-year-old man had a six months history of non-healing ulcer on the left foot and experienced intermittent claudication while walking less than 10 meters. He had been a long-standing heavy smoker, but had not used tobacco for the last 5 years.

The physical examination revealed a cachectic man, who had finger clubbing. On examination, we found no pulse on femoral arteries and a wound and gangrene of the left hallux. MR Angiography (MRA) of aorta and lower limbs was requested for diagnosis and percutaneous intervention / surgical planning.

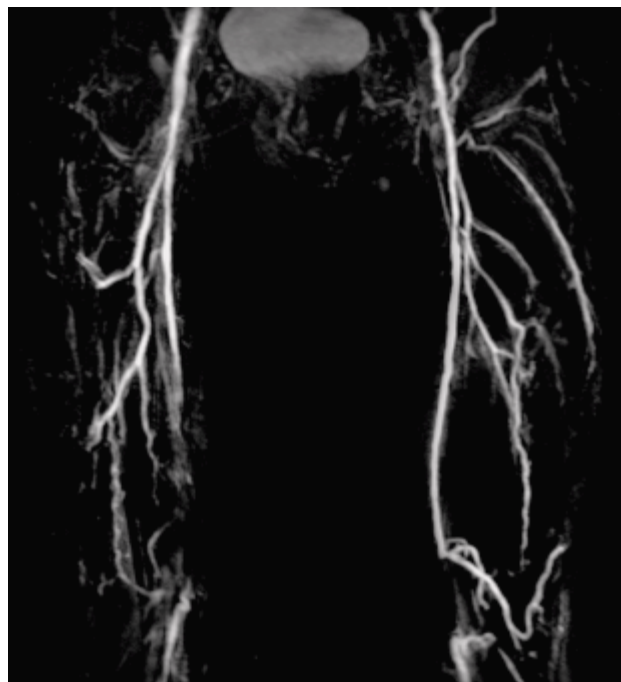Imaging findings

The MRA showed diffuse and subtle atherosclerotic irregularity of the aorta, mild stenosis at the origin of the common iliacs and proximal occlusion of both external iliacs (Fig. 1). Common femoral arteries are filled through collaterals. There is a distal occlusion of the left superficial femoral artery indicating previous thrombosis. The right superficial artery is occluded in its mid portion. Deep femoral arteries are patent and serve as collateral pathways (Fig. 2).

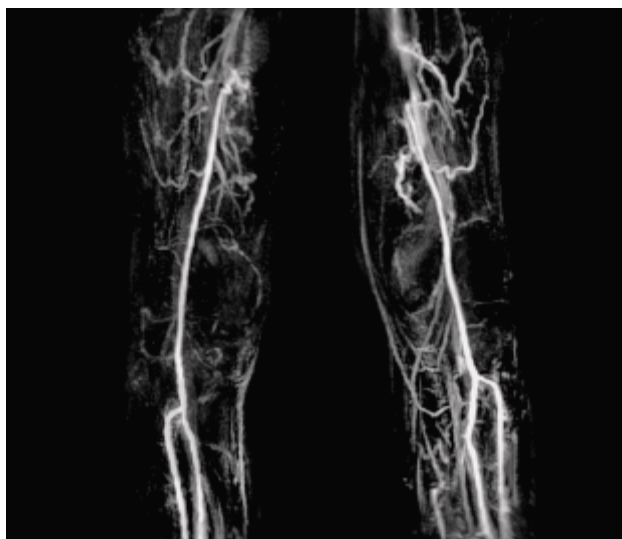
Popliteal arteries are widely patent presenting subtle atherosclerotic irregularity. Proximal tibial anterior arteries and fibular are patent bilaterally and posterior tibial are occluded (Fig. 3).



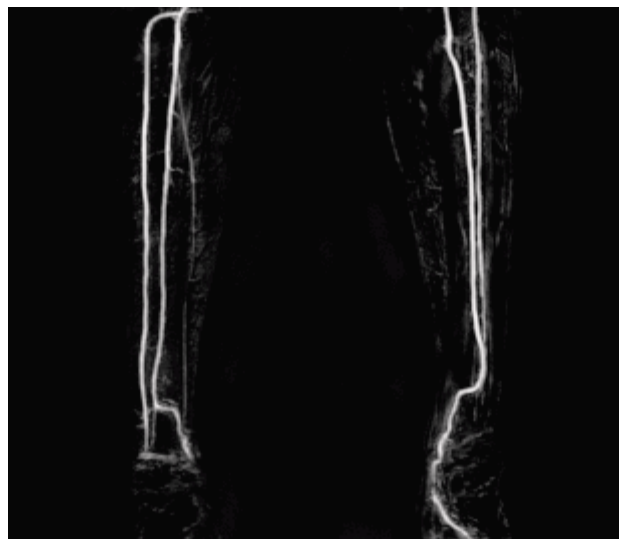[Figure 1] Maximum Intensity Projection (MIP) reconstruction of abdominal aorta and iliac arteries showing bilateral external iliac occlusion.



[Figure 2] MIP from contrast enhanced MRA documenting femoral arteries disease.



[Figure 3] MIP reconstruction of popliteal and distal runoff arteries.



[Figure 4] Distal runoff arteries. MRA documented posterior tibial arteries occlusion, left anterior tibial disease and patent fibular arteries.

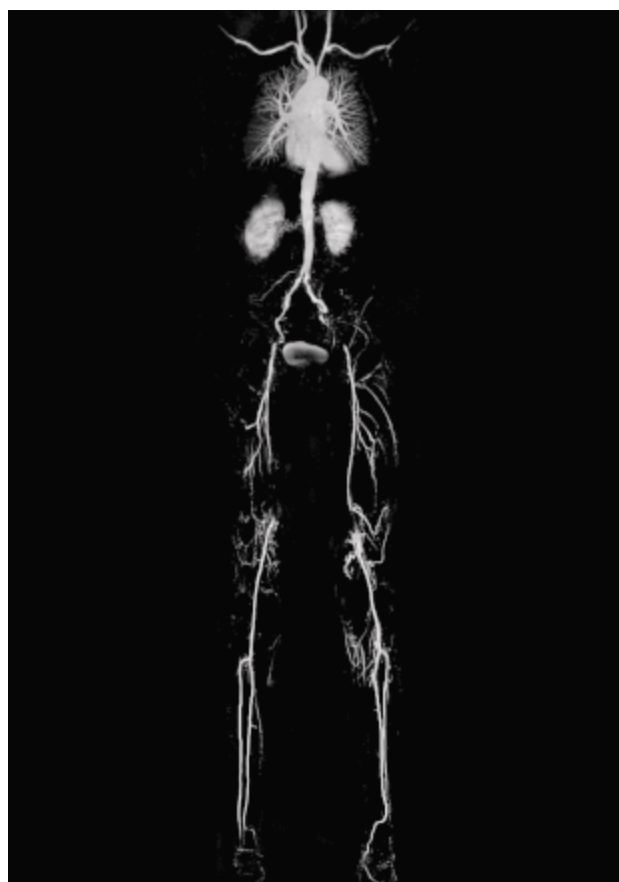
Left anterior tibial artery has multiple severe stenosis and it is occluded distally. Left fibular is patent. Right anterior tibial and fibular arteries are widely patent (Fig. 4). A panoramic view is documented using the composing software (Fig. 5).

Discussion

Chronic arterial insufficiency is a multiple lesion complex disease. Usually, patients with such a condition suffer chronic pulmonary obstructive disease, strokes, myocardial infarction and nephropathy. Conventional angiography is an invasive and risk-related procedure, especially in this type of patient. A good quality diagnostic image is essential to determine location and severity of lesion. A therapeutic approach (vascular bypass or percutaneous angioplasty) is a very important decision.

Doppler ultrasound is limited and time consuming in multiple lesion patients and does not offer an angiographic image. Multislice CT may be used with the inconvenience of nephrotoxic contrast media, radiation and very time consuming reconstruction of original images. In patients with extensively calcified arteries, Multislice CT may be limited and difficult to determine severity of the lesions.

This case represents an advanced atherosclerotic disease, in which MRA offered a whole-body, good quality panoramic study.



[Figure 5] Composed image gives a panoramic view of the disease and is a useful tool to plan treatment.

Case Report MAGNETOM Avanto

Aorta Coarctation

Paulo R. Schwartzman, M.D., Ph.D.

Hospital Moinhos de Vento, Porto Alegre, Brazil

Patient history

A 30-year-old woman complains of shortness of breath during exercise. The patient denies smoking or any previous lung problem. The physical examination reveals a systolic heart murmur and a pulse difference between arm and legs. An echo was performed and demonstrated normal left ventricular function, normal heart valves but a turbulent flow at proximal descending aorta.

MR Angiography (MRA) of the aorta was requested for diagnosis of a suspected aortic coarctation.

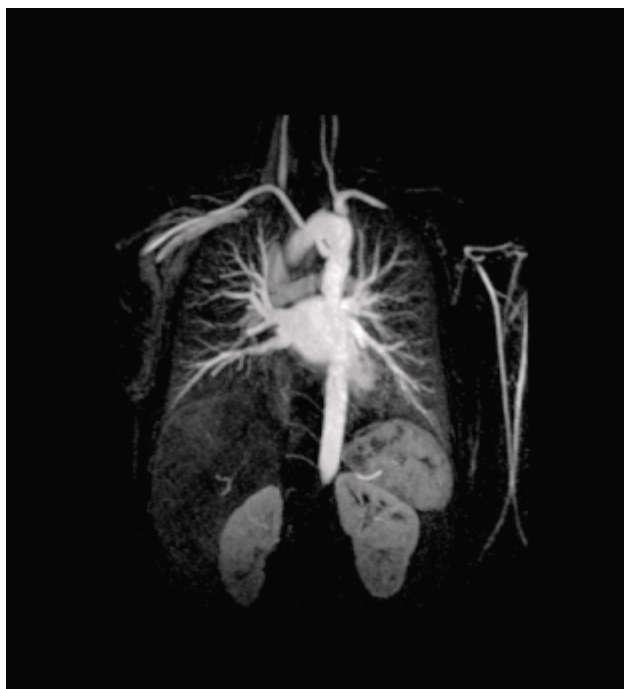Imaging findings

The MRA was reconstructed with different techniques and confirmed the diagnosis of coarctation of the aorta. However, this also revealed an aberrant left subclavian artery. This

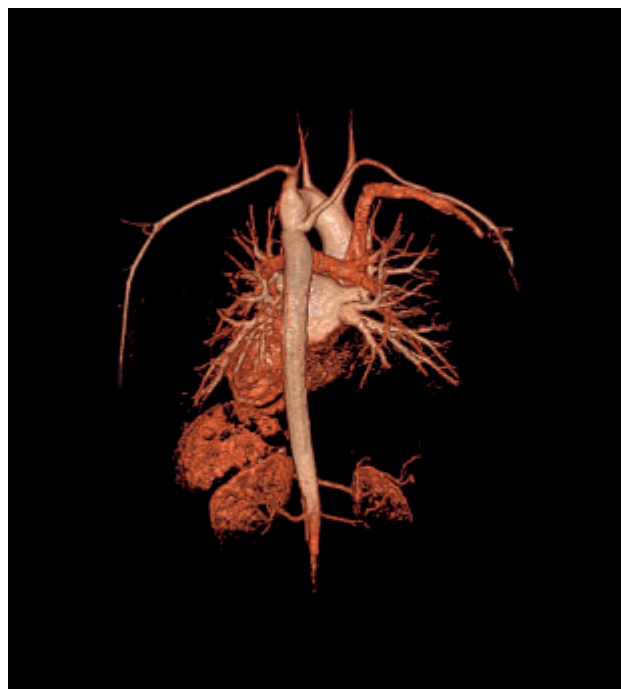diagnosis is an important point for surgical planning since re-implantation of the artery will be required. Thin maximum intensity projections (thinMIP) images (Fig. 1) illustrate the findings. In addition, Volume Rendering Technique (VRT) (Fig. 2) in different projections and colors demonstrates the vascular anomaly.

Discussion

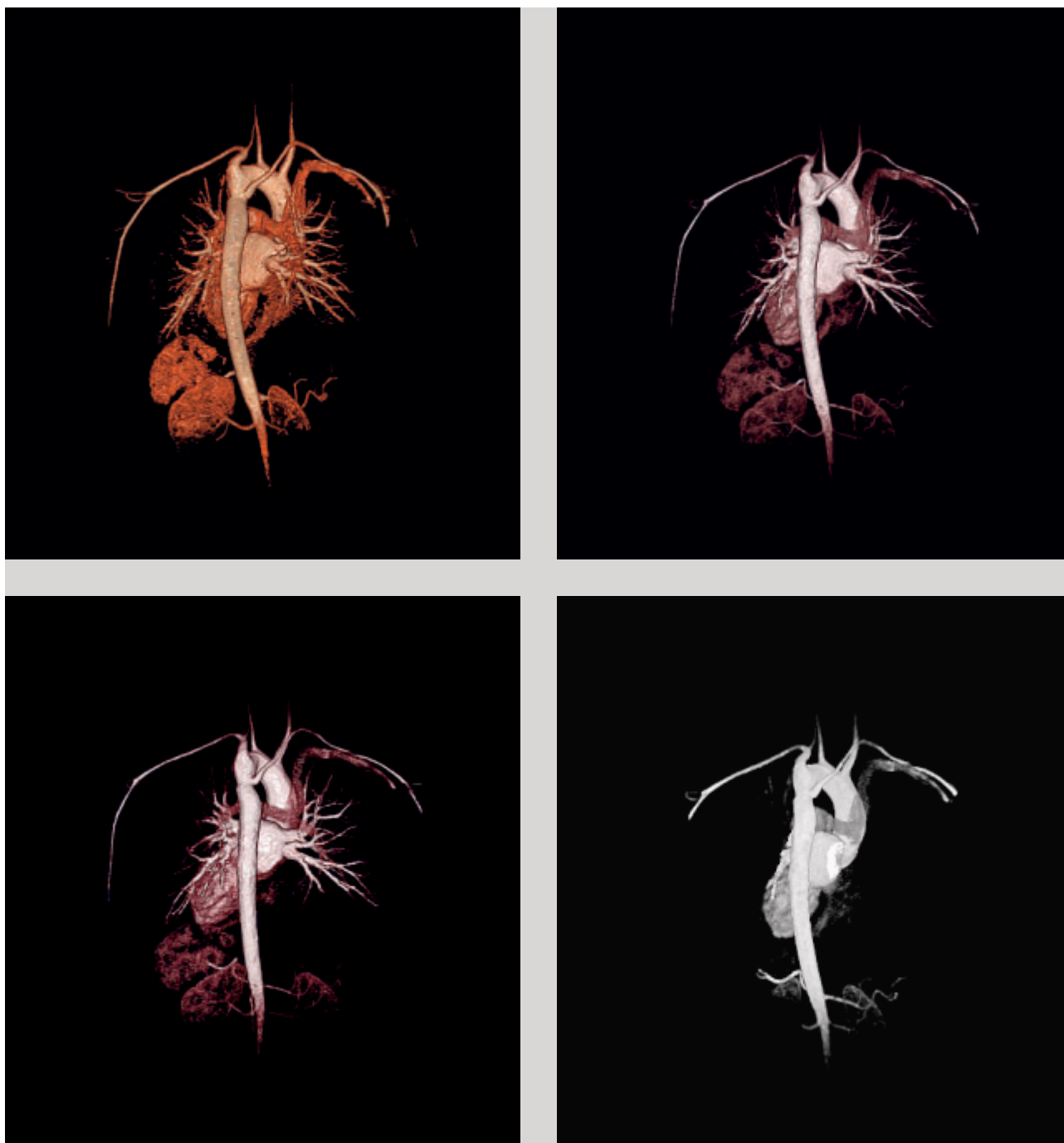
Coarctation of the aorta is one of the most common congenital heart diseases and is often under-diagnosed. The patient has symptoms only with severe aortic obstruction. Usually the vascular anomaly is suspected during a routine physical examination due to heart murmur or a pulse difference between upper and lower limbs. Echo is the first choice and



[Figure 1] ThinMIP reconstruction image of the thoracic aorta with coarctation of the aorta and aberrant left subclavian artery.



[Figure 2] Posterior view with VRT images demonstrating the vascular anomalies.



[Figure 2] Posterior view with VRT images demonstrating the vascular anomalies.

often has difficulty in visualizing the arch and the proximal portion of the descending aorta. Conventional angiography was used in the past, but currently its use is not acceptable due to risks related to the procedure. A good quality diagnostic image is essential to determine location and severity of lesion. And magnetic resonance angiography has become

the non-invasive procedure of choice due to an entire non-invasive visualization of the thoracic aorta. Multislice CT may be also used, but has the inconvenience of nephrotoxic contrast media and radiation exposure in usually young patients. This case characterizes a typical patient with long-standing aortic coarctation which is easily diagnosed by MRA.

Case Report MAGNETOM Avanto

Chest Pain and Myocarditis*

Paulo R. Schwartzman, M.D., Ph.D.

Hospital Moinhos de Vento, Porto Alegre, Brazil

Patient history

An 18-year-old athletic young man woke at 6 am with chest pain and intense sweating. After taking Tylenol and the persistence of the pain, the patient was taken to the emergency department. The ECG shows ST elevation in the anterior and lateral wall. The cardiac enzymes (CK, MB and troponin) were also elevated, suggesting acute myocardial infarction. The patient was taken to the cath lab, which shows normal coronary arteries. A cardiac MRI is requested to verify the presence and type of myocardial scar.

Imaging findings

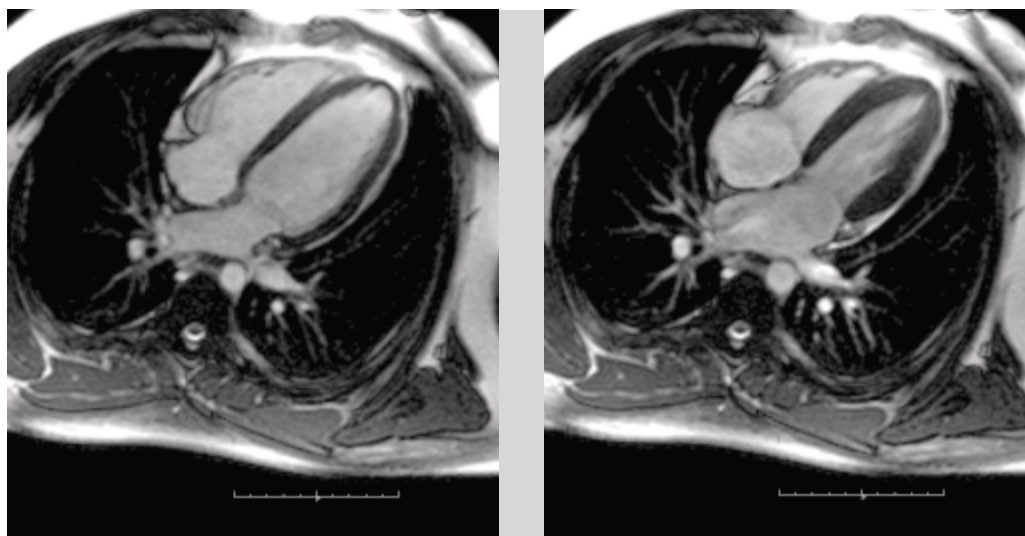
The cardiac magnetic resonance exam consisted of cine images with TrueFISP and gradient echo sequences with grid tagging to evaluate myocardial contractility. In addition, tissue characterization images were acquired 15 minutes after CM dose to detect myocardial fibrosis*.

The cine TrueFISP images acquired at long-axis 4 chamber view (Fig. 1) and 3 chamber view (Fig. 2) demonstrate normal contractility. The gradient echo with SPAMM images at the same long-axis positions as the TrueFISP, demonstrate normal segmental contraction (Fig. 3).

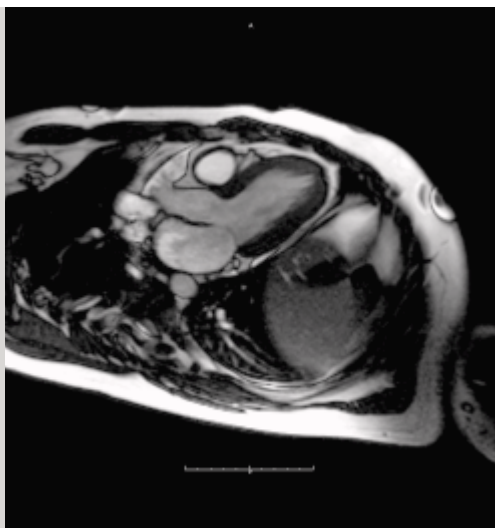
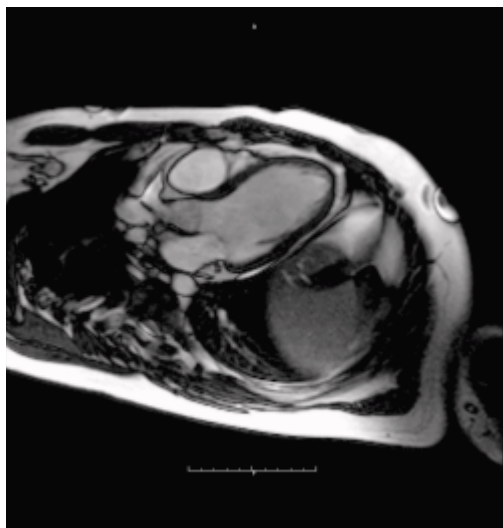
The tissue characterization images with increased intensity reveal a mesocardial fibrosis in the posterior and lateral wall suggestive of myocarditis.

Discussion

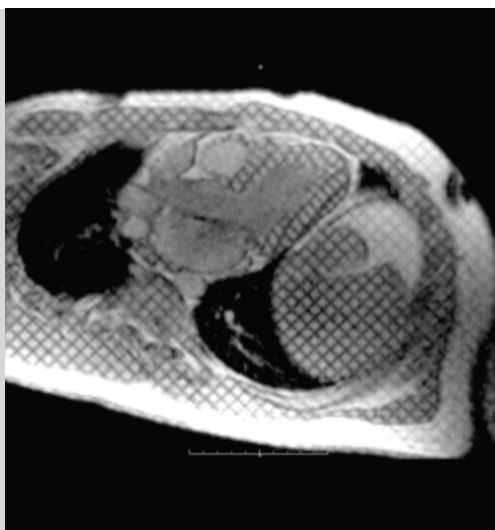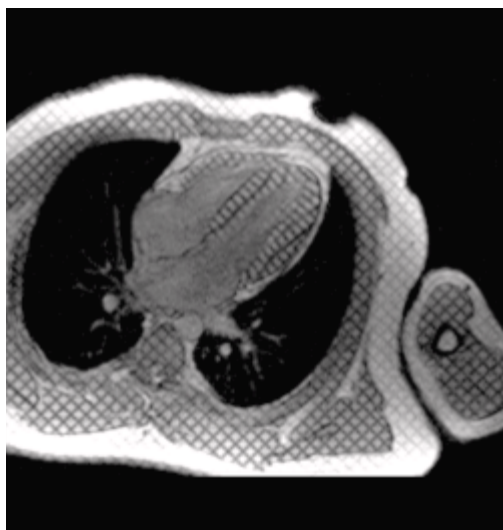Myocarditis is a difficult diagnosis. The symptoms may vary widely and not infrequently the patients are taken to the cath lab due to elevated cardiac enzymes to rule out myocardial infarction. The myocardial biopsy is negative in more than 50% of cases and imaging modalities have poor markers for inflammatory myocardial disease. Nuclear medicine may play a role in the diagnosis but the few studies in the international literature show controversial results. Recently, cardiac magnetic resonance has been used in the diagnosis of myocarditis and a typical mesocardial / subepicardial fibrosis, most common in the posterior and lateral wall, suggests the diagnosis. This case represents a typical patient with a difficult diagnosis with normal segmental contractility regardless of the presence of myocardial fibrosis. The elevated cardiac enzymes demonstrated myocardial injury, confirmed by high spatial resolution cardiac MR.



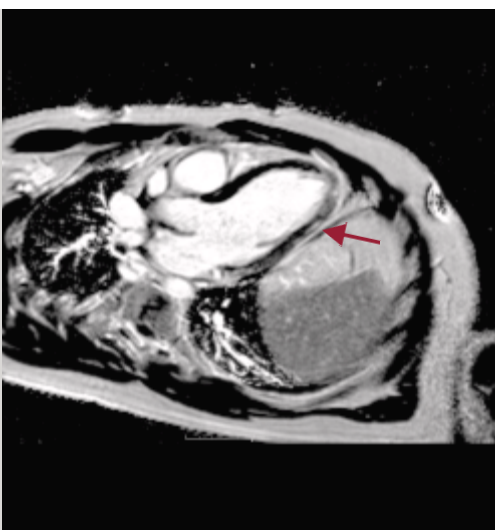
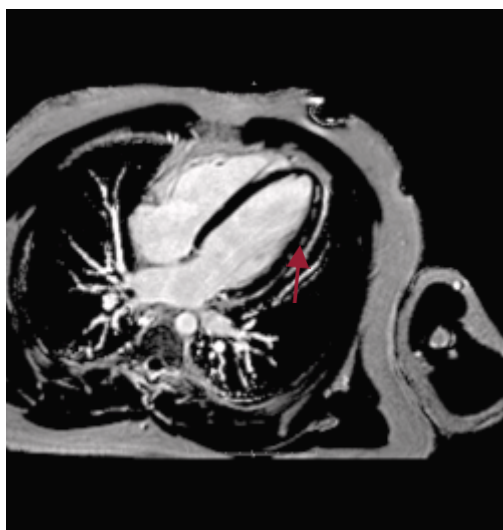
[Figure 1]
4-chamber
view at diastole
(left) and at end-
systole (right)
demonstrating nor-
mal contractility.



[Figure 2]
3-chamber view
at diastole (left)
and at end-systole
(right) demon-
strating normal
contractility.



[Figure 3]
The gradient
echo with grid
tagging images
at end-systole in
four (left) and
three-chamber
(right) view
demonstrating
normal segmen-
tal contraction.



[Figure 4]
Tissue characteri-
zation 4- and
3-chamber view
demonstrating
myocardial fibrosis
(arrow).

*The information about this product is preliminary.

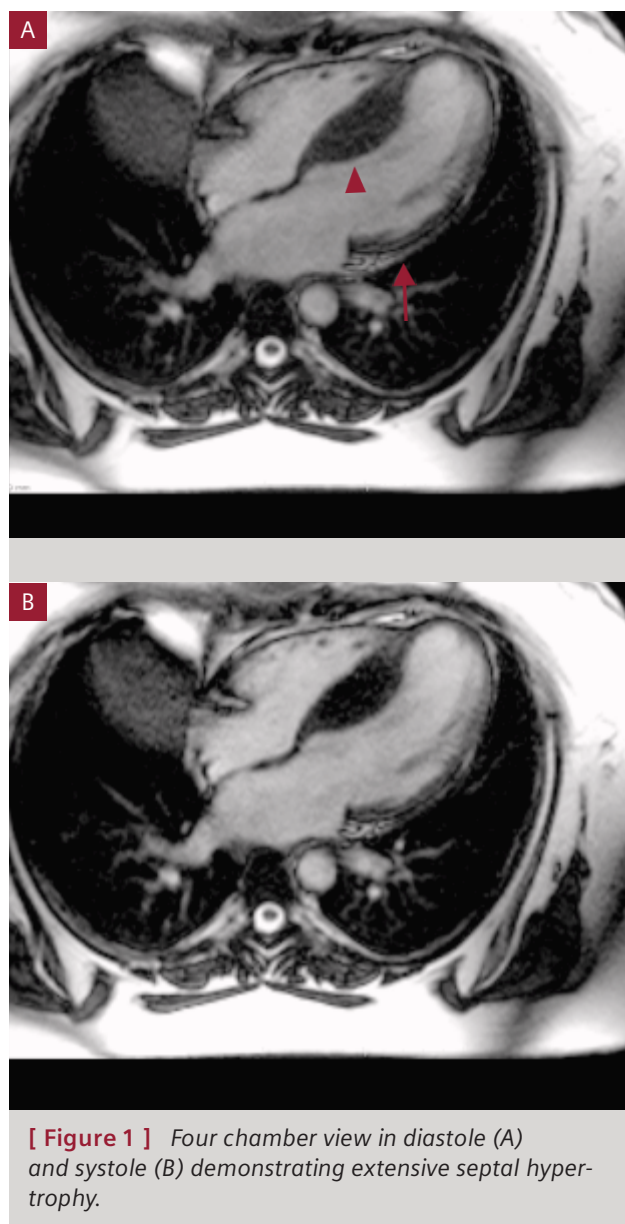
The product is under development. It is not commercially available in the US and its future availability cannot be assured.

Case Report MAGNETOM Sonata

Hypertrophic Cardiomyopathy and Stress Perfusion

Paulo R. Schwartzman, M.D., Ph.D.

Escola Paulista de Medicina, Unifesp, São Paulo, Brazil



Patient history

A 38-year-old female complained of chest pain associated with exercise, which resolved after 2–3 min of rest. Echo demonstrated an asymmetrical septal hypertrophy with no left ventricular outflow obstruction. A stress nuclear test was performed and no perfusion deficit was detected. Stress perfusion cardiac magnetic resonance was requested to define if chest pain was secondary to a perfusion deficit.

Stress MR protocol*

The cardiac magnetic resonance exam protocol was as follows:

1. Cine-images on three long-axis views (two, three and four chamber view) and three short axis-views (base, mid-ventricular and apical).
2. Dipyridamole stress perfusion images in four short axis slices acquired 2 min after a 4 min dipyridamole injection and CM.
3. Short axis TrueFISP cine images were obtained from base to apex to define LV volumes.
4. Rest perfusion on the same four short axis views as the slices of stress perfusion.
5. Tissue characterization images acquired 15 min after CM on the same image plane as previous long axis and short-axis views to define the presence of myocardial fibrosis.

Imaging findings

The TrueFISP cine images in the four-chamber view (Fig. 1) and short-axis view (Fig. 2) documented the extensive (32 mm – arrowhead) and asymmetrical (arrow) hypertrophy.

The stress perfusion* short-axis image (Fig. 3, left) demonstrates a septal perfusion deficit (arrow) during the gadolinium injection. The rest perfusion image demonstrates normal (arrow) perfusion (Fig. 3, right).

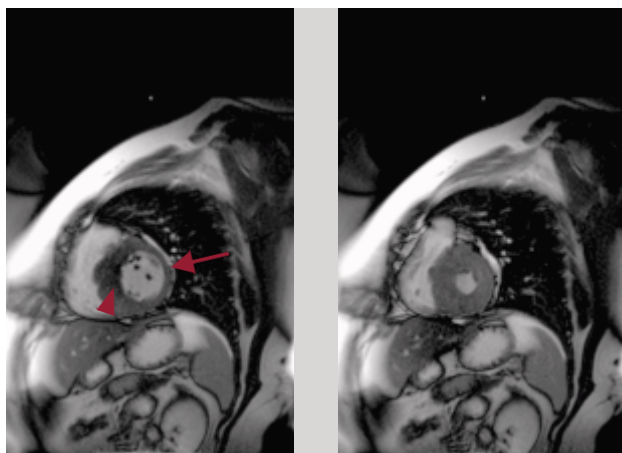
Tissue characterization image* after CM in the 4 chamber view (Fig. 4, left) and short-axis view (Fig. 4, right) demonstrate the septal hypertrophy and absence of myocardial fibrosis.

Discussion

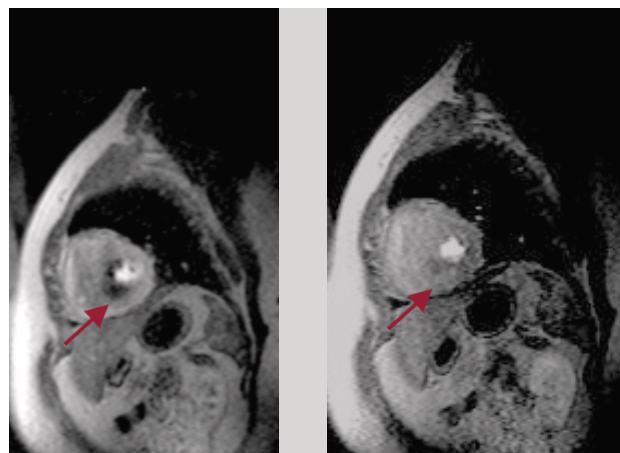
The characteristic finding of inappropriate myocardial hypertrophy in the absence of an obvious cause for the hypertrophy is the marker for hypertrophic cardiomyopathy. This is a genetic disease associated with eight different genes, and frequently it does not present with symptoms. Often the diagnosis is made by a routine echo. Several patients may complain of chest pain and dyspnea, despite normal coronary arteries. The perfusion deficit with normal coronary arteries is secondary to a disproportion of extensive hypertrophy and normal coronary flow.

Nuclear stress testing is usually performed to rule out coronary artery disease in patients with chest pain and hyper-

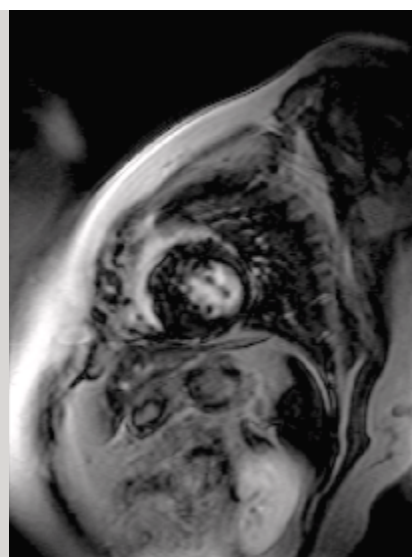
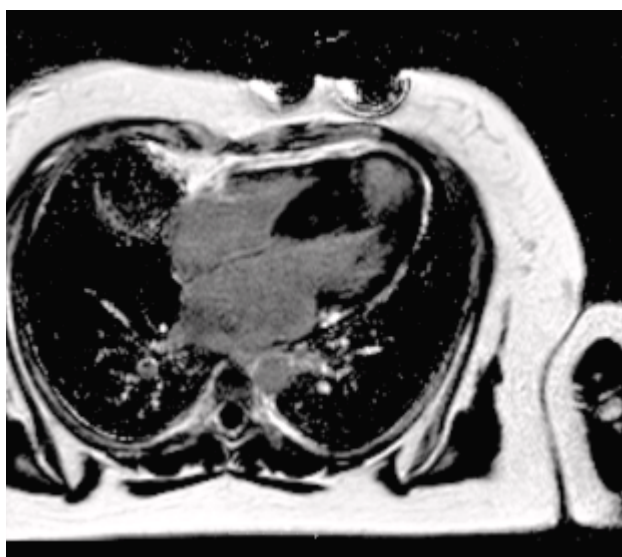
trophic cardiomyopathy. However due to suboptimal spatial resolution, smaller perfusion deficits may not be detected. This case represents an application of cardiac magnetic resonance in patients with chest pain and normal stress imaging test. The exercise-related chest pain in this young female patient with asymmetrical septal cardiomyopathy, normal coronary arteries, normal nuclear stress testing – but an abnormal perfusion deficit – was properly diagnosed by cardiac magnetic resonance. This deficit is explained by an imbalance of severe hypertrophy and normal myocardial perfusion.



[Figure 2] Basal short axis images in diastole (left) and systole (right) demonstrating the septum hypertrophy.



[Figure 3] Stress perfusion basal short axis view 2 minutes after the end of a 4-minute dipyridamole infusion (left) and rest perfusion (right) images.



[Figure 4] Delayed-enhancement images 10 min. after gadolinium injection (0.4 ml/kg) demonstrate the absence of myocardial fibrosis on the four-chamber view (left) and basal short axis-view (right).

*The information about this product is preliminary.

The product is under development. It is not commercially available in the US and its future availability cannot be assured.

Case Report MAGNETOM Sonata Left Subclavian Artery Occlusion*

Paulo R. Schwartzman, M.D., Ph.D.

Escola Paulista de Medicina, Unifesp, São Paulo, Brazil

Patient History

51-year-old woman complains of left arm pain, which lasts for 15–20 minutes. The pain is increased with arm exercise movements and decreases with rest. At examination, there is a slight decrease on radial pulse (3+/4) compared to right radial pulse (4+/4).

A doppler was performed and suggested decreased flow to left arm. Magnetic resonance angiography (MRA) was requested to define the presence or absence of arterial stenosis.

Imaging findings

An MRA was performed on a Siemens MAGNETOM Sonata using care-bolus technique (Fig. 1) followed by a 3-dimensional (3-D) coronal MRA acquisition (Fig. 2). The 3-D acquisition consisted of a coronal slab positioned on the middle of the thorax with 80 slices of 1.5 mm thickness. Subtraction was performed (Fig. 3) between the images with and without contrast, documenting the proximal left subclavian

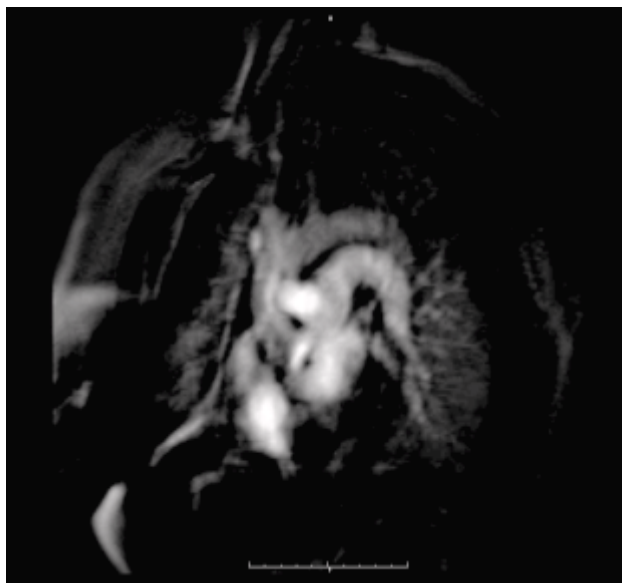
artery occlusion. Also the mid and distal flow filling due to collaterals was confirmed.

Thick (Fig. 4) and thin (Fig. 5) maximal intensity projections (MIP) were performed confirming the left subclavian artery occlusion.

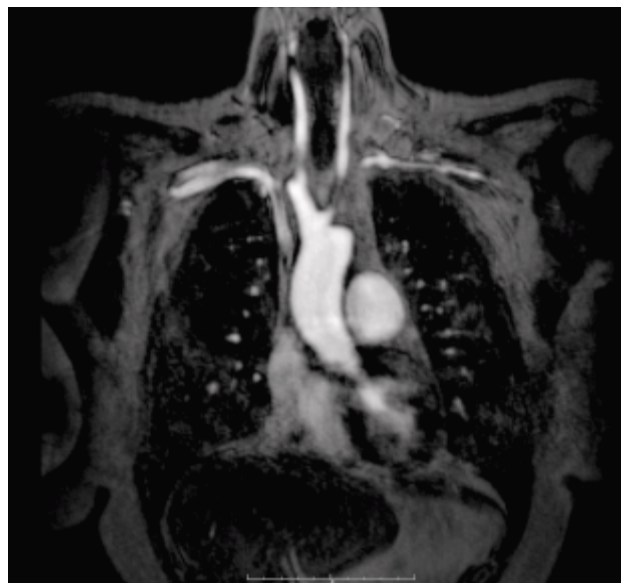
Discussion

Magnetic resonance angiography has been used routinely for several years, but recently with the improvement in MRA hardware and software, the results have been more reliable. The goal of MR angiography is to detect vascular abnormalities non-invasively. This case represents a nice example of how MR angiography can be utilized to confirm or exclude vascular pathologies.

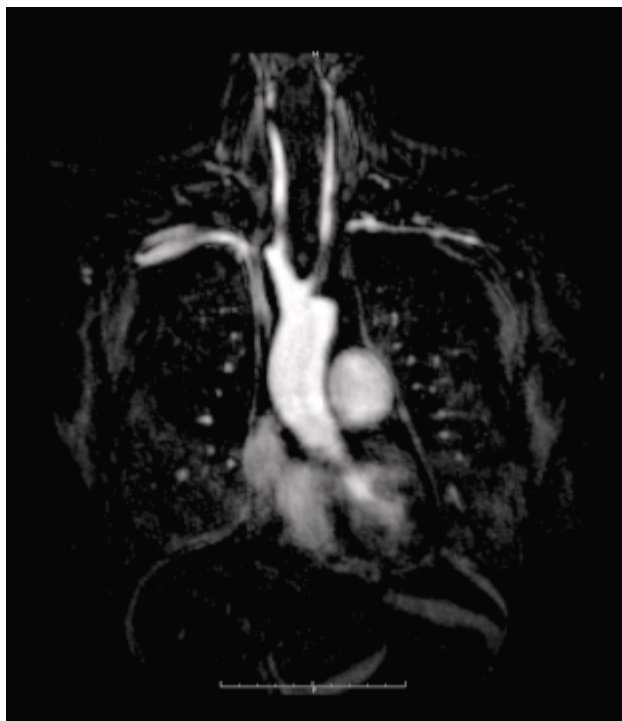*The information about this product is preliminary. The product is under development. It is not commercially available in the US and its future availability cannot be assured.



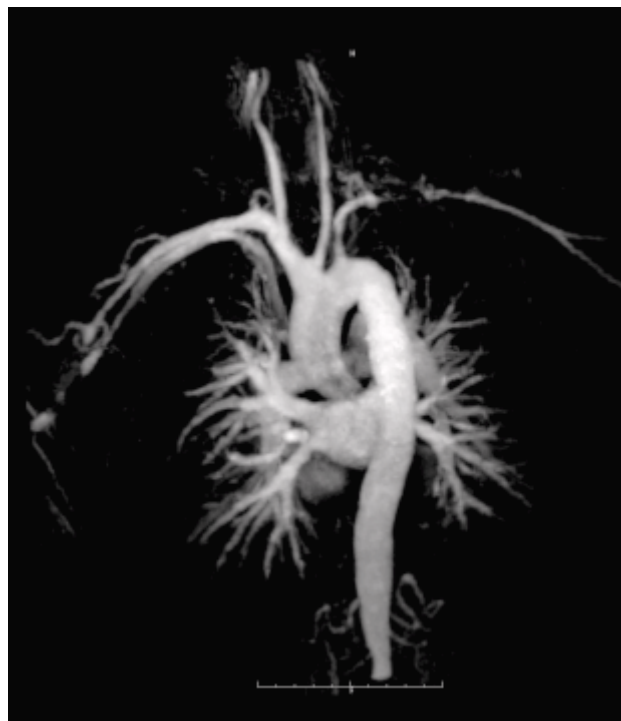
[Figure 1] Care-bolus technique to define the best moment for MRA acquisition.



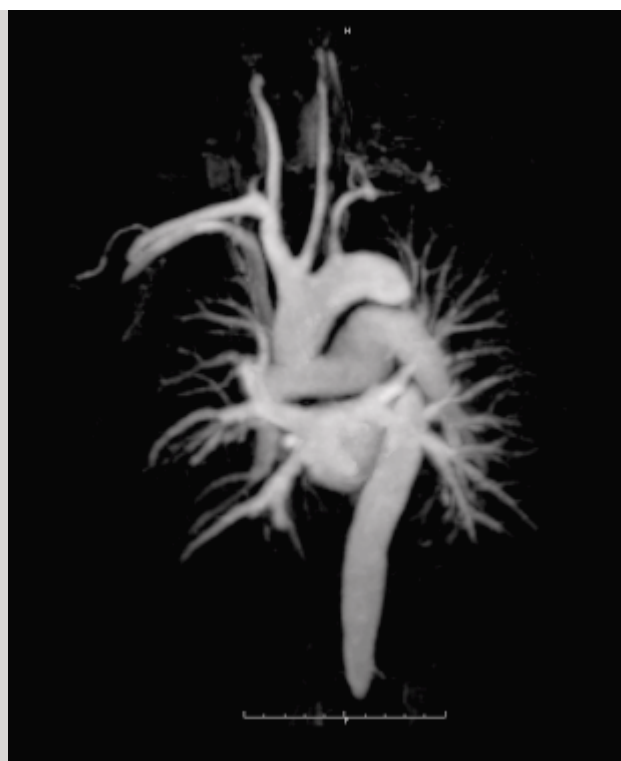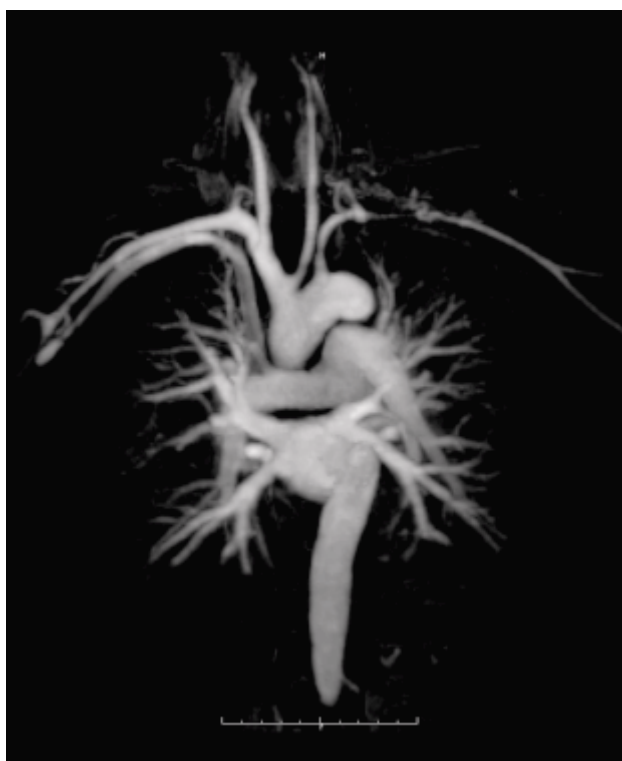[Figure 2] Raw data MR Angiography image shows the subclavian artery stenosis.



[Figure 3] Raw data MR Angiography image shows the subclavian artery stenosis.



[Figure 4] MIP image shows the subclavian artery stenosis.



[Figure 5] Raw data MR Angiography images showing the subclavian artery stenosis.

Special Offer: Cardiovascular

Cardiovascular MR imaging is increasingly becoming a part of the daily routine of MR users. The exciting applications includes, for example, cardiac function, flow analysis, morphologic diagnosis, tissue characterization and angiographic information.

Siemens offers a wide range of software and hardware options for cardiovascular MR. **And from now through June 2007 these are available to our existing MAGNETOM customers at special promotion conditions.**

For more information or an offer, please contact your local Siemens representative. For more information about your closest Siemens office please refer to:

www.siemens.com/offices.

Or send an e-mail to magnetomworld@siemens.com to learn more about this promotion.

Software and hardware eligible for this promotion:

MAGNETOM Avanto

Cardiac Options

- PMU Wireless
- Physio Control
- Advanced Cardiac
- Flow Quantification
- Argus Flow
- Advanced High Order Shim
- Argus Function
- Argus Dynamic Signal
- Interactive Real Time
- Body Matrix coils

Vascular

- syngo Vessel View
- syngo 3D VRT (Volume Rendering Technique)
- syngo Fly Through
- Peripheral Angiography Matrix coil

MAGNETOM Espree

Cardiac Options

- PMU Wireless
- Advanced Cardiac
- Flow Quantification
- Argus Flow
- Advanced High Order Shim
- Argus Function
- Argus Dynamic Signal
- Interactive Real Time
- Body Matrix coils

Vascular

- syngo Vessel View
- syngo 3D VRT (Volume Rendering Technique)
- syngo Fly Through
- Peripheral Angiography Matrix coil

MAGNETOM Symphony, A Tim System

Cardiac Options

- PMU Wireless
- Physio Control
- Advanced Cardiac
- Flow Quantification
- Argus Flow
- Advanced High Order Shim
- Argus Function
- Argus Dynamic Signal
- Interactive Real Time
- Body Matrix coils

Vascular

- syngo Vessel View
- syngo 3D VRT (Volume Rendering Technique)
- syngo Fly Through
- Peripheral Angiography Matrix coil

MAGNETOM Trio, A Tim System

Cardiac Options

- PMU Wireless
- Physio Control
- Advanced Cardiac
- Flow Quantification
- Argus Flow
- Advanced High Order Shim
- Argus Function
- Argus Dynamic Signal
- Interactive Real Time
- Body Matrix coils

Vascular

- syngo Vessel View
- syngo 3D VRT (Volume Rendering Technique)
- syngo Fly Through
- Peripheral Angiography Matrix coil

MAGNETOM Harmony**Cardiac Options**

- | | |
|----------------------------|-------------------------|
| ■ PMU Electronics | ■ Argus Function |
| ■ syngo Advanced Cardiac | ■ Argus Dynamic Signal |
| ■ Flow Quantification | ■ Interactive Real Time |
| ■ Argus Flow | |
| ■ Advanced High Order Shim | |

Vascular

- | | |
|---|-----------------------------|
| ■ syngo Vessel View | ■ syngo Panoramic Table |
| ■ syngo 3D VRT (Volume Rendering Technique) | ■ syngo Advanced Angio Pack |
| ■ syngo Fly Through | ■ syngo Core Bolus |
| ■ Peripheral Angiography Matrix coil | ■ Interact. RM. Imaging |

- | | |
|----------------------|--|
| ■ Cardiac MR Pack SW | |
| ■ Cardiac MR Pack HW | |

MAGNETOM Sonata**Cardiac Options**

- | | |
|----------------------------|-------------------------|
| ■ PMU Electronics | ■ Argus Function |
| ■ syngo Advanced Cardiac | ■ Argus Dynamic Signal |
| ■ Flow Quantification | ■ Interactive Real Time |
| ■ Argus Flow | ■ Argus Viewer |
| ■ Advanced High Order Shim | |

Vascular

- | | |
|---|-----------------------------|
| ■ syngo Vessel View | ■ syngo Panoramic Table |
| ■ syngo 3D VRT (Volume Rendering Technique) | ■ syngo Advanced Angio Pack |
| ■ syngo Fly Through | ■ syngo Core Bolus |
| ■ Peripheral Angiography Matrix coil | ■ Large FoV Adapter |
| | ■ Interact. RM. Imaging |

- | | |
|----------------------|---------------|
| ■ Cardiac MR Pack SW | ■ Exam Room |
| ■ Cardiac MR Pack HW | ■ PMU Display |

MAGNETOM Symphony**Cardiac Options**

- | | |
|----------------------------|-------------------------|
| ■ PMU Electronics | ■ Argus Function |
| ■ syngo Advanced Cardiac | ■ Argus Dynamic Signal |
| ■ Flow Quantification | ■ Interactive Real Time |
| ■ Argus Flow | ■ Argus Viewer |
| ■ Advanced High Order Shim | |

Vascular

- | | |
|---|-----------------------------|
| ■ syngo Vessel View | ■ syngo Panoramic Table |
| ■ syngo 3D VRT (Volume Rendering Technique) | ■ syngo Advanced Angio Pack |
| ■ syngo Fly Through | ■ syngo Core Bolus |
| ■ Peripheral Angiography Matrix coil | ■ Large FoV Adapter |
| | ■ Interact. RM. Imaging |

- | | |
|-------------------------|----------------------|
| ■ Cardiac MR Pack SW | ■ Exam Room |
| ■ Cardiac MR Pack HW | ■ PMU Display |
| ■ Active ECG Electrodes | ■ CP Body Array Flex |

MAGNETOM Trio**Cardiac Options**

- | | |
|-----------------------------|-------------------------|
| ■ PMU Electronics | ■ Argus Function |
| ■ Advanced Cardiac | ■ Argus Dynamic Signal |
| ■ syngo Flow Quantification | ■ Interactive Real Time |
| ■ Argus Flow | ■ Argus Viewer |
| ■ Advanced High Order Shim | |

Vascular

- | | |
|---|--------------------------------------|
| ■ syngo Vessel View | ■ syngo Fly Through |
| ■ syngo 3D VRT (Volume Rendering Technique) | ■ Peripheral Angiography Matrix coil |

- | | |
|---------------|--|
| ■ Exam Room | |
| ■ PMU Display | |

MRI: New Terminology for Implants and Devices

Frank G. Shellock, Ph.D., FACC

Adjunct Clinical Professor of Radiology and Medicine, University of Southern California, Los Angeles, USA
www.MRIsafety.com, www.IMRSEr.org

Prior to allowing patients and other individuals into the MRI environment, careful screening is performed to determine the presence of implants or devices that may pose hazards or risks [1]. Once an implant or device is identified, the labeling for a given object is examined and a decision is made with regard to whether or not it is acceptable for the patient to undergo an MRI procedure or for an individual to enter the MRI environment.

“Old” Terminology

The terminology applied to implants and devices relative to the MRI environment has evolved over the years. In 1997, the Food and Drug Administration, Center for Devices and Radiological Health, proposed definitions for the terms “MR Safe” and “MR Compatible” [2]. These terms are defined as follows: **MR Safe** – the device, when used in the MRI environment, has been demonstrated to present no additional risk to the patient or other individual, but may affect the quality of the diagnostic information. The MRI conditions in which the device was tested should be specified in conjunction with the term MR safe since a device which is safe under one set of conditions may not be found to be so under more extreme MRI conditions.

MR Compatible – a device shall be considered “MR compatible” if it is MR safe and the device, when used in the MRI environment, has been demonstrated to neither significantly affect the quality of the diagnostic information nor have its operations affected by the MR system. The MRI conditions in which the device was tested should be specified in conjunction with the term MR safe since a device which is safe under one set of conditions may not be found to be so under more extreme MR conditions.

Using this terminology, MR safety testing of an implant or object involved assessments of magnetic field interactions, heating, and, in some cases, induced electrical currents while MR compatibility testing required all of these as well as characterization of artifacts. In addition, it may have been necessary to evaluate the impact of various MRI conditions on the functional or operational aspects of an implant or device.

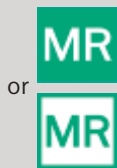
“New” Terminology

Over the years, manufacturers generally used the terms MR safe and MR compatible to label medical devices. However, in time it became apparent that these terms were confusing and were often used interchangeably or incorrectly [3]. Therefore, in an effort to clarify the terminology and, more importantly, because the misuse of these terms could result in serious accidents for patients and other individuals, the MR task group of the American Society for Testing and Materials (ASTM) International developed a new set of terms with associated icons [4]. The new terms, MR Safe, MR Conditional, and MR Unsafe are defined by the ASTM document [4], as follows.

MR Safe – an item that poses no known hazards in all MRI environments. Using the new terminology, “MR safe” items include non-conducting, non-metallic, non-magnetic items such as a plastic Petri dish. An item may be determined to be MR Safe by providing a scientifically based rationale rather than test data.

MR Conditional – an item that has been demonstrated to pose no known hazards in a specified MRI environment with specified conditions of use. Field conditions that define the MRI environment include static magnetic field strength, spatial gradient, dB/dt (time varying magnetic fields), radio frequency (RF) fields, and specific absorption rate (SAR). Additional conditions, including specific configurations of the item (e.g., the routing of leads used for a neurostimulation system), may be required.

For MR Conditional items, the item labeling includes results of testing sufficient to characterize the behavior of the item in the MRI environment. In particular, testing for items that may be placed in the MRI environment should address magnetically induced displacement force and torque, and RF heating. Other possible safety issues include but are not limited to, thermal injury, induced currents/voltages, electromagnetic compatibility, neurostimulation, acoustic noise, interaction among devices, and the safe functioning of the item and the safe operation of the MR system. Any parameter that affects the safety of the item should be listed and any condition that is known to produce an unsafe condition must be described.



The "MR safe" icon consists of the letters 'MR' in green in a white square with a green border, or the letters 'MR' in white within a green square.



The "MR conditional" icon consists of the letters 'MR' in black inside a yellow triangle with a black border.



The "MR unsafe" icon consists of the letters 'MR' in black on a white field inside a red circle with a diagonal red band.

MR Unsafe – an item that is known to pose hazards in all MRI environments.

MR Unsafe items include magnetic items such as a pair of ferromagnetic scissors.

In addition to the new terms, the ASTM document introduced corresponding icons, consistent with international standards for colors and shapes of safety signs. The icons are intended to be used on items that may be brought into or near the MRI

environment as well as in product labeling. The icons may be reproduced in color or in black and white, however the use of color is encouraged because of the added visibility. The "MR unsafe" icon consists of the letters 'MR' in black on a white field inside a red circle with a diagonal red band.

For MR Conditional items, the item labeling must include results of testing sufficient to characterize the behavior of the item in the MRI environment.

Notably, the new terminology is not being applied retrospectively to implants and devices that have already received FDA approved labeling using the terms "MR safe" or "MR compatible".

Hopefully, the utilization of this new terminology will serve to elucidate matters related to biomedical implants and devices and help to ensure the safe use of MRI technology.

References

- [1] Shellock FG. Reference Manual for Magnetic Resonance Safety, Implants, and Devices: Update 2006. Biomedical Research Publishing Group, Los Angeles, CA, 2006.
- [2] United States Food and Drug Administration, Center for Devices and Radiological Health, A Primer on Medical Device Interactions with Magnetic Resonance Imaging Systems. <http://www.fda.gov/cdrh/ode/primerf6.html>, 1997.
- [3] Shellock FG, Crues JV. Commentary: MR safety and the American College of Radiology White Paper. American Journal of Roentgenology 2002; 178: 1349–1352.
- [4] American Society for Testing and Materials (ASTM) International, Designation: F2503–05. Standard Practice for Marking Medical Devices and Other Items for Safety in the Magnetic Resonance Environment. ASTM International, West Conshohocken, PA, 2005.

Refurbished MRI Systems Now Available through the Proven Excellence Program

The Refurbished Systems division in the USA recently incorporated MRI into its Proven Excellence product portfolio. Proven Excellence (PE) is Siemens' multi-modality medical equipment refurbishment program. The MAGNETOM Symphony, Harmony, and Concerto are proven products from our MRI equipment portfolio that can meet your everyday clinical and technological demands. These systems are available at an affordable price point through our Proven Excellence Program.

The program starts with an initial inspection of each system, taking into consideration age, condition, service history, performance and upgradeability of software and hardware. After a professional de-installation and transportation to our Siemens Refurbishing Systems facility, the system is thoroughly cleaned, disinfected and painted, worn parts are

replaced with original spare parts and applicable software updates are performed. After passing a complete system check with original test equipment and procedures, the system is rewarded with our Proven Excellence quality seal. This seal represents the fulfillment of the strict specifications of relevant international norms and standards as well as security regulations.

After transportation to the customer site, the system is installed by our Siemens installation and service team of trained technicians.

With the Proven Excellence Program, Siemens Medical Solutions also offers its customers various flexible financing solutions and service contracts as well as a warranty typically equivalent to that of new systems. Moreover, spare parts are generally available for 5 years.

MR Safety at 3 Tesla: Bare Metal and Drug Eluting Coronary Stents

Frank G. Shellock, Ph.D., FACC

Adjunct Clinical Professor of Radiology and Medicine, University of Southern California, Los Angeles, USA
www.MRIsafety.com, www.IMRSE.org

Patients with coronary artery disease are often treated by percutaneous transluminal coronary angioplasty (PTCA). Re-narrowing at the angioplasty site, or restenosis, occurs in as many as 50% of patients following PTCA. Therefore, after coronary artery intervention, either a bare metal or drug eluting stent is placed in an effort to prevent restenosis. There is considerable attention focused on the use of drug eluting stents to prevent coronary artery restenosis that tends to occur in a substantial number of patients following stenting with "bare" devices. Studies have reported that drug eluting stents reduce the incidence of target vessel failure compared to uncoated metallic stents. As such, drug eluting stents are now used on a widespread basis (upwards of 80%) in patients with coronary artery disease.

Recently, MR safety information has been obtained for several bare wire and drug eluting coronary stents, which have been reported to be safe for patients undergoing MR procedures at 3 Tesla or less (i.e., based on assessments of magnetic field interactions and MRI-related heating). These coronary artery stents include the following:

Endeavor Drug Eluting Coronary Artery Stent (Medtronic Vascular) – Through non-clinical testing, the Endeavor stent has been shown to be MRI safe at field strengths of 3 Tesla or less, and a maximum whole body averaged specific absorption rate (SAR) of 2.0 W/kg for 15 minutes of MRI. The Endeavor stent should not migrate in this MRI environment. MRI at 3T or less may be performed immediately following the implantation of the Endeavor stent. Non-clinical testing has not been performed to rule out the possibility of stent migration at field strengths higher than 3 Tesla.

In this testing, the stent produced a maximum temperature rise of 0.5 degrees C at a maximum whole body averaged SAR of 2.0 W/kg for 15 minutes of MRI.

MR imaging quality may be compromised if the area of interest is in the exact same area or relatively close to the position of the stent.

TAXUS Express Paclitaxel-Eluting Coronary Stent (Boston Scientific Corporation) – Through non-clinical testing, the TAXUS Express stent has been shown to be MRI safe at field strengths of 3 Tesla or less, and a maximum whole body averaged specific absorption rate (SAR) of 2.0 W/kg for 15 minutes of MRI. The TAXUS Express stent should not migrate in this MRI environment. MRI at 3T or less may be performed immediately following the implantation of the TAXUS Express stent. Non-clinical testing has not been performed to rule out the possibility of stent migration at field strengths higher than 3 Tesla.

In this testing, the stent produced a maximum temperature rise of 0.65 degrees C at a maximum whole body averaged SAR of 2.0 W/kg for 15 minutes of MRI. The effect of heating in the MRI environment was similar for overlapping bare metal stents (2 to 5-mm overlap at the ends), made of the same stainless steel material and having the same stent design. The effect of heating in the MRI environment on stents with fractured struts is not known. The temperature rise of 0.65 degrees C for 15 minutes is calculated to result in an increase in cumulative drug release of 0.001% of the total dose.

MR imaging quality may be compromised if the area of interest is in the exact same area or relatively close to the position of the stent.

Liberté Coronary Artery Stent (bare metal coronary artery stent, Boston Scientific Corporation) – The Liberté Stent has been shown to be MR safe at field strengths of 3 Tesla or less, and a maximum whole body averaged specific absorption rate (SAR) of 2.0 W/kg for 15 minutes of MR imaging. The Liberté Stent should not migrate in this MR environment. MR imaging at 3T or less may be performed immediately following the implantation of the Liberté Stent.

In this testing, the stent experienced a maximum temperature rise of 0.65 degrees C at a maximum whole body averaged SAR of 2 W/kg for 15 minutes of MR imaging. The temperature rise was observed to be similar for comparable bare

metal overlapping stents (2 to 5 mm overlap at the ends). Heating has not been determined for fractured struts. MR imaging quality may be compromised if the area of interest is in the exact same area or relatively close to the position of the stent.

This stent has not been evaluated to determine if it is safe in MRI systems with field strengths greater than 3T.

TAXUS Liberté Paclitaxel-Eluting Coronary Stent (Boston Scientific Corporation) – Through non-clinical testing, the TAXUS Liberté stent has been shown to be MRI safe at field strengths of 3 Tesla or less, and a maximum whole body averaged specific absorption rate (SAR) of 2.0 W/kg for 15 minutes of MRI. The TAXUS Liberté stent should not migrate in this MRI environment. MRI at 3T or less may be performed immediately following the implantation of the TAXUS Liberté stent. Non-clinical testing has not been performed to rule out the possibility of stent migration at field strengths higher than 3 Tesla. In this testing, the stent produced a maximum temperature rise of 0.65 degrees C at a maximum whole body averaged SAR of 2.0 W/kg for 15 minutes of MRI. The effect of heating in the MRI environment was similar for overlapping bare metal stents (2 to 5 mm overlap at the ends), made of the same stainless steel material and having the same stent design. The effect of heating in the MRI environment on stents with fractured struts is not known. The temperature rise of 0.65 degrees C for 15 minutes is calculated to result in an increase in cumulative drug release of 0.001% of the total dose.

MR imaging quality may be compromised if the area of interest is in the exact same area or relatively close to the position of the stent.

CYPHER Sirolimus-eluting Coronary Stent (Cordis Corporation/Johnson and Johnson) – Through non-clinical testing, single and two overlapping CYPHER Stents have been shown to be MRI safe at field strengths of 3 Tesla or less, and a maximum whole body averaged specific absorption rate (SAR) of 4.0 W/kg for 15 minutes of MRI. Single and two over-

lapping CYPHER Stents should not migrate in this MRI environment. Non-clinical testing has not been performed to rule out the possibility of stent migration at field strengths higher than 3 Tesla.

In this testing, single CYPHER Stents up to 33 mm in length produced a temperature rise of less than 1 degree C, and two overlapped 33 mm length CYPHER Stents produced a temperature rise of less than 2 degrees C at a maximum whole body averaged specific absorption rate (SAR) of 4.0 W/kg for 15 minutes of MRI. The effect of heating in the MRI environment for stents with fractured struts is not known. The effect of heating in the MRI environment on the drug or polymer coating is not known.

MR imaging quality may be compromised if the area of interest is in the exact same area or relatively close to the position of the stent.

Note: "TAXUS" is the trademark name on the drug coating, and refers to the drug eluting coating addition to the bare metal stent. As such, when there is the addition of the drug eluting coating, it will be referred to as the TAXUS and then the specific name of the stent. For example, TAXUS Express stent. The bare metal stent does not contain the TAXUS prefix.

Note: This statement applies to all currently marketed CYPHER Stents in the United States.

References

Shellock FG, Forder J. Drug eluting coronary stent: In vitro evaluation of magnet resonance safety at 3-Tesla. *Journal of Cardiovascular Magnetic Resonance* 7: 415–419, 2005.

2nd MAGNETOM World Pediatric User Meeting, February 17–19, 2006

Peter Kreisler, Ph.D.

Siemens Medical Solutions, MR Scientific Application Support, Erlangen, Germany

The Siemens MR application development group initiated the 2nd Pediatric User Meeting.

The meeting, held in Philadelphia, Pennsylvania, USA, was attended by approximately 50 internationally-known pediatric radiologists and experienced technologists from the US, Germany, Great Britain, the Netherlands, Belgium, Austria and Australia.

The whole of the first day (Saturday) was dedicated to clinically focused presentations from many MAGNETOM users. Contributions were grouped into the following sub-topics

- Neuro Imaging
- Neuro Spectroscopy and Neuro Research
- Cardiac Imaging
- Body Imaging
- Orthopedic Imaging
- Fetal Imaging

The presentations gave a very distinct overview on the range of clinical questions that are answered by the high performance MR scanners of today. The participants use MAGNETOM Symphony, MAGNETOM Avanto and MAGNETOM Trio. The final presentation on fetal imaging* – a domain for ultrasound – ranged from a demonstration of the capabilities of this established technique right through to advanced 3D capabilities.

Sunday morning started with presentations on current developments at Siemens with respect to the upcoming software version *syngo* MR B13. The focus was on Clinical Applications, Advanced Neuro, Spectroscopy and Cardiac Imaging. In addition, Advanced Imaging Research Inc. (located in Cleveland) presented their coils and support tools for scanning of neonates.

The Sunday morning session was followed by three parallel working group meetings on Neuro, Body/Ortho and Cardiac applications. Each of the three working groups discussed in detail the current clinical routine, future use and clinical and technical requirements to address future applications. The topics ranged from clinical questions, hardware and advanced sequences to new approaches in image post-processing.

The two days spent together at the Pediatric User Meeting resulted in a renewing of old contacts and in creating new contacts between users, in valuable feedback and fruitful input to the Siemens development groups. Siemens already offers on Tim (Total imaging matrix) systems a set of pediatric optimized, age dependent protocols (Pediatric Suite) and will use this input to further facilitate the work of clinicians and MR technologists doing pediatric examinations. We would like to thank all participants and clinical partners for their contributions, either in the presentations they gave or their input to discussions.

*The safety of imaging fetuses/infants has not been established.

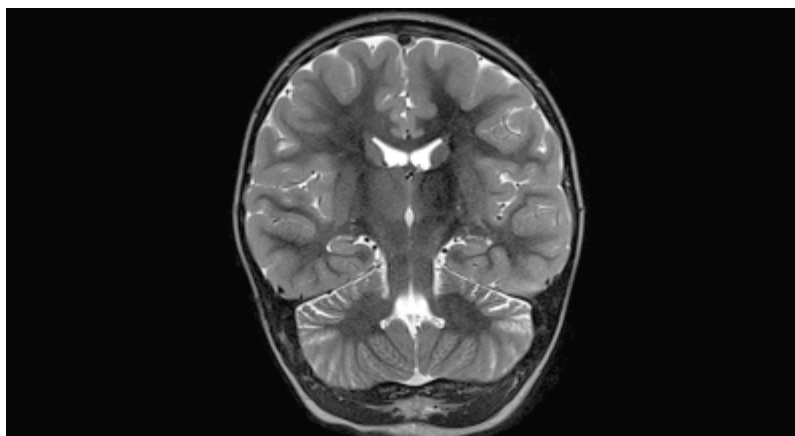


Participants at the 2nd pediatric user meeting.

Pediatric imaging

MR's safety due to lack of x-ray is one of the major factors making MR the examination of choice for pediatric patients. In recent years MR imaging with Tim (Total imaging matrix) has created major developments in this area: BLADE has

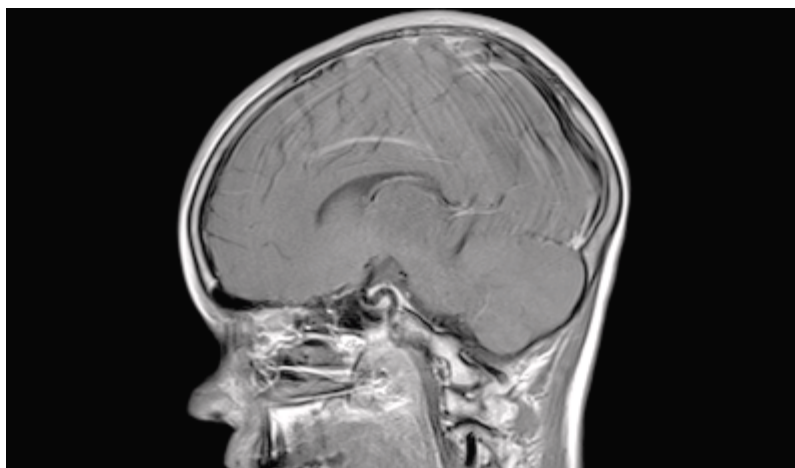
helped decrease motion artefacts, GRAPPA has dramatically improved imaging speed and sequences like TrueFISP fatsat have been extremely useful for state-of-the-art skeletal imaging.



[Figure 1] MAGNETOM Trio, A Tim System
T2 TSE coronal, GRAPPA 2, 5-year-old.

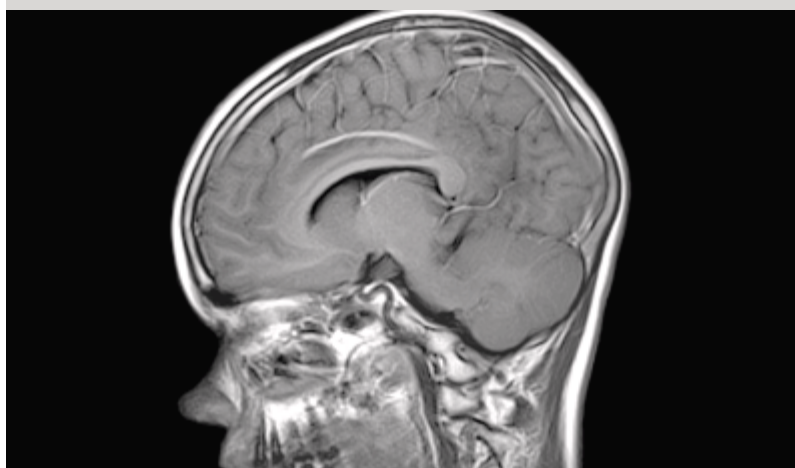
TR/TE	5780/103
TA	2:48 min
SL	3 mm
slices	27
FoV	200 mm
matrix	512

Courtesy of University
of North Carolina, Chapel Hill, USA



[Figure 2A] MAGNETOM Avanto
T1 SE sagittal, GRAPPA 2, **without motion correction**, 12-year-old.

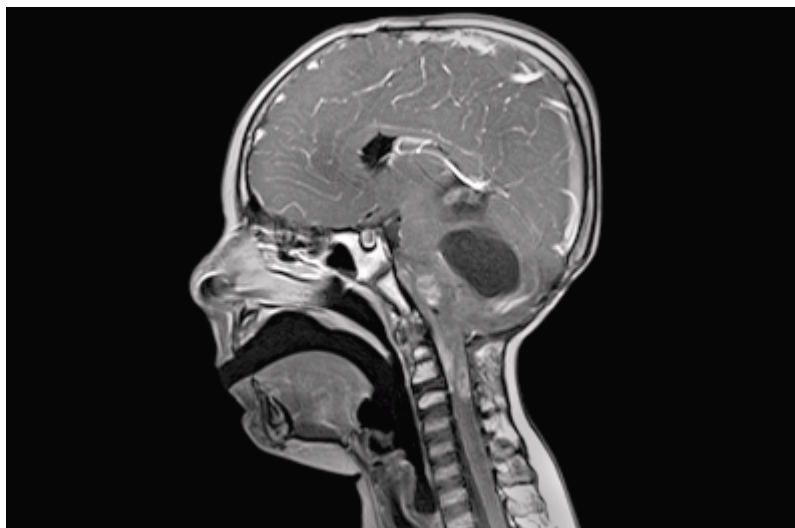
TR/TE	700/11
TA	2:31 min
SL	5 mm
slices	24
FoV	200 mm
matrix	256



[Figure 2B] MAGNETOM Avanto,
T1 TIRM sagittal, **with BLADE**, 12-year-old.

TR/TE	1970/55
TI	860
TA	5:06 min
SL	5 mm
slices	21
FoV	200 mm
matrix	256

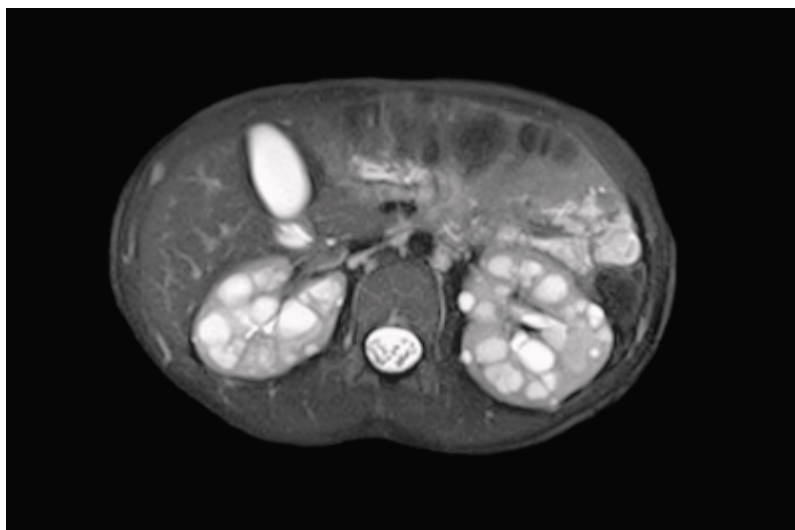
Courtesy of Children's Hospital, Denver, CO, USA



[Figure 3] MAGNETOM Symphony
T1 SE sagittal, post contrast, 4-year-old,
ependymoma

TR/TE	600/17
TA	3:30 min
SL	3 mm
slices	11
FoV	230 mm
matrix	256

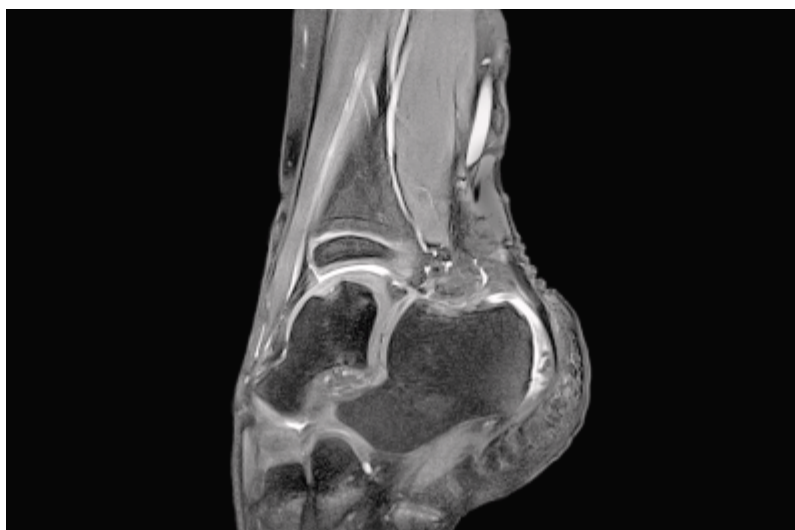Courtesy of UZ Gent MR 1, Gent, Belgium



[Figure 4] MAGNETOM Avanto
T2 HASTE transversal, GRAPPA 2, 9-year-old,
poly cystic kidneys

TR/TE	199950/102
TA	3:21 min
SL	5 mm
slices	38
FoV	260 mm
matrix	256

Courtesy of Children's Hospital, Denver, USA



[Figure 5] MAGNETOM Espree
T2 3D TrueFISP sagittal water excitation,
7-year-old, osteochondrosis dissecans

TR/TE	9.5/3.5
TA	4:17 min
eff. SL	1.5 mm
partitions	48
FoV	160 mm
matrix	384

Courtesy of Klinikum Bremen-Mitte, Bremen, Germany