

T1-weighted Phase Sensitive Inversion Recovery for Imaging Multiple Sclerosis Lesions in the Cervical Spinal Cord

Bart Schraa, MSc., Senior MR Application Specialist

Siemens LTD Canada

Introduction

Multiple sclerosis (MS) is an inflammatory disease in which the insulating covers of nerve cells in the brain and spinal cord are damaged. Magnetic resonance imaging (MRI) was first used to visualize multiple sclerosis (MS) in the upper cervical spine in late 1980 [1]. Spinal MS is often associated with concomitant brain lesions; however, as many as 20% of patients with spinal lesions do not have intracranial plaques [2]. This article describes the experiences with a T1-weighted phase sensitive inversion recovery sequence for the detection of MS lesions in the cervical spinal cord using the MAGNETOM Skyra with syngo MR D13A software.

Inversion Recovery Sequences used for imaging Multiple Sclerosis

Several inversion recovery techniques are used for imaging lesions in MS. Among these are Fluid Attenuated Inversion Recovery (FLAIR), Sampling Perfection with Application optimized Contrasts using different flip-angle Evolutions Double Inversion Recovery (SPACE-DIR), and T1-weighted Phase Sensitive Inversion Recovery (PSIR).

Fluid Attenuated Inversion Recovery

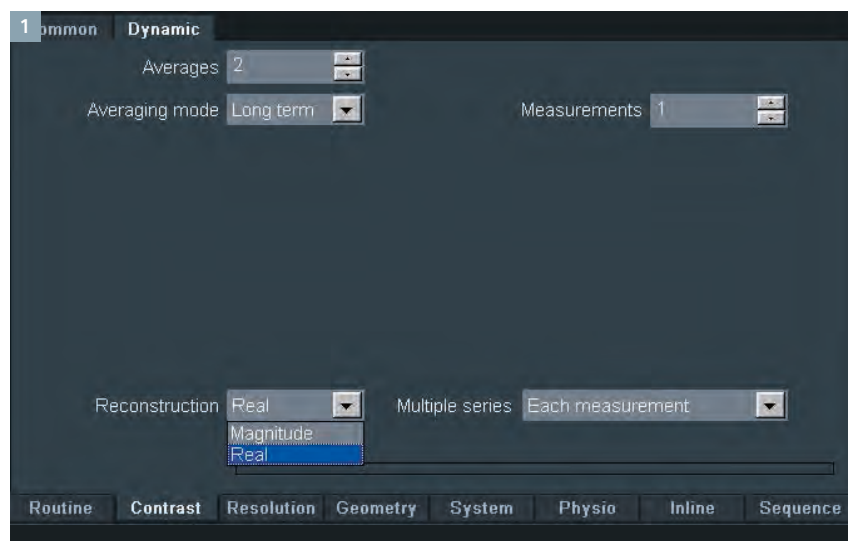
FLAIR is commonly used to assess white matter lesions and in particular

MS lesions in the brain. The FLAIR technique is a T2-weighted sequence with a long TR and TE and is used to demonstrate the changes in T2 relaxation times in lesions when compared to normal tissue. As the name indicates, the signal of cerebro-spinal fluid (CSF) is attenuated.

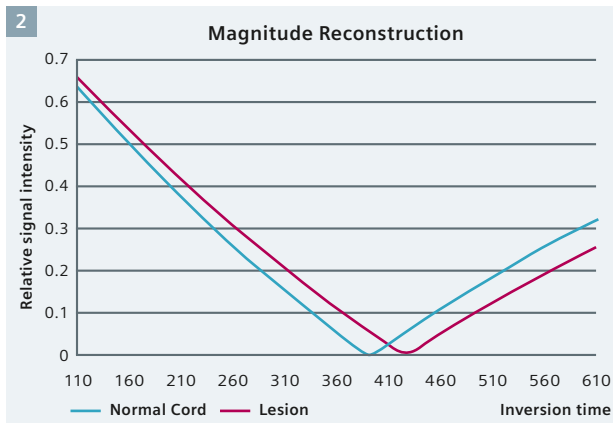
CSF has a long T1 relaxation times compared to the other tissues in both the brain and cervical spine. Therefore, a rather long inversion time is needed to null the signal of CSF (~ 2500 ms). Hence, the contrast in T2-weighted FLAIR images allows for easier assessment of (MS) lesions, especially when the lesions are close to CSF, as compared to normal T2-weighted images. However, while the FLAIR technique works well in the brain, it is hampered by flow and motion artifacts when used in the cervical spine.

Double Inversion recovery

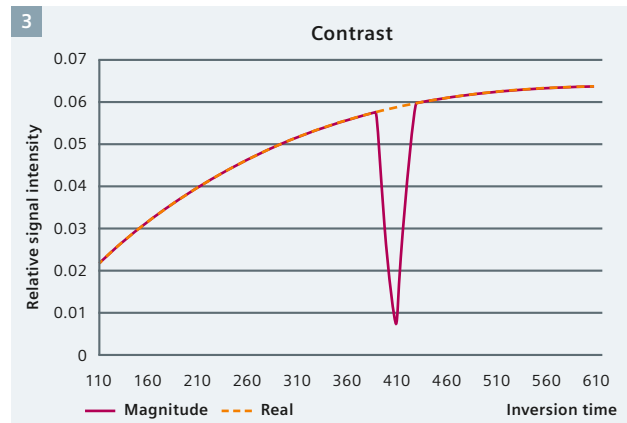
The Double Inversion Recovery technique has been implemented in the SPACE-DIR sequence in the Siemens syngo MR D13 software. A protocol optimized for brain imaging is also provided. SPACE-DIR is a T2-weighted technique which uses two inversion pulses, combined with a fat saturation pulse, to null both the signal of CSF and normal white matter. Similar to the FLAIR technique, this sequence is used to exploit the changes in T2 relaxation times in lesions when compared to normal tissue. In the brain, SPACE-DIR improves visualization of



1 Parameter Card for choosing magnitude or phase sensitive (real) reconstruction method in an Inversion Recovery sequence.



2 Signal behavior in an inversion recovery sequence using magnitude reconstruction.



3 Contrast behavior in an inversion recovery sequence using magnitude or phase sensitive (real) reconstruction.

the cortex and reveals cortical lesions as hyperintense relative to normal surrounding gray matter. It also provides a high contrast between white matter lesions and the surrounding normal white matter. Initial studies have investigated the applicability of DIR for lesion imaging in the spinal cord with positive results [3]. Nevertheless, while SPACE-DIR provides a high contrast and isotropic voxels, its rather long acquisition time (~8 min) may prove challenging within a clinical setting.

T1-weighted phase sensitive inversion recovery

A promising potential alternative for imaging MS lesions in the cervical spinal cord [4], is the T1-weighted true or phase sensitive inversion recovery (PSIR) sequence. This technique has been used to detect MS lesions both in white and cortical gray matter in the brain [5, 6]. This sequence exploits the differences in T1 relaxation times of tissues rather than the differences in T2 relaxation times as for both FLAIR and SPACE-DIR.

Since the inversion time used is chosen such that it nulls the signal of normal white matter (~350–400 ms @ 3T), normal white matter is displayed as intermediate gray. All other tissues will have either lower or higher signal intensity than normal white matter depending on their T1 relaxation time relative to normal white matter. This provides a high contrast between MS lesions and surrounding tissue. Moreover, because PSIR uses a short TE, it is less sensitive to flow artifacts. High resolution imaging can also be achieved within reasonable scan times.

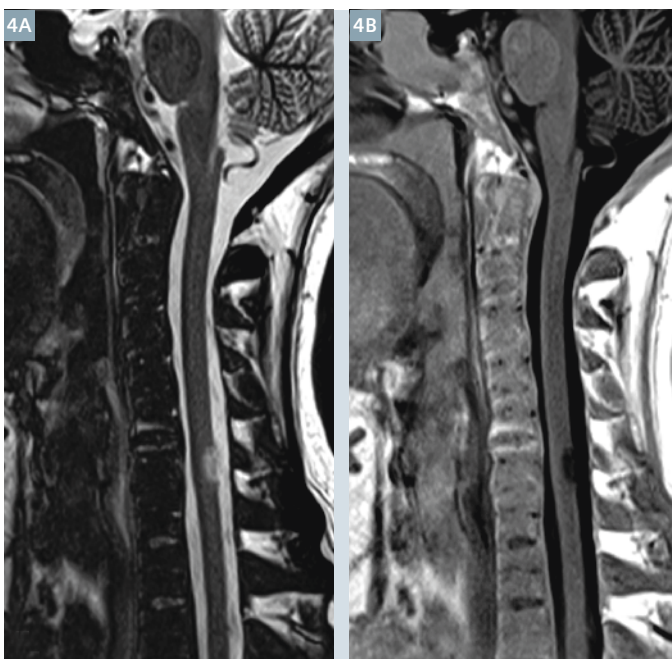
Based on these advantages, T1-weighted PSIR is now being explored for the detection of MS lesions in the cervical spinal cord.

Reconstruction methods

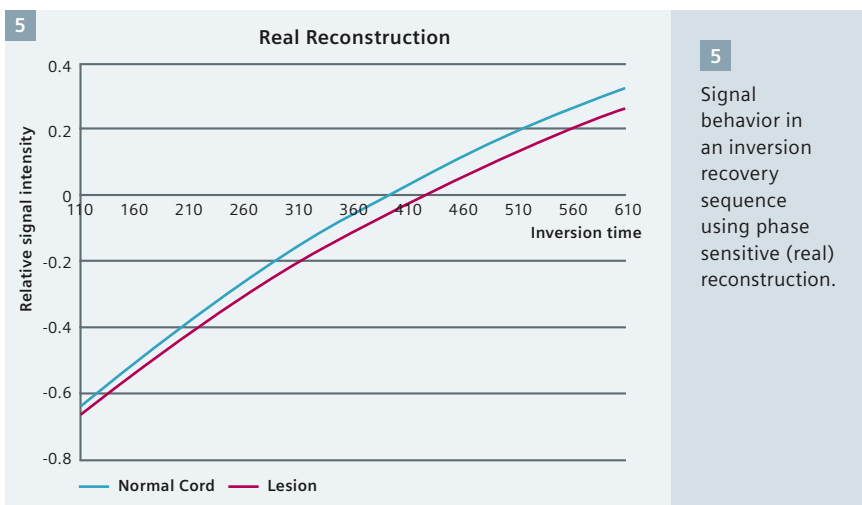
The T1-weighted PSIR images can be reconstructed as a magnitude or a phase sensitive (real) image (Fig. 1).

Magnitude reconstruction

The magnitude reconstruction does not consider the sign of the signal. Therefore, the tissue which is nulled by the inversion time will have a signal intensity of zero and all other tissues will have higher signal intensity (ranging from 0 to +4096), regardless of whether they have shorter or longer T1 relaxation time than the nulled tissue (Fig. 2). However, there is a range of inversion times where the contrast between two different

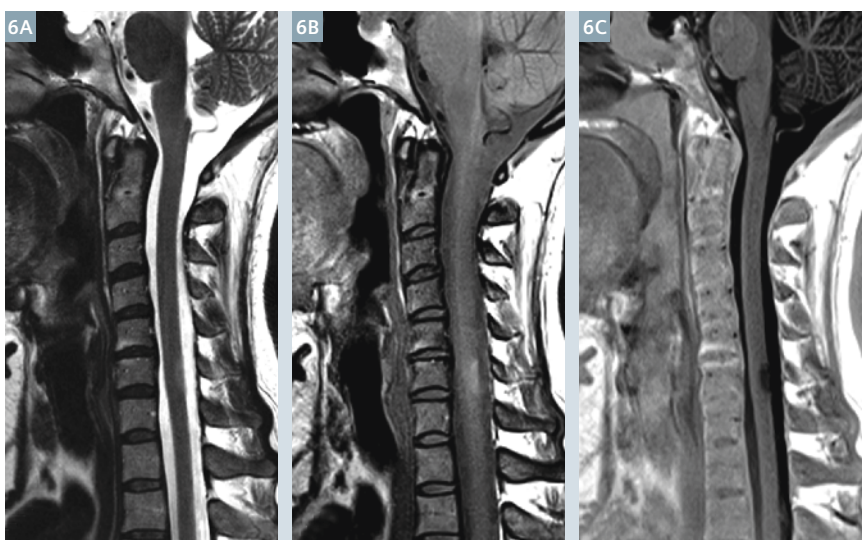


4 T1-weighted PSIR images using (4A) magnitude and (4B) phase sensitive (real) reconstructions.

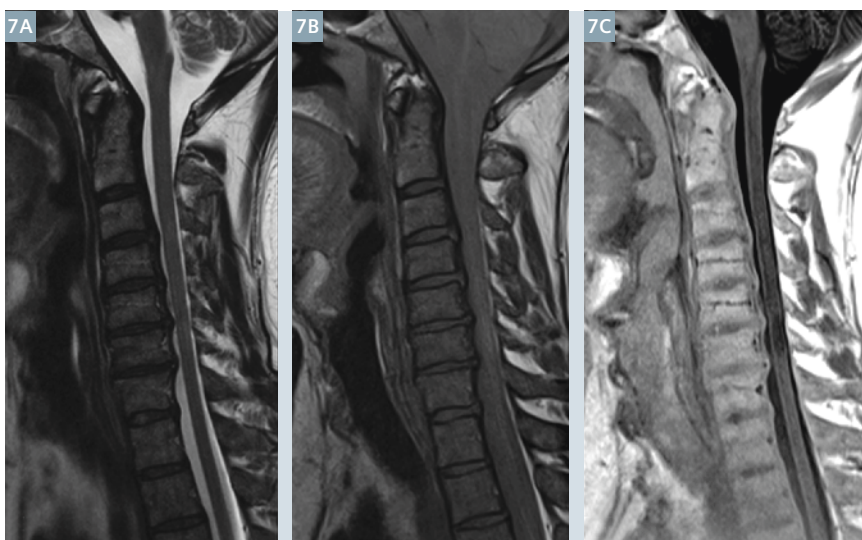


tissues, e.g., lesion and normal tissue, can be decreased or even disappear. This range depends on T1 relaxation times of the two tissues and range between the two inversion times that would null one or the other tissue. In the example shown in figure 3, it ranges from approximately 390 to 430 ms. An example of the magnitude image is shown in figure 4A.

Phase sensitive reconstruction
 In the phase sensitive reconstruction, the sign of the signal is taken in account for the reconstruction of the image (Fig. 5). As opposed to the magnitude reconstruction where the signal intensity in the image ranges from 0 to +4096, for the phase sensitive reconstruction it ranges from -4096 to +4096. This results in an image where the tissue which is nulled by the inversion time will be displayed as intermediate gray and all other tissues will have a lower or higher signal intensity depending on their T1 relaxation times relative to the T1 relaxation time of the nulled tissue. Tissues with a shorter T1 relaxation time will have a higher signal (e.g. fat), whereas tissues with a longer T1 relaxation time will have lower signal (e.g. CSF). Unlike the magnitude reconstruction, the contrast between tissues remains largely preserved independent of the chosen inversion time. Since the T1 relaxation time of lesions might vary from patient to patient and even from lesion to lesion, the phase sensitive reconstruction should be used to reconstruct the images. An example of the phase sensitive reconstruction is shown in figure 4B.



6 T2- (**6A**), PD- (**6B**) and T1-weighted (**6C**) PSIR images of a patient with a known MS lesion at the level of C6 (Case 1).

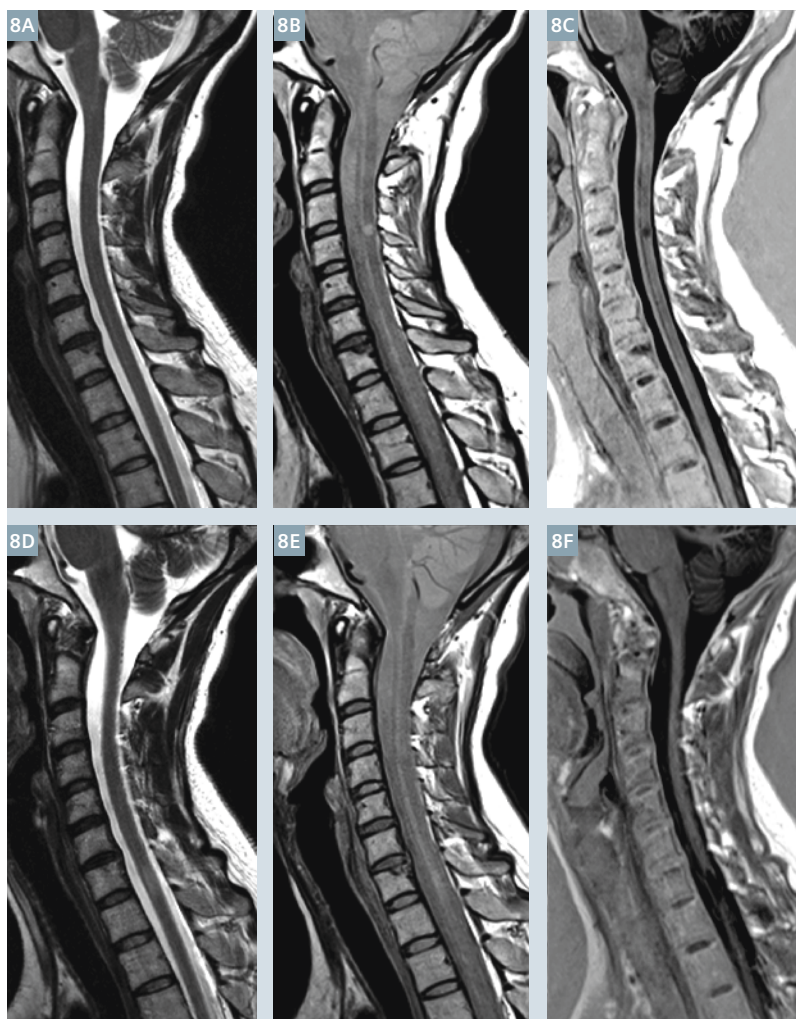


7 T2- (**7A**), PD- (**7B**) and T1-weighted PSIR (**7C**) images of a patient with known diffuse MS lesions at the level of C3–C6 (Case 2).

Clinical Cases

Case 1
 Patient with a MS lesion at the level of C6 (Fig. 6). The lesion is difficult to see on the T2- and PD-weighted images. However, the MS lesion can be clearly seen in the T1-weighted PSIR image.

Case 2
 Patient with diffuse MS lesions in the spinal cord from level C3 to C6 (Fig. 7). The lesions are hardly visible on the T2- and PD-weighted images, whereas the T1-weighted PSIR shows the lesions more clearly.



8 T2- (8A, D), PD- (8B, E) and T1-weighted PSIR (8C, F) images of a patient with known MS lesions at the level of C3–C4 (top row) and C7–T1 (bottom row) (Case 3).

Table 1: Imaging parameters for the sequences used in the clinical cases.

	t2_tse_sag_384	pd_tse_sag_p2	t1_tir_sag_ms
TR	3500.0 ms	2500.0 ms	2400.0 ms
TE	106.0 ms	23 ms	9.4 ms
TI			400 ms
Slices	15	15	15
Slice thickness	3.0 mm	3.0 mm	3.0 mm
FOV Read	220 mm	220 mm	220 mm
FOV Phase	100.0%	100.0%	100.0%
Magn. preparation	None	None	Slice-sel. IR
Base resolution	384	320	320

Case 3

Patient with a known MS lesion at the level of C3–C4 (Figs. 8 A–C) and C7–T1 (Figs. 8 D–F). The lesion at the level of C3–C4 can hardly be seen on the T2-weighted image. Both the PD- and the T1-weighted PSIR show this lesion clearly. While the lesion at the level of C7–T1 is poorly visible on the T2- and PD-weighted images, the T1-weighted PSIR shows it very clearly.

Imaging Parameters

The parameters for the sequences used in the clinical cases are listed in table 1.

Conclusion

The T1-weighted PSIR shows great potential in revealing MS lesions in the cervical spinal cord. While using this technique it is important to use the phase sensitive reconstruction to preserve the contrast between MS lesions and normal appearing tissue. Due of the nature of the reconstruction, and because T1 values of lesions can vary from patient to patient, for reliable depiction of lesions, the phase sensitive reconstruction is recommended. This is as, unlike the magnitude reconstruction, the phase sensitive reconstruction provides a contrast between different tissues that is largely independent of the chosen inversion time.

Acknowledgements

We acknowledge the invaluable support of Dr. Montanera, Dr. Alcaide Leon and Mrs. Karima Murji of St. Michael's Hospital (Toronto, Canada) for providing the clinical cases and their feedback.

References

- 1 Honig LS, Sheremata WA. Magnetic resonance imaging of spinal cord lesions in multiple sclerosis. J Neurol Neurosurg Psychiatry. Apr 1989;52(4):459-466.
- 2 Noseworthy JH, Lucchinetti C, Rodriguez M, et al. Multiple sclerosis. N Engl J Med. Sep 28 2000;343(13):938-452.
- 3 Shipp D. Case Report: Cervical Spine 3D Double Inversion Recovery (DIR) in Demyelination. MAGNETOM FLASH magazine 1/2012 ISMRM Edition: 49-50
- 4 Poonawalla AH, Hou P, Nelson FA, Wolinsky JS, Narayana PA. Cervical Spinal Cord Lesions in Multiple Sclerosis: T1-weighted Inversion-Recovery MR Imaging with Phase-Sensitive Reconstruction. Radiology. 2008 Jan; 246(1): 258-264.
- 5 Hou P, Hasan KM, Sitton CW, Wolinsky JS, Narayana PA. Phase-sensitive T1 inversion recovery imaging: a time-efficient interleaved technique for improved tissue contrast in neuroimaging. AJNR Am J Neuroradiol 2005;26:1432-1438.
- 6 Nelson F, Poonawalla AH, Hou P, Huang F, Wolinsky JS, Narayana P. Improved visualization of intracortical lesions in multiple sclerosis by phase-sensitive inversion recovery in combination with fast double inversion recovery MR imaging. Presented at the 22nd Congress of the European Committee for the Treatment and Research in Multiple Sclerosis, Madrid, September 27-30, 2006; 639.

Download

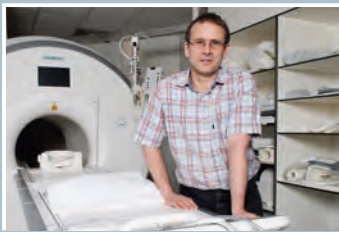Visit us at www.siemens.com/MAGNETOM-world to download the .edx file for 3T MAGNETOM Skyra

Contact

Bart Schraa, MSc.
Siemens Canada Ltd.
NAM RC-CA H CX-CS APP
1577 North Service
Road East
L6H 0H6 Oakville ON
Canada
Phone: +1 (416) 818 6795
bart.schraa@siemens.com

Expert Talks

Don't miss the talks of experienced and renowned experts covering a broad range of MR imaging



Highest quality imaging in an optimized clinical workflow

Johan Dehem, M.D.
VZW Jan Yperman, Ieper, Belgium



MR/PET and radiology as information business

Dieter Enzman, M.D.
University of California Los Angeles, Los Angeles, CA, USA

Visit us at www.siemens.com/magnetom-world

Go to [Clinical Corner > Clinical Talks](#)