

MAGNETOM Aera – Combining Throughput and Highest Quality Spine Imaging in an Optimized Clinical Workflow

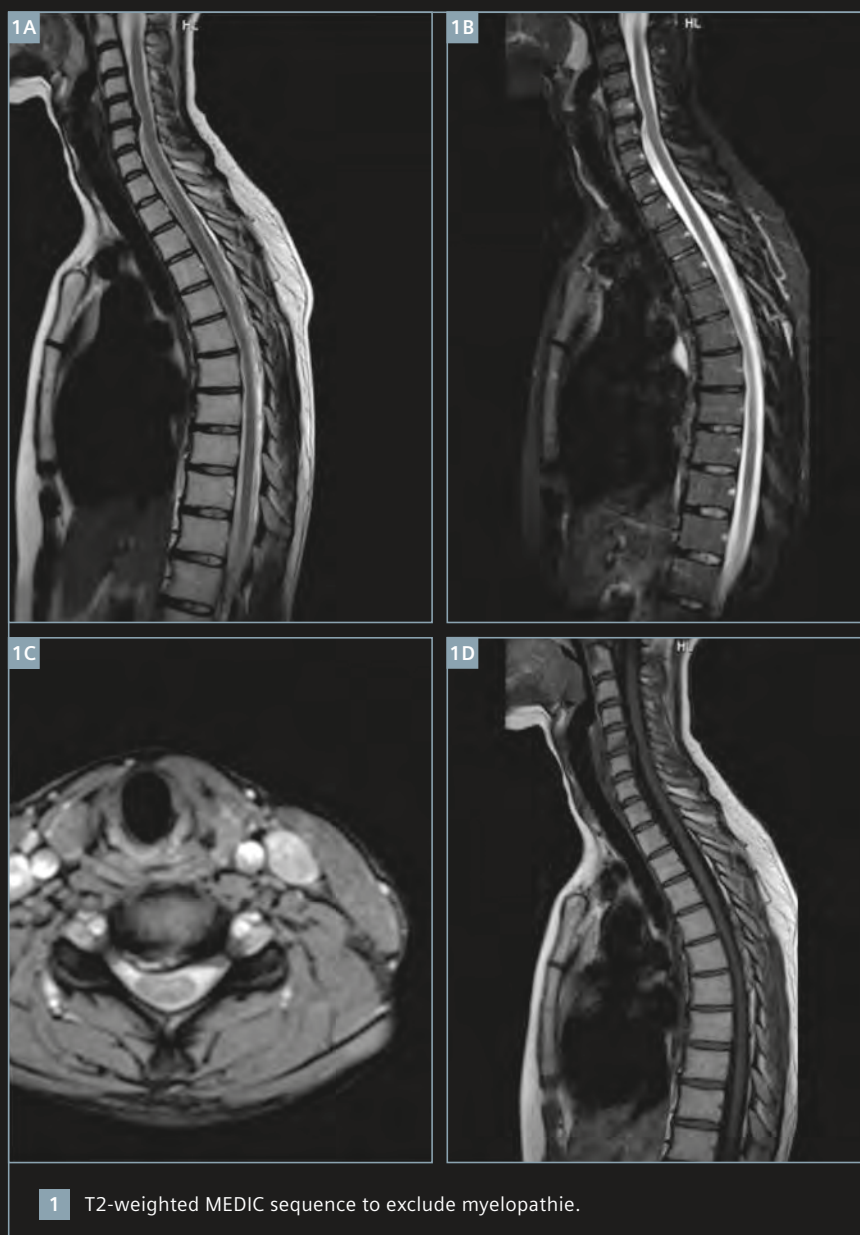
Johan Dehem, M.D.

VZW Jan Yperman, Ieper, Belgium

Cervical spine imaging

Thanks to Tim's flexibility with coil combinations, MR imaging of the cervical spine is in 99% percent of the cases a swift and easy standard program evaluating degenerative disease.

Figure 1 shows a case of herniated disk where you can clearly exclude myelopathy since the T2-weighted MEDIC sequence demonstrates the 'butterfly' of normal gray matter in the myelon.



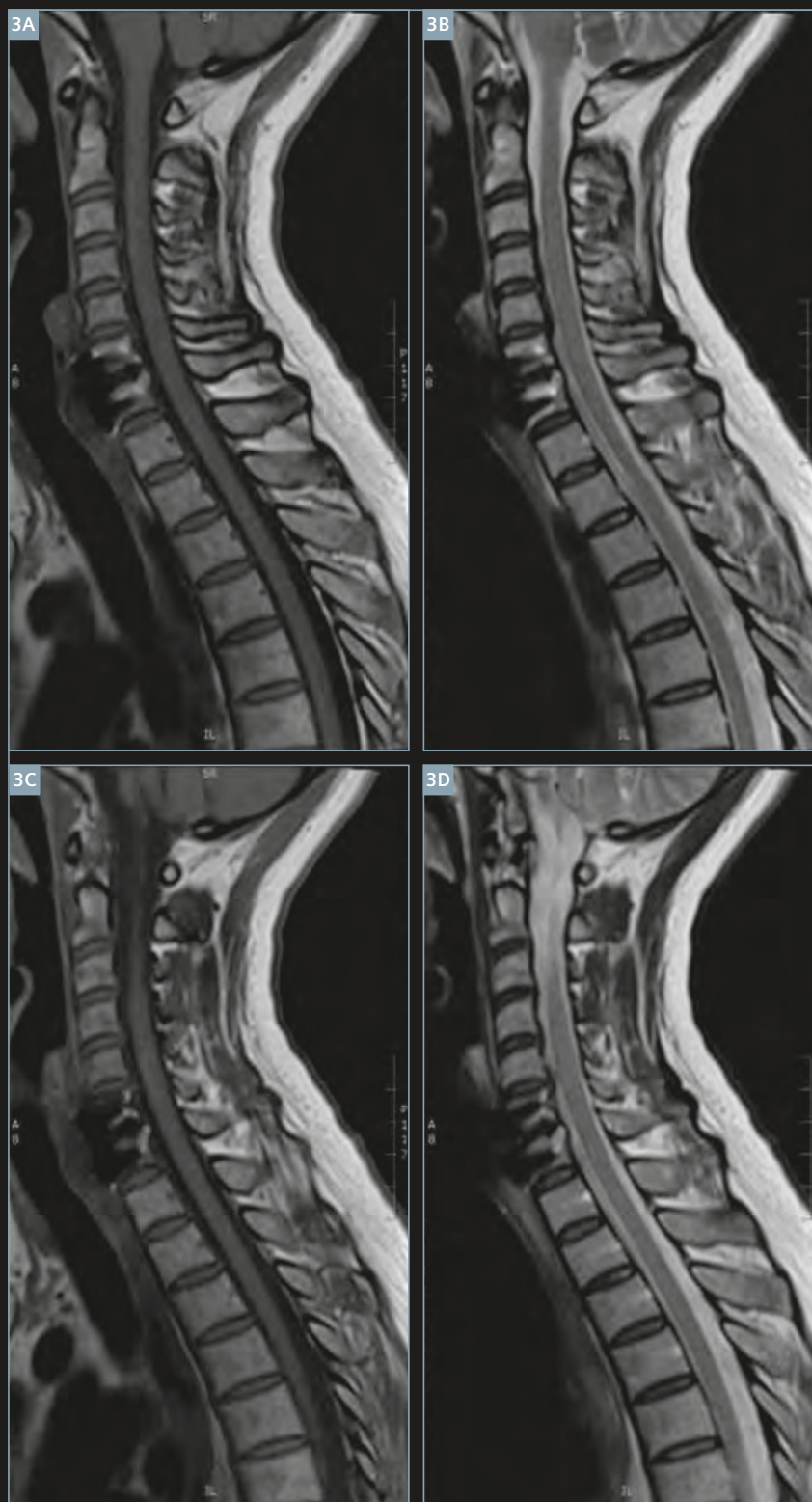2		
1	AASpine_Scout	
2	t1_tse_sag	01:13
3	t2_tse_fs-dixon_sag	02:16
4	t2_me2d_tra_p2	02:34
5	AutoAlign Verification	
6	t2_space_trans_p2	02:37
		Σ 08:40
2	AutoAlign in the Spine Dot Engine.	

Despite the high resolution (2.1 mm slice thickness for the sagittal T2w Dixon TSE) scanning times for the c-spine are very patient friendly. Moreover the Spine Dot Engine (Fig. 2) helps to align and plan the slices speeding up the scanning by avoiding planning gaps during scanning. We are thus able to schedule patients every 10 minutes.

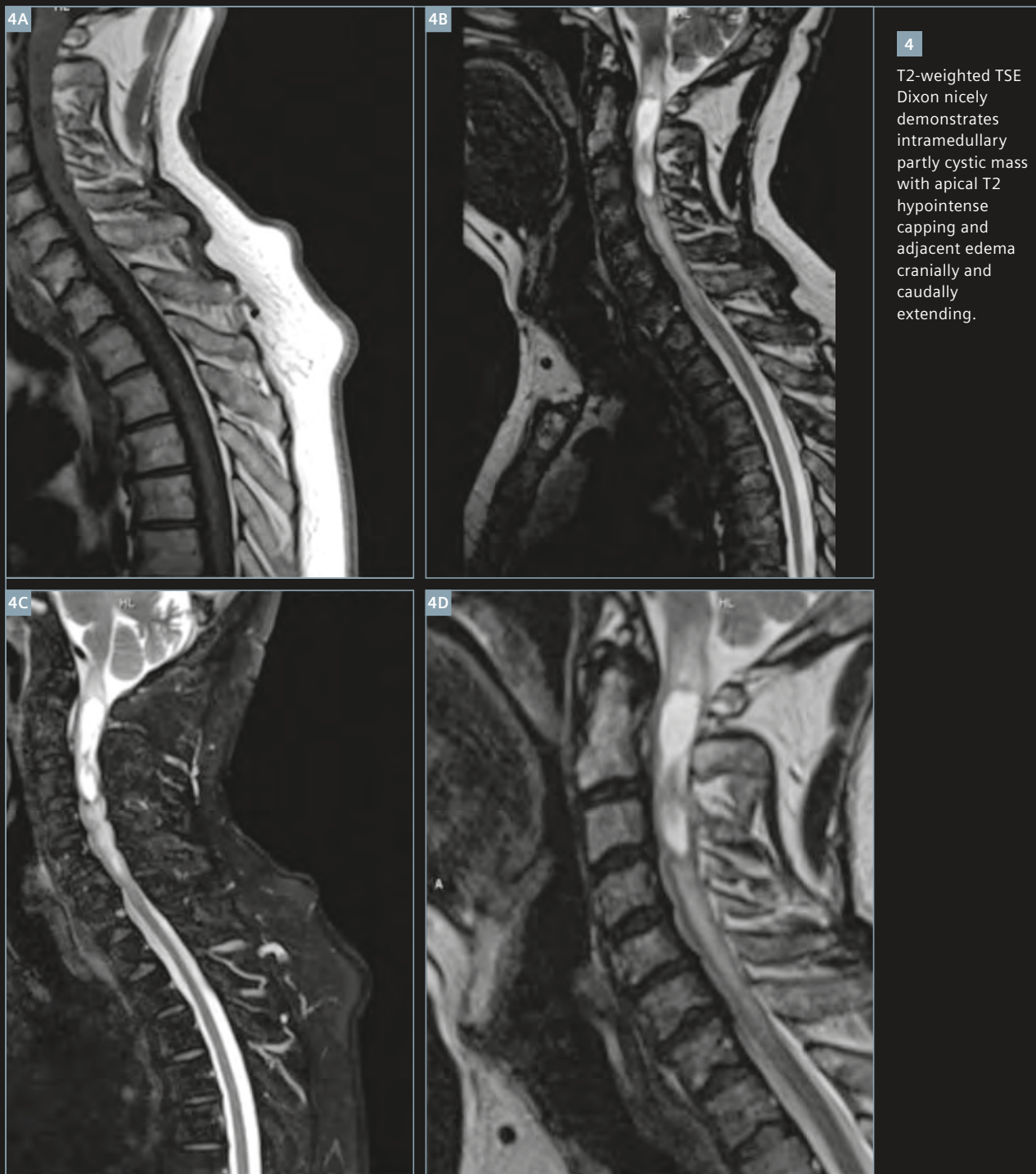The cervical spine can sometimes be quite challenging, be it technically or diagnostically.

In this case metal* susceptibility artifacts are reduced using WARP imaging (Fig. 3). The Spine Dot Engine has a convenient option to change the scanning protocol on the fly from normal to 'metal suppression' WARP mode by a simple mouse click, thereby eliminating the need to obtain sequences from another program or to change all of your parameters in the sequence card for each and every sequence. Metal artifact reduction is only a mouse click away.

*The MRI restrictions (if any) of the metal implant must be considered prior to patient undergoing MRI exam. MR imaging of patients with metallic implants brings specific risks. However, certain implants are approved by the governing regulatory bodies to be MR conditionally safe. For such implants, the previously mentioned warning may not be applicable. Please contact the implant manufacturer for the specific conditional information. The conditions for MR safety are the responsibility of the implant manufacturer, not of Siemens.

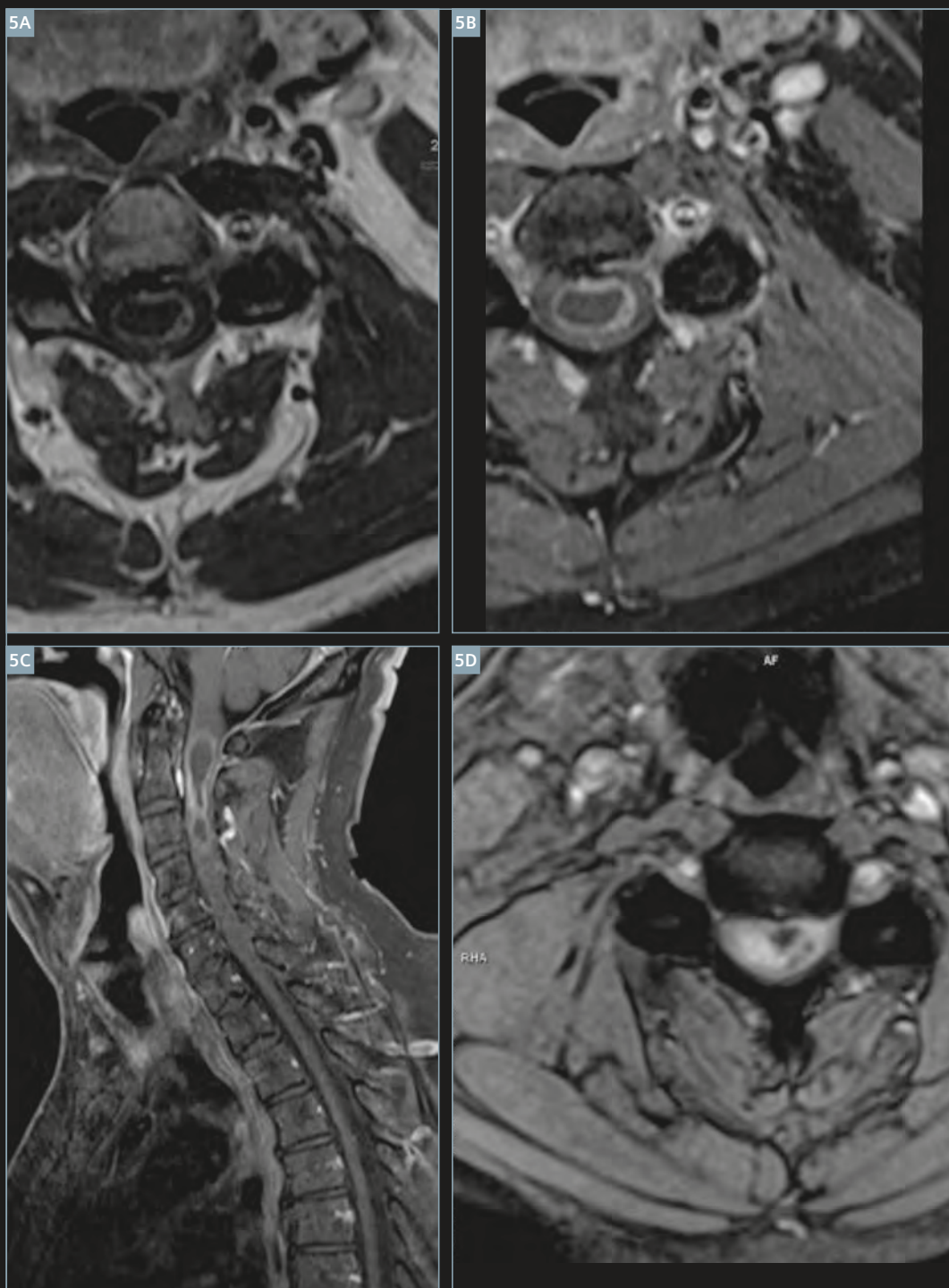


3 WARP imaging to reduce metal susceptibility artifacts.



This 65-year-old man suffers from numbness in both hands and loss of force in the upper limb bilaterally. An MRI c-spine was ordered to exclude myelopathy. On T1 the lesion is slightly hypointense. T2w TSE

Dixon nicely demonstrates intramedullary partly cystic mass with apical T2 hypointense capping and adjacent edema cranially and caudally extending (Fig. 4).



5

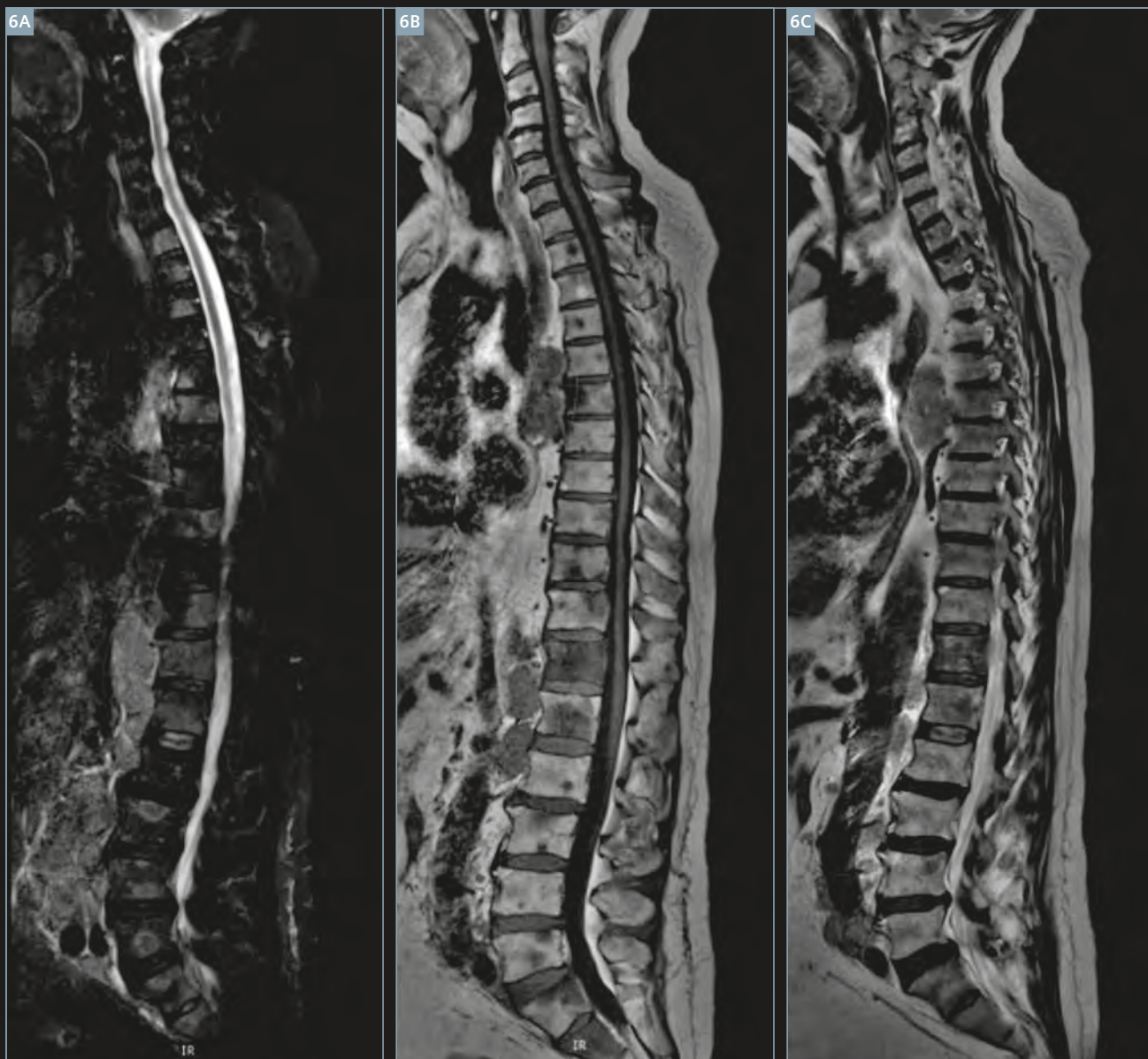
T1w (5A), axial
T1w FS Dixon
technique (5B),
sagittal Dixon fat
sat (5C) and T2w
MEDIC (5D).

Axial T1w and T1w FS Dixon technique and sagittal Dixon fat sat (impeccable as always) nicely demonstrate the peripheral contrast enhancement and central necrosis. The T2w MEDIC demonstrates inlaying hemosiderine, giving away the diagnosis of ependymoma.

Spine Dot Engine

Since the Spine Dot Engine starts with a 3D localizer on C2 level – be it for lumbar, dorsal or cervical spine – a full-spine scan is no big deal. We start the Spine Dot Engine on the lumbar region and simply add the T2,

T2 STIR and T1 TSE once for the cervico-dorsal spine. Inline composing or adjusted composing in *syngo.via* gives you highest quality full-spine images with good detail of e.g. adjacent lymph nodes in mediastinum or retro peritoneum.

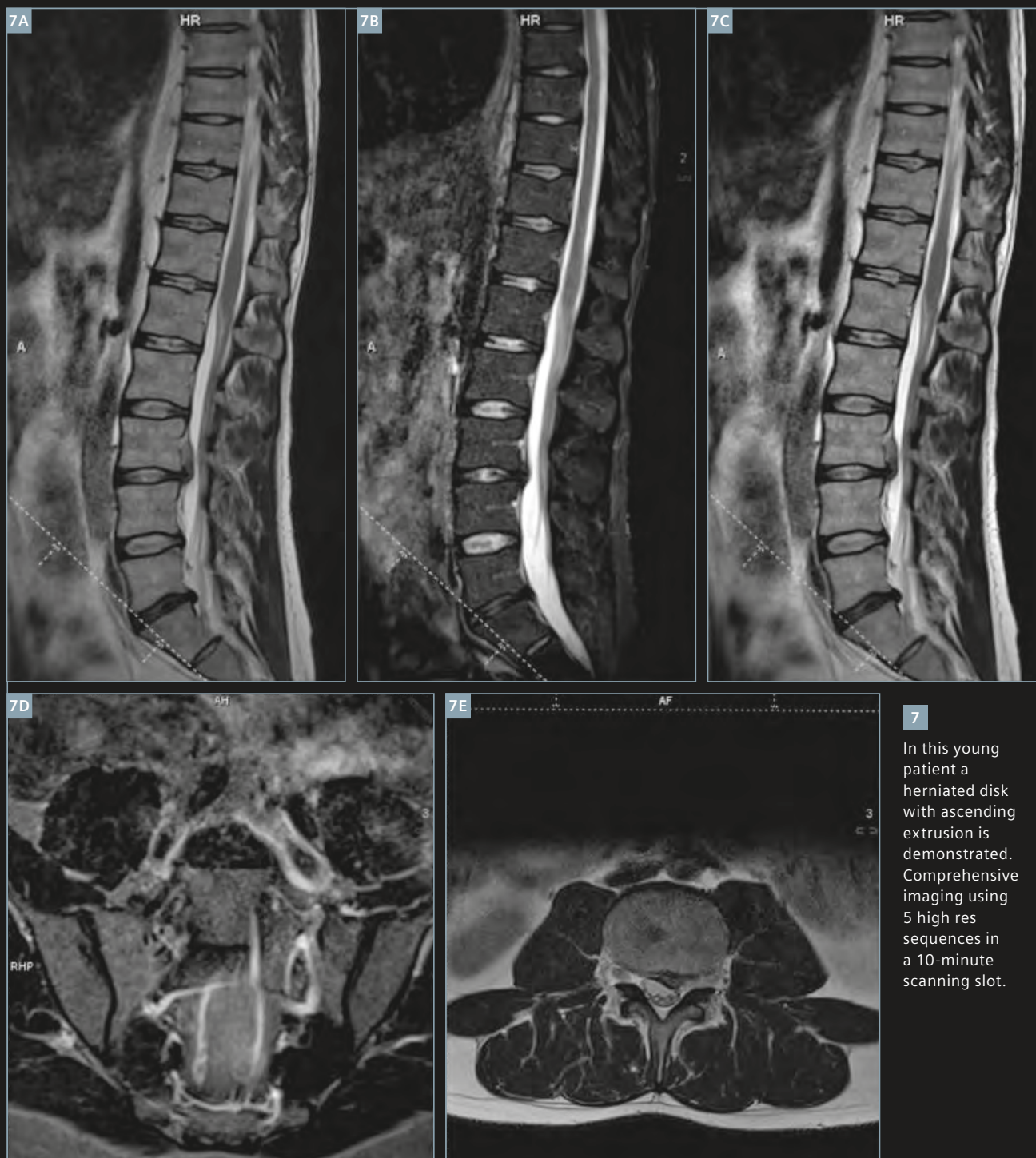

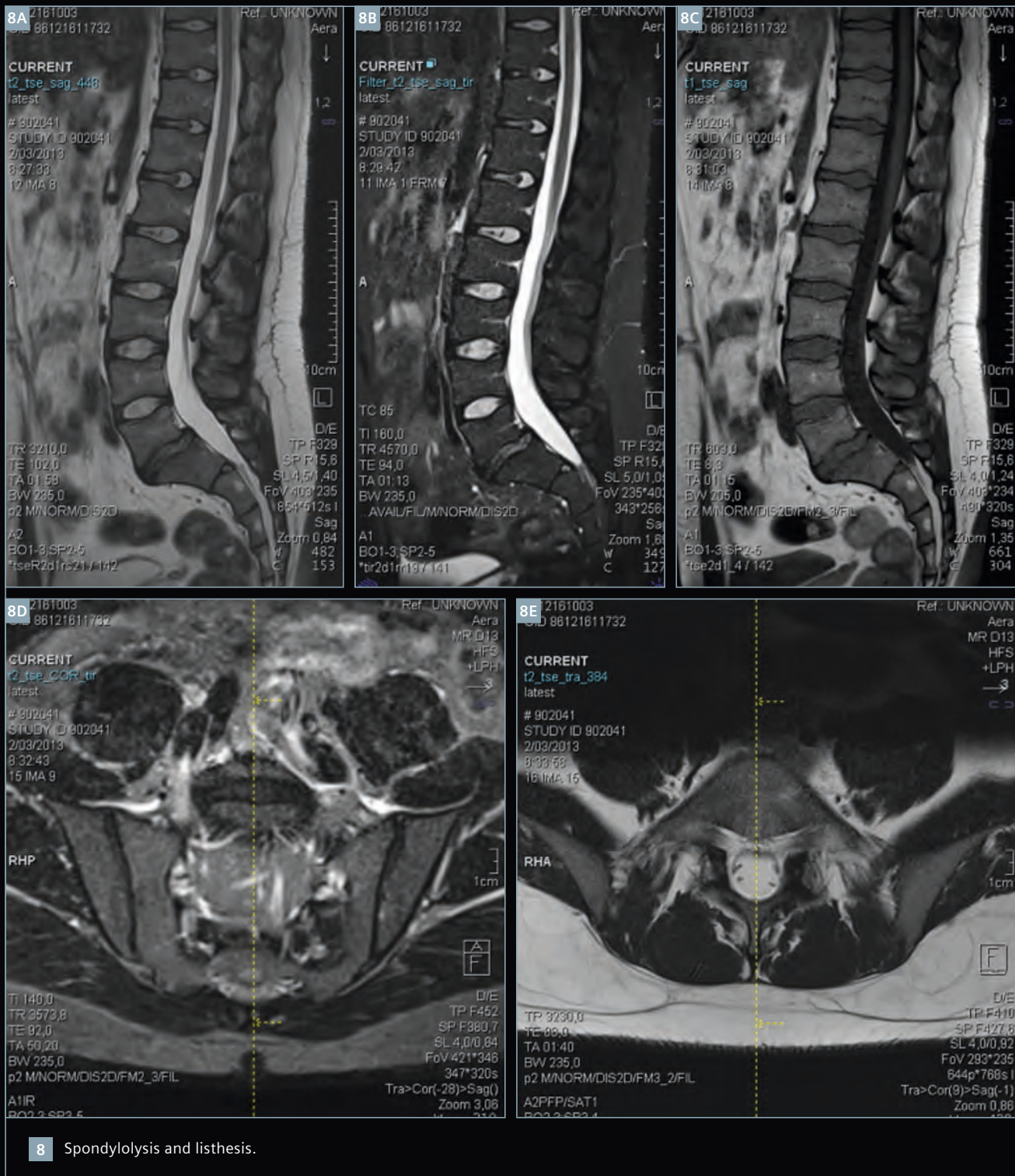
6 Example of prevertebral detail: Full spine examination clearly depicts bone metastasis in this prostate cancer patient but at the same time reveals retroperitoneal and mediastinal lymphadenopathies.

Lumbar spine imaging

Lumbar spine examination is part of the daily routine of radiology, so maintaining high image quality is paramount. Since most patients complain of pain, imaging time should also be as short as possible

to make optimal use of the window of opportunity that you have to scan the patient. In our institution we need 10 minutes to install the patient, and scan 3 sagittal views, one coronal and one axial series.

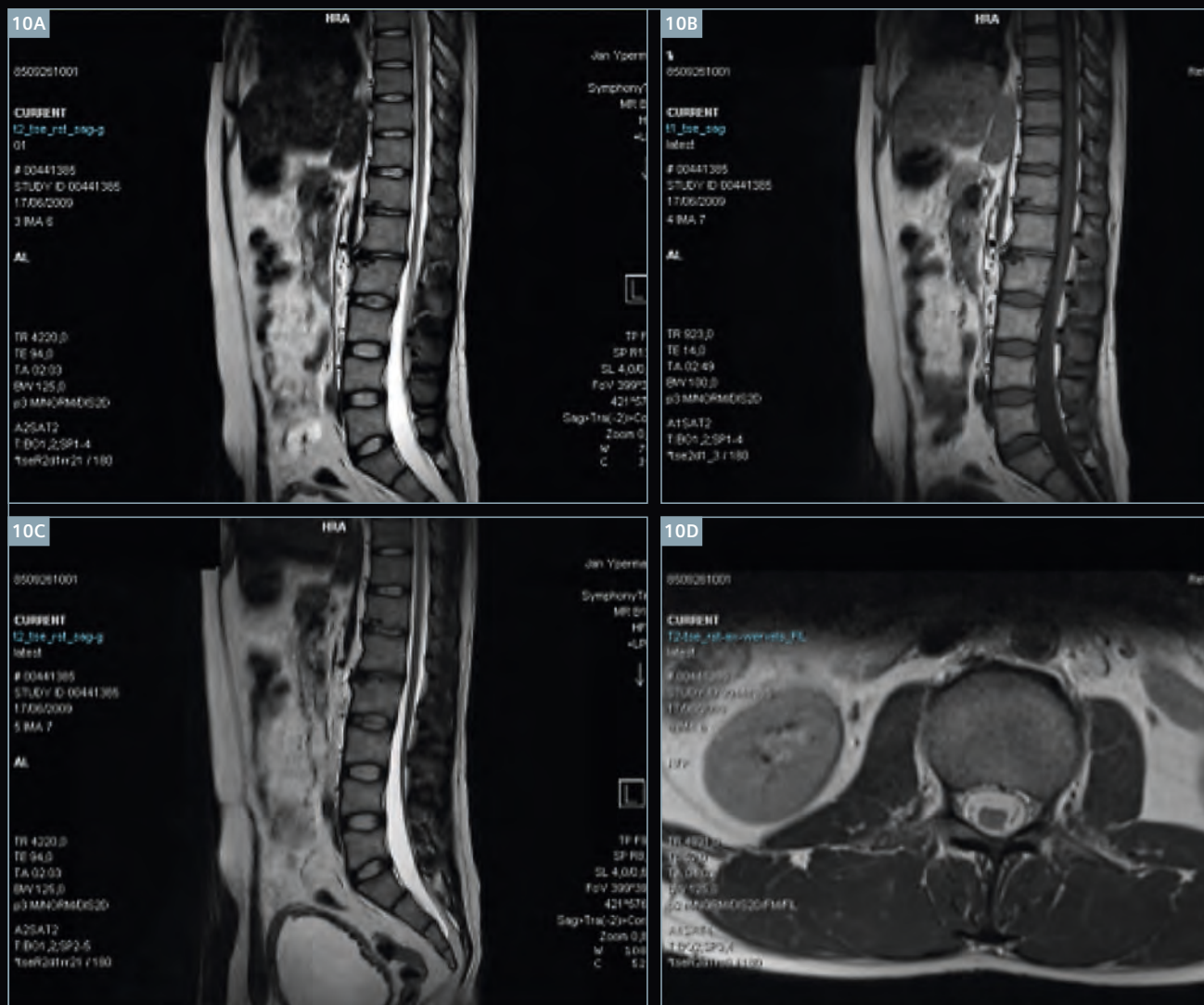




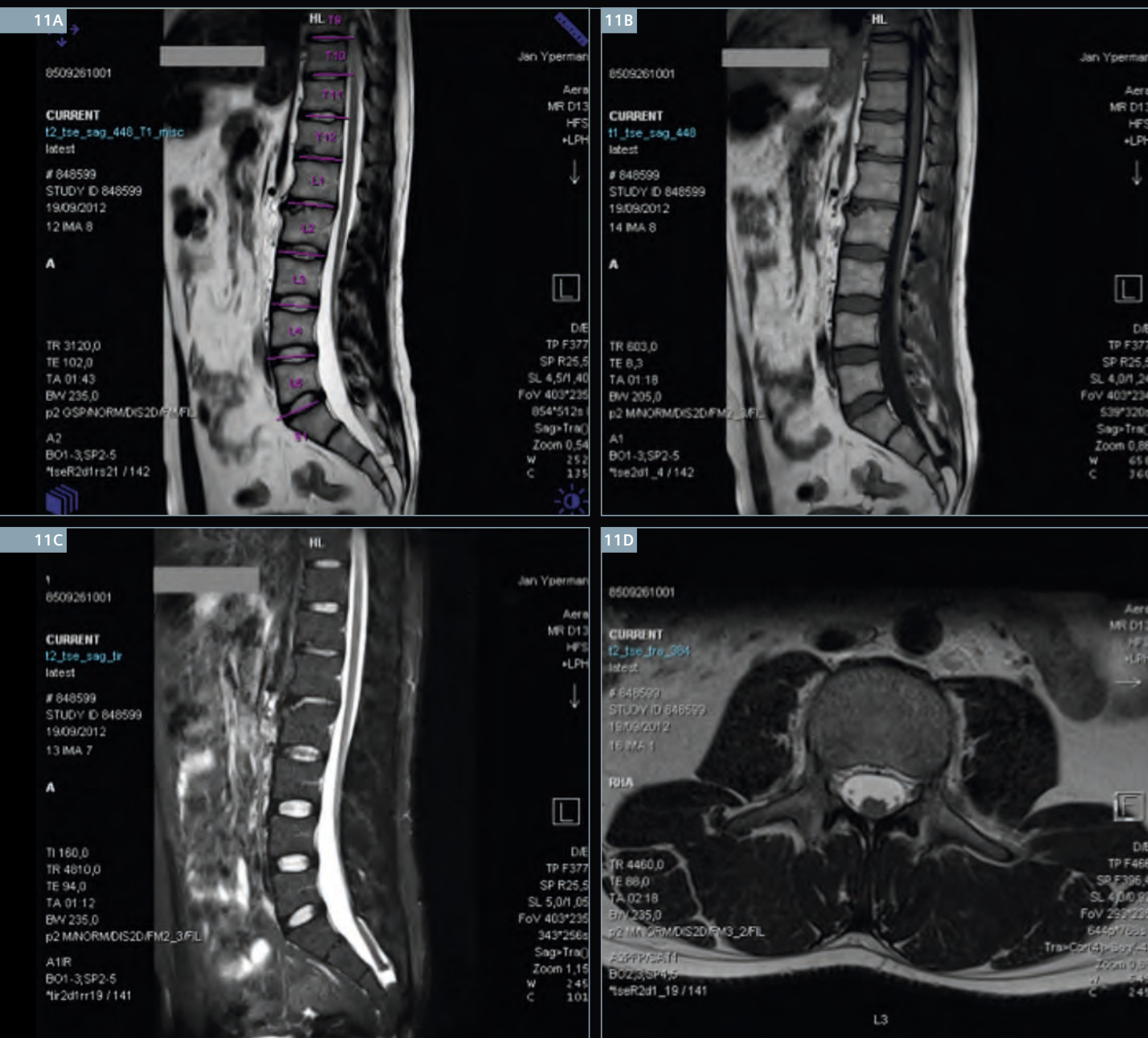
9		
1	I_AASpine_Scout	
2	II_AASpine_Scout	00:24
3	t2_tse_sag_448	02:07
4	t2_tse_sag_tir	01:24
5	t1_tse_sag	01:18
6	t2_tse_tra_384	01:48
7	t2_tse_COR_tir	00:49
8	AutoAlign Verification	
		Σ 10:08

9
Scan time
slightly over
10 minutes.

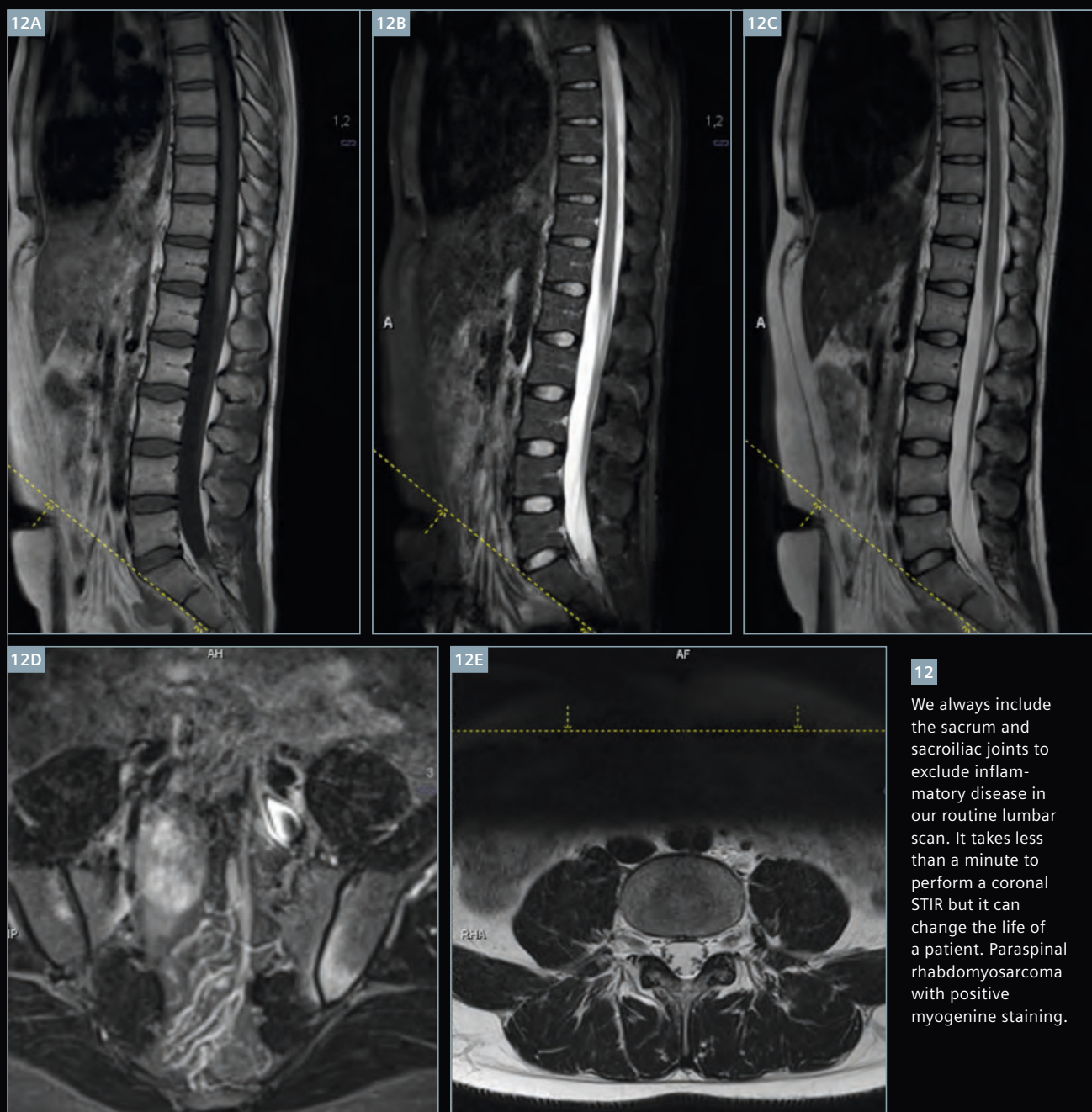
High quality and high speed do go together indeed! When you compare a contemporary lumbar spine on MAGNETOM Aera (Fig. 11) with the spine examination we used to do on the MAGNETOM Symphony a Tim System (Fig. 10) you do see an improvement in scanning times (up to 50% faster) for better image quality. Figures 10 (SATS) and 11 (Aera) show a case of a patient with a tethered cord where the image quality improvement is visible at 30% faster examination time.



10 A patient with a tethered cord. Note the neurogenic bladder and the small lipomeningocele. Images have been acquired using a MAGNETOM Symphony, a Tim system. The imaging time was well over 2 minutes for each acquisition.

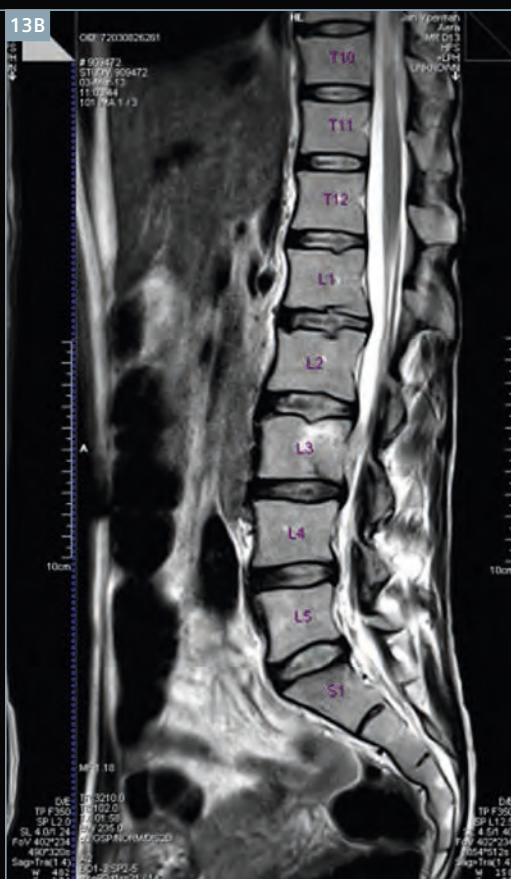
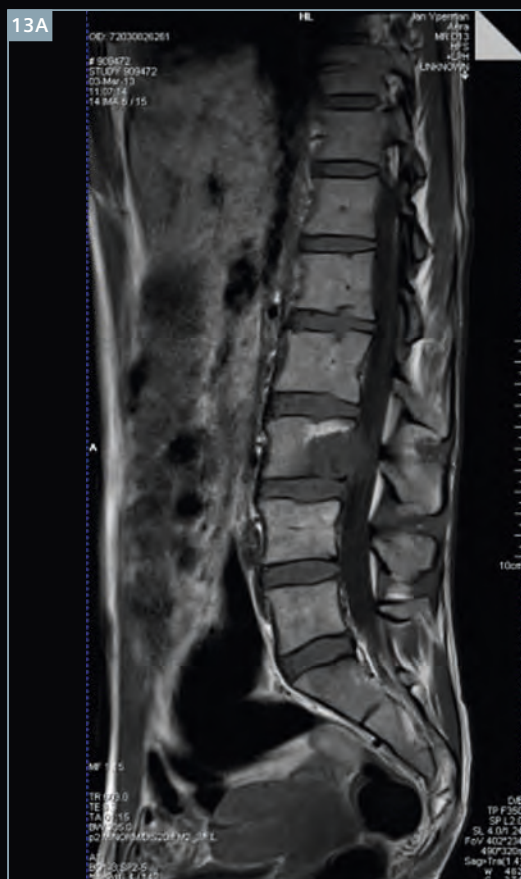


11 Same patient as in figure 10 on the MAGNETOM Aera system. Sharpness and homogeneity of the images has improved while acquisition times have dropped up to 50% (just take a look at the sag T1). Note tethered cord, neurogenic bladder and the small lipomeningocele.

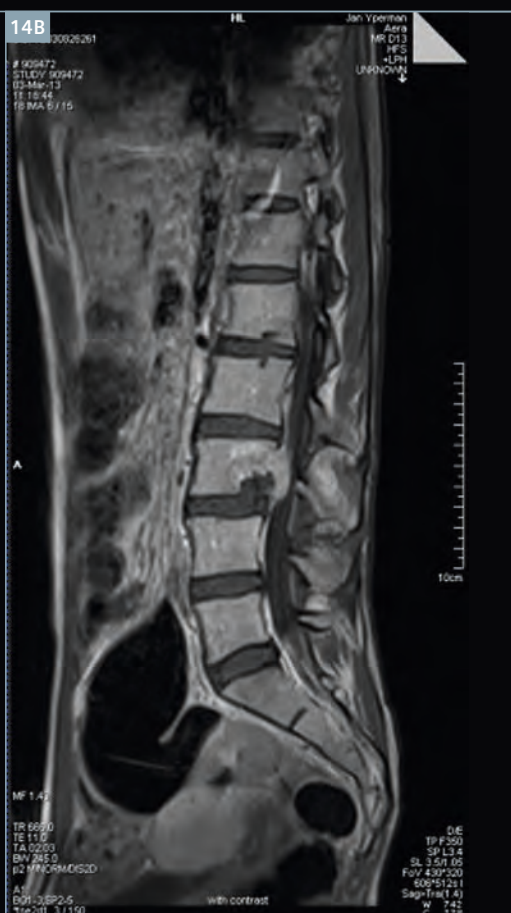
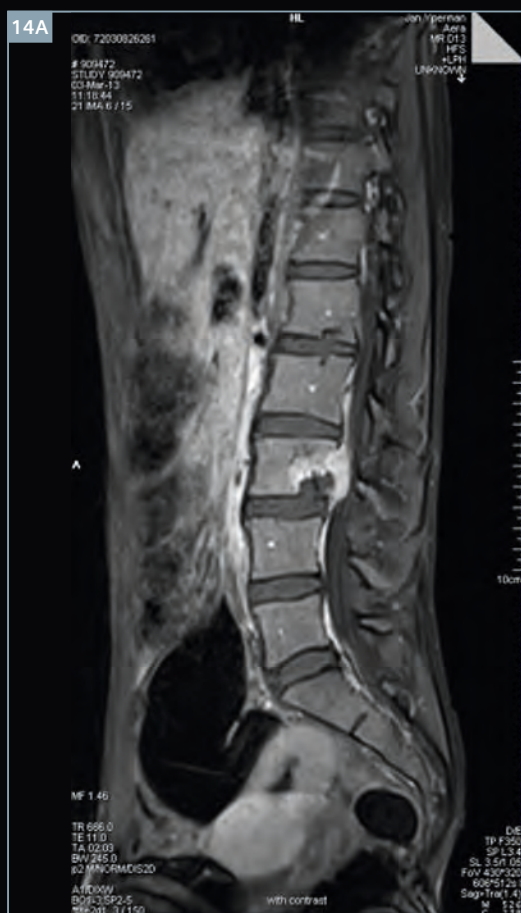
Sometimes, however, a simple lumbar spine scan turns out to be not so simple at all and we require additional imaging such as in the case of this 40-year-old lady in agony for the previous 8 days (Fig. 13–16). It turned out to be nerve root and thecal sac compression by a neoplastic lesion in the L3 vertebra. Additional sequences after gadolinium were performed. Dixon axial and sagittal T1w and T1w FS

images nicely demonstrate the tumor. The additional 3D VIBE CP (with breath-hold 21 s) gives a nice 3D overview. The axial diffusion-weighted imaging is in favor of malignant disease with a low ADC value. Again speed is important while imaging a patient in pain. It turned out to be a paraspinal rhabdomyosarcoma with positive myogenine staining.

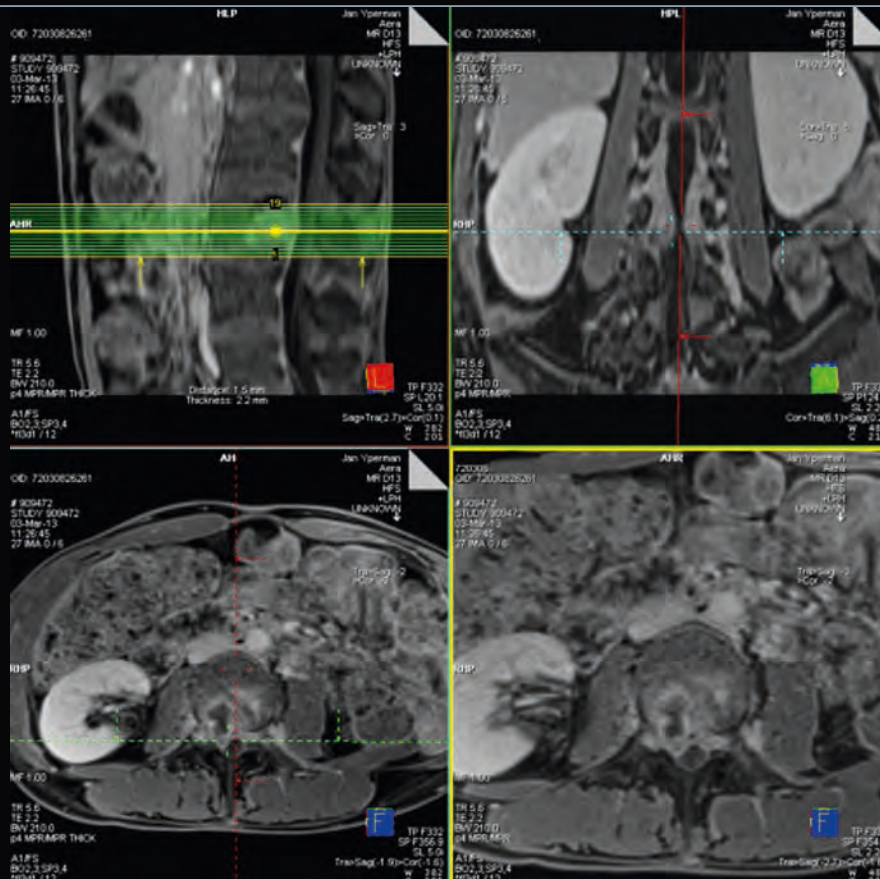
**13**

Standard sagittal T1w and T2w TSE demonstrate bone destruction of the third lumbar vertebra.

**14**

Contrast-enhanced sagittal T1 and T1 FS TSE (Dixon technique) demonstrate peripheral enhancement and invasion of the dural space.

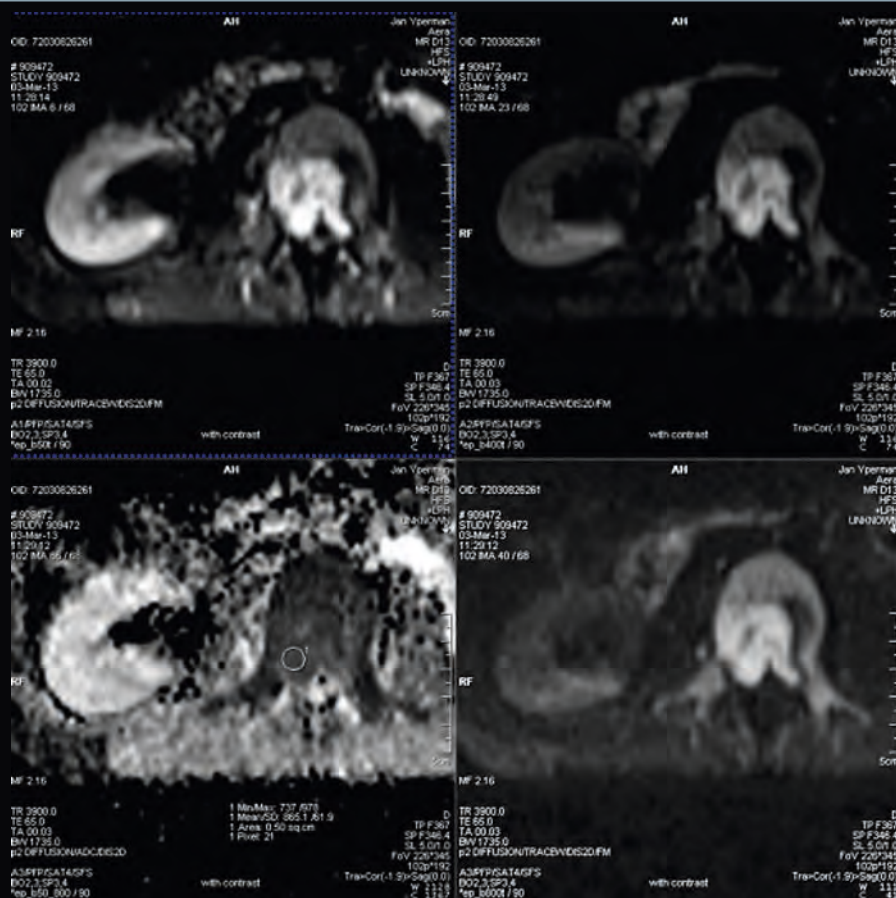
15



15

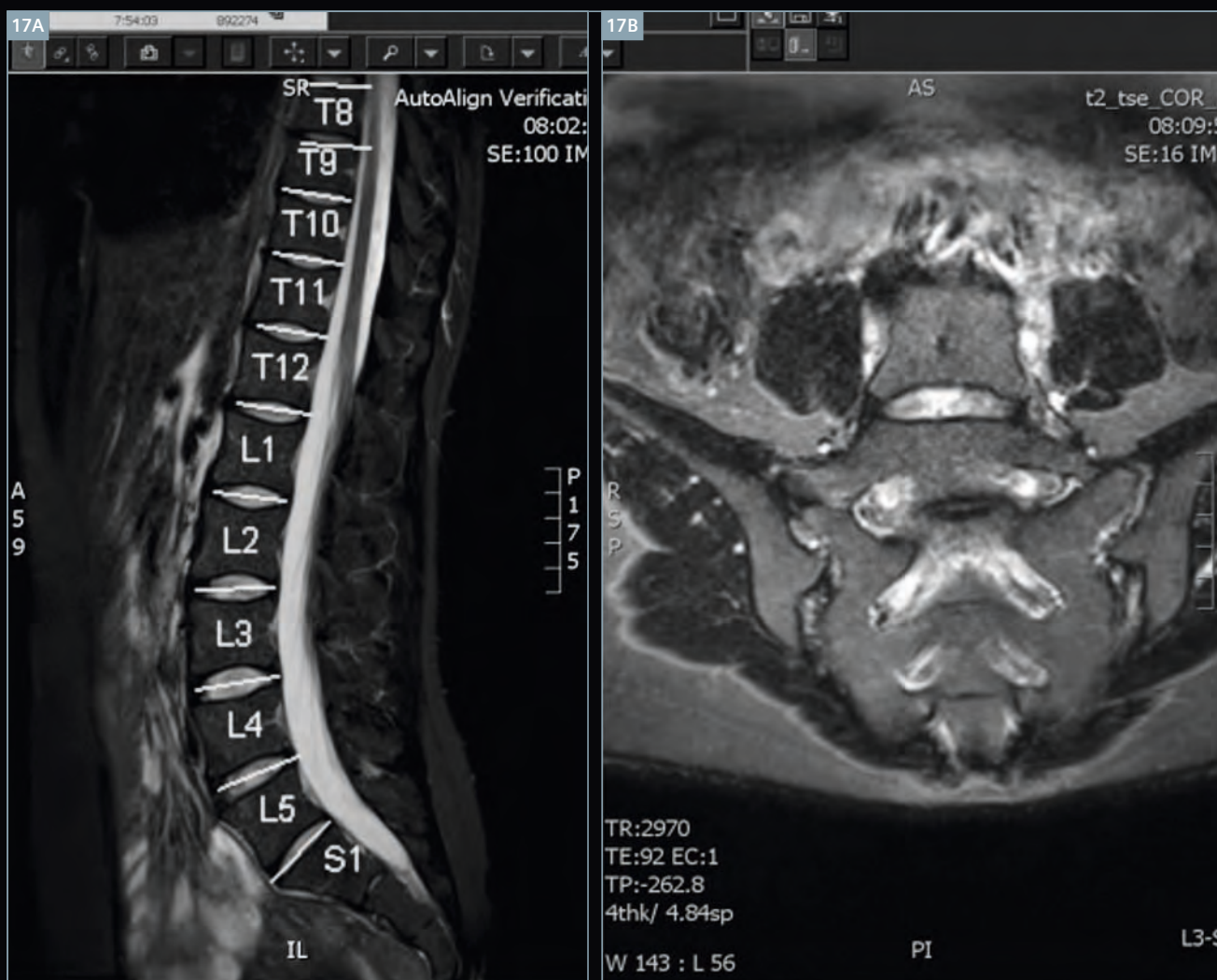
Contrast-enhanced T1w VIBE: breath-hold 21 seconds axial acquisition with coronal reconstructions demonstrate tumor extending in the spinal canal.

16



16

Diffusion-weighted imaging demonstrates restricted diffusion in favor of highly malignant lesion.



17 Unilateral right sided sacralisation of L5 (Type I) accurately labeled by the Spine Dot Engine in a patient with lower back pain.

Automatic vertebra numbering

Last but not least: Automatic numbering of vertebrae (starting your examination with the localizer at the level of the chin to include C2 as a reference) is a game changer.

Knowing the trouble that can occur with lumbosacral transitional anomalies and the detective work needed to discover if you are dealing with yet another sacralisation or lumbarisation, the accurate and reliable label-

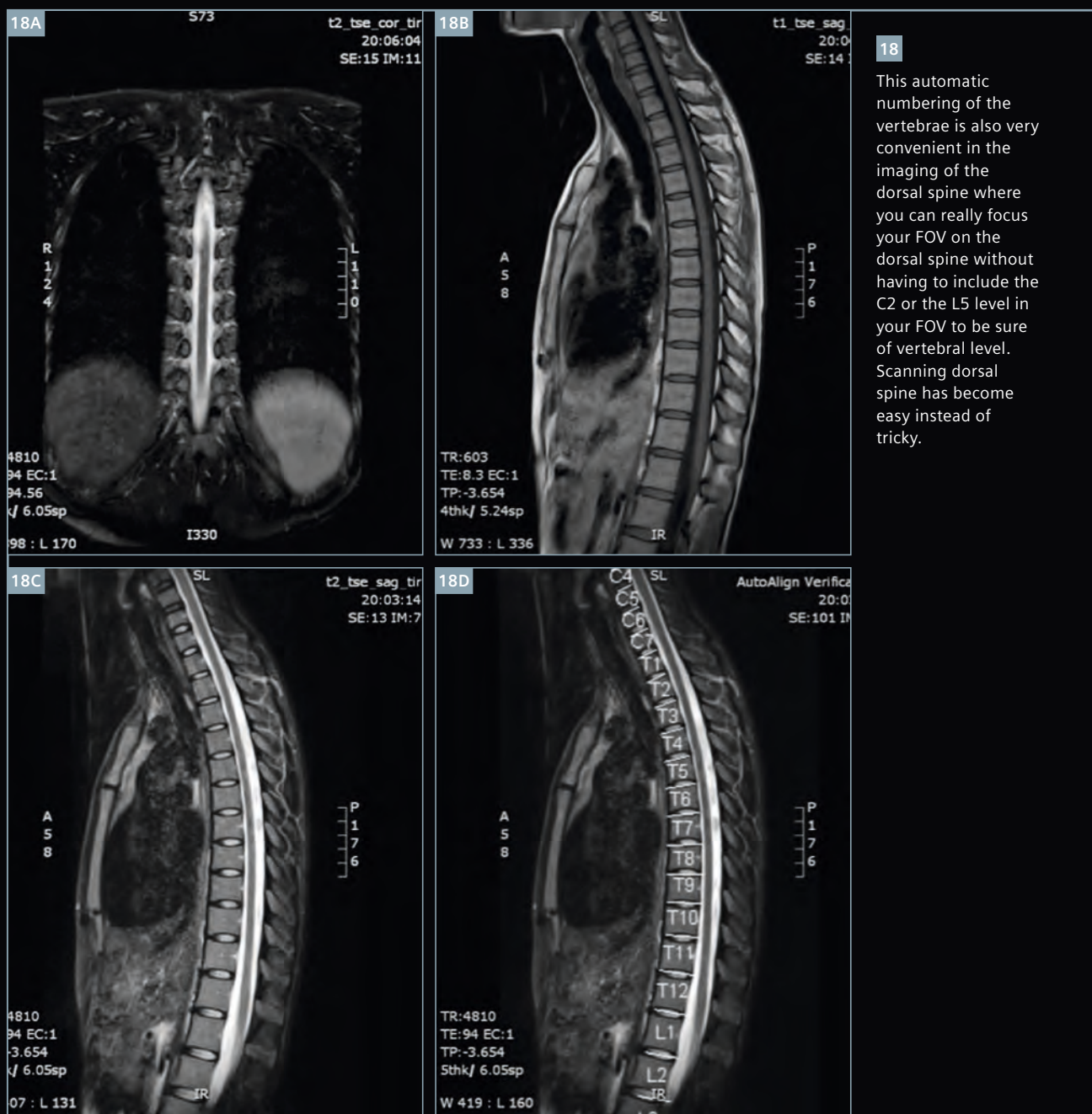
ing of the vertebrae by the Spine Dot Engine is a very convenient way of improving the quality and speeding up your reporting of lumbar spine examinations. Reported incidence of these transitional anomalies can be as high as up to 35.9% in some populations [1]

References

- 1 Erken E, Ozer HT, Gulek B, Durgun B. The association between cervical rib and sacralization. Spine 2002 ; 27:1659-1664.

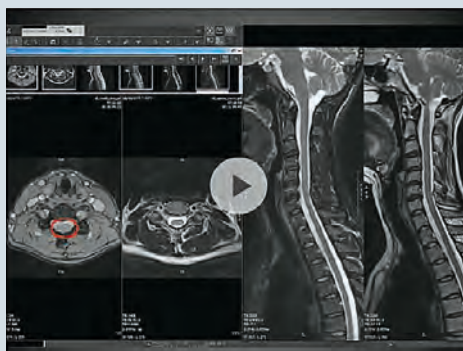Contact

Johan Dehem, M.D.
VZW jan Yperman
Yeper
Belgium
johan.dehem@gmail.com



Further information

Visit us at www.siemens.com/magnetom-world to listen to Dr. Dehem's talk on **Highest Quality Imaging in an Optimized Clinical Workflow** given during the lunch symposium at the 15th International MRI Symposium MR 2013 in Garmisch-Partenkirchen, Germany.



Johan Dehem, M.D.
VZW Jan Yperman
(Ieper, Belgium)