SIEMENS

AXIOM Innovations

The Magazine for Interventional Radiology, Cardiology, and Surgery

December 2013 | International Edition

Issue 17

Artis one.

Designed around you.
Page 8

Dear Reader,

I am proud to announce that at this year's RSNA we will launch our new system, Artis® one®. In the cover story you will read a compelling interview with Prof. Achenbach (University Erlangen-Nuremberg), who explains the essential imaging requirements for interventional cardiology, and provides insight on his expectations for Artis one. This new technology will redefine the way you interact with the system, the way you do interventions, and the resulting positive impact on your organization. As more and more hospitals are interested in increasing the utilization of their labs, the Artis one is designed to support a wide spectrum of procedures, from interventional routine to more complex interventions like TAVI or hybrid procedures; and all of this without compromising our image quality. Another impressive benefit of the Artis one is its surprisingly small footprint, needing a room size of just 25 square meters. This is a big advantage for hospitals with limited space. All in all, the new Artis one system allows a high utilization of the lab, enabling higher reimbursement and increased efficiency.

At surgical sites we see a significant trend toward multidisciplinary use in a hybrid lab environment. At the University of Ulm, for example, the Artis zeego® is used by seven different surgical specialties, all with different needs. In this edition you can read more about how the Artis zeego enables flexibility and tailored use for each individual doctor in one room.

I am also pleased to share further customer experiences with you, reflecting the high interest in the two new products we introduced just one year ago, the Artis Q® and the Artis Q.zen®. These two systems have now proven

“High utilization of labs as well as multidisciplinary teamwork is the trend we have to anticipate in the future.“

Dr. Heinrich Kolem,
CEO of the Angiography & Interventional X-Ray Systems,
Business Unit (AX) at Siemens Healthcare

themselves in everyday clinical practice, delivering up to 70% better visibility of small devices at the same dose and are able to generate equal image quality with up to 60%** less dose. We have already received more than 150 orders from around the globe and AXIOM Innovations took the opportunity to visit a few of the first installations to learn about their experiences.

Finally, I would like to offer my sincere thanks to you for your overwhelming response and very positive feedback to our AXIOM Innovations survey. This analysis clearly shows the increasing interest in the magazine. AXIOM Innovations has become a trusted source for information relating to medical technology and we look forward to continue providing you with our latest innovations.

Enjoy reading this edition!

Sincerely yours,

Dr. Heinrich Kolem

** Compared to previous X-ray tube technology. Data on file.

Content

One Year into a New Vision
with Artis Q and Artis Q.zen

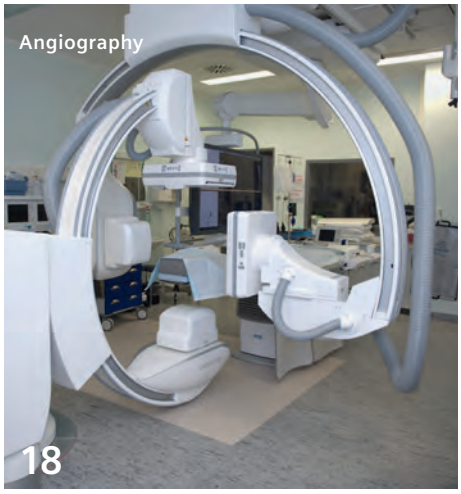

Towards One-Stop-Management
in Acute Stroke with Artis Q

Cover

Redefining Routine

Artis one redefines the way of interacting with the system, the way of treating interventions, and the resulting positive impact on organizations' reimbursement and profitable efficiency.

News

Cover Story

Angiography

How Integrated Fluoroscopy with CartoUnivu™ Can Help Reduce Unnecessary Radiation

A New Hybrid OR Improves Multidisciplinary Treatment

CARE+CLEAR: Standard with Every Artis System

Cardiology

Surgery

Customer Care

Frost & Sullivan named Siemens "Company of the Year 2013 in Interventional Radiology"

Multidisciplinary Hybrid OR with Artis Q and Surgical Table From Maquet

Haukeland University Hospital in Bergen just opened their first hybrid operating room in a newly built surgery center: an 80 square meter OR featuring the Artis zeego angiography system with the robotic technology of the Artis Q family. Equipped with a ground-breaking new tube and detector, as well as a host of novel software options, the Artis Q family offers outstanding image quality, dose saving features, and flexibility for imaging in multiple clinical disciplines. Another important benefit of the new Artis zeego system is the superior flexibility based on its robotic nature which is especially important in an OR environment. As an example, intra-operative 3D imaging (*syngo*® DynaCT) is possible even with the patient in a spine or sitting position, which is often crucial in neuro surgery as performed at Haukeland University Hospital. This Artis zeego system also features a host of other unique benefits, such as a variable isocenter. This allows for free adjustment of table and C-arm height to make work for the respective user most comfortable and ergonomic.

Artis Q with Maquet table in spine position.

John-Einar Thorsheim, Project Manager at Haukeland University Hospital, explained, "Our vision was to build a hybrid OR that numerous disciplines can benefit from – cardio-thoracic surgery, vascular surgery, neuro and trauma surgery, in cooperation with radiology and cardiology."

Combining the new Artis zeego with a surgical table does just that by adding to the versatility of the OR for use in both minimally invasive, hybrid, and open procedures.

Hybrid Operating Rooms for Little Patients

The Children's University Hospital Cracow
Photo: Barlomiej Pawlak

The Children's University Hospital Cracow recently opened one of the world's most modern hybrid ORs for pediatric treatment. It will contribute to saving the lives of newborns and infants with complex heart defects.

The 590-bed hospital is an important educational and research center, closely cooperating with leading pediatric hospitals from all over the world. Each year, the institute treats 28,000 children, provides 160,000 out-patient consultations, and performs 5,600 surgical procedures.

The hybrid OR offers both diagnosis and treatment in one room, in one procedure. Different steps that used to be done in a "staged" approach over several separate interventions can now be combined in one single procedure. Cardiac surgeons and cardiologists perform these extremely complex cases in a joint approach. This can lead to a reduced hospitalization and rehabilitation period, and a quicker return home for small patients.

The OR is equipped with a Siemens Artis zee® biplane angiography system, featuring a number of specialized applications to support physicians in their treatment. Particularly beneficial is the ability to acquire CT-like images in 3D through rotational angiography, known as *syngo* DynaCT, during a procedure in the OR, without having to transfer the patient to the CT scanner.

In the future, the hospital plans on further extending hybrid OR usage to include treatment such as electrophysiology procedures.

One Year into a New Vision

"The difference in image quality is immediately visible to the naked eye"

Prof. Martin Skalej, MD about Artis Q

Magdeburg, Germany

"With the new system, we feel far more confident in many interventions that we perform"

Prof. Frank Wacker, MD about Artis Q

Hannover, Germany

One year on from the launch of Siemens' new vision for interventional imaging, the Artis Q and the Artis Q.zen have firmly established themselves across the globe with more than 150 orders and 50 installations; from Japan in the Far East, to the USA in the West. From down under in Australia, to India in South Asia, and throughout Europe in the northern hemisphere.

The greatest measure for the success of the Artis Q and the Artis Q.zen has been the empowerment of interventional physicians around the world, eliciting responses such as those shown on the left.

The Artis Q and Artis Q.zen go way beyond incremental improvements in image processing. The most powerful interventional X-ray tube ever produced by Siemens, combined with the actively cooled 16-bit detector technology, is redefining what the performance and image quality of an interventional system should be.

Increasing the visibility of small structures by up to 70%*, even in obese patients and at steep angles, and reducing radiation dose by up to 60%*, the Artis Q is exceeding all expectations. The unique crystalline silicone technology within the Artis Q.zen detector has redefined the discussion on dose from low to ultra-low dose and is already clinically proven in electrophysiology.

Read more about our customers' first experiences with the Artis Q and the Artis Q.zen on the following pages.

* Compared to previous X-ray tube technology. Siemens data on file.

Redefining Routine

Instead of moving the patient around the system, the Artis one moves around the patient.

For more information, please visit the Artis one website.

Further Information

www.siemens.com/artis-one

Minimally invasive procedures are on the rise worldwide. Physicians are performing highly specialized interventions that were inconceivable just a few years ago. Some are complex interventions, such as treatment of a cerebral arteriovenous malformation (AVM) or revascularization of a chronic total coronary occlusion (CTO); however, these are only one side of the story. Most interventions are routine procedures – many of them performed repeatedly each day.

Different types of procedures have different needs when it comes to rooms and equipment. To meet those requirements, physicians prefer to have a dedicated room for each procedure type: one room for complex interventions, supported by equipment tailored to the customer needs. Routine labs should be optimized to cover a broad spectrum of procedures and to realize a high patient throughput.

Rethinking Technology

These new developments in market demand are reflected in the changing product portfolio of Siemens angiography systems. "We already support challenging cases with our established Artis Q/Artis Q.zen and Artis zee families," says Francois Nolte, Vice President of Marketing & Product Management AX at Siemens Healthcare. "However, for routine interventions, physicians need a system that can adapt to different scenarios and provide tailored support for each task. It must be easy to understand, so that rotating teams can adjust to it quickly." This requirement – to support a broad spectrum of procedures with ease – needed to be met without making compromises in image quality or dose saving.

In creating Artis one, Siemens took all these requirements into consideration. The result is a system that offers uncompromised image quality and a new, intuitive way of interaction. And what is more, Artis one can create a strong positive impact on organizations that use it. As Nolte points out: "To create a kind of universal Swiss Army knife for routine cases, we have rethought interventional imaging from the ground up." Siemens is presenting this latest addition to its Artis system portfolio at RSNA 2013.

Uncompromised Imaging

High-quality images are mandatory for successful procedures – especially for those requiring angiography. Artis one provides high-contrast images with excellent spatial and temporal resolution, and it also includes next-generation imaging tools that take image quality to a new level: CLEARstent Live enhances the stent image in real-time, allowing confirmation of the stent and the balloon markers at a glance. HeartSweep provides all the necessary diagnostic cardiac angulations in a single sweep, avoiding foreshortening. This makes it easier to find and navigate to the ideal projection for an intervention, allowing reductions in dose and contrast agent. Together with CLEARstent, these tools provide optimal support along the entire cardiology workflow, from diagnosis and interventional guidance to procedural assessment and documentation.

Some procedures also require enhanced anatomical understanding – for example, in assessing the shape of aortic aneurysms during endovascular aneurysm repair (EVAR). Here Artis one adds the third dimension with advanced 3D imaging tools, along with the possibility to view other modality 3D volumes such as CT, MR, or *syngo* DynaCT images. These tools make planning and orientation easier for the entire interventional team. With Artis one, 3D images are quickly and easily acquired. The results are processed in real-time and are available for the interventional case within seconds. In addition, they can be easily reviewed and manipulated from inside the examination room with an intuitive joystick control.

In addition to handling cardiac and body-vascular cases, universal angiography labs may also be used for peripheral procedures. These require an imaging system that permits whole-body coverage without having to move the patient. Artis one offers a longitudinal coverage of 2.10 meters, supporting peripheral interventions from head to toe.

To make sure that image quality does not come at the price of a higher radiation dose, advanced dose-saving technology is part of Artis one, which includes CARE+CLEAR. Additionally, Artis one features MEGALIX Cat Plus, the first angiography X-ray tube to offer a unique flat-emitter technology. "Rethinking a concept does not have to mean reinvent everything," explains Nolte. "At the end of the day, CARE+CLEAR has already proven its value in close to 5,000 installations around the world. And yet, including it for our customers as part of the package with all Artis systems is still unique within our market. By basing Artis one on state-of-the-art imaging technology such as CLEARchoice, we have made sure it delivers the image quality our customers prefer."

Intuitive Interaction

To ensure a high utilization rate, combo labs are often staffed by teams from multiple disciplines. So, their imaging systems must be easy to understand and intuitive to operate. These systems should allow anesthesiologists free access to patients as needed, and they should be easy

The broader the mix, the more the room will be used. With more patients treated, more procedures will be reimbursed – a simple equation that maximizes return-on-investment.

to move out of the way quickly in critical situations. All this requires an intelligent movement design.

"Artis one represents a paradigm shift," says Siemens development team member Oliver Hornung. "Instead of requiring medical teams to move the patient around the system, the Artis one system moves around the patient." Artis one features Siemens-built motor controllers originally developed for the manufacturing industry and now adapted to the needs of medical applications. These controllers allow a precisely synchronized movement of several axes, enabling a smooth adjustment to any predefined position. Whether for TAVI or abdominal procedures or for other vascular or hybrid procedures, the system always allows optimal access to the patient. "Artis one always knows where to go," explains Hornung.

Smooth system operation is also made easy by intelligent controls that keep the user's attention focused. All buttons are tactile, which makes them easy to find even beneath sterile covers. The new heads-up display provides all relevant information exactly where it is needed, with layouts that users can adapt to the needs of the procedure and their individual preferences. They can choose to display live X-ray images next to 3D images for better orientation, and they can also display data from hemodynamic or electrophysiological recording systems at the same time, as well as images from third party systems such as ultrasound. The size of the images can be adjusted as needed, allowing live images of the procedure to be as much as 90% larger (compared to the current standard of 19-inch screens).

Markus Rossmeier, PhD, who leads the user experience team at Siemens, summarizes Artis one and its new user interface as follows: "Focused information on an intelligently designed screen, with the entire unit configurable to be easy for rotating staff to use – all this allows interventional teams to make the most of their time and to potentially perform more procedures per day as a result."

Positive Impact

High treatment quality and economic success are by no means mutually exclusive – rather, they are two sides of the same coin. Hospitals can sometimes achieve both of these goals in a surprisingly simple way and thus stay competitive in the long run. Artis one is a case in point: it needs only one screen in the exam room, plus one in the control room. As a result, everything important is displayed in one place – and system installation becomes faster, so angiography rooms start generating revenues more quickly. In addition, Artis one has a small footprint offering large returns. With a minimum room requirement of just 25 square meters, it offers flexibility comparable to ceiling-mounted systems that generally occupy 45 square meters or more.

While easy installation and fast revenue generation are onetime effects, hospital managers will welcome another income-relevant aspect in which the procedure mix is a key factor. The broader the mix, the more the room will be used. With more patients treated, more procedures will be reimbursed – a simple equation that maximizes return-on-investment. Artis one represents a smart way for hospitals to hit the "sweet spot" of their business in today's environment while keeping options open for future procedures. Or, as François Nolte puts it: "As a manufacturer, we want to maximize the positive impact on our customers' organizations – by maximizing the use of their new angiography labs and improving their ROI."

Artis one has a small footprint – yet offers large returns.

Investing in Routine

By Hildegard Kaulen, PhD

Prof. Stephan Achenbach, MD, is the Chairman of the Department of Cardiology at the University Hospital in Erlangen, Germany. Smaller hospitals in the region refer patients there specifically for complex interventional cardiology procedures. At the same time, his department provides routine cardiac care for the city of Erlangen, with a population of 100,000, as well as the surrounding area. The University hospital is home to Erlangen's only 24/7 emergency service for interventional cardiology. We spoke to Prof. Achenbach about the daily balancing act between routine and advanced interventional procedures.

"A good angiography system provides good images; a very good system provides good images at low radiation dose."

Prof. Stephan Achenbach, MD
Cardiology Department,
University Clinic in Erlangen, Germany

Prof. Achenbach, has the spectrum of interventional cardiology procedures changed in recent years?
Of course. Today, we routinely carry out procedures that were simply not possible in the past. This includes transcatheter aortic valve implantation and transcatheter closure of the left atrial appendage to name just a few. Currently, we are even seeing the first catheter-based mitral valve replacements. The spectrum is constantly becoming broader as new techniques and approaches are being developed. However, it is very hard to predict what the mix of basic as compared to very complex procedures will be in typical cardiac catheterization laboratories just a few years from now. Even though you may hear many interventionalists ask "where have all the type A lesions gone?", routine procedures still clearly dominate the workload – and this is the case for every interventional cardiology program, including my own department. In our country it would not be possible to focus an entire program solely on complex procedures. In many cases they would not even be adequately reimbursed.

From your point of view, what constitutes a complex procedure and what is routine intervention?
While every intervention that initially seemed "routine" can unpredictably turn into a complex case at any time, I would draw a somewhat arbitrary line at chronic total coronary artery occlusions.

Were the situation to arise, would it be preferable to have separate rooms for complicated procedures and routine catheter interventions?
Certainly. That would make it easier to manage the caseload of the day. Not every patient who needs a cardiac examination requires a high-end system. Actually, for routine procedures, having to operate a very elaborate system may even be a distracting. For example, when the user is not fully familiar with the angiography system and interaction is not intuitive. Routine procedures are all about working quickly, safely and efficiently. It is patient throughput that counts. On the other hand, in the case of complex procedures, it is important to be able to take the time needed and not to feel under pressure because the next procedure is waiting in line.

What are the requirements for routine coronary interventions?
Users should immediately feel comfortable in the cath lab and be able to orient themselves quickly. Operating the angiography system should be easy and intuitive. Nobody wants straightforward procedures to be delayed by complicated menu selections. On the other hand, image quality will always be crucial. One should never assume that routine interventions do not require excellent image quality.

Why is image quality so important in cardiology?
Good image quality is a prerequisite for working safely and efficiently. With poor quality images, you run the risk of provoking mistakes and complications. Contrast-rich images with good spatial and temporal resolution help us to make the correct clinical decisions. Anyone who has become used to a particular standard would in any case find it difficult to put up with less during routine procedures. When it comes to image quality, every user has a comfort zone which he or she is reluctant to compromise. In addition, something else is important: a good angiography system provides good images; a very good system provides good images at low radiation dose.

Which software tools do you appreciate, besides the applications for reducing radiation exposure?
Post-processing tools do play a role. Some of the stents we now use are very delicate and therefore difficult to see. Tools that enhance stent visibility are extremely useful. For example, CLEARstent and CLEARstent Live allow you to reconfirm that the stent is fully expanded and was placed properly, or that the spacing of two adjoining stents is correct.

An intuitive user interface makes your work safer and more efficient. Do you see additional advantages?
An easy to learn and intuitive user interface is also certainly advantageous if several rotating teams use the same system, or if a broad procedure mix is being performed. And this is not just the case for smaller hospitals. Larger hospitals can, for instance, consider starting a peripheral program if cardiac procedures would not occupy an additional angiography system at full capacity. This way, the case mix is improved.

Would you see more flexible C-arm positioning as an advantage?
When I think about it, I can see numerous relevant advantages. At the moment we have a situation where the space around the patient's head is occupied by the C-arm. For procedures involving an anesthesiologist, this is where he or she would optimally be positioned. Also, as procedures become more sophisticated, the need for extra equipment – for example, various imaging modalities – in the cath lab increases. However, for this kind of support, you need to have enough room around the table, and the most valuable "real estate" is definitely close to the patient's head and chest. It woud therefore be really useful to be able to flexibly position the C-arm around the patient. In an emergency, being able to rapidly move it out of the way and far to the side may be crucial.

How important are space efficient angiography systems and a quick installation process?
Space is always limited in a hospital – in every department, wherever it is in the world. Therefore it is an advantage when a new or additional angiography system requires only little space. Naturally, it also makes a difference whether the installation process takes six weeks or just a couple of days: not just because of the immediate impact regarding procedures that would be missed. When a cath lab is out of action for a long time, cooperation with referring physicians can suffer. They may start referring their patients to other places, and the consequences of this can be long-term.

In your opinion, what advantages does the new Artis one offer?
Users are very satisfied when they can orient themselves quickly and work efficiently: when they are provided with good image quality; when they find useful tools at their disposal that they really need, and when the radiation exposure for them and their patients is as low as possible. In these respects, the Artis one system has a lot to offer.

You are soon to receive the very first Artis one worldwide. What are your expectations?
We are very excited. I see our new Artis one installation as a sound investment in routine. In the future, I continue to expect the majority of procedures there, and many of the procedures that we see as complex today will soon become standard, as well. It has always been this way. That is why I am so convinced that it is important to invest in a cath lab which will provide an optimal environment for my department's everyday challenges.

Hildegard Kaulen, PhD, is a molecular biologist. After holding positions at the Rockefeller University in New York and the Harvard Medical School in Boston, she became a freelance science journalist in the mid-1990s. She writes for a number of respected newspapers and science magazines.

Contact

hanno.herrmann@siemens.com
vera.juennemann@siemens.com

"I see our new Artis one installation as a sound investment in routine."

Prof. Stephan Achenbach, MD
Head of the Cardiology Department,
University Clinic in Erlangen, Germany

Artis Q
"During Interventional Therapy, Information is Everything."

The Department of Diagnostic and Interventional Radiology at the Hannover Medical School has two fully equipped DSA systems available for diagnostic angiograms and vascular interventions. Their most recent addition is an Artis Q ceiling – the first installation of this system dedicated for abdominal and peripheral vascualr Interventional Radiology worldwide. The Hannover IR team has now been working with the new Artis Q ceiling since June 2013, and AXIOM Innovations had the opportunity to meet Prof. Frank Wacker, Head of the Department, who shares his experience.

For more information please visit our Artis Q website

www.siemens.com/artis-q

Professor Wacker, your department performs more than 140,000 examinations per year. What is your main focus?
We are one of the largest comprehensive transplant centers in Europe, so many of our patients come here before or after a transplantation. In addition to diagnostic procedures, we perform approximately 1,200 angio procedures and approximately 500-600 CT-guided procedures.

What are the main interventional therapies you perform in the angio suite?
We treat a lot of liver cancer patients who are seen by our hepatologists at the MHH. In our multidisciplinary liver tumor board, we see fifteen to twenty patients with liver cancer per week, and many of these patients undergo transarterial chemoembolization (TACE) of the liver. TACE is indeed a bread-and-butter intervention in our angio suite but we also perform TIPS, we treat GI bleeding, and we do arterial recanalization and venous thrombolysis, but our main patient load is TACE.

Your new Artis Q system was installed around two months ago (June 2013). What were your expectations?
When Siemens informed us that they were developing a new system with a new tube delivering more power from smaller focal spots with shorter pulses, and a 16-bit detector, I was intrigued, however it is hard to estimate what such new technology really means in daily routine. To satisfy this curiosity we decided to test the system ourselves and measure dose levels before making any purchasing decision. A team lead by Bernhard Meyer, MD, the head of IR at the MHH, visited the Siemens factory in Forchheim to measure the possibilities of dose reduction and gauge the real benefit of this new technology.

From June until August your team has already performed around 140 procedures with the new system. What is your impression so far?
When a system is installed for the first time worldwide you always expect some hiccups or downtime, but we did not experience any of this. This is really amazing! From the first procedures, we started to lower the fluoroscopy dose gradually from intervention to intervention and were surprised that we could actually go lower and lower – and the image quality was still good. In some cases we could reduce the level to as little as twenty percent of the original dose.

Where is this significant dose reduction most important?
I think the greatest benefit lies in fluoroscopy. When you perform DSA and fluoroscopy, everyone in the room is affected by the radiation, not just the patient but also the operator, the technologist, and the radiologist. They are all close to the table, often for a fairly long time, and that is why a low dose is doubly important. At the same time you need good image quality to ensure that you do not have to repeat the DSA run or the *syngo* DynaCT.

How satisfied are you with the image quality?
You always expect better image quality from a new system. We wanted sharp images whenever we need them, with excellent contrast to see the smallest vessels, but at the same time we expected that the dose level for the whole procedure would be lower than what we had before. So far we are more than happy with what we got!

You perform a great number of different interventions in the angio suite. Did the purchase of the new system influence your range of treatments?
We treat more aneurysms now, both iliac and aortic aneurysms, in cooperation with our vascular surgeons. Normally they perform these interventions in the OR with a simple C-arm. But once they saw the image quality we can now provide and the 3D capabilities of *syngo* DynaCT, they were hooked! They now come down to our department with some of their more complicated cases.

"When a system is installed for the first time worldwide, you always expect some hiccups or downtime, but we did not experience any of this. That is really amazing!"

Prof. Frank Wacker, MD
Head of the Department of Diagnostic and Interventional Radiology,
Hannover Medical School, Germany

Beyond dose reduction, what differences do you see between Artis Q and former generations of angiographic systems?

I have worked with Artis systems before in Berlin and Baltimore, and one major difference is the increased speed of 3D acquisition. *syngo* DynaCT used to take eight or ten seconds but now you can get high image quality in a five second run, or sometimes in even less than five seconds – and that of course reduces breathing artifacts and movement artifacts significantly. The faster *syngo* DynaCT really is a main benefit.

When do you use *syngo* DynaCT?

syngo DynaCT is a milestone technology. You can use it whenever you need 3D information. I could give you numerous cases where it really improved our work. Maybe the most intuitive example would be a TACE procedure. When a patient comes for the first TACE, we do a single DynaCT run in the arterial phase and sometimes also a portal venous run. This gives us a good overview of the vessel anatomy. We see the tumor feeders and we find out if there are other arteries that go to the stomach or to the phrenic arteries. We can also identify the left and the right gastric artery, which is important when you plan selective internal radiation therapy (SIRT). With a single five second run you get a map of the arteries in good quality and with reduced motion artifacts. This helps in the initial therapy, but also when the patient comes back.

You use a lot of different materials in the interventional suite. Are there any devices or tools you can see better with the new system?

Our general impression is that the contrast between the surrounding tissue and the guide wire is improved for smaller guide wires and microcatheters. Especially in runoff vessels we use very thin, low-profile material such as 0.014 inch wires. So the higher contrast is of great help in our daily work.

What other applications do you consider beneficial in your new Artis Q system?

First, I simply have to repeat that *syngo* DynaCT is a milestone technology, which is, however, still underutilized in IR. Everybody in the IR community who finds it useful should emphasize the benefit because I really think it is of enormous value for the patients. But there are also other applications that are extremely helpful. *syngo* iPilot, for example, enables overlays of prior information from PET•CT, CT, or MRI. This helps you understand or treat better because you actually have the information where you need it – in the IR room. This is especially important when you have detected a tumor or a bleeder with CT. In times like today, where everybody uses smartphones and where we talk about augmented reality, *syngo* iPilot simply is a logical step.

Finally, there is *syngo* iGuide. I think needle guidance is very interesting for institutions that do not have enough CT capacity. For some interventions, *syngo* iGuide is a great help because instead of using CT guidance it allows you to do the puncture in the angio suite. For double oblique approaches *syngo* iGuide might even be faster than conventional CT guidance.

Can you give a concrete example of this?

There are applications such as endoleak therapy where you want to do a percutaneous puncture, like a direct aneurysm puncture, and then an embolization of the endoleak. Normally you had to make a compromise. You could use the angio suite – but there you would lack the perfect targeting tool for the percutaneous puncture. Or you had to perform the procedure in CT, where you could actually target the endoleak – but then the embolization would be much more difficult. The solution is an angio suite with *syngo* DynaCT because you can do the puncture with *syngo* iGuide and then perform the embolization using fluoro and DSA.

You often spend a long time looking at the display during interventions. How important is the large display of the Artis Q system for you?

During the intervention, information is everything. What I really like about the large display – beyond its actual size of course – is that you can have different layouts. You can choose if you want to see the PACS screen, vital signs, prior runs, or the *syngo* Workplace. So when somebody reconstructs additional information outside the IR room, the radiologist does not have to leave this room in order to look at the images. It is much more intuitive to bring the information into the IR room. We really appreciate this and we fought hard to get the large display.

How can Siemens best keep supporting you?

The most important thing is that you continue listening to us and working with us. Interventional radiology is one of the most exciting and interesting specialties in medicine. We continue to evolve, but technical innovation is very hard to justify just in itself, what we really need is support for multi-center studies showing the full benefit of IR technologies for the patient. So the role of Siemens is more than just selling machines. It also lies in supporting the work of the institutions and bringing them together for multi-center trials that bring the field forward.

Contact

simone.henrichs@siemens.com

"From the first procedures, we started to lower the fluoroscopy dose gradually … and were surprised that we could actually go lower and lower … In some cases we could reduce the level to as little as twenty percent of the original dose."

Prof. Frank Wacker, MD
Head of the Department of Diagnostic and Interventional Radiology,
Hannover Medical School, Germany

The Hannover IR team: Prof. Dr. Frank Wacker, Mirja Kobbe, Steffen Marquardt, Yvonne Jürgens, Dr. Jan Hinrichs.

Artis Q
Towards One-Stop-Management in Acute Stroke

By Philipp Grätzel von Grätz

Prof. Martin Skalej, MD

With the new Artis Q biplane angiography system, the Institute of Neuroradiology at Magdeburg University, Germany, is breaking new ground in the field of interventional neurosciences. Better image quality not only increases patient safety and provides new diagnostic possibilities. It also paves the way for entirely new approaches to patient care, for example the one-stop strategy in acute stroke management.

When Prof. Martin Skalej, MD, from the Institute of Neuroradiology at Magdeburg University Hospital in Germany was asked if he could imagine his institute becoming a test site for the new Siemens Artis Q biplane angiography system, he said yes almost immediately. The medical faculty of Magdeburg University has specialized in neurosciences, and the Institute of Neuroradiology, in particular, has a reputation for using the latest technology in imaging and interventional therapies. "This is why we were happy to be asked to be the first test site for the Artis Q biplane system worldwide," says Prof. Skalej. "And we really enjoyed contributing to the development of the system before the official launch at RSNA 2012."

Thanks to a new, more powerful X-ray tube, the new high-dynamic range detector with 16-bit read-out, the Artis Q product family features an unusually high contrast resolution even at steep angulations. The combination of new hardware and the new, dedicated cone-beam reconstruction algorithm delivers enhanced image quality with excellent soft-tissue resolution, especially in advanced 3D-imaging. "The difference in image quality is immediately visible to the naked eye," says Prof. Skalej. "It is especially relevant in fluoroscopy. With the new system, we feel far more confident in many interventions that we perform."

Improved Visibility of Coils and Stents

One example that illustrates the merits of higher image quality particularly well is neuroanatomical interventions with blood vessel implants. In patients with aneurysms of the cerebral arteries, for example, the implantation of little platinum spirals, or coils, is the therapy of choice for preventing ruptures. But there is a problem: these metal structures are highly radio-opaque. They generated many artifacts on older systems. This has improved considerably with the new detector technology of the Artis Q, according to Prof. Skalej, "We can be more confident than before that we are

looking at the correct projection and that we have coiled the aneurysm completely. I am convinced that this translates into fewer complications and thus increased patient safety." Another example that shows the clinical relevance of better image quality is cancer patients with bone metastases in the spinal cord. These patients are treated with radio-frequency ablation (RFA), a technology that heats the tissue to 80 to 100 degrees centigrade in order to selectively destroy the tumor. "The difficulty is placing the needles so that the tumor tissue and not the medulla is targeted. This is much easier when the image quality is good. So we now perform almost all spinal cord interventions in tumor patients on the new angiography system."

The improvements in X-ray tube and detector technology can also be used to reduce radiation dose while maintaining image quality, says Prof. Skalej: "In fluoroscopic interventions, we will always go for maximum image quality to ensure that the implants are optimally placed. But in follow-up examinations, or in situations where we only need an overview image, the option for dose reduction is really intriguing."

Acute Stroke – Time is Brain

Even more intriguing are the new opportunities that the Artis Q system creates in the management of patients with acute stroke. For many years, the standard of care in patients with acute ischemic stroke was intra venous thrombolysis – provided that the patient arrived early enough at the hospital for the thrombolytic agent to be administered within 4.5 hours after onset of stroke. In recent years, however, new interventional treatments of patients with ischemic stroke have increasingly gained acceptance. With the aid of stent technology and intra-arterial retriever devices, thrombolytic material is extracted from the vessel and blood flow restored.

Prof. Skalej emphasizes that, for the moment, intravenous (i.v.) thrombolysis remains standard of care: "The patient group that most benefits from intra-arterial interventions has not yet been well defined. But we know, for example, that a thrombus of more than eight millimeters in length in the middle cerebral artery almost never disappears with i.v. thrombolysis alone. These are the patients who typically benefit from interventional therapies." In Magdeburg, around 60 out of 800 stroke patients a year are being treated with interventional therapies. "This is a good number for a city like Magdeburg with its rural surroundings. In fact, with our 60 intra-arterial stroke interventions per year, we are already getting close to the aneurysm interventions, of which we perform 80 per year." Within this broader trend towards a more diversified treatment paradigm for stroke patients, the Artis Q system offers an exciting prospect: thanks to the increase in image quality, "one-stop stroke management" may become possible. Patients with suspected stroke who are referred to the hospital by emergency services could have all the necessary diagnostics and initial treatment in the angio suite, very similar to patients with myocardial infarction who nowadays are brought directly into the cath lab without any further delay.

Functional Diagnostics for Angio Systems

One-stop stroke management is dependent on two things: first, it is necessary to exclude intracranial bleeding directly with the angiography system and not, as currently standard, with a diagnostic CT or MRI. The introduction of the Artis Q system was a massive step forward in this respect. Once a hemorrhage is excluded, patients can be treated with either i.v. thrombolysis or intra-arterial recanalization without having to transport them to a different room or relocate them. The second important step is to differentiate between patients who benefit most from i.v. thrombolysis and patients who benefit from an intra-arterial intervention or a combination of intervention and i.v. thrombolysis. The research is ongoing. Most neurologists and neuroradiologists agree that functional brain imaging could be the key to making this distinction, for example the measurement of the brain perfusion. At the moment, this is usually done by CT or MRI. With the Artis Q system, Prof. Skalej and his collaborating partners from Siemens have embarked on a research project that aims to make functional diagnostics available for angiography systems. The option to measure the parenchymal blood volume (*syngo* DynaPBV Neuro) as a static perfusion parameter has already become part of the product. Prof. Skalej is convinced that more perfusion-related parameters will follow: "*syngo* DynaPBV Neuro is the first step. Now we are working on how to determine dynamic parameters like the cerebral blood flow (CBF) and mean transit time (MTT). If we succeed, hospitals will truly be able to offer one-stop stroke management in the angio suite and to set CT aside."

syngo DynaCT Micro and i.v. *syngo* DynaCT DSA Extend the Spectrum

One-stop stroke management is definitely on the horizon, but the technology is not quite there yet. Other features of the Artis Q system are, even today, extending the possibilities of routine neuroradiological care. One feature that Prof. Skalej particularly likes is the option of performing an intravenously injected *syngo* DynaCT-angiogram with the Artis Q: "I.v. *syngo* DynaCT angiography works extremely well with the Artis Q. It is not possible to achieve the same image quality with other systems since there are far more artifacts and resolution is much poorer." Prof. Skalej is using i.v. *syngo* DynaCT for follow-up examinations of patients with stents or flow-diverters. After implantation of these devices, follow-up examinations are necessary every three to six months. They can be done as arterial angiographies, but this is a more invasive procedure than the i.v. angiography, which only requires a small hollow needle in the vein to administer contrast medium.

Another new function of the Artis Q system that Prof. Skalej and his colleagues from the Department of Otolaryngology have intensively researched is *syngo* DynaCT Micro. This allows the finest and most intricate anatomical structures to be visualized, for example in the inner ear. "We have carried out experimental and clinical studies in patients who need cochlear implants. These studies have proved very successful, so much that we now use the method in daily routine," says Prof. Skalej. *syngo* DynaCT Micro is also used in patients with inner-ear tumors, in trauma patients, and in patients with malformations. "The Artis Q and *syngo* DynaCT Micro is a quantum leap from regular cone-beam CT in terms of spatial resolution and is well advanced from what is offered by today's conventional MSCT."

Philipp Grätzel von Grätz is a medical doctor turned freelance writer and book author based in Berlin, Germany. His focus is on biomedicine, medical technology, health IT, and health policy.

For more information please visit our Artis Q website

Further Information

www.siemens.com/artis-q-family

Contact

stefan.sl.lautenschlaeger@siemens.com

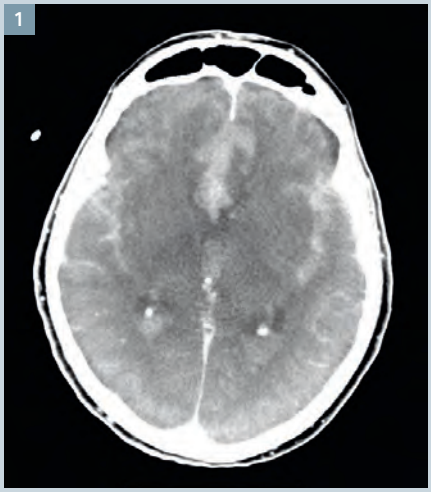

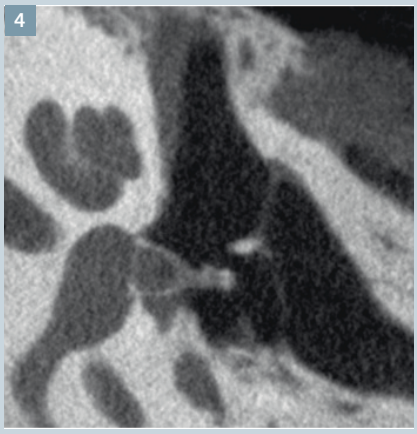

1 *syngo* DynaCT with the HDR detector and dedicated cone-beam reconstruction showing SAB (subarachnoidal bleeding) and frontal bleeding.

2 *syngo* DynaCT with the HDR detector and dedicated cone-beam reconstruction showing sinus close to the skull base.

3 *syngo* DynaCT Micro showing the overlap of two Surpass flow diverters.

4 *syngo* DynaCT Micro offering high-resolution temporal bone imaging.

Stroke – Thrombectomy Supported by *syngo* iFlow

Courtesy of Beverly Aagaard-Kienitz, MD, and Charles Strother, MD

Department of Radiology, University of Wisconsin School of Medicine and Public Health
Madison/Wisconsin, USA

Patient History

A 49-year-old left handed woman with sudden onset of left hemiplegia noted to have a right M1 MCA occlusion on a CT angiogram. Five hours after stroke onset and two hours after IV tPA the patient was transferred to neurointerventional radiology for further treatment.

Diagnosis

Cerebral angiogram shows complete occlusion of the M1 segment of the right MCA. No other abnormalities were present.

Treatment

Following a combination of mechanical thrombectomy using a penumbra aspiration device and thrombolysis, the final angiogram demonstrates only a small distal thromboemboli with the angular artery.

Comments

The initial CT Perfusion scan showed a reduced CBF and a prolonged TTP and MTT in the territory of the right M1. Using *syngo* iFlow very slow flow was seen in the arteries supplying the tissue shown to have abnormal CBF, TTP and MTT on the PCT. After successful recanalization the final angiogram with *syngo* iFlow applied demonstrated significant improvement in blood flow in these arteries as compared to the initial study.

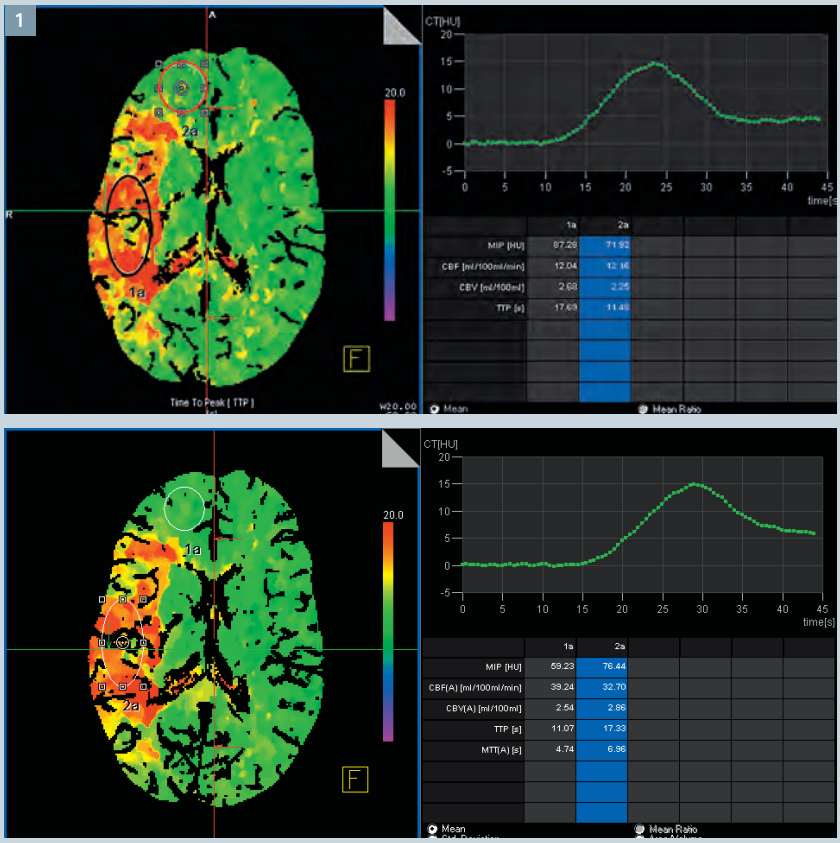

1 The pre-treatment CT Perfusion scan shows reduced CBF and prolonged TTP and MTT in the distribution of the right MCA. The green time attenuation curve on the top shows the TTP in the ROI indicated by the red circle. The green time attenuation curve on the bottom shows the TTP in the ROI indicated by the black ellipse. There is a 6.2 sec. delay in TTP in the ischemic tissue. The curve from the ROI in the ischemic tissue also shows that there is slower wash out of contrast in this region than from the tissue in ROI placed over normal tissue.

Contact

heike.theessen@siemens.com

kevin.royalty@siemens.com

2

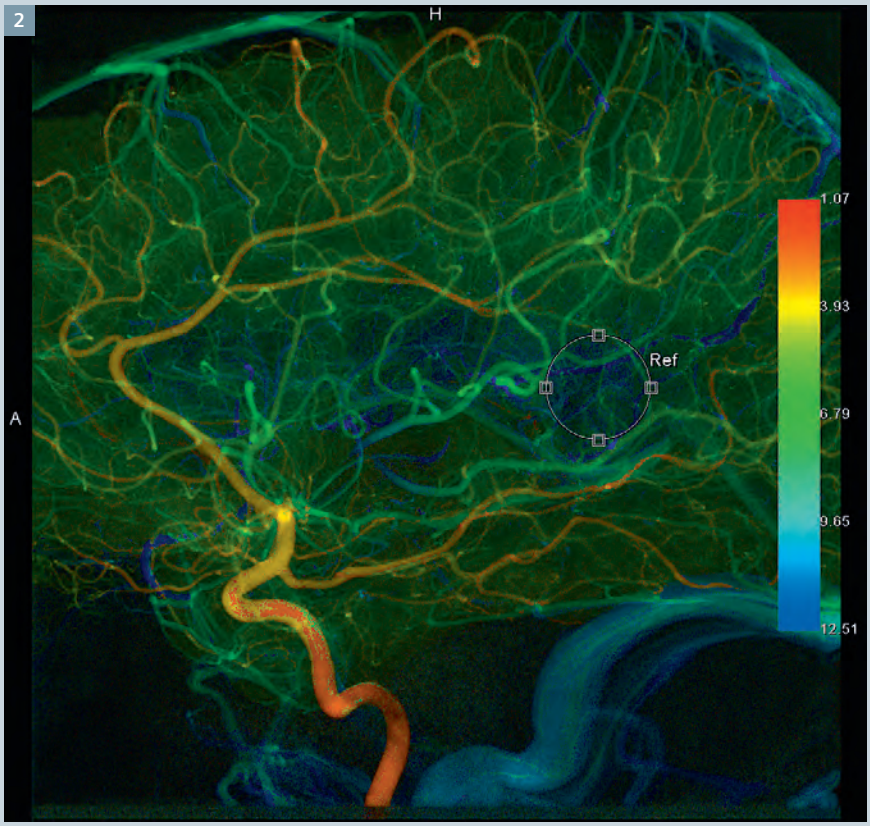

2 *syngo* iFlow shows very slow flow in the M2 and M3 branches of the right MCA with some branches filling 12.5 sec. or more after start of the acquisition. In this image the TTP in all anterior cerebral and posterior cerebral branches is in the range between 2 and 3.5 sec.. The TTP in the MCA branches is significantly longer with values ranging between 6.5 and 12.5 sec. or longer. These values correlate well with the differences in tissue TTP seen on the PCT scan.

Time intensity curves from a ROI in the ischemia

3

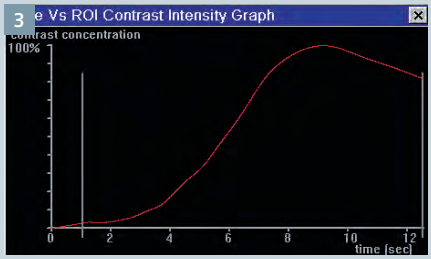

Pre-revascularization

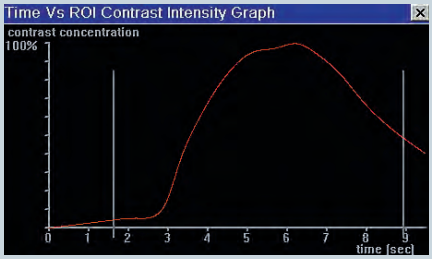

Post-revascularization

3 The pre-revascularization TIC shows that the TTP in the ischemic tissue included in the ROI occurs about 9 sec. after start of the acquisition. Following revascularization this value decreases to about 6 sec.. Following treatment contrast washes out of the ROI much faster than it did prior to revascularization. The *syngo* iFlow image and these curves give an operator insights into tissue perfusion which cannot be extracted visually from the standard 2D DSA acquisition.

Objective Assessment of Transcatheter Arterial Chemoembolization Supported by *syngo* iFlow

Courtesy of Xue-bin Zhang, MD

Department of Interventional Radiology, Renji Hospital, Shanghai, China

Patient History

A 53-year-old male patient was diagnosed with cholangiocellular carcinoma three years ago and has already received transcatheter chemoembolization (TACE) ten times, at an interval between one and a half and three months. Now he has been admitted to the hospital for further treatment.

Diagnosis

Upper abdominal MR scan showed multiple intra-hepatic metastases. Compared to previous MR images the lesions have clearly increased in size and proliferated in number.

Treatment

A pre-procedural DSA was performed with the catheter tip at the common hepatic artery. Embolization was performed selectively using iodized oil (Lipiodol Ultrafluide; Guerbet, France) mixed with mitomycin. Gelatin sponge particles (Alicon, Hangzhou, China) with a size of 1 µm were utilized to enhance the embolic effect. A post-treatment angiogram was obtained with the same acquisition parameters.

Xue-bin Zhang, MD

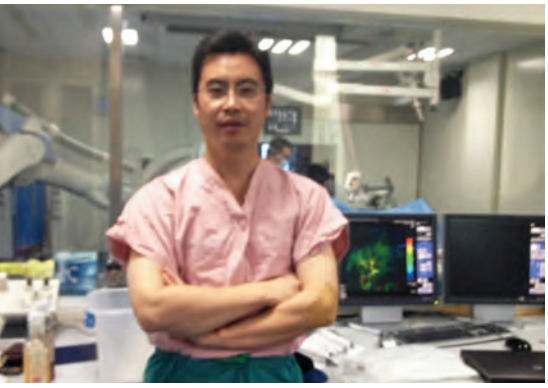

Data Analysis

syngo iFlow images were generated for both pre- and post-procedural DSA sequences. The maximum enhancement and the time to peak (TTP) were measured respectively at several homologous anatomic landmarks: (A) The origin of the tumor feeding artery (TFA), (B) the embolized site of the TFA and (C) the parenchyma of the tumor (Fig. 1). The difference of TTP between landmarks (A) and (B) was defined as the tumor blood supply time (TBST).

The pre- and post-*syngo* iFlow images illustrate that the TTP of the embolized site of the TFA was delayed from 5.07 sec. to 6.93 sec., and the TBST after embolization (2.66 sec.) was also greatly delayed compared to that before embolization (0 sec.), which quantitatively measured the deterioration of the hemodynamic condition of the lesion.

In addition, a circular region of interest (ROI) was selected in the proximal and distal TFA for measurements of pre- and post-DSA sequences (Fig. 2), which visualized the ROI time intensity curve (TIC) and calculated the ratio of area under the curve (AUC), Peak Intensity (PI) between the origin (ROI Ref) and distal end (ROI 2) of the TFA (Fig. 3) in addition to the pixel measurements.

The pre- and post-procedural TIC of proximal TFA both rose steeply, they presented a quick-in and quick-out pattern; the post-procedural TIC of the distal TFA changed from a quick-in and quick-out to a slow-in and slow-out pattern. TTP for proximal and distal TFA were the same (5.07 sec.) before the interventional treatment. After the treatment the TFA delayed from 5.33 sec. to 6.93 sec., which corresponded with the result of the pixel measurement. Ratio of AUC (ROI 2 AUC/ROI REF AUC) decreased from 1.28 to 1.05 after the embolization.

Comments

syngo iFlow offers a new way to represent DSA series and provides an objective evaluation measurement. All measured values such as TTP, AUC, PI, and TIC curve pattern can be analyzed to detect the physiological changes induced by the embolization. It may serve as a functional biomarker to help to determine the optimal end point for TACE procedures. A preliminary study regarding this topic has been performed and the results were presented at RSNA 2012 [1].

[1] Zhang XB, Zhuang ZG; Ye H; Beilner J; Kowarschik M, Cheng J. A quantitative assessment for the endpoint of transcatheter arterial chemoembolization: preliminary study of color-coded digital subtraction angiography. RSNA. 2012.

Contact

kaiyi.huang@siemens.com

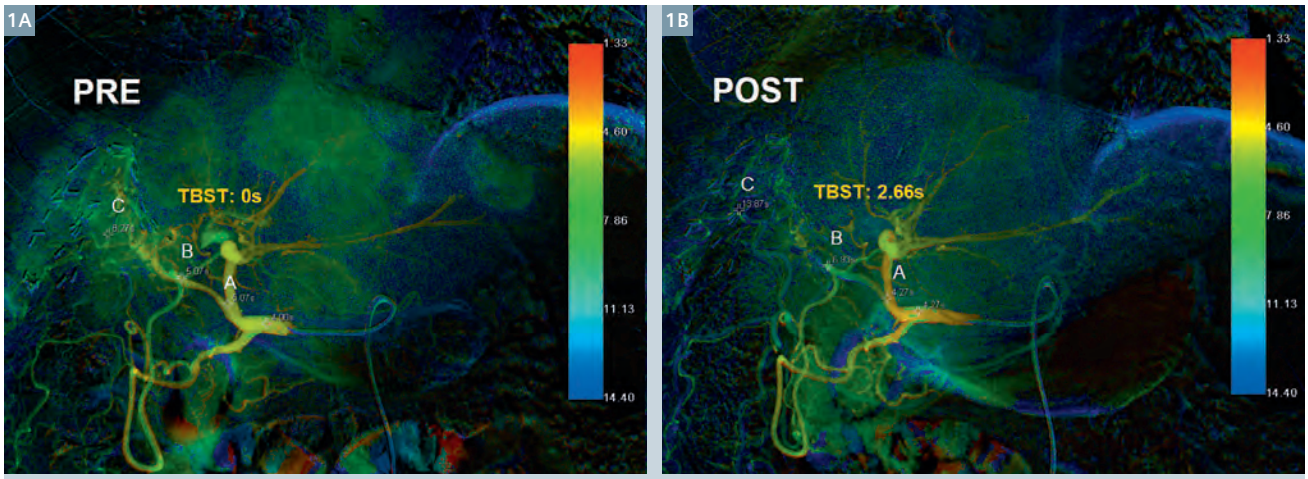

1 The measurement of TTP on respective points along the main tumor feeding artery and tumor parenchyma pre- and post-embolization. The differences of TTP between the origin of the main tumor feeding artery and the embolized site of the main tumor feeding artery (TBST) pre- and post-procedure were calculated.

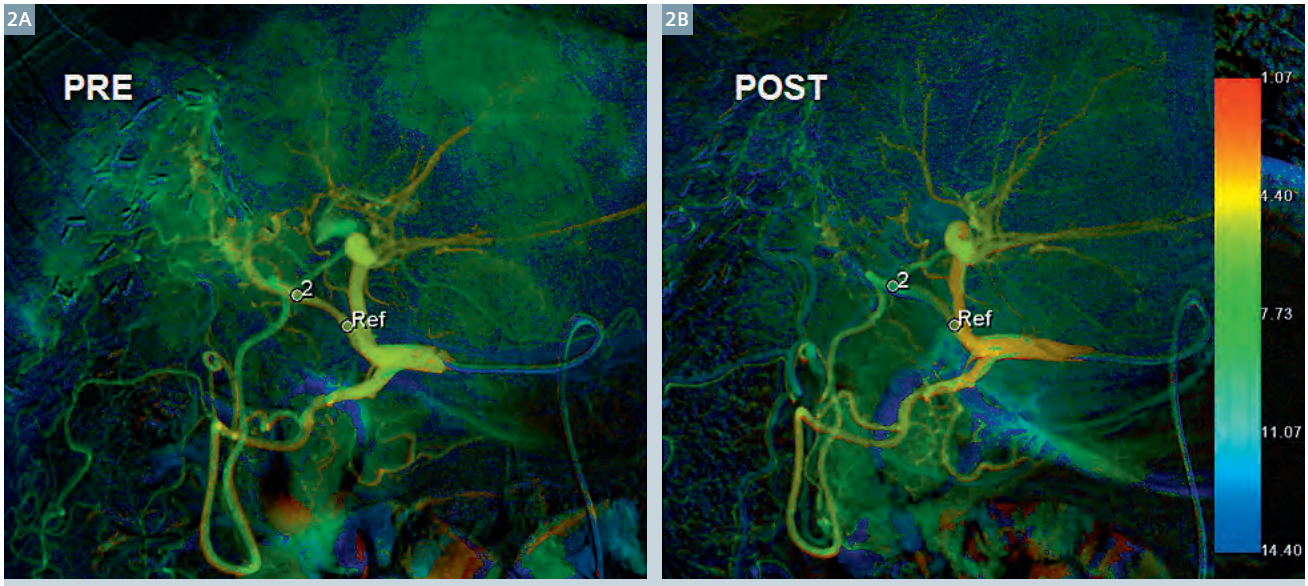

2 ROI measurement of the origin and distal end of the tumor feeding artery for pre- and post-procedural DSA sequences.

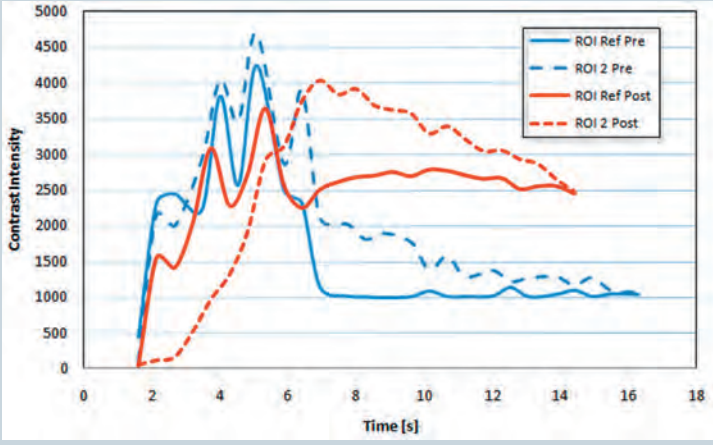

3 TIC of TFA for pre- and post-procedure, exported by *syngo* iFlow. It showed a different curve pattern with decreased AUC, PI and increased TTP after embolization.

Intra-Arterial CBV Imaging for Whole Brain Supported by Intra-Arterial *syngo* DynaPBV Neuro

Courtesy of Ruxiang Xu, MD, and Qiang Zhang, MD

Affiliated Bayi Brain Hospital, Military General Hospital of Beijing PLA, Beijing, China

Patient History

A 40-year-old male patient with a ten year history of hypertension and hyperlipemia experienced hypertensive intracerebral hemorrhage at the right basal ganglia two years ago. He was treated using brain hematoma puncture drainage and medication. After the treatment he showed remaining symptoms of left limb weakness.

Diagnosis

The patient's muscle strength (level 0-5, with 0 complete paralysis and 5 normal) was tested to be level four for the left upper limb, level five for left lower limb and right limbs. The muscle tension was increased for left limb tendon, together with hyperreflexia and positive pathological reflex detected for the left limb.

Computed tomography (CT) examination showed two encephalomalacia lesions at right basal ganglia and right temporal lobe, respectively (Fig. 1).

Conventional intravenous CT perfusion imaging (CTPI) and an intra-arterial *syngo* DynaPBV Neuro examination were performed. In order to generate *syngo* DynaPBV Neuro images, visualization of a 3D mask was acquired first. Then a pigtail catheter was placed at the ascending aorta and 24 cc of 75% diluted contrast agent (CA) (Iohexol 350, Beijing BEILU Pharmaceutical Co., Ltd.) was injected over 24 sec. at an injection rate of 3 cc/sec.. To ensure that the brain tissue was sufficiently perfused, a *syngo* DynaPBV Neuro run was performed by an Artis zeego system with 16 sec. delay.

Image Analysis

Cerebral blood volume (CBV), which is an important perfusion parameter indicating brain hemodynamics in the capillary level and viability of the brain parenchyma, was obtained from both techniques and compared.

From Fig. 2 and Fig. 3, both CTPI and *syngo* DynaPBV Neuro images demonstrated a similar decrease of CBV value at the right basal ganglia, left temporal lobe and bilateral frontal lobe. A minor difference was only observed at the bilateral frontal lobe, where a low perfusion region in the *syngo* DynaPBV Neuro images was shown to be smaller than in the CTPI images. In addition, it can be seen that a major encephalomalacia lesion, starting from the right basal ganglia and extending to the right temporal lobe in the CT image (Fig. 1B) was even more precisely captured in the *syngo* DynaPBV Neuro image (Fig. 3B) in terms of its shape and size.

Comments

syngo DynaPBV Neuro offered a way to acquire brain functional information immediately in the catheter lab, which indicated disorders of brain perfusion. From the results shown in this case report, in general, CBV value obtained with this technique matched well with the results from conventional CTPI, proving the capability of *syngo* DynaPBV Neuro for displaying normal brain tissue and detecting lesions with good accuracy. In particular, this technique demonstrated higher sensitivity than CTPI for detecting a large encephalomalacia lesion, which corresponded better to the findings in CT images. Moreover, compared with intravenous injection, the intra-arterial CA injection protocol adopted in this study required only 15% of CA. This helped to minimize the CA induced side effects.

Contact

qi_sun@siemens.com

Qiang Zhang, MD (left) and Ruxiang Xu, MD (right).

1 CT images from two representative slices. Two encephalomalacia lesions can be observed at the right basal ganglia and right temporal lobe.

2 CTPI images from two representative slices. Low perfusion regions were found at right basal ganglia, left temporal lobe, and bilateral frontal lobe.

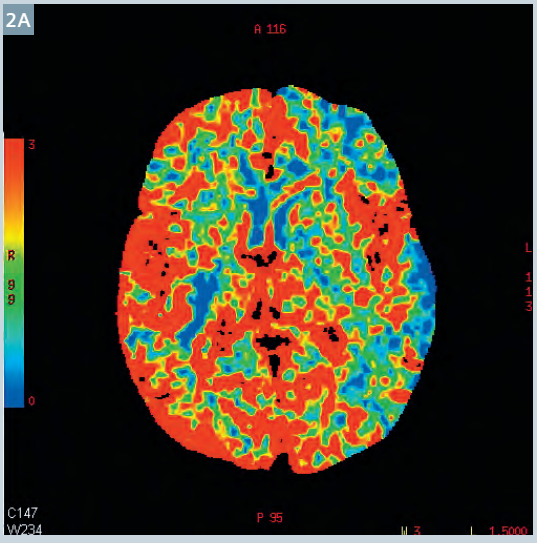

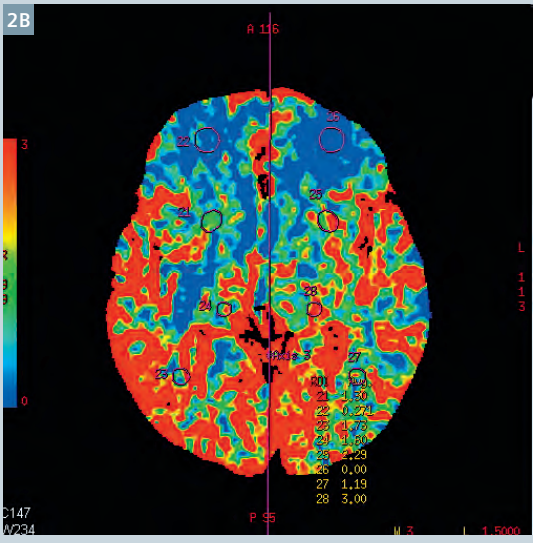

3 *syngo* DynaPBV Neuro images from two representative slices. Low perfusion regions were found at the right basal ganglia, bilateral frontal lobe and temporal lobe.

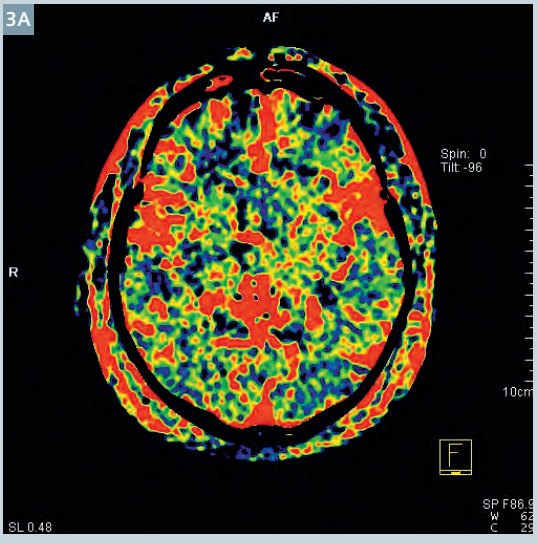

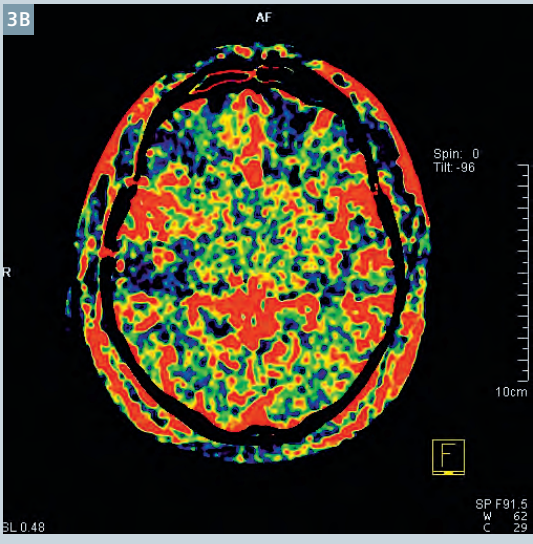

Accurate Placement of Flow Diverter Device Supported by *syngo* DynaCT

Courtesy of Ciceri Elisa, MD, Faragò Giuseppe, MD, Caldiera Valentina, MD, Sagaria Nazario, and Listrani Massimiliano

Neurological Institute C. Besta, Milan, Italy

Patient History

68-year-old female, with several years' history of headache, referred for neurological evaluation and treatment after incidental finding of a wide-neck carotid-ophthalmic aneurysm.

Diagnosis

Angio-CT and MRI demonstrated the presence of a left paraophthalmic aneurysm. The aneurysm measures 8 mm in its largest diameter, with a neck of 6 mm. The ophthalmic artery arises in proximity to the aneurysmal neck (Fig. 1A and 1B).

After collegial discussion with the neurologists and neurosurgeons, endovascular treatment was suggested. Benefits and risks of the treatment were discussed with the patient, and finally the procedure was performed successfully utilizing a flow diverter device (PED) (Pipeline, ev3, Irvine, California).

Treatment

After one week double anti-platelet therapy the procedure was performed under general anesthesia and systemic heparinization. The *syngo* InSpace 3D rotational angiography visualized the aneurysmal sac and the morphological details of the surrounding vessels by VRT reconstructions. The best working position was determined and correct measurements of the parent artery were performed in order to correctly choose the dimension of the PED (Fig. 1c). The procedure was performed under *syngo* iPilot guidance merged with standard roadmap DSA, to provide the best 3D live roadmap visualization during PED positioning (Fig. 2).

Comments

The PED was carefully deployed across the aneurysmal neck. A final *syngo* DynaCT acquisition precisely showed the relationship between the PED, the parent artery, and the ophthalmic artery (Fig. 3). Additionally, to clarify the position of the PED at the level of the tortuous carotid siphon, a fusion with MRI and *syngo* DynaCT image reconstruction was performed (Fig. 4). The procedure was arranged without any technical or clinical complications and the patient returned for the 6-month follow-up angiography that showed complete disappearance of the aneurysm with preservation of the antegrade flow in the ophthalmic artery (Fig. 5).

Contact

stefano.boriotti@siemens.com

1 3D-Time-of-flight-MR, axial (A), MIP coronal reconstructions (B) and 3D rotational angiography VRT reconstruction (C) of the left internal carotid artery. The ophthalmic artery origin is close to the aneurysmal neck (arrow). Note pre-treatment measurements of the parent artery and of the aneurysmal sac.

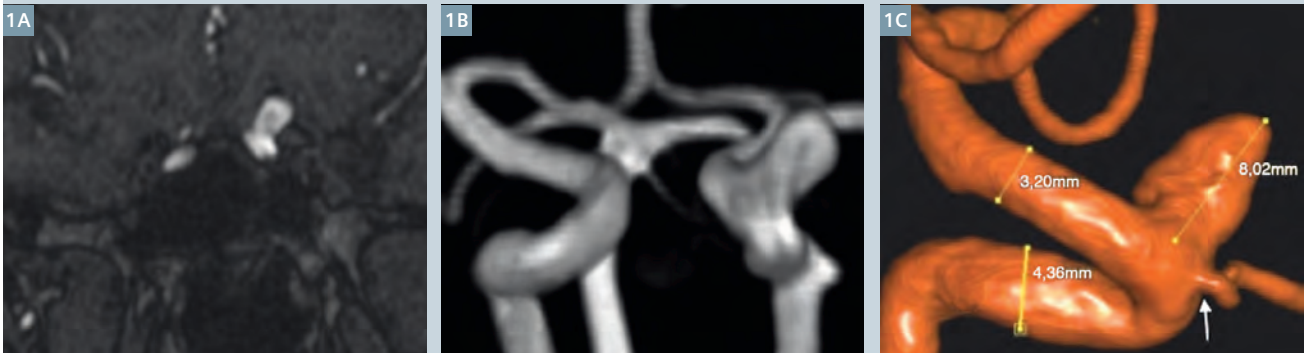

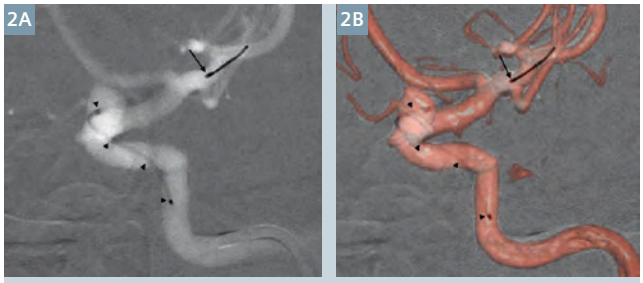

2 Standard intraprocedural roadmap DSA (A), overlapped with *syngo* InSpace 3D rotational angiography (B) utilizing the *syngo* iPilot system, allow a more accurate live 3D intravascular navigation during the release of the PED. Distally, the microwire extends above the tip of the microcatheter (arrow) inside the middle cerebral artery. The PED, slightly radio-opaque, is progressing within the microcatheter, still unsheated (arrowheads).

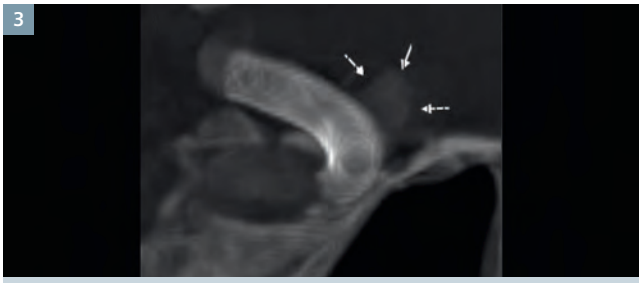

3 Post-treatment *syngo* DynaCT, oblique VRT reconstruction, showing the PED well deployed across the aneurysmal neck inside the parent artery, covering the ophthalmic artery origin. The aneurysmal sac is faintly opacified by contrast stagnation (arrows).

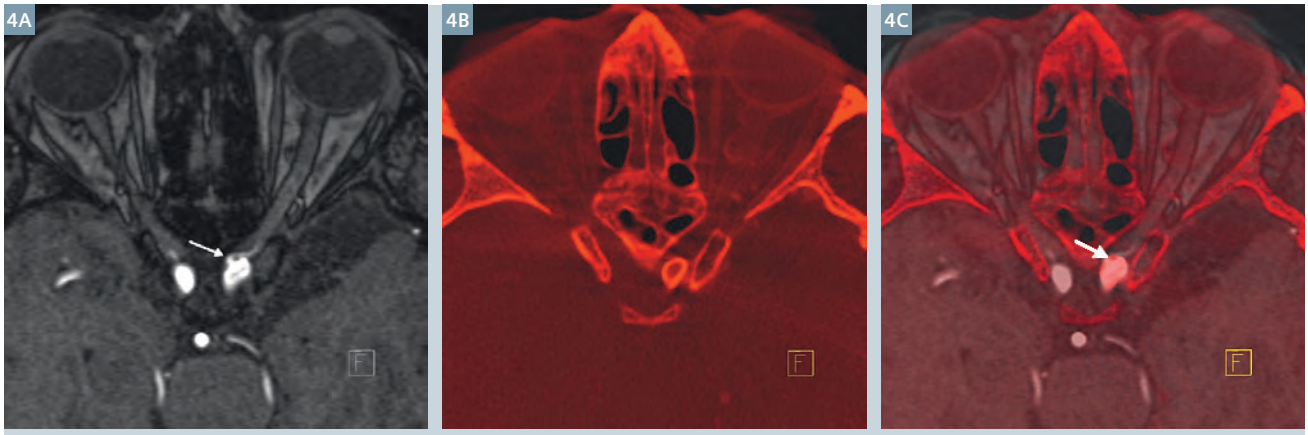

4 The corresponding axial images of pre-treatment Time-of-flight-MR (A) and post-treatment *syngo* DynaCT (B) at the level of caudal edge of the aneurysmal neck. The image obtained by the fusion process with *syngo* InSpace 3D/3D Fusion between the two techniques (C) enhanced the anatomical relationship between the device and the surrounding anatomical structures. Note the excellent visualization of the ophthalmic artery (arrow in A and C), and of the PED, highly radiolucent, fully deployed (B and C).

5 Six-month follow-up DSA shows complete occlusion of the paraophthalmic aneurysm with normal opacification of both the ophthalmic (arrow) and the parent arteries.

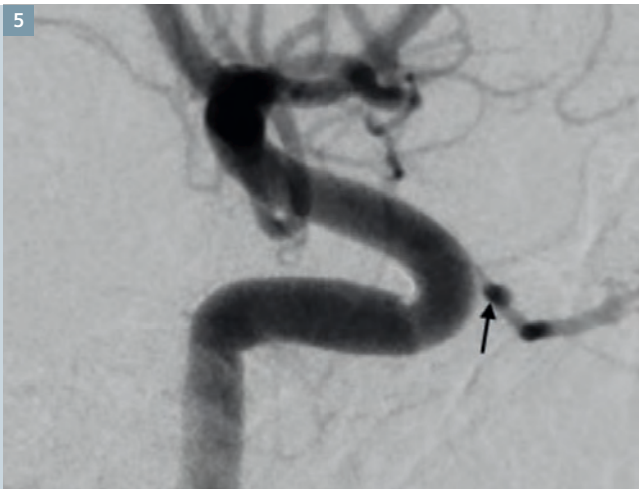

Stent Placement Supported by IVUSmap

Courtesy of Jiro Ando, MD

Department of Cardiovascular Medicine, The University of Tokyo, Tokyo, Japan

Patient History

An 80-year-old male, who suffered from anterior chest pain on exertion in Feb, 2012, was treated via implantation of a drug eluting stent in the left main trunk and the proximal part of the left anterior descending artery.

Diagnosis

Follow-up angiography showed 75% stenosis of the distal right coronary artery 8 months after initial treatment.

Treatment

IVUS catheter (EagleEye® Platinum, Volcano Corp., U.S.A.) was introduced into the distal part of the RCA lesion, and catheter pullback was performed with an automatic pullback device at a rate of 0.5 mm/sec. ECG-triggered fluoroscopy was acquired during pullback and was used to perform co-registration of the angiographic and IVUS images. The IVUS image showed a 11.0 mm stenotic lesion proximal to a branch of the distal RCA (white arrow in Fig. 1). The distal end of the stenosis was 10.0 mm away from the branch. The stent end target landing positions were identified at locations where the amount of plaque was comparatively small. The reference diameters were around 3.1 mm, so a 3.0 mm x 14 mm stent (Nobori®, Terumo Corp., Japan) was selected for treatment. The distal RCA branch was used as a reference landmark point during stent deployment. The stent was placed and subsequent angiography showed that stenosis was resolved.

Comments

Stent placement without the use of IVUSmap requires the physician to switch attention between angiographic images and IVUS images alternately, and to orient within the coronary tree, identify branches and radiopaque markers. Highly developed skills and experience of the physician are required to perform these complex tasks. On the other hand, through IVUSmap, co-registered images useful for guidance can be easily obtained by placing two bookmarks on the distal and proximal ends of the stenosis (Fig. 3). IVUSmap provides an easy approach for length measurements between bookmarks visible on either IVUS or angiography images. Our assessment of the co-registration accuracy suggests that this technology can be used for guidance during stenting. I believe that this technology has the potential to contribute to placing stents more intuitively and accurately.

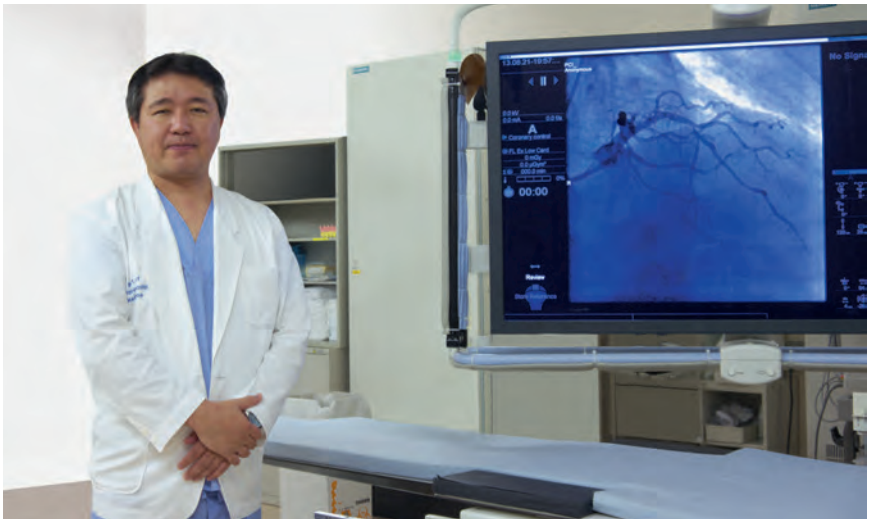

Jiro Ando, MD, in front of his system for cardiovascular treatment.

Contact

ken.shigeta@siemens.com

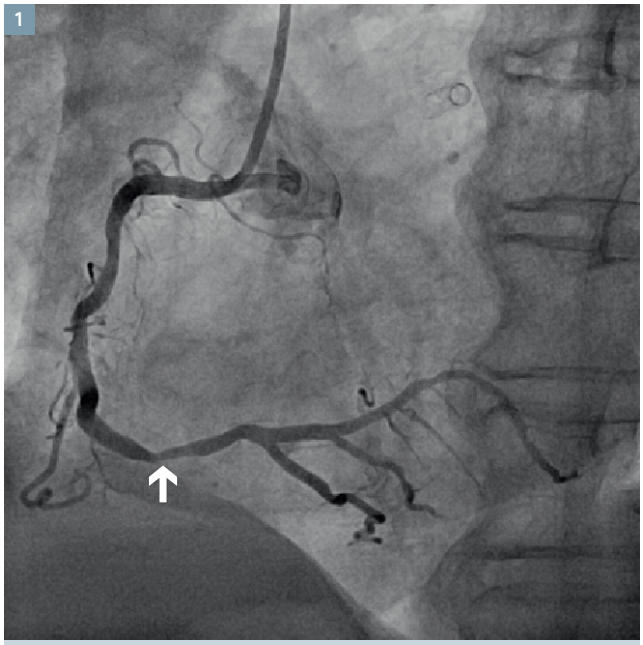

1 Angiography before the stenting, which shows stenosis of the distal right coronary artery (arrow).

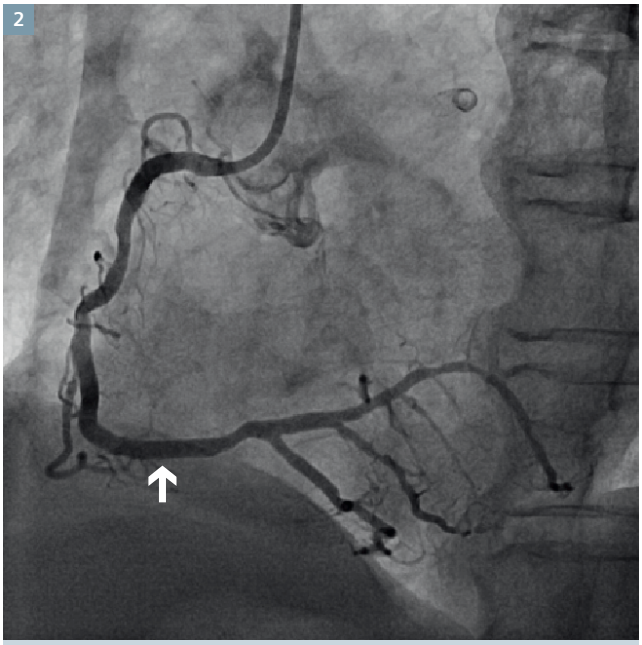

2 Angiography after the stenting, which shows that stenosis was resolved (arrow).

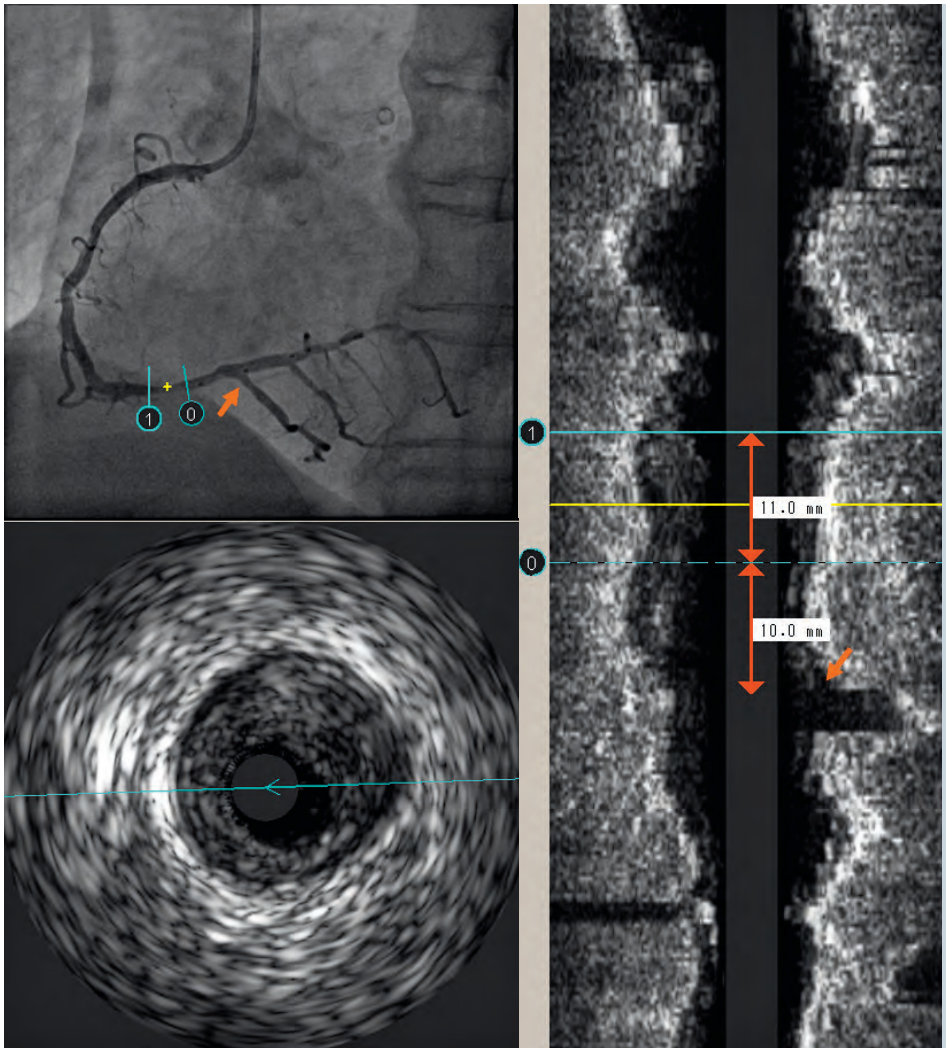

3 Angiography and IVUS images co-registered by IVUSmap. Two bookmarks are placed on the distal and proximal ends of the stenosis. The orange arrows indicate the branch that is visible in both angiography and IVUS images.

Diagnosis of Coronary Artery Disease Supported by FFR

Courtesy of Praveen Chandra, MD, Medanta The Medicity, Gurgaon, India

Clinical angiogram images are considered one of the gold standards in diagnosing coronary artery diseases. Most of the time it allows us to make the right decision during coronary interventions, but in some cases the decision making is bit tough with angiography images. Praveen Chandra, MD, Chairman Division of Interventional Cardiology, Medanta The Medicity, Gurgaon, India frequently uses FFR for decision making to avoid unnecessary angioplasty and bypass surgery in a reasonable number of cases.

"FFR supported us in making the right decision at the right time!"

Praveen Chandra, MD
Division of Interventional Cardiology,
Medanta The Medicity,
Gurgaon, India

In certain situations Fractional Flow Reserve (FFR) is a reliable tool for planning intervention easier and faster for assessing the severity of epicardial stenoses. Especially in situations such as borderline lesions, lesion with a distal vessel having competitive flow from collaterals and some eccentric lesions where in a few shots the lesion looks tighter or wider than reality. It has been shown that it is safe to defer an intervention in a single vessel disease patient when FFR > 0.80.

On many occasions we took critical patients with deranged renal function, (elevated factors like Blood Urea and Creatinine) we reduce contrast load to the patient by cutting to fewer angio shots and decide on severity based on FFR. This cutting edge technology clearly identifies the patient that can be safely treated by medicines alone, and also avoids unnecessary angioplasty and bypass surgery in a reasonable number of cases. FFR is more dependable because FFR determines the ischemic severity of the block, specific to the particular block. It reduces extra procedures and time to wait for results, such as with stress thallium. In dealing with left main cases the decision between PTCA and CABG it helps a lot. Thus FFR supported us in making the right decision at the right time.

The integrated FFR with Sensis Lite[1] is the new tool incorporated in our new lab that simplifies workflow and displays the exact report, which helps us in faster decision making. This integration, unlike the other previous versions of FFR we had in our lab makes the workplace free of various pieces of equipment, allows use of the common user interface of Sensis Lite, fewer cables and less chance of an incorrect connection with improved efficiency. FFR also reduces the number of stents used on the patient thus reduces the risk and cost to the patient. Using FFR has improved the clinical outcome for patients, and deciding in favor of stent implantation is much simpler and evidence based, with better long-term outcomes than seen in other groups of patients.

In MEDANTA we match the highest standards of healthcare delivery worldwide, and were the first in India to use integrated FFR with the Sensis Lite hemodynamic system. Our interventional cardiology team got this technology in an earlier lab as standalone system. We now have integrated FFR along with a recently acquired cath lab with Sensis Lite.

So far our team has used FFR for 315 patients, 414 coronary arterial lesions that were border line in terms of angiographic criteria. In 255 lesions FFR was negative and in 159 lesions FFR was positive. 53 patients had angioplasty deferred in view of non-significant lesions, and in 16 patients CABG was planned instead of PCI in view of significant left main or TVD. A total of 199 stents were saved due to an insignificant lesion. In patients with multi-vessel disease, PCI of hemodynamically non-significant stenosis can be safely deferred, even if initially planned on the basis of the angiogram.

[1] This product is commercially not available in the US.

Contact

harish.gulhar@siemens.com

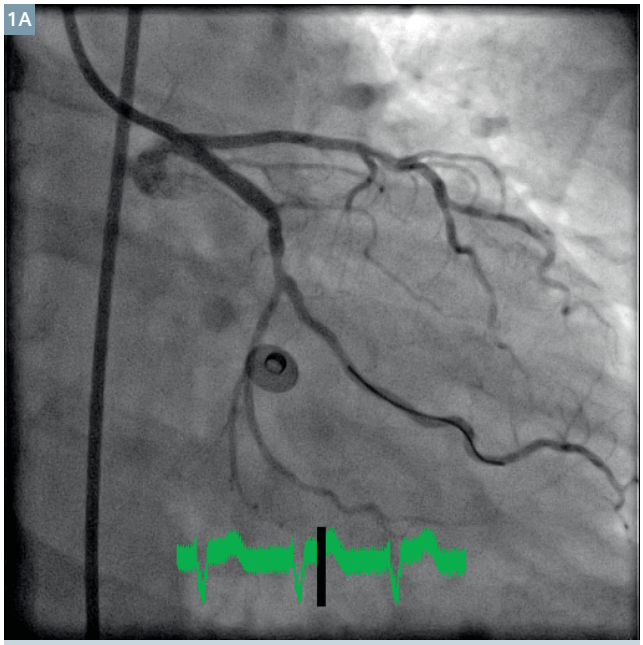

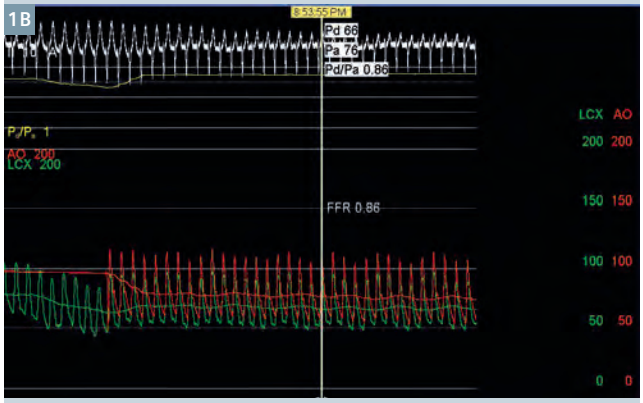

1 Border line lesion of Circumflex: patient referred to medical management.

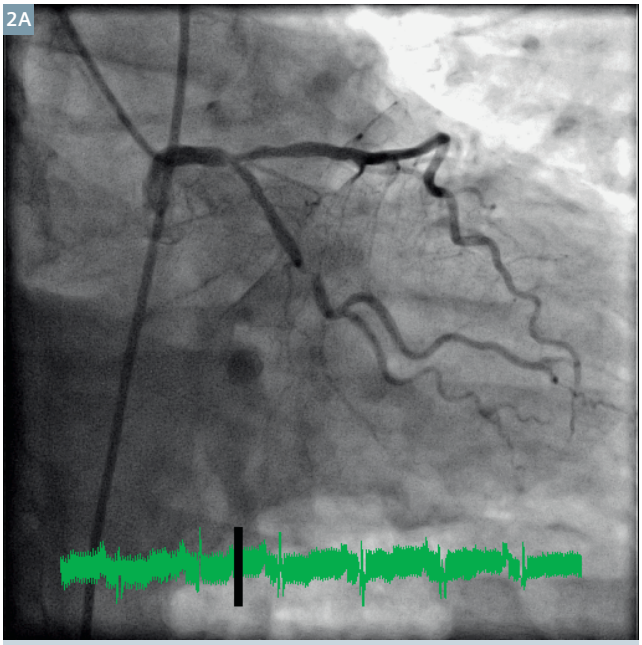

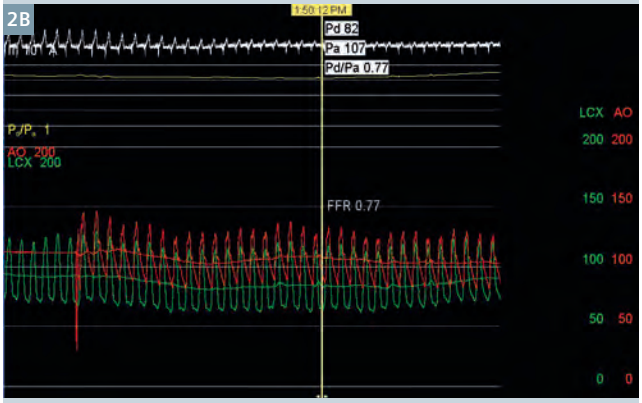

2 Proximal Circumflex artery management with FFR.

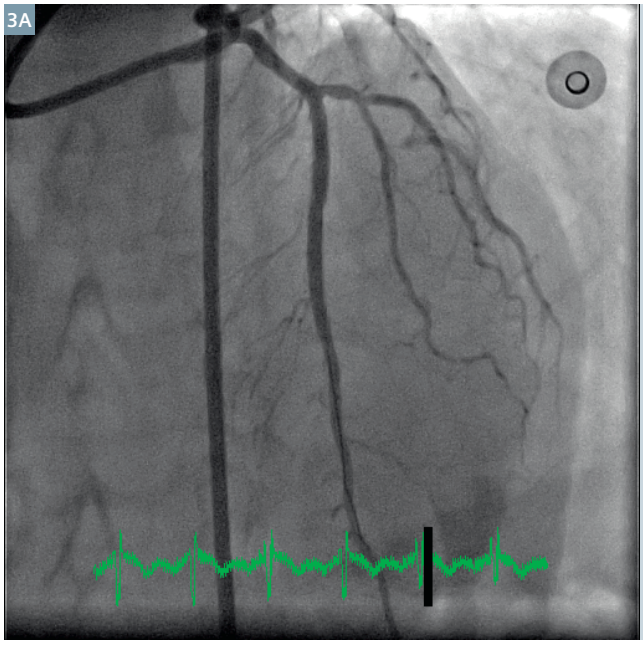

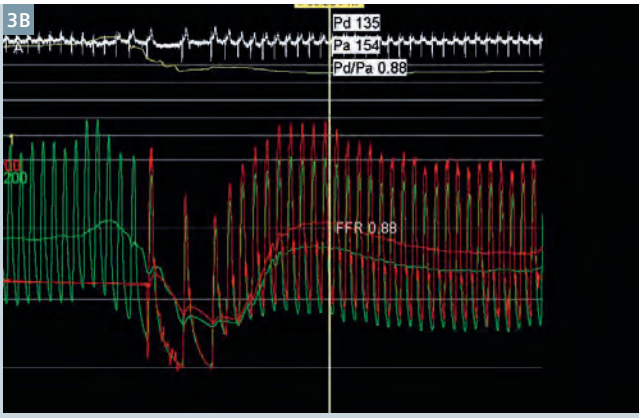

3 LAD Post CTO stenting FFR measurement shows flow restored.

CLEAR Visualization of Stent Placement

Courtesy of Nagendra Chouhan, MD, Medanta The Medicity, Gurgaon, India

Coronary artery disease (CAD) is the most common cause of death worldwide in the general population over the age of 20. Percutaneous coronary intervention is one of the standard treatment options for CAD. With deployment of a metallic stent the constricted coronary arteries can be dilated.

"Heavier patients make imaging more difficult, and increasingly finer struts have made our lives difficult. Additionally, stent structures have become more and more delicate, hence CLEARstent technology comes in handy."

Nagendra Chouhan, MD,
Division of Interventional Cardiology,
Medanta The Medicity,
Gurgaon, India

The long term success and safety of percutaneous interventions to administer CAD depends on accurate positioning of stent and proper apposition of stent struts with vessel wall along with other parameters. Visual assessment with conventional two-dimensional fluoroscopic imaging may be misleading due to poor visualization of the non-deployed rapidly moving stent. The struts of upcoming next generation stents are becoming thinner which make them less radio-opaque and even more difficult to visualize on live fluoroscopic images pre- and post-deployment. Although intravascular ultrasound (IVUS) and optical coherence tomography (OCT), are considered the gold standard for optimizing the result of angioplasty post-stent deployment by allowing endovascular imaging of the vessel and stent interaction, they have certain limitations. IVUS is not only invasive and time consuming, but it also has an impact on catheterization, laboratory efficiency, and cost-effectiveness. The other major limitation of these procedures is that they are only useful after stent deployment and are not helpful in positioning of the stent pre-deployment, especially in cases of overlapping stents where it is imperative to prevent geographic misses.

CLEARstent Comes in Handy

CLEARstent enables the operator to rapidly and precisely assess stent deployment. The visibility of the stent is enhanced automatically. Day-to-day work does not need the luxury of complex detail that OCT offers. Physicians need an easy-to-use tool to assess intervention success. Merely knowing that the stent has opened up correctly and is well opposed to the vessel wall is essential information for the interventionist.

Heavier patients make imaging more difficult, and increasingly finer struts have made our lives difficult. Additionally, stent structures have become more and more delicate, hence CLEARstent technology comes in handy (Fig. 1). Depending on the presence of contrast, CLEARstent either shows the stent enhanced image or automatically toggles between the stent enhanced image, and contrast filled vessel. Automatic region of interest selection ensures the visibility of the entire stent and not just the region in between balloon markers. The CLEARstent dynamic loop between inverted static stent image and best matching frame (with contrast medium) system automatically computes and displays the result (Fig. 2A and 2B).

Optimizing the Placement of Overlapping Stents

A 42-year-old male presented with severe retrosternal pressure which had persisted for the last two hours. His ECG revealed anterior MI. In the course of a primary PCI a thrombus containing a large LAD-diagonal lesion was detected. CLEARstent facilitates the visualization of the stents (Fig. 3) and shows that the first stent needs further post-dilatation. Using TAP technique, CLEARstent helps optimize the placement of the two stents to treat the bifurcation lesion (Fig. 4). The technical challenge of minimal overlap could be easily overcome by using CLEARstent, which enables easy and precise treatment without unnecessary expenses.

"CLEARstent makes our job really easy!"

Contact

harish.gulhar@siemens.com

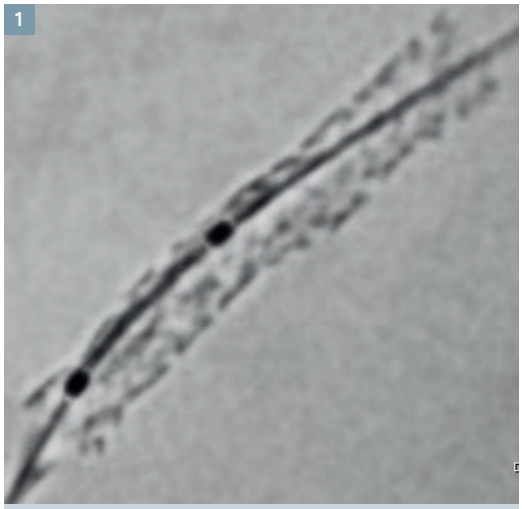

1 CLEARstent for visualization of the finest stent struts.

2 CLEARstent Dynamic: Simultaneous information by looped display of stent (A) and vessel (B) (contrast flow).

3 Shows first stent, which is too narrow.

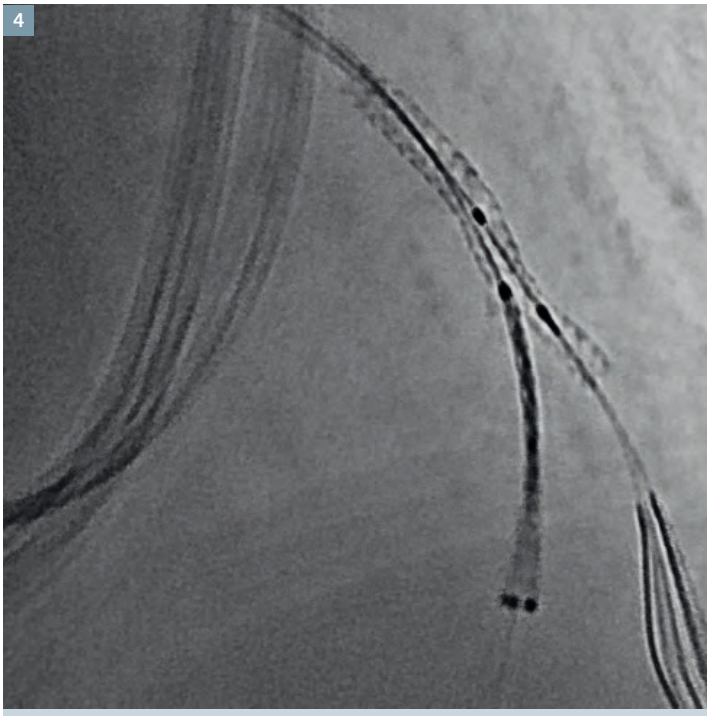

4 The second stent being placed just abutting the first stent.

CLEARstent – A Useful Tool Not Only to Document Stent Expansion

Courtesy of Jaques Berland, MD, and Sami Bouraoui, MD

Cardiology Department, Saint Hilaire Clinic, Rouen, France

Patient History

An 84-year-old patient was hospitalized with chest tightness involving retrosternal pressure upon exertion. 10 years before, the same symptoms had occurred with a coronary angiogram. This showed tight ostial stenosis of the anterior interventricular artery (LAD) and the proximal part of the circumflex artery (LCX). Back then, two stents were implanted, a Cordis Cypher Sirolimus-eluting stent on the proximal LAD, and an ACS Multilink bare metal stent in the proximal part of the LCX.

Diagnosis

The patient underwent a coronary angiogram (Fig. 1) which showed a tight distal stenosis of the left main coronary artery extending into the ostium of the anterior interventricular artery. The circumflex seemed to be unaffected. An angioplasty for the distal lesion of the left main artery was the suggested course of treatment due to the patient's age.

Jaques Berland, MD

1 Left coronary artery seen from RAO 1° / CAU 27° (A) and LAO 58° / CAU 31° (B) showing tight stenosis reaching from left main artery across LCX into LAD

Treatment

The procedure was carried out on an Artis zee floor-mounted angiography system. The therapeutic strategy for this patient mainly depended on good knowledge of the positions of the stents that were implanted around ten years prior. Given that traditional angiographic images make it difficult to accurately view the edges of the implanted stents, it was decided to use the CLEARstent software in order to precisely assess the positions of the old stents in relation to the left main artery.

CLEARstent requires balloon or similar markers to align the individual images of a coronary angiogram for enhancement. As the coronary flow could be compromised by a thick balloon crossing the stenosis, we decided to use a special, thinner ATW guide wire featuring CLEARstent detectable markers at 10 mm intervals and with a diameter of 0.0076 inch.

In addition, the wire would also enable a conventional angioplasty to be carried out (Fig. 2). With the guide wire placed in the anterior interventricular artery (Fig. 3), the CLEARstent images with and without contrast injections first confirm the positioning of the old Cypher stent in the proximal part of the LAD. It protruded about 1 millimeter into the left main artery covering the ostium of the Multilink stent, which was positioned in the circumflex artery. The contrast injection made it possible to assess the extent of calcification which obscured the previously implanted stent in the angiography images (Fig. 3).
We then positioned the ATW guide within the LCX so we could see more accurately the Multilink stent and confirm that it was indeed aligned with the ostium of the circumflex artery and not protruding into the left main artery (Fig. 4).

Guided by this information, we predilated the anterior interventricular artery ostium with a high-pressure 3 mm balloon and also predilated the circumflex artery ostium with a very high-pressure balloon (Fig. 5). A 16x3.5 mm Boston Scientific Taxus Element stent was placed in a crossover position starting in the left main artery and towards the LAD, with a 3 to 4 mm overlap with the old Cypher stent. Positioning was reconfirmed using CLEARstent without contrast injection (Fig. 6). Then the Taxus stent was implanted at 16 atmospheres.

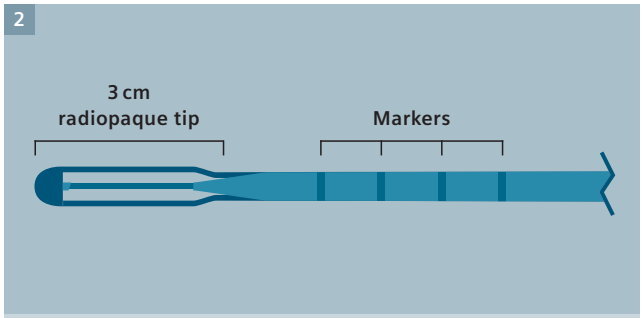

2 ATW Marker Wire.

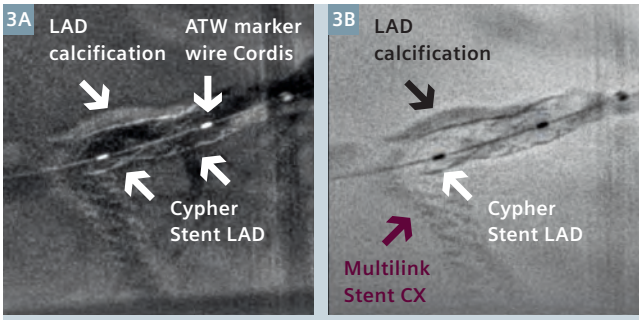

3 CLEARstent Dynamic (A) and CLEARstent (B) enhanced images used for diagnostic overwiev showing the Cordis ATW marker wire and previously implanted stents in LAD and LCX.

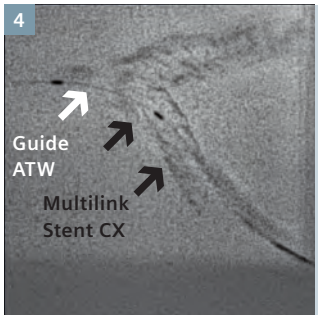

4 Second CLEARstent image shows exact alignment of implanted stent with ostium of circumflex branch.

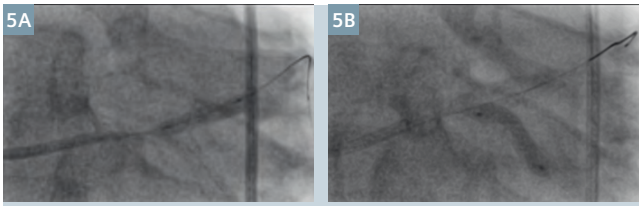

5 Pre-dilatation of LAD (A) and LCX (B).

Full deployment of the stent was achieved by post-dilation using a 8x4 mm non-compliant high-pressure balloon (20 atm), reaching from the left main artery into the LAD. The result was assessed with CLEARstent using the markers of the non-compliant balloon. The resulting image confirmed full deployment of the stent. We also obtained a clear visualization of the two stent layers within the first few millimetres of the anterior interventricular artery (Fig. 7). At the same time, a contrast injection confirmed excellent flow in the circumflex artery, which allowed us to avoid crushing the new stent in order to open it towards the circumflex artery.

The perfect end result was confirmed using conventional angiography (Fig. 8). Six months later, the patient was completely free of angina symptoms.

Comments

CLEARstent was developed in particular to assess the proper deployment of endocoronary prostheses along with their relation to the vessel wall. As demonstrated in this case, the software can furthermore be used to improve visualization of the artery and its wall or other applications, as in our case:

- Viewing the position of stents implanted years earlier, particularly in order to assess the location of any restenosis,
- Assessing the extent of calcification of an artery which may be difficult to see in conventional angiography images,
- Assisting while positioning an undeployed stent, particularly across ostia of the coronary arteries, or into secondary branches for treatment of bifurcations,
- Confirming the position of stents in adjacent to others with a minimum overlap.

Particular dilation guide wire, the Cordis ATW Marker Wire was used. This enabled the treatment with CLEARstend without insertion of a balloon. We can envisage also using this wire with a small-diameter catheter at the time of a diagnostic coronary angiogram procedure.

Compared to other systems (e.g. StentBoost), CLEARstent enables improved viewing of the stents with concurrent contrast opacification. This provides better assessment of the flow through stents, particularly collateral ones, and also facilitates fitting endoprostheses in the most difficult cases (left main artery, bifurcational or ostial lesions), thereby avoiding use of costly endovascular imaging instruments (IVUS and OCT) in the majority of cases.

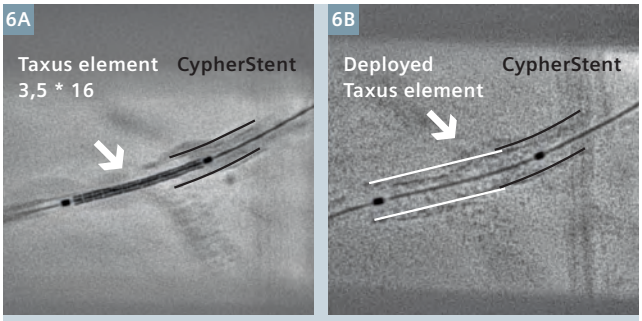

6 CLEARstent used for assessment of stent positioning (A) and stent expansion (B) before and after balloon inflation.

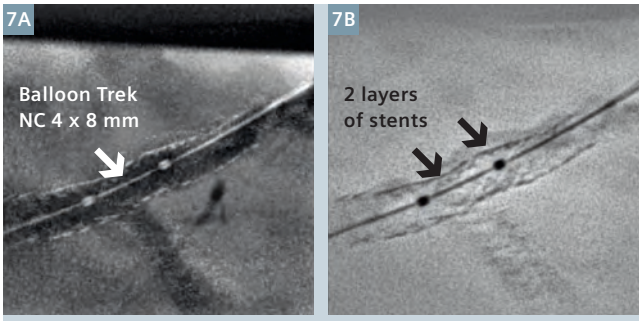

7 After post-dilatation, CLEARstent Dynamic (A) and CLEARstent (B) views confirm the new stent being well apposed to the vessel wall and also show clearly the two layers of stents where overlapping.

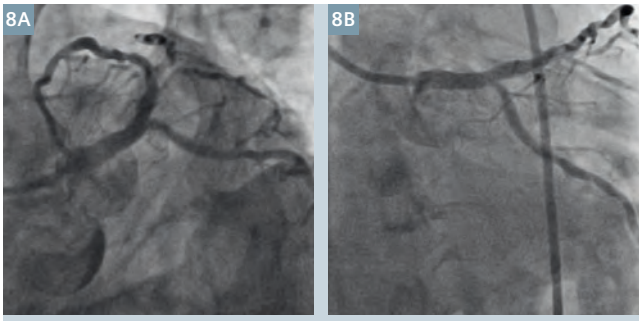

8 Final angiography shows satisfying result and confirm good procedure success.

Contact

hanno.herrmann@siemens.com

MEDTRON® AG

Precision in every detail

Accurate.Reliable.Wireless.

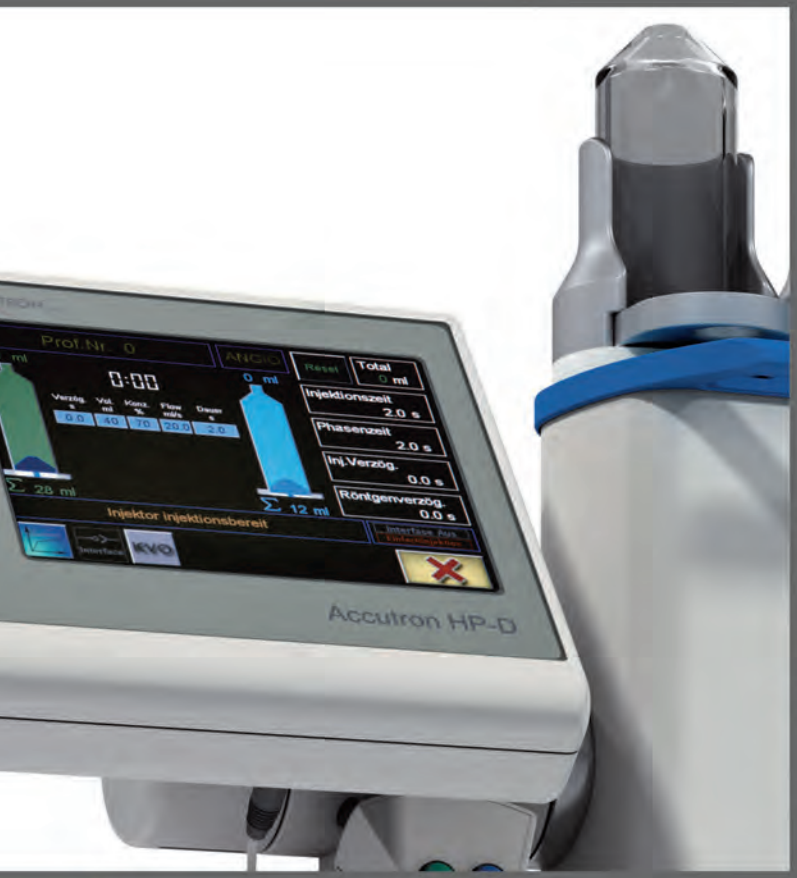

- Wireless synchronisation via interface
- Dual Injection System :
  Simultaneous injection of contrast medium and saline solution:
  - helps to avoid artifacts
  - is patient-friendly
  - reduces costs

Accutron HP-D

the precise multi-talent for angiography

Contrast medium injectors and corresponding consumables

Information & catalogue at: www.medtron.com

Interventional Left Atrial Appendage Closure Supported by *syngo* DynaCT Cardiac

Courtesy of Markus Füller, MD, Georg von Bodman, MD, and Michael Block, MD

Klinik Augustinum, Department of Cardiology, Munich, Germany

Patient History

A 82-year-old male patient presented with recurrent large subcutaneous hematomas and suffusion bleeding under oral anticoagulation with phenprocoumon and additional steroid therapy for treatment of polymyalgia rheumatica. Oral anticoagulation was required for persistent atrial fibrillation with a CHA_2DS_2-VASc-Score of five points. The patient had undergone aortocoronary bypass grafting 20 years ago and had had a cerebrovascular transient ischemic attack two months before.

Diagnosis

The patient was referred for interventional left atrial appendage (LAA) closure. Preprocedural evaluation using transesophageal echocardiography (TEE) demonstrated suitable anatomic characteristics of the patient's LAA (Fig. 1).

Markus Füller, MD

Treatment

Interventional LAA closure with the Watchman device (Boston Scientific) was performed under conscious sedation using TEE guidance. After transseptal puncture of the atrial septum an Amplatz Extra Stiff-wire was inserted into the left upper pulmonary vein and the Watchman access system was introduced into the left atrium. Then a 5F pigtail catheter was advanced and positioned in proximity to the LAA ostium. After additional insertion of a transvenous temporary pacing lead into the right ventricular apex, rotational angiography (RA) was performed under rapid ventricular pacing with a rate of 200 beats per minute. During a breath-hold maneuver 65 cc of a mixture of 46% contrast medium (iodine concentration 350 mg/cc) and 56% saline was injected at a rate of 15 cc/sec. with the start of the 200° C-arm rotation 2 seconds after beginning of contrast medium injection (Fig. 2).

The three dimensional dataset was reconstructed using *syngo* DynaCT Cardiac and the segmented model of the LAA was shown as an overlay on the live fluoroscopy image using *syngo* iPilot enhanced (Fig. 3). Evaluation of these overlay images revealed that the LAA ostium could be best visualized in orthogonal planes by fluoroscopy in a RAO 21°, caudal 20° and a LAO 104°, caudal 6° angulation. Implantation of a 24 mm Watchman device was performed using standard technique. Evaluation of the device after implantation showed adequate device compression, minimal protrusion into the left atrium, complete seal of the LAA and stable position during the tug test (Fig. 4 and 5).

After interventional LAA closure the patient was under dual antiplatelet therapy with Aspirin and Clopidogrel for six months. Since TEE examination after six months showed a favourable result of the Watchman device, clopidogrel therapy then could be discontinued and the patient remained under therapy with aspirin. Under this medical regimen no further bleeding events occurred.

Comments

Recent interest has focused on the left atrial appendage (LAA) as a potential source of thromboembolism and stroke in patients with atrial fibrillation, which may be amenable to permanent occlusion by catheter delivered devices. Interventional LAA closure is usually performed under guidance with TEE and conventional fluoroscopy. Precise anatomic characterization and visualization of the LAA are necessary for proper device selection, sizing, and implantation.

TEE is the primary imaging modality for interventional LAA closure; nevertheless, image quality can be impaired and TEE cannot provide a clear three dimensional visualization of LAA anatomy. The supplementary use of intra-procedural 3D imaging using *syngo* DynaCT Cardiac has the potential to save additional contrast medium, facilitate and accelerate the procedure, and helps to make the treatment safer.

Contact

hanno.herrmann@siemens.com

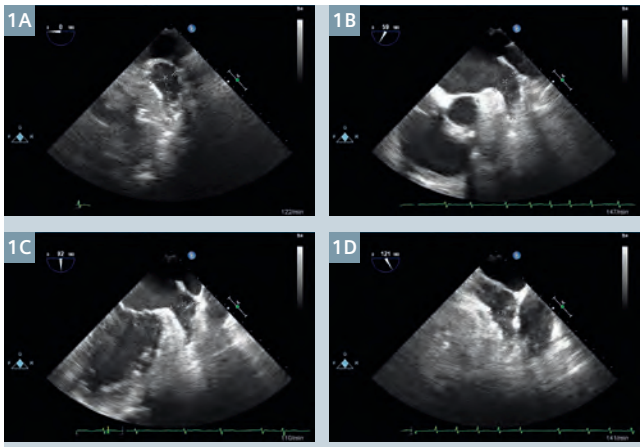

1 Preprocedural TEE showing the left atrial appendage in 0° (A), 59° (B), 92° (C) and 121° (D) views. LAA ostium diameter was 19.2 – 21.0 mm, LAA length was 28.5 – 35.6 mm.

2 Rotational angiography of the left atrium showing LA (1), LAA (2), Watchman access sheath (3) and temporary pacing lead (4).

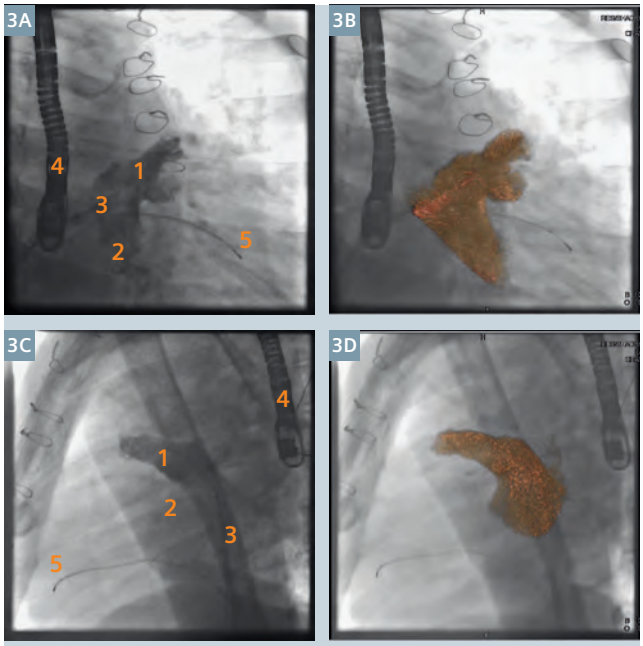

3 Fluoroscopic images of angiographies of the LAA in a RAO 21°, caudal 20° (A) and a LAO 104°, caudal 6° view (C). Corresponding overlay images (B and D) of three dimensional LAA reconstructions and fluoroscopy images using *syngo* iPilot. 1: LAA; 2: Left atrium; 3: Watchman access sheath; 4: TEE probe; 5: Temporary pacing lead.

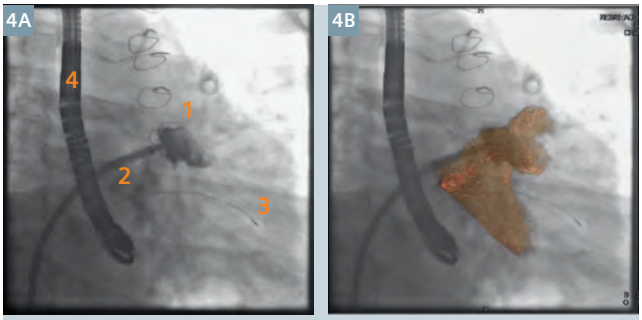

4 Fluoroscopy (A) and overlay image (B) showing Watchman device after device deployment in a RAO 21°, caudal 21° view. 1: Watchman device; 2: Assembly of access sheath and device delivery system; 3: Temporary pacemaker lead; 4: TEE probe.

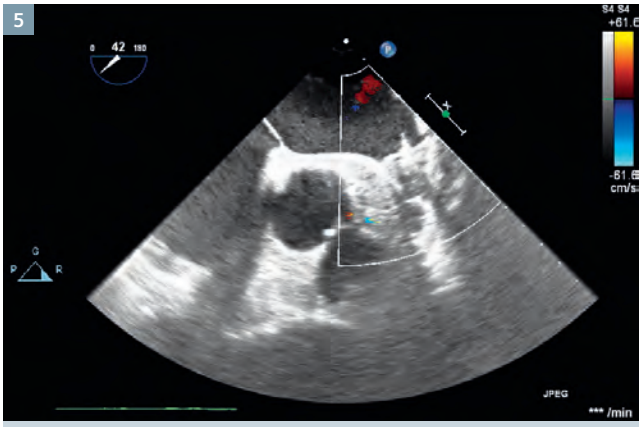

5 TEE showing the Watchman device in its final position in a 42° view.

Tako-Tsubo Syndrome with Cardiogenic Shock and Left Ventricular Outflow Tract Obstruction

Courtesy of Roberto Martín-Reyes, MD

Department of Cardiology, Fundación Jiménez Díaz, Madrid, Spain

Patient History

An 83-year-old hypertensive woman arrived in our emergency room complaining of acute chest pain and dyspnea, after a physical and psychologically stressful event. Her past medical history was otherwise irrelevant.

Diagnosis

On physical examination blood pressure was 100/60 mmHg, pulse rate 64 bpm, a 3/6 apical systolic murmur was heard, and there were signs of peripheral hypo-perfusion. Fluid therapy with intravenous saline was initially administered. The 12-lead electrocardiogram exhibited sinus rhythm with minor ST-segment elevation in V1-V2 without additional significant repolarization changes. The chest X-ray showed signs of alveolar edema without cardiomegaly. The cTnI was 8.11 ng/cc [normal <0.012], NT-proBNP 18.300 pg/cc [normal <900 for this age], and D-Dimer 4452 mcg/l [normal <494]. A multislice CT scan study excluded an aortic dissection and a pulmonary embolism.

Treatment

Shortly after admission, the patient became very dyspneic, cyanotic, and stuporous, with oxygen desaturation and hypotension (80/40 mmHg) despite IV fluid therapy. Orotracheal intubation was performed and dopamine infusion was immediately started. A transthoracic echocardiogram showed an extensive apical akinesia with a left ventricular ejection fraction (LVEF) around 20% and mild mitral regurgitation. Because of the hemodynamic instability a Swan-Ganz catheter was inserted in the pulmonary artery. The systolic right ventricular and pulmonary artery pressures were 44 mmHg, the mean pulmonary artery wedge pressure 25 mmHg, and the cardiac index 1.7 L/min/m², thus confirming the diagnosis of cardiogenic shock.

An urgent coronary angiography disclosed no significant coronary stenosis. The angiographic LVEF was 35% and there was a wide akinesia of the mid and apical segments of the LV, with hyperkinesia of the basal areas and moderate mitral regurgitation (Fig. 1A and B). The mid-segment of the left anterior descending coronary artery showed systolic milking and also the first and second septal branches collapsed during systole (Fig. 1C and D). At the apical LV the systolic pressure was 160 mmHg and the end-diastolic pressure 28 mmHg. On withdrawing the catheter there was an intermediate LV chamber with systolic pressures of 110 mmHg, similar to those obtained within the ascending aorta (110/60 mmHg) (Fig. 2). A peak-to-peak systolic gradient of 50 mmHg existed between the apical LV and the ascending aorta or the intermediate LV chamber.

Thus, we found a systolic gradient at the level of the mid LV cavity without any significant gradient across the aortic valve. Because of these findings the dopamine infusion was withdrawn resulting in an increase of the arterial pressure and an improvement of the peripheral perfusion. IV metoprolol was started further resulting in a significant clinical and hemodynamic improvement (cardiac index 2.1 L/min/m² and pulmonary artery wedge pressure 20 mmHg). Forty eight hours later the patient was extubated and transferred to the cardiology ward without signs of heart failure.

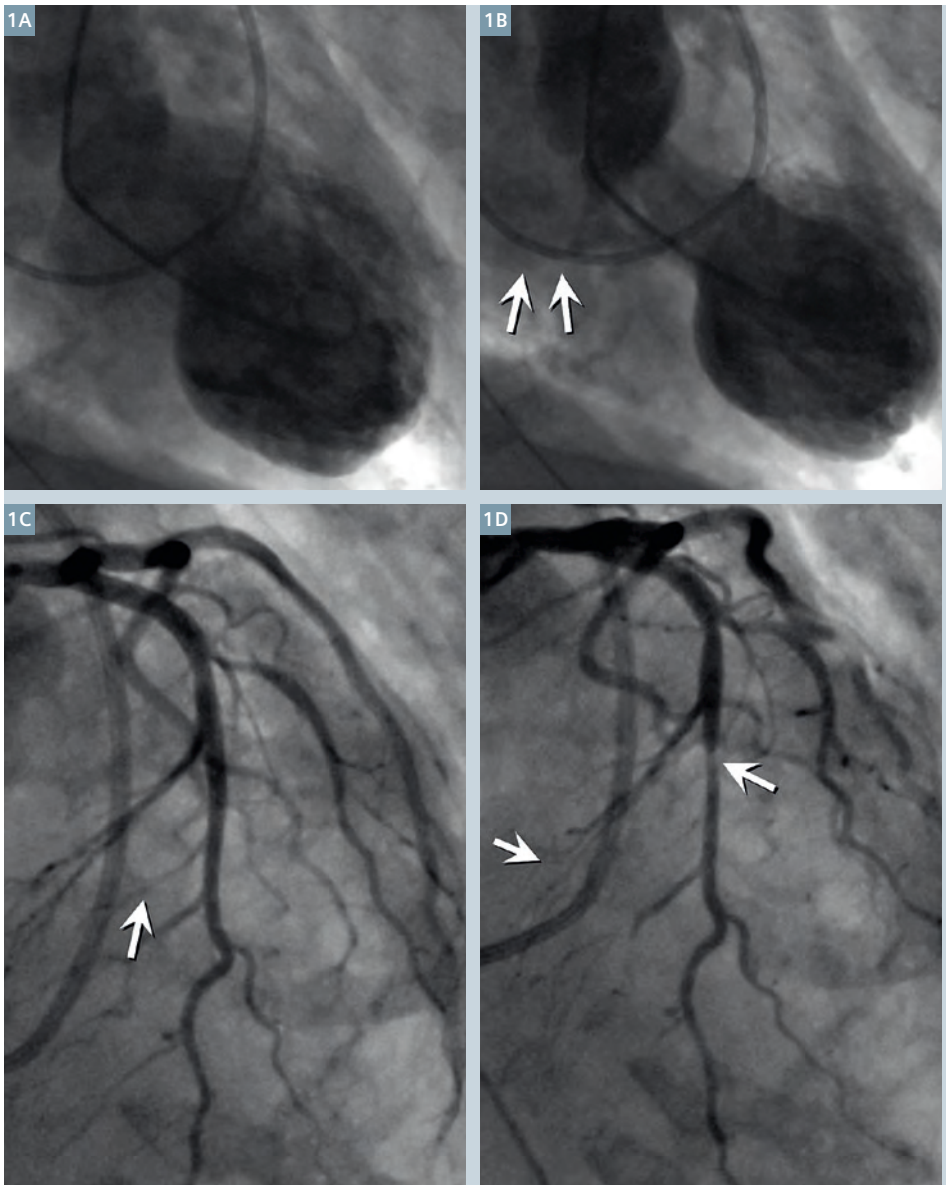

1 Left ventriculograms showing apical ballooning with basal hyperdynamic contraction: end-systole (A) and end-diastole (B). Arrows mark the left atrial margins depicted because of the presence of mitral regurgitation.

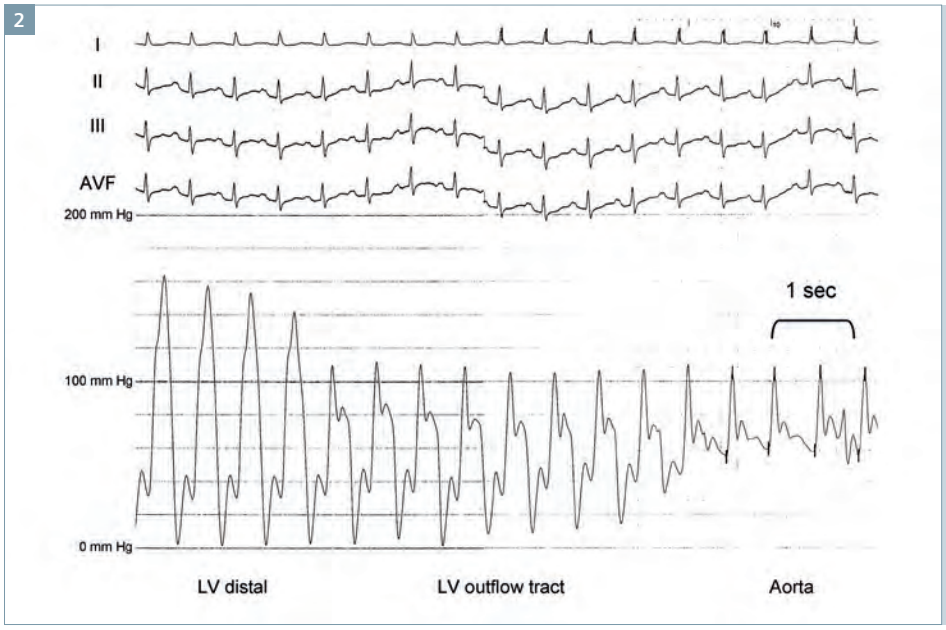

2 Pull-back pressure recordings obtained at the apical region and outflow tract of the left ventricle, and the ascending aorta. A gradient of 50 mmHg existed between the distal left ventricle and the outflow tract, without significant transaortic valve gradient.

Seven days after admission, an echocardiogram showed persistent apical akinesia, no LV outflow tract obstruction (Fig. 3A), a LVEF of 40%, and mild mitral regurgitation. The septum presented a sigmoid morphology with a septal thickness of 12.5 mm (Fig. 3B). The patient was discharged home on bisoprolol, spironolactone, lisinopril, and simvastatin.

One month later, the echocardiogram showed normal LVEF without regional motion abnormalities. A cardiac MRI performed at that time confirmed a normal LVEF, a sigmoid septum with a septal bulge of 13 mm (Fig. 3C and 3D) without subaortic LV obstruction or significant mitral regurgitation, and absence of late gadolinium enhancement.

Comments

In this patient with Tako-tsubo (TT) syndrome and mid LV obstruction leading to cardiogenic shock and acute pulmonary edema, we document for the first time and to the best of our knowledge, the intraventricular gradient with the recording of pressures within the apical LV, the intermediate LV chamber, and the aorta. In addition, we report for the first time the systolic collapse of septal branches in a TT syndrome with dynamic subaortic obstruction.

The presence of mid LV obstruction in TT has been detected in some 20% of the patients with this syndrome [1]. The relation between cardiogenic shock and subaortic LV obstruction is not well established in the literature. In the series of 32 TT patients reported on by El Mahmoud et al. there was mid LV obstruction in eight cases, two of whom had cardiogenic shock [2]. It is tempting to suggest that in patients with TT syndrome and severe systolic LV dysfunction, the presence of subaortic obstruction adds an important hemodynamic burden that may lead to cardiogenic shock [3].

A "sigmoid septum" has been previously linked to the development of LV outflow tract obstruction in patients with TT syndrome. Thus, in the study by El Mahmoud et al. all their cases with LV obstruction had a sigmoid septum, a finding only encountered in 29% of the patients without obstruction. Our patient had a sigmoid septum of 13 mm in the MRI study. In addition, our patient showed milking of the left anterior descending coronary artery and systolic collapse of the proximal septal branches reflecting a hypercontractile state of the basal left ventricle under the influence of endogenous and, in our case, exogenous, cathecholamines. The hemodynamic situation in our patient was worsened by the infusion of dopamine which increased the LV gradient, and most likely the severity of mitral regurgitation.

The initial echocardiographic study did not identify the presence of LV outflow tract obstruction and the diagnosis of TT was not suspected. The coronariographic study demonstrating normal coronary arteries, myocardial bridging in the mid segment of the left anterior coronary artery, and the mid ventricular gradient was crucial to establish not only the diagnosis, but also to correct the wrong therapeutic approach. Treatment in patients with TT syndrome and cardiogenic shock or pulmonary edema in the very acute stages includes the avoidance of cathecholamines and vasodilating agents, and the use of beta-blockers [4,5]. Verapamil, a drug that can reduce dynamic gradients in hypertrophic cardiomyopathy, should be avoided in the setting of TT syndrome because of the depressed LVEF and the frequently high LV end-diastolic pressures. Norepinephrine that increases afterload could be an option in patients with significant hypotension. Fluid therapy must be handled carefully in these patients who characteristically have very high LV filling pressures and in whom the shock state does not depend on a hypovolemic situation. IABP and extracorporeal cardiopulmonary support have been used in anecdotal cases [6].

While in our case the mid LV gradient was not observed at the time of the initial echocardiographic study in which severe LV systolic dysfunction and heart failure with shock were present, the subaortic gradient would have been documented if a repeat echocardiogram had been obtained after initiating the infusion of dopamine. This was not done so the correct diagnosis was delayed until the cardiac catheterization was performed. The lesson to take home is that the combination of shock and TT syndrome is a deadly tramp if dopamine infusion is used for hemodynamic support. TT syndrome is seldom suspected in an emergency room, and under a marked hemodynamic impairment with severe systolic LV dysfunction, the use of dopamine support is understandable. When a TT syndrome is present, dopamine may further deteriorate the clinical situation through the creation of a subaortic dynamic gradient.

[1] Chockalingam A, Tejwani L, Aggarwal K, Dellsperger KC. Dynamic left ventricular outflow tract obstruction in acute myocardial infarction with shock: cause, effect, and coincidence. Circulation. 2007 Jul 31;116(5):e110-3.

[2] El Mahmoud R, Mansencal N, Pilliére R, Leyer F, Abbou N, Michaud P, Nallet O, Digne F, Lacombe P, Cattan S, Dubourg O. Prevalence and characteristics of left ventricular outflow tract obstruction in Tako-Tsubo syndrome. Am Heart J. 2008 Sep;156(3):543-8.

[3] Brunetti ND, Ieva R, Rossi G, Barone N, De Gennaro L, Pellegrino PL, Mavilio G, Cuculo A, Di Biase M. Ventricular outflow tract obstruction, systolic anterior motion and acute mitral regurgitation in Tako-Tsubo syndrome. Int J Cardiol. 2008 Jul 21;127(3):e152-7

[4] Yoshioka T, Hashimoto A, Tsuchihashi K, Nagao K, Kyuma M, Ooiwa H, Nozawa A, Shimoshige S, Eguchi M, Wakabayashi T, Yuda S, Hase M, Nakata T, Shimamoto K. Clinical implications of midventricular obstruction and intravenous propranolol use in transient left ventricular apical ballooning (Tako-tsubo cardiomyopathy). Am Heart J. 2008 Mar;155(3):526.e1-7.

[5] Kyuma M, Tsuchihashi K, Shinshi Y, et al. Effect of intravenous propranolol on left ventricular apical ballooning without coronary artery stenosis (ampulla cardiomyopathy): Three cases. Circ J 2002;66:1181-4.

[6] Bonacchi M, Maiani M, Harmelin G, Sani G. Intractable cardiogenic shock in stress cardiomyopathy with left ventricular outflow tract obstruction: is extra-corporeal life support the best treatment?. Eur J Heart Fail. 2009 Jul;11(7):721-7.

Contact

nuria.barron@siemens.com

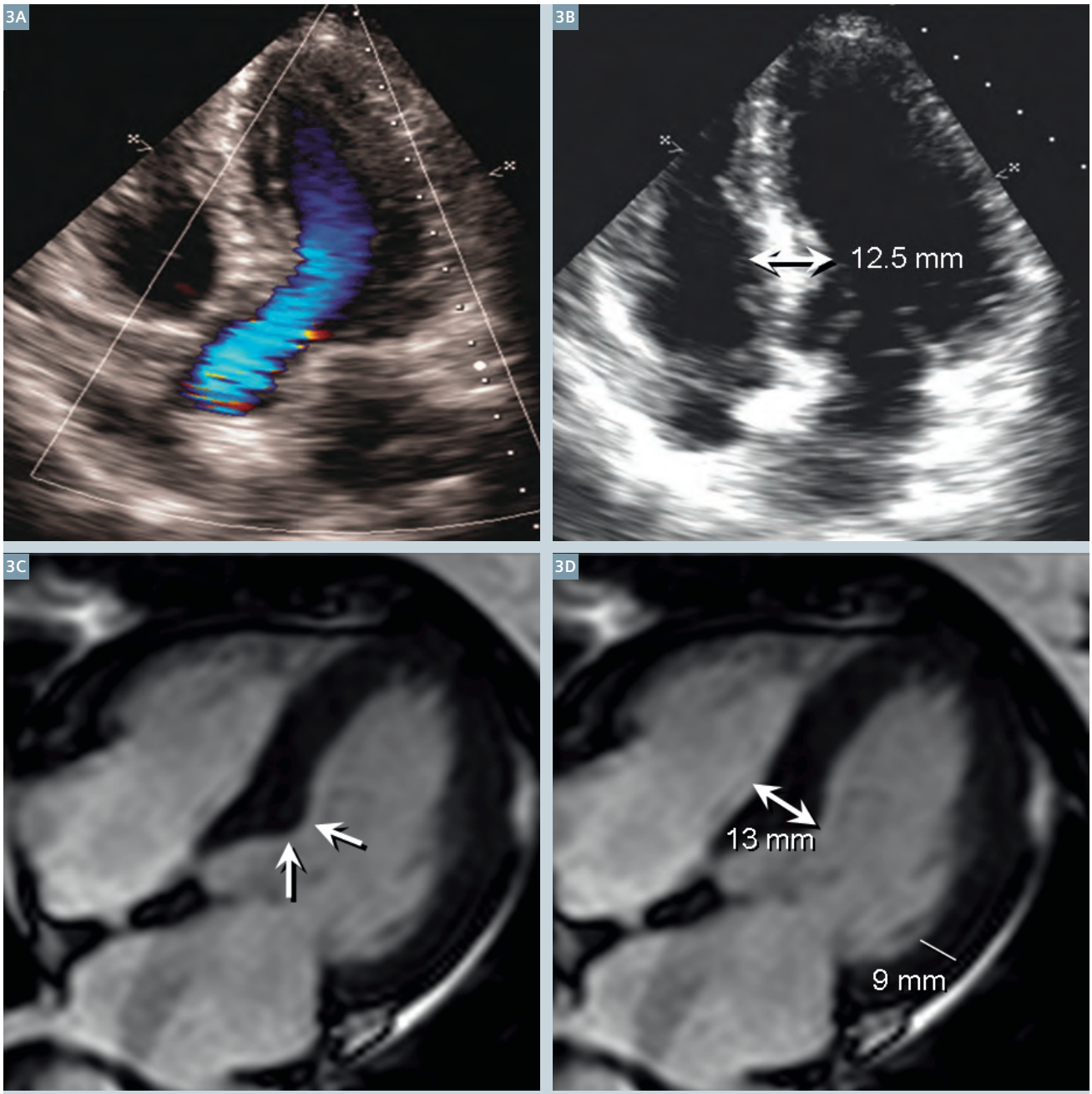

3 Transthoracic echocardiogram (five chambers view) obtained one month after hospital discharge, showing normal flow without subaortic LV obstruction or significant mitral regurgitation (A). Note the sigmoid septum (B). Cardiac MRI study showing the septal bulge (C) 13 mm thick (D).

How Integrated Fluoro View Can Help

CartoUnivu™ is a new software module that has the potential to reduce exposure times during electrophysiological interventions. The software combines registered and corresponding fluoro images of the heart with the electroanatomical map of the Carto® 3 system. These single integrated views display the catheter's real-time position. Isabel Deisenhofer, MD, from the German Heart Center Munich describes her experiences with the new software.

By Hildegard Kaulen, PhD

"Biosense Webster has no independent knowledge concerning the information contained in this article and finding and conclusions expressed are those reached by the author."

1 Registration screen of the Carto® 3 System with CartoUnivu™ Module showing the registration fluoroscopy image. The Siemens Artis angiography system sends acquired images to the Carto® 3 system including the exact table position and current angulation of the C-arm.

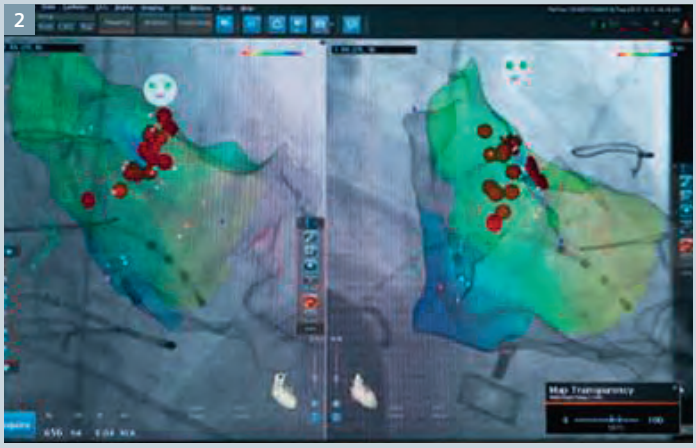

2 Intergrated fluoroscopic image of the chest and 3D reconstruction of the LV. Two planes (AP on the left and RAO 45° on the right) are juxtaposed side-by-side and visualized with a reconstructed 3D overlay map of the LV. The red markers highlight ablation targets in the left ventricular outflow tract region that were applied to eliminate ventricular tachycardia.

Fluoroscopy provides a precise image of reality. In the electrophysiology laboratory, it tracks the exact position of the cardiac catheter in real time. However, this precision comes at a price in the form of the accompanying exposure. Additionally, low levels of confidence entrap users to step more often on fluoro; with the result that radiation load is higher for everyone in the EP lab: patients, doctors, and staff alike.

CartoUnivu™ Module combined with Artis system are now helping physicians resort less frequently to the knee-jerk reaction of yet another fluoroscopic shot, thereby reducing exposure times. The software module combines fluoro images and the Carto® 3 System 3D map into a single, integrated view. With the familiar fluoroscopy in the background, users intuitively develop greater confidence in the electroanatomical 3D map of the heart. They currently see both images on separate screens and have to combine them in their mind's eye. CartoUnivu™ Module now does this for them.

Reducing Unnecessary Radiation Load

Developed by Biosense Webster[Inc.], the software stores selected fluoro images taken during the intervention and projects them behind the Carto® 3 System map as fixed images. Cine sequences can also be displayed. If the 3D model is rotated during the intervention as another angle is required, the corresponding X-ray image is also visualized behind the map if available. The software package can be installed in all Siemens angiography systems released since 2006 without additional upgrades or costs, thereby allowing earlier system generations to be equipped with this state-of-the-art technology. As a result, Siemens offers its clients optimal flexibility – also as far as the installation of other navigation systems is concerned. A wide range of interfaces can be implemented.

Initial Experiences in Munich

Dr. Isabel Deisenhofer has tested CartoUnivu™ Module. The cardiologist

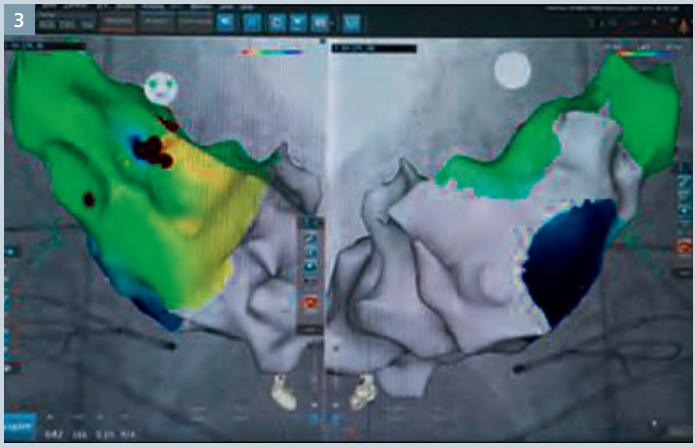

3 As in figure 2, the chest fluoroscopic image and the 3D map of the LV are integrated, but the 3D map is shown in a solid (non-transparent) mode. The CartoUnivu™ Module can display "180° turned" views of any projection recorded as well, providing completely new fluoroscopic views at the heart.

is one of just a few women active in the field of interventional electrophysiology. Her training includes periods under the tutelage of Prof. Dr. Michel Haissaguerre at the University Hospital in Bordeaux, one of the leading specialists in the field. Dr. Deisenhofer heads the Department of Electrophysiology at the German Heart Center Munich. There, 1,200 catheter ablations are performed in adults and 140 in children each year. The Munich Heart Center's consolidated approach is one of its particular strengths, with all age groups and cardiac diseases treated under one roof. Said Dr. Deisenhofer: "Many patients present with complex arrhythmias and complex comorbidities. Tomorrow we will ablate an 86-year-old patient with recurrent ventricular tachycardia despite medical therapy who was rejected by another institution." Dr. Deisenhofer has performed 40 ablations using CartoUnivu™ Module in the past six weeks.

Plaything or Added-Value Product

Is the software simply a fancy gimmick, or does it deliver genuine added value? "Added value is certainly discernible," said Dr. Deisenhofer. "Exposure times are reduced significantly. Although all you do is display an additional fixed image and quickly forget that the fluoro image may have been generated a while back and is no longer up to date, the integration with the Carto® map creates the illusion of a real-time image. Together with other information like the ECG, which is derived directly from the heart, you gain confidence and are less tempted to step on fluoro in order to assure yourself of the catheter's current position," Dr. Deisenhofer continued. "I always scrutinize innovations extremely carefully. But this software really is very useful." Both C-arm and magnetic field must be registered in order to allow the fluoro images to be integrated into the Carto® 3 System map. Dr. Deisenhofer does this after the transseptal puncture, subsequently transferring and saving four acquisition projections in CartoUnivu™ Module namely: AP, LAO 45°, RAO 45°, and left lateral.

She uses only these projections during the remainder of the intervention. The new software turns the images as desired, transforming an AP projection into a PA projection, for example. It can also juxtapose two radiographic planes, as in a biplane view or it can make the electroanatomical map of the heart appear transparent against the background of the fluoro image. "You learn to rely on these integrated views quite intuitively, using them almost incidentally, like power steering," commented Dr. Deisenhofer. "With the new software, you maneuver your way through the heart more easily and safely, only realizing later on that this new-found security is due to the integration of both views," said the electrophysiologist. "I am convinced that users won't wish to forego its benefits once they've grown accustomed to it."

No Complications, No Additional Costs

The intelligent integration of the 3D map with the corresponding fluoro image supports the catheter's intuitive navigation in the heart. What are the clinical results of its 40 consecutive cases? "We haven't yet completed the evaluation process," commented Dr. Deisenhofer, "so I can only provide a rough estimate. We anticipate that the exposure will be reduced by at least 50 percent. According to the fluoroscopy time and experience of an operator, he or she will be able to reduce the personal fluoroscopy time to probably half of the values. I expect this effect to be present for operators of all levels of experience." Dr. Deisenhofer is not counting on it to save her time during interventions. The steep learning curve resulting from the software's introduction pays off, as the integration of two technologies that were previously used in parallel blends seamlessly into clinical workflows. Another benefit: apart from the software's acquisition, no other outlay is incurred. Dr. Deisenhofer deems the static nature of both map and fluoro image a possible limitation, as the heart's pumping motion is not visible. The spatial stability could also prove problematic, although Dr. Deisenhofer has not observed any major deviations.

Will the Profession Become More Appealing to Women?

Will more women be attracted to the field of interventional electrophysiology if radiation load decreases? "That may well be the case," said the electrophysiologist. "Many women are afraid of the exposure. I take a more relaxed approach, and also had positive role models. I know women who continued to ablate during their pregnancies after taking appropriate precautions. I did the same during mine."

Although EP is still a male dominated discipline, with new methods to help reduce radiation exposure, it should become more attractive for women. The EPIC Alliance, of which Dr. Deisenhofer and one hundred other female electrophysiologists are members, aims to attract more women to the specialty, supporting and promoting them via the network. In the long term, medicine just cannot afford to dispense with female talents in the field of electrophysiology.

Dr. Hildegard Kaulen is a molecular biologist. After stints at the Rockefeller University in New York and the Harvard Medical School in Boston, she moved to the field of freelance science journalism in the mid-1990s and contributes to numerous reputable daily newspapers and scientific journals.

Contact

dietrich.till@siemens.com

EHC Global Forum in Collaboration with Siemens for a Humanitarian Purpose in Aswan

Courtesy of Ahmed ElGuindy, MSc, MRCP, Division of Cardiology, Aswan Heart Centre, Aswan, Egypt,
Magdi Yacoub, FRS, Harefield Heart Science Centre, National Heart and Lung Institute, Imperial College London, UK,
and **Roberto Ferrari, PhD,** European Heart for Children Global Forum, Italy

Like many Egyptian cities, Aswan has many attractions for the enjoyment of tourists, but there is more to life in Aswan. For the majority of the local population, life is a struggle against poverty. This is particularly the case for those families who have children suffering from congenital heart disease. Until recently they did not have access to the necessary treatment that would give their children a healthy future, but in April 2013, a collaboration changed all of this.

The mission of the center:

1. Offering state-of-the-art medical services to the Egyptian people, particularly the underprivileged and vulnerable age-groups. All services are free of charge.

2. Training a generation of young Egyptian doctors, nurses, and scientists at the highest international standards.

3. Advancing basic science and applied research as an integral component of the program and promoting biomedical research in Egypt.

The second phase of the Aswan Heart Centre (AHC) from Magdi Yacoub Foundation (MYF), together with the Chain of Hope and the European Heart for Children Global Forum, has officially opened. The modern state-of-the-art Heart Center offers adults with CV diseases and children with CHD treatment, all free of charge. The AHC is a compact, four-floor building that meets the highest international standards and offers all the subspecialties in cardiology such as cardiovascular imaging suite interacting echo, fully upgraded cardiac cath labs, and cardiac surgery rooms. Furthermore there is a pediatric intensive care unit and new outpatient clinic that preserves the dignity of the patients and their family members, while at the same time offering them the necessary comfort.

11,000 patients have been examined in the outpatient clinic. 1,326 cardiac catheterizations and 783 open heart procedures have been performed, of which 40% were pediatric procedures. Here we describe a case of a myocardial bridge in a young adult with hypertrophic cardiomyopathy: using coronary pressure measurements to guide decision-making.

Patient History

A 24-year-old female presented with a two year history of progressive shortness of breath and exertional angina, especially after meals.

Diagnosis

Physical examination was unremarkable apart from an apical fourth heart sound and a systolic murmur over the left sternal border that did not radiate to the neck vessels. A 12-lead electrocardiogram showed left ventricular hypertrophy and strain. Echocardiography showed assymetric left ventricular hypertrophy with a maximal thickness of 22 mm at the basal interventricular septum, systolic anterior motion (SAM) of the anterior mitral valve leaflet and a resting peak systolic gradient across the left ventricular outflow tract (LVOT) of 92 mmHg consistent with the diagnosis of hypertrophic obstructive cardiomyopathy (HOCM). The patient had no family history of hypertrophic cardiomyopathy (HCM) or sudden cardiac death (SCD). Genetic testing revealed a myosin-binding protein C Glu441Lys missense mutation. A two-month trial of bisoprolol – titrated up to 7.5 mg/day – failed to improve her symptoms. Accordingly, surgical septal reduction therapy (extended septal myectomy) was advised.

Treatment

Preoperative coronary angiography – which is routinely performed as part of pre-myectomy work-up at our institution – revealed a myocardial bridge affecting the mid-segment of the left anterior descending (LAD) artery with near-complete obliteration of its lumen during systole that apparently did not continue into diastole. Three septal perforators arising from the mid-segment of the LAD artery showed similar complete "squeezing" during systole (Fig. 1). Thermodilution-derived coronary flow reserve (CFR) – measured invasively using a pressure/temperature sensor-tipped 0.014-inch wire (Radi PressureWire™ – St. Jude Medical, Inc.; St. Paul, Minnesota) and dedicated software (Thermo™ package) was significantly impaired in the LAD territory (1.23). The index of microcirculatory resistance (IMR) – measured using the same wire and software package – was also abnormal (53), denoting significantly elevated microvascular resistance which – on its own – can explain the blunted CFR values. Conventional fractional flow reserve (FFR) in the LAD was 0.91, however, diastolic FFR (derived from diastolic rather than mean aortic and distal LAD pressures) was 0.75 (Fig. 3). A decision to perform surgical unroofing and full mobilization of the tunneled segment of the LAD artery during extended septal myectomy was made based upon the above findings.

Repeat coronary angiography four weeks after surgery revealed complete relief of the mobilized segment of the LAD artery – with no obliteration during systole (Fig. 2). Repeat CFR, IMR and diastolic FFR measurements showed significant improvement – measuring 1.7, 21 and 0.98 respectively (Fig. 3). Six months after surgery, the patient reports significantly improved exercise capacity with complete freedom from angina symptoms.

Discussion

Myocardial tunnels are frequently encountered in patients with hypertrophic cardiomyopathy with a reported prevalence of up to 40% in some post-mortem series [1–3]. The incidental finding of a myocardial bridge on coronary angiography does not seem to carry an adverse prognosis or increased risk of SCD in this patient population [3], [4], and accordingly should not on its own warrant intervention [5]. However, in patients with HCM and myocardial bridging presenting with angina as a prominent complaint, the physiological significance (i.e. ischemic burden) of such a finding should be carefully evaluated. Accurate identification of the small subset of patients with ischemia-producing myocardial bridges followed by surgical management improves symptoms considerably [6], [7] and may arguably reduce the risk of SCD [8], [9]. Establishing a causal link between the presence of

a myocardial bridge and regional ischemia might prove to be a difficult task in this setting however.

Angiographic features of myocardial bridges including length of the tunneled segment, degree of systolic compression, and depth within the myocardium are not reliable predictors of their potential to cause ischemia [10]. In addition, conventional angiography frequently fails to identify persistence of epicardial compression into variable periods of diastole (and hence more likelihood of causing ischemia) compared to other modalities such as intravascular ultrasound and intracoronary Doppler flow velocity measurements [11]. It is therefore not advisable to rely on coronary angiography only to determine the physiological significance of myocardial bridges except in cases with very mild compression that is unequivocally limited to systole [7]. Results of myocardial perfusion imaging on the other hand may be confounded by a number of factors in this subset of patients, including the presence of diffuse subendocardial ischemia, extensive microvascular disease, severe compression of septal perforators as well as patchy fibrosis, and should therefore be interpreted with caution [12–14].

FFR has recently emerged as a simple, accurate, highly-reproducible and lesion-specific index of the physiological significance of fixed epicardial coronary stenosis, with strong evidence supporting its correlation with clinical outcomes [15–21]. Its value in patients with "dynamic" epicardial coronary disease such as myocardial bridging is much less studied and remains limited to a few small series and case reports [22], [23]. Furthermore, conventional FFR measurement – defined as the ratio of mean pressure distal to a lesion to mean proximal/aortic pressure – in the setting of coronary bridges is prone to fallacies related to cyclical changes in coronary flow and distal pressure. The "squeezing" of the blood column distal to bridged segment against a highly resistive microcirculation (during systole) causes overshooting of the distal coronary pressure compared to the proximal/aortic pressure resulting in a negative pressure gradient across the myocardial bridge during systole. This surge in distal intracoronary systolic pressure increases the mean distal coronary pressure and consequently (falsely) increases the FFR values. In some instances, non-physiological values of >1 are obtained due to this phenomenon. This has been frequently referred to as "the FFR paradox". To overcome this limitation, the ratio between diastolic pressures – rather than mean – has been proposed to evaluate the physiological significance of epicardial stenosis. This is demonstrated in the present report where "conventional" FFR was 0.91 while diastolic FFR was 0.76. This approach offers the added theoretical advantage of limiting evaluation of the effect of myocardial bridges to diastole, the period where coronary blood flow predominantly occurs.

The additional use of incremental doses of i.v. dobutamine to increase contractility and heart rate can further enhance the diagnostic yield of this technique by simulating the effects of exercise on the myocardium and consequently augment the "squeezing" of the bridged segment prior to pressure measurements [22]. The use of dobutamine was not deemed necessary in this patient given the low "non-augmented" diastolic FFR value. Successful surgical relief of the tunneled LAD segment led to normalization of diastolic FFR with restoration of concordance with "conventional" FFR measurements, which further supports the theory of the "FFR paradox".

Conclusion

Myocardial bridges are frequently encountered in patients with HCM and are inconsequential in the majority of cases. However, it is crucial to accurately identify the small subset of patients where the presence of such bridges is associated with regional myocardial ischemia. Diastolic FFR measurement is a simple and highly reproducible tool that can reliably quantify the functional significance of such lesions in patients where the symptom pattern and/or angiographic features raise suspicion about their clinical significance.

[1] H. Kitazume, J. R. Kramer, D. Krauthamer, S. El Tobgi, W. L. Proudfit, and F. M. Sones, "Myocardial bridges in obstructive hypertrophic cardiomyopathy.," American heart journal, vol. 106, no. 1 Pt 1, pp. 131–5, Jul. 1983.
[2] F. Navarro-Lopez, J. Soler, J. Magriña, E. Esplugues, J. C. Pare, G. Sanz, and A. Betriu, "Systolic compression of coronary artery in hypertrophic cardiomyopathy.," International journal of cardiology, vol. 12, no. 3, pp. 309–20, Sep. 1986.
[3] C. Basso, G. Thiene, S. Mackey-Bojack, A. C. Frigo, D. Corrado, and B. J. Maron, "Myocardial bridging, a frequent component of the hypertrophic cardiomyopathy phenotype, lacks systematic association with sudden cardiac death.," European heart journal, vol. 30, no. 13, pp. 1627–34, Jul. 2009.
[4] S. A. Mohiddin, D. Begley, J. Shih, and L. Fananapazir, "Myocardial bridging does not predict sudden death in children with hypertrophic cardiomyopathy but is associated with more severe cardiac disease.," Journal of the American College of Cardiology, vol. 36, no. 7, pp. 2270–8, Dec. 2000.
[5] I. Olivotto, F. Cecchi, and M. H. Yacoub, "Myocardial bridging and sudden death in hypertrophic cardiomyopathy: Salome drops another veil.," European heart journal, vol. 30, no. 13, pp. 1549–50, Jul. 2009.
[6] J. Downar, W. G. Williams, C. McDonald, E. D. Wigle, and B. W. McCrindle, "Outcomes after 'unroofing' of a myocardial bridge of the left anterior descending coronary artery in children with hypertrophic cardiomyopathy.," Pediatric cardiology, vol. 25, no. 4, pp. 390–3.
[7] I. Olivotto, F. Cecchi, R. Bini, S. Favilli, B. Murzi, I. El-Hamamsy, and M. H. Yacoub, "Tunneled left anterior descending artery in a child with hypertrophic cardiomyopathy.," Nature Clinical Practice Cardiovascular Medicine, vol. 6, no. 2. pp. 134–139, 2009.
[8] A. T. Yetman, B. W. McCrindle, C. MacDonald, R. M. Freedom, and R. Gow, "Myocardial bridging in children with hypertrophic cardiomyopathy--a risk factor for sudden death.," The New England journal of medicine, vol. 339, no. 17, pp. 1201–9, Oct. 1998.
[9] F. Gori, C. Basso, and G. Thiene, "Myocardial infarction in a patient with hypertrophic cardiomyopathy.," The New England journal of medicine, vol. 342, no. 8, pp. 593–4, Feb. 2000.
[10] P. Sorajja, S. R. Ommen, R. a Nishimura, B. J. Gersh, A. J. Tajik, and D. R. Holmes, "Myocardial bridging in adult patients with hypertrophic cardiomyopathy," Journal of the American College of Cardiology, vol. 42, no. 5, pp. 889–894, Sep. 2003.
[11] J. Ge, a Jeremias, a Rupp, M. Abels, D. Baumgart, F. Liu, M. Haude, G. Görge, C. von Birgelen, S. Sack, and R. Erbel, "New signs characteristic of myocardial bridging demonstrated by intracoronary ultrasound and Doppler.," European heart journal, vol. 20, no. 23, pp. 1707–16, Dec. 1999.
[12] M. S. Maron, I. Olivotto, B. J. Maron, S. K. Prasad, F. Cecchi, J. E. Udelson, and P. G. Camici, "The case for myocardial ischemia in hypertrophic cardiomyopathy.," Journal of the American College of Cardiology, vol. 54, no. 9, pp. 866–75, Aug. 2009.
[13] P. Knaapen, T. Germans, P. G. Camici, O. E. Rimoldi, P. A. Dijkmans, W. G. Van Dockum, J. W. R. Twisk, A. C. Van Rossum, A. A. Lammertsma, F. C. Visser, N. Heart, H. Campus, T. Erasmus, and P. Knaapen, "Determinants of Coronary Microvascu

lar Dysfunction in Symptomatic Hypertrophic Cardiomyopathy," American Journal Of Physiology, pp. 1–34, 2007.
[14] S. E. Petersen, M. Jerosch-Herold, L. E. Hudsmith, M. D. Robson, J. M. Francis, H. a Doll, J. B. Selvanayagam, S. Neubauer, and H. Watkins, "Evidence for microvascular dysfunction in hypertrophic cardiomyopathy: new insights from multiparametric magnetic resonance imaging.," Circulation, vol. 115, no. 18, pp. 2418–25, May 2007.
[15] N. H. Pijls, B. De Bruyne, K. Peels, P. H. Van Der Voort, H. J. Bonnier, J. J. Bartunek J Koolen, and J. J. Koolen, "Measurement of fractional flow reserve to assess the functional severity of coronary-artery stenoses.," The New England journal of medicine, vol. 334, no. 26, pp. 1703–8, Jun. 1996.
[16] B. Beleslin, M. Ostojic, A. Djordjevic-Dikic, V. Vukcevic, S. Stojkovic, M. Nedeljkovic, G. Stankovic, D. Orlic, N. Milic, J. Stepanovic, V. Giga, and J. Saponjski, "The value of fractional and coronary flow reserve in predicting myocardial recovery in patients with previous myocardial infarction.," European heart journal, vol. 29, no. 21, pp. 2617–24, Nov. 2008.
[17] M. J. Kern and H. Samady, "Current concepts of integrated coronary physiology in the catheterization laboratory.," Journal of the American College of Cardiology, vol. 55, no. 3, pp. 173–85, Jan. 2010.
[18] N. Melikian, P. De Bondt, P. Tonino, O. De Winter, E. Wyffels, J. Bartunek, G. R. Heyndrickx, W. F. Fearon, N. H. J. Pijls, W. Wijns, and B. De Bruyne, "Fractional flow reserve and myocardial perfusion imaging in patients with angiographic multivessel coronary artery disease.," JACC. Cardiovascular interventions, vol. 3, no. 3, pp. 307–14, Mar. 2010.
[19] B. De Bruyne, N. H. J. Pijls, B. Kalesan, E. Barbato, P. a L. Tonino, Z. Piroth, N. Jagic, S. Mobius-Winckler, G. Rioufol, N. Witt, P. Kala, P. MacCarthy, T. Engström, K. G. Oldroyd, K. Mavromatis, G. Manoharan, P. Verlee, O. Frobert, N. Curzen, J. B. Johnson, P. Jüni, and W. F. Fearon, "Fractional flow reserve-guided PCI versus medical therapy in stable coronary disease.," The New England journal of medicine, vol. 367, no. 11, pp. 991–1001, Sep. 2012.
[20] N. H. J. Pijls and J.-W. E. M. Sels, "Functional measurement of coronary stenosis.," Journal of the American College of Cardiology, vol. 59, no. 12, pp. 1045–57, Mar. 2012.
[21] A. M. ElGuindy and R. O. Bonow, "FAME 2 – The best initial strategy for patients with stable coronary artery disease: Do we have an answer at last?," Global Cardiology Science and Practice, vol. 2012, no. 2, p. 18, Dec. 2012.
[22] J. Escaned, J. Cortés, A. Flores, J. Goicolea, F. Alfonso, R. Hernández, A. Fernández-Ortiz, M. Sabaté, C. Bañuelos, and C. Macaya, "Importance of diastolic fractional flow reserve and dobutamine challenge in physiologic assessment of myocardial bridging," Journal of the American College of Cardiology, vol. 42, no. 2, pp. 226–233, Jul. 2003.
[23] M. Kersemans, F. Van Heuverswyn, M. De Pauw, P. Gheeraert, Y. Taeymans, and B. Drieghe, "Hemodynamic effect of myocardial bridging.," Circulation. Cardiovascular interventions, vol. 2, no. 4, pp. 361–2, Aug. 2009.

Contact

david.groke@siemens.com

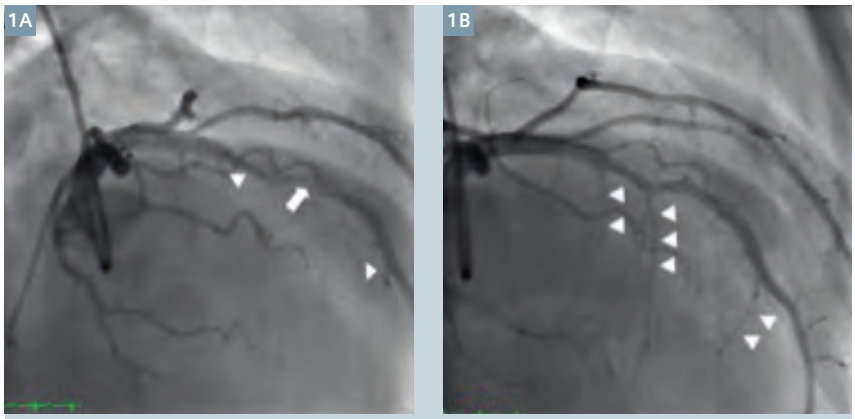

1 Pre-operative coronary angiogram. Still images in the RAO cranial projection are shown. The mid segment (arrow) of the LAD shows near-total obliteration at end-systole (A) and appears completely unaffected during end-diastole (B). Septal perforators arising from the mid are also squeezed during systole leading to complete obliteration of their lumen (arrow heads).

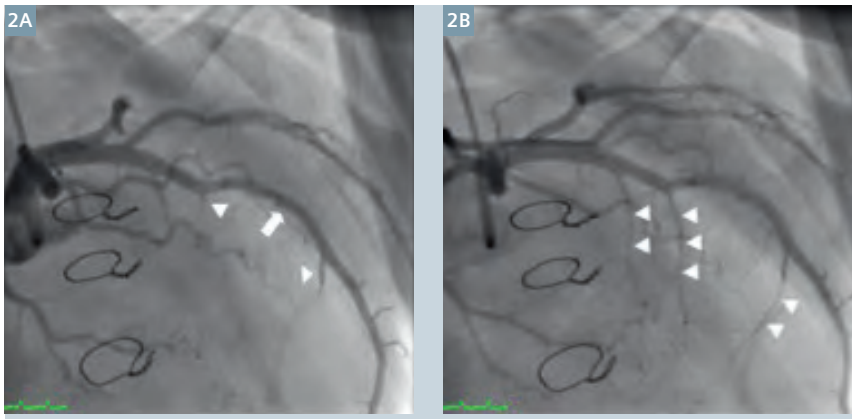

2 Post-operative coronary angiogram. Still images in the RAO cranial projection are shown. The mid segment (arrow) of the LAD is fully patent during end-systole with no residual systolic obliteration (A) compared to end-diastole (B). Systolic obliteration of the septal perforators remains unchanged (arrow heads).

3 Pre- and post-operative coronary pressure measurements as thermodilution-derived coronary flow reserve and microcirculatory resistance measurements. Pre-operative (A) FFR calculated from mean pressures (FFR_{mean}) was 0.91, however, when diastolic pressures were used, FFR was 0.75 (FFR_{dia}). Post-operative (B) FFR_{dia} was 0.98 which is very close to FFR_{mean} calculated at the same time suggesting complete relief of systolic squeezing. Thermodilution curves at basal conditions and after induction of steady-state maximum hyperemia are also shown in both the pre- and post-operative studies along with the derived CFR and IMR values.

Angiography and Computer Tomography in one OR – First of its Kind in the World

Courtesy of Robert Weersink, MD, University Health Network, Toronto, Canada
By Jay Parkes

The integration of two Siemens devices, Artis zeego and SOMATOM Definition Flash, within a single OR provides new opportunities for clinicians to evaluate the best imaging modality for the operating room based on image quality, navigation and accuracy, and fusion of different imaging modalities with real-time virtual endoscopy.

The recently opened GTx-OR (Guided Therapeutics Operating Room) at the University Health Network in Toronto is the first OR site in the world to combine a Siemens SOMATOM Definition Flash scanner and a Siemens Artis zeego robotic angiography system within the same operating theater. The SOMATOM Definition Flash scanner provides the 'gold standard' for CT imaging, while the Artis zeego provides excellent 3D rotational angiography for flexible integration within the operating environment. An Artis OR table that can articulate between the two modalities is included in the roster of GTx-OR equipment.

The plan is to use the speed of the CT system to capture a high resolution CT dataset and co-register these images with cone-beam CT images acquired using the Artis zeego during the surgical procedure. That way the surgeons can update the 3D image during the procedure and have full access to the patient at the same time. The updated 3D image lets the surgeon localize the remaining tissue to be removed, and provides an accurate 3D map for tracking and navigation of surgical tools or with Video-Assisted Thoracic Surgery (VATS). Currently, there is not a lot of published data available regarding this use of 3D intraoperative imaging "The dual-energy CT gives you exquisite image definition and incredible resolution," said Robert Weersink, MD, a medical physicist at UHN who is also a leader of the GTx-OR project.

Since it is difficult for a surgical team to access a patient inside the O-ring of the CT scanner, however, the patient can be moved to the Artis zeego, which also provides high-quality 3D images – for helping surgeons as they conduct open and minimally invasive procedures. The C-arm of the highly robotic Artis zeego can be swung away from the patient while surgeons work, and then moved back into the exact same position, enabling the doctors to re-image and resume their work.

"We're at the interface of industry and academia, surgery and physics.

We can take ideas that start in the lab ... test them, and bring them for the benefit of patients."

Jonathan Irish, MD
Chief of Surgical Oncology at UHN and leader of the GTx-OR project

Better Margins for Tumor Excision

According to Jonathan Irish, MD, Chief of Surgical Oncology at UHN and leader of the GTx-OR project, cancer funding has provided most of the financial support. As a result, the first to be treated have been cancer patients, such as those with tumors in the head and neck region, for example. Here, tumors are often close to important anatomical structures, such as arteries and nerves, so localization of the anatomy is a very important initial step in surgery to avoid serious damage to the patient.

In the past, surgeons using pre-operative imaging have been able to precisely visualize the anatomy in this region. However, as soon as surgery begins, the anatomy changes due to manipulation by the surgeon. This challenge is compounded by the fact that important structures in this region are typically very small and surgeons wish to operate in a minimally invasive manner as often as possible. For these reasons, accurate image guidance can be tremendously helpful. In the GTx-OR, this will be accomplished by coregistering the CT scanner, and *syngo* DynaCT images acquired during the procedure using the Artis zeego. Dr. Irish expects this high-level imaging hardware and software to give surgeons in the GTx-OR an even better view of what they are cutting so they can excise more of the tumors they are targeting, while leaving healthy tissue intact.

Ultra-Minimally Invasive Surgical Resection of Small Pulmonary Nodules

An increasing number of small pulmonary nodules are being detected on CT scans due to CT screenings in high risk patients. CT-guided, fine-needle aspiration or transbronchial biopsy is performed for the diagnosis of such nodules; however, this procedure is limited

by the location and size of the nodule. As a result, there is an increasing demand for VATS for tissue diagnosis as well as treatment of such nodules. VATS is in fact becoming the standard of care for resection of lung neoplasm.

The VATS procedure is performed on a deflated lung in the region of the lesion. Nodules located near the surface of the lung can be detected during VATS without palpation. However, most nodules are too small and located deeper than the surface and thus difficult to find using VATS alone. As a result, some patients require a thoracotomy for palpation. Once nodules are identified, endostaplers are used to perform wedge resection for diagnostic purposes, and pathology is performed to confirm negative margins on resected specimens. Because of the significant disconnect between the localization of the tumor in the diagnostic CT and the VATS procedure, patients may end up undergoing a large thoracotomy for complete resection. This results in significant reduction in patient quality of life. One proposal for how to address this problem using the GTx-OR configuration is that:

- Flash CT immediately prior to the procedure with the patient in the surgical procedure position to identify lung nodules;
- *syngo* DynaCT using the Artis zeego to register the patient and tumor position with that of the thorascope;
- Tracked and integrated video from the thorascope be used to guide the surgical procedure.

A CT of the lung prior to the procedure followed by registration of this image to a *syngo* DynaCT using the Artis zeego during the procedure would give proper localization of the lung nodule in the surgical field frame of reference. Real-time tracking of the tumor location on the endoscopic image, using updated 3D images with the Artis zeego, would ensure more accurate targeting during the resection. With greater confidence in localizing the target, surgeons would be able to reduce the volume of excised tissue. With registration of the thorascopic tool to the CT frame of reference, the tumor target can be identified on the endoscopic image in real-time. As the endoscope changes position, the crosshair of the tumor site would continually track tumor location and depth. Depending on the method of removal, tip tracking of the resection tools as they are advanced to the target can be in-cluded to ensure accuracy. Since treatment margins are large, the tracking accuracy required is approximately 3-5 mm. Follow-up CT can be used to ensure complete resection.

Imaging Facilitates Best Possible Outcomes

The GTx-OR initiative is led by the Techna Institute, a Research and Development Center at UHN that brings surgeons, physicists, scientists, engineers and imaging specialists together to explore and refine new operating techniques – both open and minimally invasive – supported by the latest imaging technologies. Surgical innovations devised by Techna will only be trialed and further developed in the GTx-OR after extensive pre-clinical testing. The goal is to use the advanced Siemens equipment to enable physicians to quickly and accurately image patients while they are on the operating table, thereby helping surgeons provide the best possible outcomes through the use of image-guided procedures.

Jay Parkes is a freelance Information Technology writer focused on the use of informatics and technology in healthcare.

Further Information

http://technainstitute.com/resources-places/gtxor

Contact

nadine.brown@siemens.com

Update on Thoracic Surgery at Völklingen, Germany

In our previous edition 16 in December 2013 we published an article "Very Promising Addition" (page 68) with Helmut Isringhaus, MD, Head of the Department of Cardiothoracic Surgery at the SHG Hospital in Völklingen, Germany. Dr. Isringhaus and his team, Klaus Urbschat, MD, and Alexander Gremekeli, MD are further developing the workflow regarding small pulmonary lung nodules. Using a large volume *syngo* DynaCT they are now able not only to cover the entire lung but also the skin around it. This is crucial for the exact pathway of the needle for the thread placement. It is necessary for the surgeon to find the entrance point through the skin into the lung for the precise placement with the support of *syngo* iGuide. After the needle thread is placed close to the nodule it is resected in a minimally invasive approach.

What is appreciated most is that this procedure takes place in one room at one time. Dr. Isringhaus said that "being able to treat the patient in a single procedure is much safer for the patient because the risks like haematothorax and pneumothorax through the placement of the thread can be controlled in a surgical setting. The patient only needs one procedure and also with the minimally invasive approach he is able to recover quicker." He also believes that the future of thoracic surgery is minimally invasive surgery; surgical instruments and imaging technology will develop further and safer and better treatment will be possible. "In parts of the world CT screening for high risk patients is already in use. This will lead to many more patients with small pulmonary nodules of unknown dignity. Especially when resecting nodules within the parenchyma, imaging plays a crucial role and image guiding surgery will become even more important," he stated.

Minimally Invasive Laparoscopic Adrenalectomy with Endoscope Fusion

A World Premiere of this Technique

At the University of Heidelberg in the Department of Urology, Dogu Teber, MD, performed a minimally invasive adrenalectomy using the Artis zeego and fusion of the intraoperative acquired images with an endoscope for surgical guidance. This surgery took place in the hybrid operating room of the Department of Vascular Surgery, owned by Prof. Dittmar Böckler, MD. After the first laparoscopic partial liver resection a year ago, technology and techniques have been further developed and the next minimally invasive laparoscopic approach was planned.

Minimally invasive surgery offers major benefits for patients but also challenges the surgeon due to the lack of natural 3D vision as well as the lack of tactile sensing. Intraoperative imaging and especially fusion imaging can help the surgeon to better guide his instruments and offers a real-time update of the changing anatomy when preoperative imaging loses its value. In laparoscopic surgery in particular, the benefit of intraoperative soft tissue imaging can be very helpful.

Tumor Detection

A kidney urinary bladder tract (KUB) of an animal was used as a first phantom. An artificial Aggar tumor was injected into the kidney and a *syngo* DynaCT was performed (Fig. 1). The artificial tumor could be easily detected in the *syngo* DynaCT. The workflow that is described in detail below was tested and proved to be practical. Also, patient positioning, access, and image acquisition capabilities in this new and sophisticated environment were tested. Then the first patient was scheduled in the hybrid operating room.

Better Visualization with Overlay

A patient with an adenoma of the adrenal gland was positioned in a lateral (kidney) position for better access to the tumor. The Artis zeego offers a complete table integration, so target organs even in sophisticated positions can be visualized.

Trokars were placed, the abdomen was insufflated with CO_2 and the anatomy was prepared. Color-coded radiopaque markers were placed on the tumor and around it. These markers are important for the endoscope registration process. Then the urologist acquired a *syngo* DynaCT with an 8s protocol.

The first step was to evaluate the differences of the preoperative CT and intraoperative *syngo* DynaCT. The overlay of the two 3D volumes matched and the *syngo* DynaCT proved to be of sufficient quality for the procedure. The markers could also be seen.

In a second step the *syngo* DynaCT data was segmented for an overlay using *syngo* iPilot. The segmentation was necessary because the tumor did not take up contrast agent and could hardly be seen in either of the two 3D volumes.

Software Calculation

The third step consisted of endoscope registration using special software provided by the German Cancer Research Center (DKFZ) and the segmentation of the *syngo* DynaCT (Fig. 3). The endoscope was registered with the software which allowed the endoscope to detect the different colors of the markers. The *syngo* DynaCT data were loaded into the software and the adenoma of the adrenal gland and the kidney were segmented. These images could now be overlayed in the real time endoscopy image. Even movement of the structures could be detected because the software calculates the locations of the markers relative to one another. An optimal superimposed image was generated (Fig. 4).

All Essential Information

In a final step, for image guidance 3D overlay was used in live fluoroscopy to guide the instruments and evaluate the depth, which is not provided by the endoscope. By changing the angulation of the Artis zeego the images also adjusted and allowed the surgeon additional 3D information for the procedure (Fig. 5).

This surgery was intended to prove that these principles can be applied and can help surgeons to optimize the procedure, particularly for critical structures. Further development and further research will follow.

It was the first operation of its kind and it is obvious that technology and workflow offer a wide-open area for innovations. However, it also demonstrated that surgery of this quality can really change paradigms in minimally invasive surgery.

Contact

ina.schwabenland@siemens.com

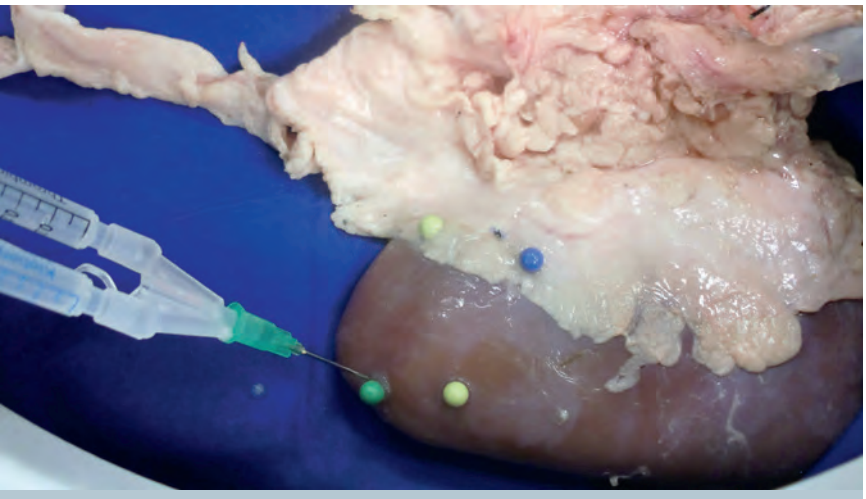

1 For the phantom trial an animal kidney urinary tract model was used. Markers were positioned and the feasibility for the endoscope *syngo* DynaCT overlay was tested.

2 Dr. Dogu Teber (right) and Dr. Gencary Hatiboglu are pioneering this first marker guided minimally invasive approach.

3 Endoscope registration process with software from the German Cancer Research Center.

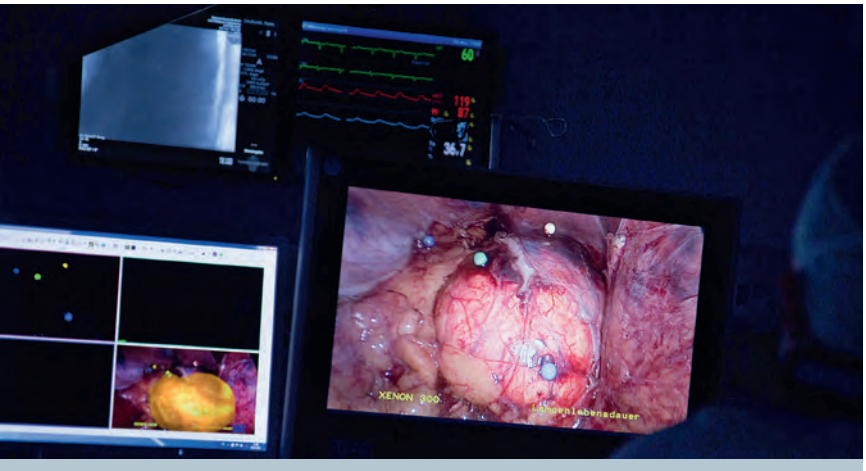

4 Markers on the adenoma of the adrenal gland and overlay of the 3D *syngo* DynaCT on the fluoroscopy image (yellow volume on the right lower corner of the left monitor).

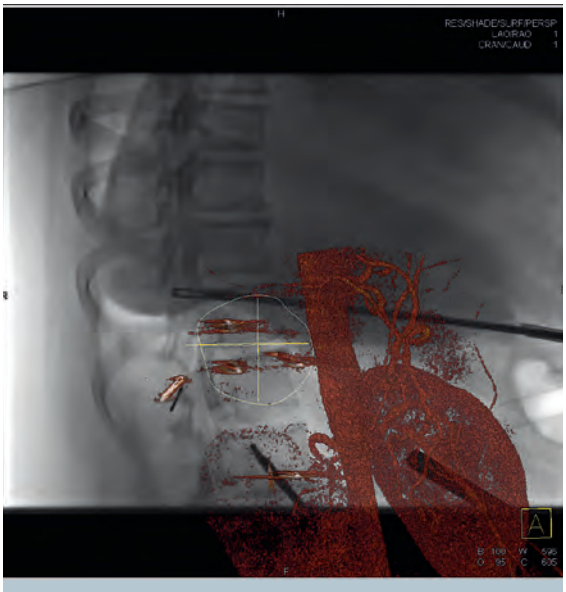

5 The overlay of the *syngo* DynaCT 3D volume on the live fluoroscopy can help to guide the surgical instruments. By changing the angulation the 3D volume automatically adjusts.

Experience with the Artis zeego in Orthopedic Trauma Surgery

Orthopedic trauma surgery is taken to another level using the Artis zeego. An increasing number of installations shows that, specifically for highly sophisticated procedures like scoliosis or pelvis fractures, the system provides a greater safety threshold for both surgeons and patients. Peace of mind at the end of the procedure, soft tissue imaging, and the ability to move the system by themselves are only a few advantages that surgeons appreciate about this new imaging device.

Cardiac and vascular surgeries are the drivers for hybrid operating rooms worldwide. It has become a standard and part of guidelines of well-known associations. The Artis zeego provides good contrast to guide the surgical devices, and also provides 3D imaging for specific questions.

Different disciplines, especially orthopedic trauma surgery, have noted the benefits of three-dimensional imaging, providing essential image quality. With some 30,000 orthopedic surgeons solely in the US alone, this market represents a great opportunity. As surgeons are used to mobile C-arms with or without 3D capabilities the system takes this kind of surgery to a new level. The integration of the fixed C-arm system with a surgical table proves to be of great benefit. The sophisticated positioning often needed in orthopedic trauma surgery can be achieved, and images can be acquired in this position by the surgeon moving the system with a joystick (Fig. 1).

Highest Hygienic Standards

Minimally invasive surgery with only small incisions is also a critical development in orthopedic trauma surgery, and fixed imaging systems like the Artis zeego can provide necessary features such as image quality and stored positions for accelerated workflows.

Demographic and lifestyle changes, such as obesity, play an important role. But tumor patients and polytraumatic patients can be treated in a hybrid environment as well. Artis zeego is of class 1a hygienic standard, which is the required standard for orthopedic surgeries. Within a running laminar air field the Artis zeego provides this hygienic standard even in working position.

As part of a multidisciplinary project, orthopedic trauma surgeons are often involved in hybrid operating room projects, and they are becoming increasingly aware of this exceptional imaging system. For example at the University of Ulm, Prof. Florian Gebhard, MD, was the lead in the hybrid operating room project (as published in AXIOM Innovations Edition 16, December 2012). He is an early adopter of this new computer assisted surgery concept. He is using Artis zeego especially for pelvis fractures, intraarticular fractures, tumor surgery, and spinal diseases. The large field of view in which an entire pelvis can be visualized in one image and the possibility of soft tissue imaging has helped him to treat more complex patients. Prof. Gebhard has been using the Artis zeego for over one year and highly appreciates the excellent image quality and the opportunity to do a *syngo* DynaCT at the end of the procedure to verify the position of the screws, change them if necessary, and therefore save the patient from a postoperative CT and secondary surgery in case of misplacement. He is also using the Artis zeego in combination with an automatically registering navigation system. One feature that he is exceptionally fond of is that the surgeon can move the system on his own under sterile conditions at tableside, avoiding discussions with staff when it comes to positioning the system (Fig. 2).

1 Prof. Gebhard at the University of Ulm is a pioneer in computer assisted surgery. He uses the system for pelvis fractures, tumor surgery, and spinal diseases.

2 Pelvis fractures are often asscociated with threatening vasculare damage. The Artis zeego offers not only an image of the pelvis in one shot but also one-stop treatment for critical patients.

3 Artis zeego provides good spatial resolution and great image quality. Especially for the thoracic spine or in obese patients this can be very beneficial.

4 Scoliosis surgery takes place across large areas of the spine. The system facilitates such surgery with its large field of view, large volume imaging, and spine composing. The wire shown on the image helps the surgeon preoperatively for better orientation.

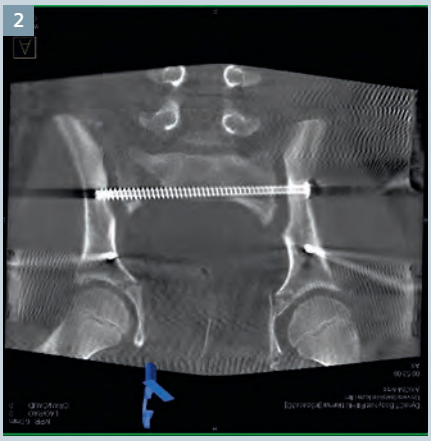

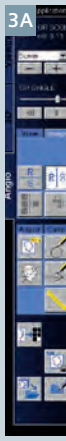

New Approach with a Multidisciplinary Concept

Per Wessberg, MD, an orthopedic trauma surgeon at Sahlgrenska University in Gothenburg, Sweden, is also part of a multidisciplinary concept. The vascular surgeons and interventional radiologists constructed a hybrid operating room in 2011. Coming from a mobile C-arm system, he was not aware that the Artis zeego could be used for the spinal cases that are his specialty. He was astonished by the large field of view and the speed of the *syngo* DynaCT. He focusses on adolescent scoliosis and he believes that the patients benefit greatly from this new environment. After a steep learning curve, once using the system he was also able to speed up the workflow compared to a conventional OR.

In Japan, at Tokushjukaj Fujisawa hospital, Sohei Ebara, MD, is using the Artis zeego for spine surgery only. A new spine and scoliosis center was opened with a hybrid operating room dedicated for these cases. Dr. Ebara provides surgery for all parts of the spine, cervical, thoracic and lumbar, and has developed workflows and accessories to fulfill the requirements for the different surgeries and the different surgical positions. As an example, for cervical cases a head clamp is attached to the operating table and the patient is positioned head first in prone position. For the lateral approach in scoliosis the patient is positioned on the side and Dr. Ebara uses endoscopes for better access to the thoracic spine. In this case the involvement of the anesthesia and OR staffs are even more critical.

He performs approximately seven to ten cases per week and has a four-month wait list for patients. It has taken time to gain experience with Artis zeego, and required open mindedness at the beginning but the effort was worthwhile as patients can be treated with greater peace of mind (Fig. 3).

Serving the Patient Better

These three doctors are great examples of the use of hybrid operating rooms in new fields of surgery. At conferences, through marketing material, and through these ambassadors the word is spreading in the community. The relationship with the AO Foundation, the largest community of orthopedic surgeons with over 30,000 members, is a great platform to expand this new imaging device for highly sophisticated procedures. One of the biggest challenges is to increase awareness that such a system is also available for orthopedic trauma surgeons.

The concept of integrating an operating table with the imaging system has proven to be very good. Not only sophisticated patient positioning can be achieved without impairment of 3D imaging but also the shuttle function is very important. First, the patient is positioned on the shuttle once he enters the OR environment – this is due to hygienic regulations. But the shuttle function is also very important for trauma patients. For example, polytraumatic patients can be positioned on the shuttle right on their arrival at the hospital. They can be treated in the emergency room, then go to diagnostics and finally to the OR without having to reposition the patient again. This can truly reduce the workflow by saving time and also avoid thr harm that could be caused by repositioning the patient on different beds (Fig. 4).

Surgeon's Freedom

With the extraordinary flexibility of the Artis zeego it leaves the surgeon freedom and access whenever he needs it. More workflows are being developed as the demand and the use of the system increase. Computer assisted surgery with the combination of navigation systems and other robotic systems are evolving, making this a very exciting field for the future.

Contact

ina.schwabenland@siemens.com

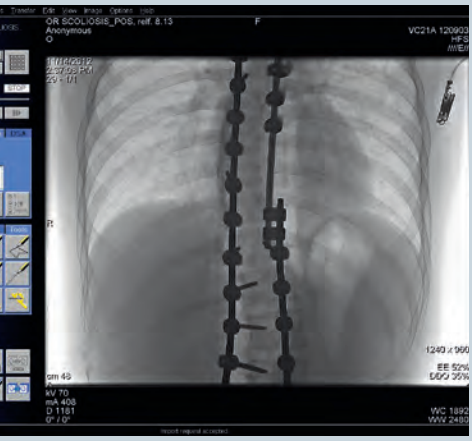

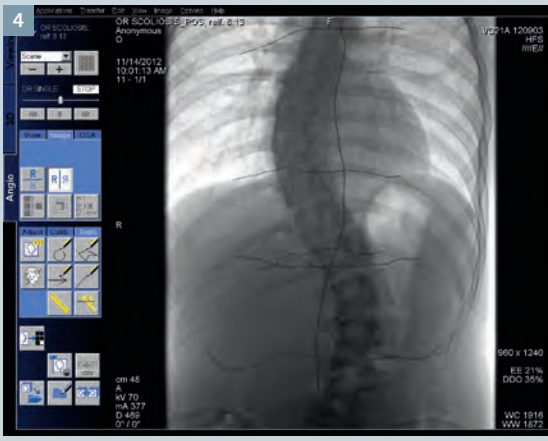

The Multidisciplinary Hybrid OR

By Wiebke Kathmann, PhD

In 2012 orthopedic trauma, cardiovascular, and neuro surgeons embarked on a common journey at the Ulm University Hospital in Germany – the multidisciplinary use of an Artis zeego hybrid room. AXIOM Innovations met the team to talk about their visions, experiences, and lessons learned during the first year.

It all started when a new University Hospital building was built in Ulm in 2012: a center of maximum care with over 1,100 beds and over 5,000 employees. This was Prof. Dr. Florian Gebhard's fortuitous moment. As the Director of Orthopedic Traumatology, Hand, Plastic, and Reconstructive Surgery, he seized the opportunity and realized his dream of setting up a 3D-robotic-imaging system integrated with navigation technology. His vision was to confirm that the combination of systems works for neurosurgery and orthopedic trauma, especially complex trauma interventions of the spine and pelvis.

Due to fiscal and room utilization constraints he invited the neurosurgeons, vascular, and heart surgeons on board early in the discussions and as a result the hybrid room was optimized for all specialties.

Planning the Hybrid OR

When setting-up a hybrid room, taking time for the details of the layout is important, reports Peter Richter, MD, Prof. Gebhard's right hand man. This is especially true if it is to be used by several disciplines. In Ulm the starting point was a 65 square meter traditional OR with the Artis zeego robotic imaging system as the centerpiece. "In our case this flexible floor-mounted system with 3D functionality and Automap gave us the versatility necessary for multidisciplinary utilization," stated Dr. Richter. "As for the navigation system, our choice was the Brainlab Curve™. Choosing the other components of the OR, like a laminar air flow, modern OR-table technology as well as large flat detectors for wide patient coverage took quite a while," recalled Dr. Richter. Since it had to be ensured that patient positioning, for example, had to meet everyone's demands regarding workflow, unrestricted access to the patient while also providing substantial space for anesthesia and the additional equipment for other specialties.

Communication and Sharing are Key

Looking back on their first year, all teams regard communication as key. They advise others who want to embark on the journey of a shared hybrid OR to plan on regular meetings from the beginning. "Clearly, a jour fixe is of great help, ideally with a coordinator taking care of the common needs of all disciplines involved." said Prof. Rainer Wirtz, MD, Director of the Clinic for Neurosurgery in Ulm and Günzburg. "That way you can discuss upcoming issues and share experiences – for instance regarding patient draping, data storage, or simple things like anesthetic equipment positioning during 3D acquisition."

Besides the jour fixe recommendation, predefined rules and a clear schedule for all disciplines involved was considered important by all groups. In Ulm the hybrid room is reserved by the orthopedic trauma surgeons two days a week, the vascular/cardiac surgeons another two days, and the neurosurgeons one day a week. Extra hours originally allocated to other teams could be booked through the coordinator in order to maximally utilize the hybrid lab. Currently, the hybrid room operates weekdays from eight a.m. until six p.m.

"The basic settings and principles all worked as desired from day one."

Prof.
Florian Gebhard, MD

Director of Orthopedic Traumatology, Hand, Plastic, and Reconstructive Surgery

Another lesson learned in Ulm was that having dedicated OR staff, working with the Artis zeego every day of the week, ensures the success of the hybrid OR. Dr. Wirtz recommends having either a technician or a nurse responsible for the room and the management of the different systems. Problems that come up at the end of the day can be forgotten or ignored so that the next team inherits them – unless person responsible for the room can act as a technical liason. Dr. Wirtz also suggests that the person in charge of the hybrid OR be complemented by another person responsible for the technical needs of each specialty, such as post-processing, troubleshooting, system movements, or positioning.

The Importance of Proper Training

Proper training is another key issue. With the additional benefit of team building in mind, Dr. Wirtz recommends for surgeons and technicians of all disciplines to participate in a common basic training unit on the system. This should be followed by a specialized training session for each discipline. "Once going live, starting with easy cases helps to optimize workflow," Dr. Wirtz explained. "Before attempting highly complicated cases, wait a couple of months until you feel comfortable with the movements of the Artis zeego, the nurses know where to stand, and the anesthesiologist identifies where to place their equipment," added Dr. Richter. Everyone agrees that only fully trained staff should be allowed to work with the system. Even though each of the Ulm hybrid room teams only had a maximum of two days a week the basics of the system were learned very quickly. "This is in part due to the very intuitive handling of the Artis zeego," stated Prof. Robert Bauernschmitt, MD, Director of Clinical Research for Cardiac Surgery sharing the hybrid OR. "Anyone experienced with Siemens' C-arm systems will have an easy time getting up to speed."

Proof of Principle

At Ulm the set-up of a multidisciplinary hybrid room has worked out well. Most expectations were met, and new clinical applications became possible. "The basic settings and principles all worked as desired from day one. New ideas that developed along the way, like programming different starting positions for the navigation in relation to the table, are now implemented," said Prof. Gebhard. "We have a very good platform after one year to develop new or improve

Artis zeego Features Used Regularly in Ulm

Application	Scope of Application	Additional Remarks
***syngo* DynaCT**	3D imaging for vessels or soft tissue.	Variable dose levels and rotation times determine quality of contrast resolution.
***syngo* DynaCT Large Volume**	The unique movements of the Artis zeego allow a volume of 35x25 cm to be acquired.	Useful for pelvic trauma, EVAR and spine surgery cases.
***syngo* InSpace 3D/3D Fusion**	After a low dose 3D spin of a contiguous bony structure, *syngo* InSpace 3D/3D Fusion allows a 3D volume from MRI, CT or PET to be used for navigation intraoperatively.	Can be used alongside or instead of *syngo* DynaCT.
***syngo* DynaPBV Neuro**	A subtracted 3D acquisition which demonstrates tissue perfusion.	Currently used in Ulm for neuro surgery but also available as *syngo* DynaPBV Body for abdominal imaging.
***syngo* iGuide**	Needle guidance software.	Useful for K-wire/screw placement during spine surgery.
***syngo* iPilot Dynamic**	Allows the superimposition of a 3D volume onto 2D fluoro regardless of system geometry (table position, zoom, C-arm angulation).	Used in conjunction with *syngo* DynaCT or *syngo* InSpace 3D/3D Fusion.
***syngo* iFlow**	One click turns a standard 2D angio run into a time-colored blood map.	The ROI function is useful to quantitate flow diverter effectiveness, post embolization tissue perfusion and post vascular intervention flow.
CAREposition	Radiation free C-arm or table repositioning.	Saves dose by reducing the amount of radiation on-time.
Overlay Ref	The contrast and dose reduced version of traditional roadmap.	Often used in conjunction with Automap.
Roadmap	Standard interventional neuro tool.	Advanced Roadmap allows for windowing of mask image during intervention.
Automap	Enables the Artis zeego to move quickly, automatically and exactly to any number of predefined views.	Especially useful in spine surgery.
Quick positions	Three quick-store and quick-retrieve buttons at tableside.	Often used in cases where two or three different imaging positions are repeatedly required.

existing workflows, like the use of *syngo* iGuide in trauma, reducing radiation exposure for everyone on the team. Hopefully we can prove that 3D imaging combined with navigation can reasonably reduce radiation dose to one twentieth of what it used to be."

The biggest success for Prof. Gebhard is the proof of principle for combining the imaging and navigation systems in orthopedic trauma surgery. "We were the first to prove that it works," stated Prof. Gebhard. Up until now images gained outside the OR could not be used intraoperatively for navigation purposes. An example is for tumor resections. Now, they can even be generated in the OR itself. "Being able to perform image fusion in the OR, or using intraoperative *syngo* DynaCT saves considerable planning and preparation time, and helps with adhering to preoperatively defined resection margins," explained Dr. Richter.

Prof. Gebhard and his team use the hybrid room for complex spinal and pelvic fractures, especially for navigated stabilization of the spine and for oncologic bone surgery. The Artis zeego provides them with more confidence due to the higher image quality, larger field of view, and greater heat loading than older style image intensifier imaging. "There is a huge benefit for minimally displaced fractures of the pelvis, for the obese, and for elderly patients," concluded Prof. Gebhard.

Neurosurgical Frontiers

As for the neurosurgeons the new angio-based hybrid lab also opened up new prospects, even though Dr. Wirtz already had long-standing experience with intraoperative imaging in neurosurgery when he came to Ulm five years ago. He is one of the pioneers of intraoperative MRI in neurosurgery. "While I was at Heidelberg University we were the first department worldwide to use intraoperative MRI in a brain tumor resection." With an MRI-based hybrid OR in Günzburg and more than 600 cases with MRI by now, Dr. Wirtz and Ralph König, MD, Assistant Director of Neurosurgery in Ulm, were interested in an angio-based hybrid room for aneurysm cases, above all. "Aneurysm clips create artifacts in MR imaging, which in turn make it difficult to evaluate the patency of the vessel," states Dr. König. „Plus, one feels more secure in using angio during sophisticated neurovascular interventions. It is very useful to have high quality DSA imaging after microsurgical excision of an AVM, in order to detect residual nidus, which would increase the patients' risk of hemorrhage." One new area of interest for the neurosurgeons

One new area of interest for the neurosurgeons is 3D imaging with an intravenous contrast injection. A ten second *syngo* DynaCT spin with 80 cc of full strength contrast and viewing with 15 mm MIP slices is the current technique.

Special Needs in Cardiovascular Cases

For Dr. Bauernschmitt, who only joined the common journey this April, the situation is a little different from his neurovascular and orthopedic counterparts. He brings more than ten years of experience in hybrid OR from his time as Deputy Director at the German Heart Center, Munich. His expertise is in innovative catheter heart valve procedures like TAVI and mitral valve repair. He and Prof. Andreas Liebold, MD, Director of Cardiovascular and Thoracic Surgery, see the hybrid OR in their field as a must-have. Prof. Liebold, who became the Director of this Department in 2011 and was Deputy Director at the University of Rostock, is now responsible for the hybrid OR. The team of cardiac surgeons brings the most experience to this OR.

As the cardiac surgeon in the Ulm multidisciplinary hybrid room, his challenge comes from the motion of the organ he deals with. "Cardiac and vascular surgeons work on soft tissues with inherent organ movement, as opposed to relatively fixed structures in trauma and neurosurgery. One could say that repairing a structure like an aortic valve is like tying a shoelace while running. Therefore, we have slightly different needs in the hybrid OR." When asked about software, Dr. Bauernschmitt's opinion is that *syngo* Aortic ValveGuide would be of great benefit to sites training in aortic valve implantation and for the new generations of anatomical valves. He is most interested in impending technical imaging advances for mitral valve repair.

Future Perspectives

If asked about the future, the physicians agree that they can see a time when expansion would be desirable and all would choose to construct a multidisciplinary hybrid lab again. Dr. Bauernschmitt's recommendation would be that "disciplines working with soft tissue like cardiac surgeons and abdominal surgeons would share one OR, while the other OR could be shared by orthopedic surgeons and neurosurgeons working on or around bones." For now, the Ulm hybrid room team will expand by training more staff and extending the hybrid room hours.

Read more about multidisciplinary use of a hybrid room in following chapters.

Medical writer Dr. Wiebke Kathmann is a frequent contributor to medical magazines for physicians of German-speaking media. She holds a MA in Biology and a PhD in Theoretical Medicine and worked as an editor for many years before going freelance in 1999. She is based in Munich and Karlsruhe, Germany.

Contact

penelope.vos@siemens.com

The Sahlgrenska University Hospital Multidisciplinary Hybrid Room

Sahlgrenska University Hospital is one of six teaching hospitals in Sweden. It provides specialized care for the 1.7 million inhabitants of West Sweden and basic care for the 700,000 inhabitants of the Gothenburg region. AXIOM Innovations spent 3 days with the team observing cases and talking about their multidisciplinary experience.

The Gothenburg multidisciplinary journey began in approximately 1996 when the vascular surgeons of that time recognized the benefits of a hybrid operating room. This idea started to become more concrete in the early 2000s when Sahlgrenska University Hospital (SUH) envisaged a new interventional imaging building with some rooms earmarked as hybrid OR. With traditional Scandinavian planning and attention to detail, it was decided to make a comparatively small investment and install an Artis zeego in the established operating theater complex so they could understand the process, learn from the experience and limit the mistakes in their new multi-lab installation. In this pilot hybrid lab, over the past two years nurses, cardiologists, vascular surgeons, spine surgeons, interventional radiologists, and anesthetists have evolved their workflows and communication to work in harmony.

Planning the Pilot Hybrid Operating Room

As soon as the multi hybrid lab proposal became more than just a dream, Karin Zachrisson, doctor of interventional radiology, and Håkan Roos, doctor of vascular surgery at Sahlgrenska University Hospital, wanted to work together to ensure the needs of both vascular surgery and interventional radiology could be realized. It is in no small part due to their efforts that the hybrid OR has had such a successful start.

The pilot hybrid OR was originally one operating theater and two adjacent rooms that were combined to make a 100 square meter room. The Artis zeego and Siemens OR table were installed diagonal to the walls so that in the most common working position (table at 15° to patient's right, Artis zeego from patient's left) the table is parallel to the walls and the anesthetists have the maximum amount of space at the patient's head. Two large displays on both sides of the tables and two additional monitors on each side of the room were positioned so that all staff have an optimal view on the intraoperative and preoperative images as well as the vital parameters. A laminar airflow field providing the highest hygienic standards was installed along with additional ambilight function for a better contrast on the monitor displays.

Team Work from the Beginning

Before the installation of the Artis zeego, SUH created an OR education group headed by Christina Ekroth who has a background as an OR nurse. In a two year collaboration between Siemens and the hospital an education plan was produced. This had the aim of introducing the different groups (assistants, nurses, interventionalists and anesthetists) to the hybrid room concept and the advantages for their patients. Ekroth, Dr. Roos and Dr. Zachrisson all stress that training and communication are both key to a smooth hybrid OR beginning. Ekroth recommends having a vision of what you want to achieve and clear your mind of preconceptions about workflow. "Working in a hybrid room is challenging and requires you to adapt and be flexible. People who say 'we want to do it this way because we've always done it this way' will not be able to benefit from all the advantages of a hybrid OR."

The majority of the interventionalists were familiar with the Siemens systems that are in different departments of SUH. The transition to the Artis zeego was easy with just one extra joystick to control the robot. For those surgeons who were unused to angiography systems the learning curve was a little steeper. A "couple of months" is often cited as the amount of time it takes to be fully accustomed to the Artis zeego if starting with zero Artis experience.

Interventional Radiology

The interventional radiologists are led by Dr. Karin Zachrisson who has been an interventional radiologist for 20 years and at SUH for ten years. She and her team perform vascular, embolization, and TIPS procedures on the Artis zeego and highlights that it is mainly used for procedures where the patient is at high risk of uncontrolled bleeding. On inter-specialty interaction Dr. Zachrisson stated; "One of the most unexpected but rewarding advantages of the hybrid lab is the improved collaboration between IR and other departments. We always had a strong relationship with the vascular surgeons but for example once we started working with the cardiologists helping them with fusion on the Artis zeego during TAVI (trans aortic valve implantation) cases, we found that they also sought our opinion for cases such as renal denervation. We grow from this cross specialty interaction."

Cardiac Interventions

The cardiologists regularly perform TAVI procedures in the hybrid lab to

All planned EVAR procedures are performed in the hybrid OR.

take advantage of the sterile conditions and of the proximity of their thoracic surgery colleagues. The thoracic surgeons assist with direct aortic and subclavian approaches, but for transfemoral approaches, they mostly work alone. The interventional cardiology team of Truls Råmunddal, MD and Petur Petursson, MD are yet to use their *syngo* Aortic ValveGuide software routinely as the CoreValve placement has a margin of error, but with the increased attractiveness of anatomically specific valves, correct placement will be greatly assisted by 3D imaging with motion correction.

Dr. Råmunddal agrees with Dr. Zachrisson that only specific cases are appropriate for the hybrid OR. "The vast majority of cardiac interventional procedures should be performed in the traditional lab. TAVIs and mitral valve interventions are exceptions. Currently we use the hybrid room for two cases every Wednesday. This may change in the future but for now it suits us."

When asked about the benefits to his patients, Dr. Råmunddal said, "Here at Sahlgrenska we perform TAVIs exclusively on patients who are unsuitable for conventional heart surgery. However, most patients are still candidates for surgical management of complications when needed. We strongly believe that the hybrid OR facilities make the TAVI procedure safer. For example, in the case of life threatening complications such as cardiac tamponade due to rupture of the left ventricle, we can have the chest open in under ten minutes and possibly fix the problem. The hybrid lab provides our TAVI patients with a bigger safety net because of the immediate access to vascular and thoracic surgical expertise."

Vascular Surgery

Dr. Håkan Roos adopted the hybrid room concept from his predecessors and it is under his leadership that it has come to fruition. "It's an obvious advantage to the patient when you don't have to weigh up the risks of moving a patient in order to convert to open surgery," he says. "In the hybrid lab, open surgery and interventional procedures are interchangeable." The entire spectrum of vascular interventions is performed. Complex procedures with fenestrated or branched stents are now feasible in a setting like this and have become standard for vascular surgeons.

A technique that the vascular surgeons are refining combines five seconds *syngo* DynaCT and *syngo* InSpace 3D/3D Fusion in order to overlay anatomical markers during EVAR procedures (Fig. 1). Interventional radiologist, Giasemi Koutouzi, MD regularly joins the vascular team to assist with post processing and fusion on the *syngo* X Workplace.

In the beginning of the hybrid lab journey, the vascular team assisted the cardiac team to learn certain skills needed during TAVI procedures. The 18Fr aortic valve delivery system sometimes requires dilatation of the iliac artery, a skill that the vascular surgeons shared with the cardiologists.

Spine Surgery

The orthopedic spine surgeons came rather late to the Artis zeego party. In 2011 spine surgery (along with pulmonary, orthopedic, and renal surgery) had not been considered as an area that would hugely benefit from using the Artis zeego, but in hindsight, the increased power and Automap functionality make it far superior to the old-style mobile C-arm systems that spine surgeons used to use.

As the room was not being fully utilized by the IR and vascular teams, the spine surgeons were invited to use the hybrid lab on Mondays and have not looked back since. "The opportunity to have access to a room with an imaging system like the Artis zeego is of great value," says Per Wessberg, MD.

Dr. Wessberg was excited by the image quality and started to use the hybrid operating room for complex spinal procedures. "For adolescent scoliosis procedures the Artis zeego brings surgery to a new level." With a portrait *syngo* DynaCT and its excellent spatial resolution he is now able to place spinal implants very precisely. On top of this, if a screw is not in the ideal position it can be corrected there and then. A *syngo* DynaCT at the end of the procedures helps the surgeon to end surgery knowing that all screws are placed optimally.

For this final 3D acquisition, SUH is using the low-dose protocol 5s DR-L that requires only 30% of the dose of a regular 5s DR protocol. For very young patients SUH is evaluating a special protocol that acquires only half the number of projection images, thus even further reducing the dose by a factor of two. The surgeons mainly use the 3D volume for control of the screw placement and as a result routinely use under 30 seconds of fluoro for scoliosis and fusion cases.

The Hybrid Nurse

Monika Wass is an OR nurse with over 20 years of experience at Sahlgrenska. She has found it challenging but interesting to amalgamate with the IR nurses. "The IR nurses were interested in evolving their sterile technique and we have learned more about handling catheters and wires" says Wass, "in the beginning we had many meetings and practiced simulated cases but nothing can 100% prepare you for the first live case. You need to be very flexible and open minded and even after two years with the Artis zeego, we still learn new things." Roos mentions that the long term goal is for nurses from either background to evolve towards becoming "hybrid nurses".

Although the global trend is moving toward interventional procedures, Wass warns nurses to keep up their surgical skills. "When an interventional procedure goes wrong, the patient can go downhill very quickly. At this time the physicians need an experienced and competent surgical nursing team by their side. Stay current," she advised.

Future Perspectives

The hospital regularly organizes "Intro days" where clinicians doing a wide variety of procedures (such as trauma and tumour surgery) are invited into the hybrid lab and shown the features of the Artis zeego that would benefit their specialties. Advantages common to all specialties include Automap,

syngo DynaCT, the increased power of the angio tube and the potential for radiation reduction. Apart from those already mentioned, the current hybrid OR users consider that other specialties who could find the room useful include; the transplant team, gastroenterology, gynecology, oncology, interventional neurology, neurosurgery, orthopedics, urology, and thoracic surgery. Some of these other specialties will begin their hybrid room experience upon completion of the new hybrid rooms.

If asked what changes they would suggest for a new lab, small modifications were discussed by the different teams. Dr. Roos and Dr. Zachrichsson wish for an operating table, like Trumpf or Maquet, whereas the cardiologists prefer the floating table top of the Siemens OR table. The anesthetic nurses would prefer to be positioned closer to the door to enable easier communication with their colleagues. Many state that the room should be wider but also appreciate that an OR can never be big enough. The theater nurses would like a bigger laminar airflow area with Ekroth joking that the whole ceiling should be laminar air. This would be entirely possible with the floor mounted Artis zeego and enough floor space.

All specialties are keen to see the development of a 24/7 hybrid OR servicing patients with uncontrolled bleeding such as ruptured aneurysms and trauma. For these patients, Dr. Roos states that the hybrid operating room would show its real benefit. Currently, logistics don't allow them to man the hybrid OR out of hours but this is the ultimate goal in order to provide the gold standard of care to the population of Western Sweden at all times.

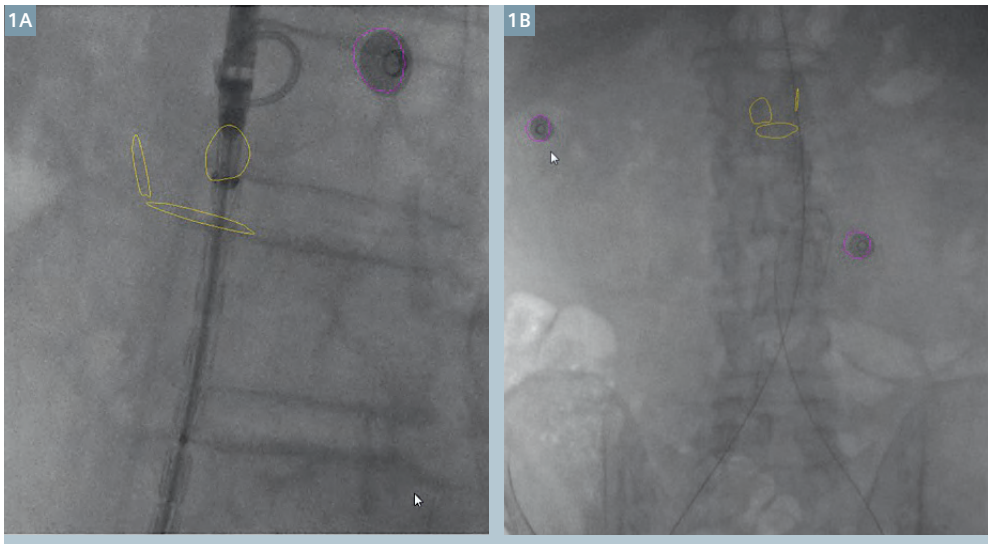

1 Markers from the CT volume are in yellow and markers from the intra-operative *syngo* DynaCT are in pink.

Håkan Roos, MD, vascular surgeon, and Karin Zachrisson, MD, interventional radiologist.

Christina Ekroth is head of an OR education group with a background as an OR nurse.

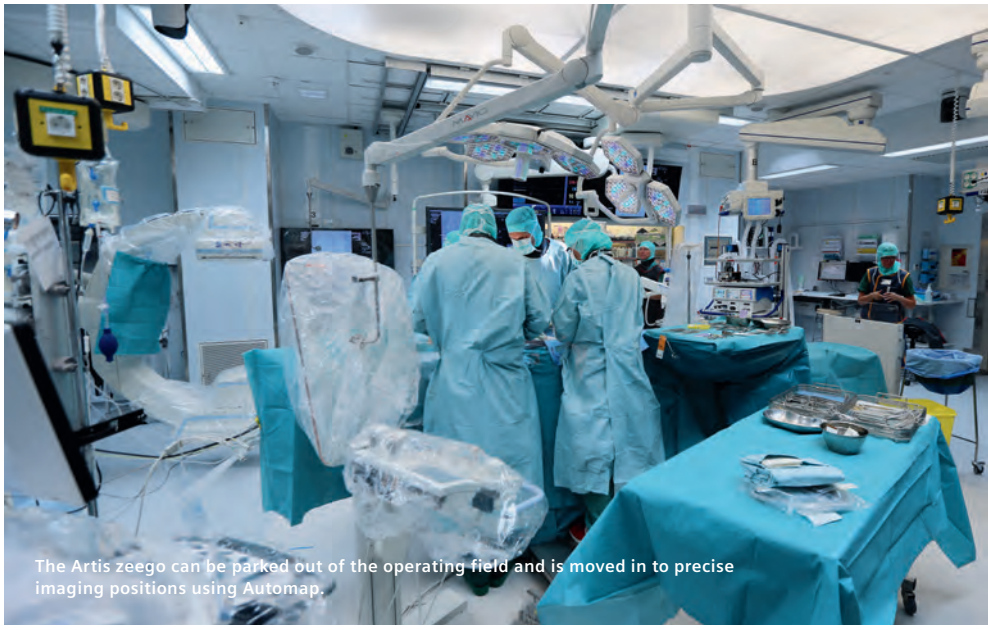

The Artis zeego can be parked out of the operating field and is moved in to precise imaging positions using Automap.

Contact

penelope.vos@siemens.com


WelchAllyn
KUMARA RAJA MD

A New Hybrid OR Improves Cardiac Treatment

"The more I can see, the clearer the image, the easier and better the outcomes are."

Kumara Rama, MD,
vascular surgeon,
St. John Hospital, Detroit, MI

St. John Hospital & Medical Center creates a state-of-the-art hybrid operating room (OR) to advance a full structural heart program that will enable new levels of patient care.

Situated on the east side of Detroit, Michigan, between the cusp of the city limits and the suburb of Gross Pointe, St. John Hospital & Medical Center serves a steady stream of patients from all walks of life. Long known for its cardiac expertise, the center performs about 2,000 percutaneous coronary and peripheral interventions and 400 open heart surgeries, including minimally invasive and robotic surgery. Now this 772-bed tertiary care facility is taking its next step toward cardiac excellence: a full structural heart program. A new hybrid OR is the vital catalyst to further this goal.

Creating the Right Environment

"We feel it is very important to stay at the cutting edge of technology," said Thomas LaLonde, MD, Chief of Cardiology and Cardiovascular Services. "If you really want to create a structural heart program, we felt very strongly that having sophisticated imaging in a hybrid lab in conjunction with the sterile environment of an operating room would be paramount to that success."

Sanjay Batra, MD, Chief of Cardiothoracic Surgery, concurs. "We felt it was very important to invest in our structural heart program – from both a physician standpoint and a system standpoint. Therefore, our first step was to build a state-of-the-art facility that enables us to perform hybrid procedures with the precision that is required."

With their vision to build a new hybrid suite firmly rooted, decision-makers at St. John Hospital proceeded to select a location for their room. Since space was conveniently available in the operating room, they selected the OR over the cath lab. This spared them the time and expense to recreate a sterile environment.

Thomas LaLonde, MD

Chief of Cardiology and
Cardiovascular Services,
St. John Hospital, Detroit, MI

"Everybody is very excited about doing cases in the hybrid room because it is beautiful – with amazing technology – and we've had nothing but excellent support from Siemens and excellent outcomes in every case we've done in there so far."

Enhanced Care for Complex Patients

The hybrid OR at St. John Hospital has been busy since its debut, supporting more than 900 cases to date. The majority of cases comes from vascular surgery, but the room is also used for neurology, thoracic and cardiovascular procedures, including over 50 TAVR cases. Looking ahead, it will be the preferred site for complex endovascular work that otherwise could not be achieved in either a conventional operating room or a cath lab setting. According to Kumara Rama, MD, vascular surgeon, "To me, a hybrid OR is an absolute must for certain procedures like a thoracic aortic aneurysm, aortic dissection, percutaneous valve, and the c-clip for the mitral valve. These kinds of procedures cannot be done without a powerful C-arm."

Further, the hybrid OR offers new options to patients who would have been excluded from surgery in the past. "With the development and advancement of angioplasty and stents and better long-term results, the number of patients requiring coronary bypass surgery is decreasing," said Dr. Batra. "As patients are living longer, however, the need for valvular surgery is increasing. As technology advances, we are able to perform these procedures on patients who would not have been operative candidates in the past. But if you don't have a state-of-the-art facility to perform these procedures, the results will certainly not be what we expect or need."

Dr. LaLonde added, "I think the multidisciplinary approach cultivated within a hybrid OR is of utmost importance. For example, a percutaneous aortic valve procedure requires a cardiologist and a cardiothoracic surgeon working side by side. Therefore, the patient benefits from a hybrid approach to care involving multiple specialties."

In addition, patients benefit from physicians' ability to provide a combined surgical intervention that addresses multiple conditions in a single setting – thereby increasing patient safety, reducing infection rates, and speeding the time to recovery. Tom Davis, MD, Director of the Cardiac Cath Lab and Peripheral Vascular Program, recounts one case involving a patient diagnosed with severe three vessel cardiac disease and a more than 80% stenosis in the carotid. Clinicians accomplished two procedures at the same time. "In the hybrid OR, we started by performing a carotid stent, did our procedure, and then the patient was prepped for bypass surgery. The anesthesia time is shorter for the patient because we did conscious sedation for the stent. From our standpoint, in terms of OR time, the combined procedure is much quicker than a carotid endarterectomy and bypass surgery. Plus, if there are complications, you can have the chest opened up within minutes. I truly believe the hybrid OR is safer for these patients."

Interestingly, the hybrid OR introduces another significant factor linked to patient care: the ability to participate in nationally renowned trials. Dr. Batra explained, "I think having the clinical expertise, the clinical results, and just as important, a world-class facility, will enable us to be selected for trials. This will allow our patients to understand and to appreciate the expertise that we offer. After all, our ultimate goal is patient care – what's best for the patients and their families."

Lessons Learned

A committee of about 15 people, headed by Dr. LaLonde and representing a cross-section of multiple disciplines and staff, diligently worked together for nearly a year to define the function of St. John Hospital's hybrid OR, identify the requisite technology, and ultimately configure the space. The result is close to pristine.

Committee members agree that site visits to view the technology in action was an invaluable part of the process. The visits also helped the committee members to visualize the space requirements for the room vis-à-vis the equipment, staff, cabinetry, and counter space that would need to be accommodated. The committee members unanimously agreed that "more is better" in terms of space. The room begins to shrink – particularly the ceiling space – as you add equipment. Dr. LaLonde advised, "It's important to do your homework. Go on multiple site visits to see a hybrid room and to talk to the people who put the room together. See what mistakes they made – we can always learn from each other's mistakes."

According to Michael Vicencio, applications specialist for cardiology, it's equally important to raise adequate funding early on. "There are always technology add-ons. Get buy-in from the different disciplines up front since this will determine which equipment is selected for the room."

Technology Requirements

The Artis zee ceiling-mounted C-arm system is the focal technology within St. John Hospital's hybrid OR. Physicians are impressed with the 3D imaging provided by *syngo* DynaCT. "The more I can see, the clearer the image, the easier and better the outcomes are," explained Dr. Rama. In addition, the flexibility and positioning capabilities of the ceiling-mounted system work best for the room – staff felt the system could be moved quickly and easily parked when not in use. Surgeons appreciate the design and automation of the system's table and believe it will ideally support the types of procedures they will handle. Affordability is another key benefit of the ceiling-mounted system.

The room is outfitted with an assortment of supporting equipment and features, as well. These include several booms, an array of lighting components, a video conference system with seven monitors, media streaming, and color balancing LED lights. However, the staff favorite is a video display with four LEDs that create a window effect. Here, a variety of tranquil, picturesque images help to soothe both the patients and OR staff.

The Rewards

Enthusiasm for the hybrid OR runs high among the staff at St. John Hospital – and with good reason. Dr. LaLonde summarized, "Everybody is very excited about doing cases in the hybrid room because it is beautiful – with amazing technology – and we've had nothing but excellent support from Siemens and excellent outcomes in every case we've done in there so far."

Contact

sabine.wich@siemens.com

Tips to Consider before Creating a Hybrid OR

1. Create a multidisciplinary team across all specialties consisting of physicians, nurses, IT, and administrative directors.
2. Decide is this a cath lab that can function as an OR or an OR that has cath lab functionality. This will help you determine what to put in the room.
3. Use or create a room as big as you can. The room always begins to shrink as you add equipment.
4. Go on site visits and note the size and space restrictions of the room and equipment. What features do they use and what features offer little benefit? This will help you determine what equipment and features should be included in your hybrid OR.

Hybrid OR: outfitted with an assortment of supporting equipment and features.

Dr. Batra and Dr. Rama in front of the video display with four LEDs that create a window effect.

Dr. Davis proudly presents the focal technology within St. John Hospital's hybrid OR: The Artis zee ceiling-mounted C-arm system.

A Miraculous Touch

Prof. Xinwei Han, MD captains of one of the biggest interventional radiology departments in the world. Zhengzhou University First Affiliated Hospital has almost 10,000 beds and the interventional radiology department consists of 208 beds. He has five Artis systems that work around the clock to treat the patients of the Henan region. He shares his knowledge with regional colleagues to offer cancer patients the best chance of survival regardless of where in Henan they live.

Text: Chen Yi | Photos: Tang Ting Ting

A 50-year-old male patient lies calmly on the operating table. A small sheath is inserted into his femoral artery. He has only received local anesthetic around the puncture site, and his fearless eyes sometimes glance at the strange contraption above his head. It is the flexible C-arm of the Artis zeego robotic interventional system installed in the interventional suite. The interventional radiologists and nurses can adjust the imaging system in hundreds of different ways according to their needs. The two 'eyes' of the robot are two monitors that help the doctors to observe their minimally invasive devices during the procedure.

This is the interventional therapy operating room at Zhengzhou University First Affiliated Hospital. It is ten in the morning, Prof. Xinwei Han, a well-known Chinese professor in the field of interventional radiology, is standing in the control room of the interventional suite. A pane of transparent lead and several pieces of monitoring equipment separate him from the proficient younger surgeons he is mentoring. The patient, who is suffering from primary carcinoma of the liver, is undergoing a super-selective hepatic arteriography chemoembolization. On the same day, a total of 40 patients are scheduled for operations in the interventional therapy department, some involve cerebrovascular diseases and esophageal stenosis, but the vast majority of patients are fighting illnesses such as stomach cancer, liver cancer, and esophageal cancer.

A Kernel of Rice

In the eyes of a Chinese patient, once he or she has entered the hospital, their life is entirely in the hands of the doctor. Prof. Han stated: "I use the simplest and most easily understandable language and describe this kind of operation as; 'Grabbing the cancer cells by the throat and making them drink a poisonous potion.' Interventional therapy doesn't require a large knife. We make a small opening on the patient's body that isn't larger than a kernel of rice, then we take an interventional device that is about one to three millimeters in diameter and enter a blood vessel. Next we take an embolization agent about the size of a tadpole and insert the agent directly into the area affected by the carcinoma. This achieves a targeted localized treatment. Data related to this procedure is instantaneously entered into the hospital information system, for all of the patient's doctors to review."

Despite having already been in use for more than 40 years globally, and having a history of nearly 30 years in China,

"As a leading hospital in the Henan province, we should take the responsibility to spread the technology and knowledge of intervention, and support them when they perform interventional procedures."

Prof. Xinwei Han, MD,
Zhengzhou University Hospital,
Henan, China

minimally invasive interventional radiology is still under-utilized in Henan province. Prof. Han, who entered the interventional radiology field in 1992, believes that with the newest technologies available on interventional imaging equipment, it is desirable to conduct the majority of special diagnoses and treatment using minimally invasive technologies and that this represents the main future trend in the Chinese healthcare system.

There are currently five Artis imaging systems operating at Zhengzhou University First Affiliated Hospital. Of these, the two Artis zeego systems were installed in 2009 and 2012 respectively. "These five systems are in use for 24 hours a day, with doctors working in shifts. The Artis zeego robots don't rest, and there are too many patients." Last year, Prof. Han and his team of 161 doctors and nurses completed 9,300 procedures, with expectations to complete 12,000 this year.

Prof. Han's Flower Gift

Prof. Han believes that; "as a leading hospital in the Henan province, we should take the responsibility to spread the technology and knowledge of intervention, and support them when they perform interventional procedures. In this way, the regional hospitals can do the straight-forward interventions and we, Zhengzhou University Hospital can focus on the more challenging cases. This will benefit our patients and staff alike."

Prof. Han clearly takes this responsibility to heart as he frequently travels to different parts of Henan province to educate his colleagues. He does this out of his own pocket and using his own vacation time. When asked why, Prof. Han replies with; "A little bit of fragrance always clings to the hands that give the flowers."

A Dream of Red Mansions

Interventional technology can treat many illnesses that were in the past untreatable, previously required an operation, or for which treatment was ineffective. Prof. Han stated: "With interventional treatment the incision is small, the procedure is very effective, and it is reasonably priced. It achieves the ideals I sought as a graduate of medicine to utilize the simplest, most scientific, and affordable medical technology to address patient illness. I often think of the classic Chinese story 'A Dream of Red Mansions' by Cao Xueqin (1715-1763), and the beautiful female character Lin Daiyu who died of hemoptysis. If interventional treatment had been invented then, she could have gone to the hospital and lived happily ever after."

Chen Yi is an award-winning author and Senior Reporter at Economic Daily, one of China's most-read business publications.

Contact

penelope.vos@siemens.com

CARE+CLEAR: Standard with Every Artis System

You Can't Haggle Over Radiation Protection

In recent years, many interventional procedures have become longer, more frequent, and more complex. That's why the need to reduce dose is increasingly important for both patients and clinical staff. In many cases, however, image quality is the key for successful procedures. A dilemma? Not with CARE+CLEAR, a comprehensive portfolio of image-quality and dose-saving tools. Because every patient and every case is different, only interventionalists can decide on the image quality they need – and then determine the lowest possible dose. AXIOM Innovations spoke with representatives from three different disciplines about their experiences with the CARE+CLEAR features.

It has been known for over 80 years that high doses of ionizing radiation can cause tissue damage. An increasingly harder line has been taken when weighing the benefits and risks associated with radiation. The International Commission on Radiological Protection (ICRP) has been dealing with all aspects of radiological protection since 1928. It now recommends that all radiological exposure over and above natural background radiation levels must be kept as low as possible and must lie below an individual radiation threshold, which has been set at 1 mSv per year for the general population.

An Ongoing Challenge for Manufacturers

We know that very high radiation doses in excess of 5,000 mSv[1], acting on the body within a short period of time, will lead to death in just a few days. Doses of over 100 mSv[1] can be harmful to the human organism and may contribute to an increased risk of cancer.

One guide for the development of low-radiation procedures is the statutory guidelines on the maximum permitted dose of radiation as approved by the International Commission on Radiological Protection. In an industrial context there are also agreements such as those of the Medical Imaging and Technology Alliance (MITA) in the US, in which manufacturers have agreed to develop their devices on the basis of established radiological protection requirements, to ensure that radiation exposure complies with the "ALARA" principle ("As Low As Reasonably Achievable", also known in some parts of the world as ALARP, i.e. "As Low As Reasonably Practicable").

"We should be concerned about everyone's well-being. And if we can generate better images using less radiation, then it makes sense for us to do so."

Prof. Ansgar Berlis, MD

Chief Physician Diagnostic and Interventional Neuroradiology at the Klinikum Augsburg

[1] http://www.medicalradiation.com

What "as low as reasonably practicable" actually means is best known by the practitioners themselves, the treatment providers who deal with different people and different diagnoses on a daily basis and whose interest it is to help people by using radiation sensibly and responsibly. We asked these professionals how they deal with the dilemma of achieving an ideal level of image quality while keeping the dose as low as possible. And we wanted to find out how much the CARE+CLEAR features helped in this task.

Radiation Protection for Patients and Staff

When asked whether he thought the CARE+CLEAR features should be supplied as standard or offered as an option, Prof. Ansgar Berlis, MD, Chief Physician Diagnostic and Interventional Neuroradiology at the Klinikum Augsburg, answered with another question: "Who would drive an automobile today without a seatbelt and an airbag?" He believes that manufacturers must look after the safety of both patients and medical staff. In Prof. Berlis' view, this type of safety system can determine whether or not a sale is made, and should be considered a quality criterion. This opinion is shared by his colleagues, Prof. Thomas Albrecht, MD, Head Physician at the Institute for Radiology and Interventional Therapy at the Vivantes Klinikum Neukölln, and Olaf Göing, MD, Head Physician Internal Medicine at the Sana Klinikum, Berlin, specializing in cardiology. Göing has a particularly radical perspective when it comes to radiological protection: "These days, when we have a better understanding of the connections between radiation dose and potential illness than we did previously, features that enable us to reduce the dose of radiation should be provided as a matter of course. There should not even be the possibility of choosing differently just to cut costs." He continued: "I will grant that as a young doctor and later as a cardiologist, I did not take these problems seriously enough. I take a totally different view now. If I were buying a new cath lab I would classify dose-reduction features as a fixture, if the case arose. All other options depend on financial and medical necessity, and can still be negotiated, unlike radiation protection."

Prof. Albrecht works at the Vivantes Klinikum Neukölln, a maximum care facility with about 1,100 beds and an equally broad range of treatment fields. The focus of the work done there, besides peripheral intervention, includes oncological intervention and embolization of hemorrhages. He considers that "radiation protection goes without saying," and in this regard is thinking not just of his patients' well-being but also that of his team: "Many interventions these days take several hours, with correspondingly long periods of X-ray exposure. Reducing the dose is essential in these cases, especially for the staff."

CAREposition and CAREprofile are the Stars of the Scene

The clear line presented by the experts shows that Siemens is on the right path with its decision to provide dose-saving and image-processing tools as standard with its Artis systems, and that it is in fact setting a clear direction. Because some competitors are still offering comparable packages on an optional basis, Siemens is going a step further and taking on a pioneering role: the CARE+CLEAR package, which currently contains 17 features, has been growing constantly since 1994 and comes as standard with every Artis system. Siemens is thus concentrating fully on the interests of those providing the treatment, which are many and varied.

For cardiologist Olaf Göing, MD, for instance, CAREposition and CAREprofile help establish the correct setting for the devices in relation to the patient's anatomy with particular speed. He makes most use of the ability to set an individual pulse rate with CAREvision. "This makes it possible to 'power down' when handling slim patients and 'power up' for very adipose patients, to avoid having to

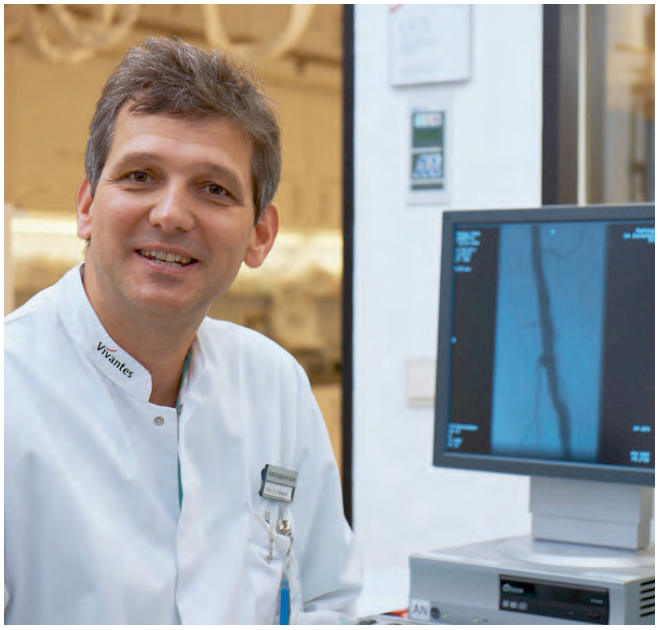

"I consider minimizing radiological exposure for the intervention personnel to be a matter of key concern. In this connection, progress in the area of device technology must be supplemented by observance of radiological protection measures by the staff."

Prof. Thomas Albrecht, MD

Head Physician at the Institute for Radiology and Interventional Therapy at the Vivantes Klinikum Neukölln

accept a loss of information. CAREposition and CAREprofile help find the right position for the tubes or detectors and the collimation and filter with regard to the part of the patient's anatomy that has to be displayed, without having to resort to X-rays, and we use them accordingly."

Conversely, in the area of neurointervention, procedures may be very lengthy. However, it is now possible to treat aneurysms, including full cerebrovascular diagnosis and treatment, in under an hour. Dr. Berlis describes the advantages of the CARE+CLEAR features in this regard: "Table and tubes can be moved with no requirement for X-rays. We can plan treatment within seconds after preparing a rotational angiogram." He adds: "These short intervention times also mean short X-ray times and reduced risks of treatment, which increase with the length of time taken by the intervention process."

In interventional radiology it is standard practice to work with low-dose programs in all parts of the body. The CARE+CLEAR features provide a benefit "for all interventions, actually," in Prof. Albrecht's view. From his perspective, too, however, the stars are the CAREprofile (using the Last Image Hold (LIH) as a reference, CAREprofile enables radiation-free collimator and semitransparent image filter adjustment. As a result, dose reductions can be achieved), and CAREposition (based on the LIH, a graphical outline of the upcoming image is displayed on the monitor, allowing you to move the table or C-arm without needing any radiation. As patients can be positioned without additional fluoroscopy, dose reductions are possible – making CAREposition an ideal choice for long procedures).

Save on Radiation Dose by All Means – But not at the Expense of Image Quality

Whether your patients are tall or short, obese or slender – interventionalists need to see. And in order to see, they need optimal image quality. Dr. Berlis can confirm that the extensive options to save on dose do not come at the cost of reduced image quality: "The low-dose programs are not only sufficient for normal patients, but also offer the best image quality." In his experience, there has been relatively little need for high-dose programs, since even with corpulent patients the low-dose programs are sufficient in the head and neck area. They are only needed when the spinal column is involved.

The low-dose programs are used both for diagnostic vascular imaging and during actual intervention. Prof. Berlis explained: "In diagnostic angiography procedures, the image frequency can be reduced when advancing the catheter and examining the supra-aortic vessels, which also means that the dose can be reduced. An image frequency of 15 per second is used during interventions and when examining minuscule vessels. At this speed the motion is sufficiently continuous for the human eye, which enables the microcatheter to be positioned down to the nearest millimeter." The CLEAR applications automatically increase certainty during interventions by keeping image quality high.

Awareness is Changing

The CLEAR applications are finally being combined with the CARE features, which have undergone constant development since 1994, and are now offered as a single package. The Combined Applications to Reduce Exposure (CARE) are simple: They are designed to help you deliver better care at the lowest reasonable dose. CARE does more than focus on patient well-being, however.

For the experts it is important to provide protection for their own teams: "Both patients and physicians want to know what dose of radiation to expect with a CT or cardiac catheterization procedure and any potential intervention. Everyone involved is more informed than was previously possible," said Dr. Göing. Prof. Berlis added: "We are talking about protecting the patients, but also ourselves and our employees. We should be concerned about every-

"With the Artis dose-monitoring features, skin dose control is easy and efficient. State-of-the art reporting solutions enable efficient and transparent reporting and documentation of radiation dose."

Olaf Göing, MD

Head Physician Internal Medicine at the Sana Klinikum, Berlin

one's well-being. And if we can generate better images using less radiation, then it makes sense for us to do so."

He offers an example to show that the population as a whole is becoming more aware of radiological exposure: "More and more patients ask after the event whether the radiation dose they were given was significant. There is a key point that we must note here: the system makes it possible to demonstrate not just the dose, but also the dose for particular table settings. Two years ago I treated an arteriovenous malformation (AVM) in the brain of a young female patient who discovered six weeks later that she was pregnant when the surgery was performed. Calculation of the uterine dose showed this to be virtually zero, since I initially X-rayed this young lady in the region of the aortic arch. The physicist on our team could see this based on the device settings, and was surprised at the same time that no X-ray of the groin had been taken."

Protecting Employees is of Maximum Importance

For manufacturers of devices for medical imaging, the important principle in the development process is that users must obtain the best possible image quality but the radiation dose must be kept as low as possible at the same time, since the actual effects cannot be established with total certainty even for low radiation doses, below 100 mSv, for instance. Further technical innovations are constantly needed to achieve these goals, as well as effective training for the radiology staff, to ensure that the devices are used correctly.

Prof. Berlis' neuroradiology team currently performs more than 300 interventions on patients each year. These include about 100 acute stroke treatments, 100-120 aneurysms and 50 arteriovenous malformations affecting the spinal column and brain. "Reducing the dose helps not only the patient but also the intervention team, which includes the interventionalist, the assistants, the medical technical radiology assistants and the anesthesiology team." This is precisely why radiological protection is considered so important at the Augsburg Clinic. The structures are set up to enable the patient to be monitored outside the examination room, and the anesthesiology team enters the examination room only when needed – to administer medication, for instance. Additional lead-lined walls on rollers protect the intervention and anesthesiology team.

Prof. Albrecht appeals to the individual responsibility of each of his colleagues: "They are not always as attentive to their own radiation exposure as I would prefer for myself. I consider minimizing radiation exposure for the intervention personnel to be a matter of key concern. In this connection, progress in the area of device technology must be supplemented by observance of radiation protection measures by the staff." Dr. Göing agrees, since he understands the task only too well: "Protecting employees as part of our 'constant activity' in the cardiac catheterization laboratory cannot be rated highly enough."

For more information please visit our CARE+CLEAR website

Further Information

www.siemens.com/care-clear

Contact

helene.huebner@siemens.com

Upcoming Congresses 2014

We always like to give you the opportunity to get in "touch" with the real system, and learn more about system handling to keep you in step with the latest technological advances. You have the chance to experience our technology at international congresses, trade fairs, and workshops. In the list below you will find information on various events where we offer you the opportunity to meet AX.

Title	Location	Short Description	Date	Contact
RSNA	Chicago, USA	Radiological Society of North America	Dec 01 – 06	http://www.rsna.org/
ALICE	Essen	Advanced Life International Course in Essen	Dec 04 – 06	http://www.alice-the-course.com/
LTCS Leipzig	Leipzig, Germany	Latest Techniques in Cardiac Surgery	Dec 05 – 07	http://www.ltcs-leipzig.com/
CSI	Bangalore, India	Computer Society of India	Dec 13 – 15	http://csianc2013.csi-vizag.org/
Boston AFIB	Orlando, USA	Boston Atrial Fibrillation Symposium	Jan 09 – 11	http://www.afsymposium.com/
Asia PCR, SingLIVE	Singapore	Asia-Pacific cardiovascular community	Jan 16 – 18	http://www.asiapcr.com/
ISET	Miami Beach, USA	International Symposium on Endovascular Therapy	Jan 18 – 22	http://www.iset.org/
STS	Orlando, USA	Society of Thoracic Surgery	Jan 25 – 29	http://www.sts.org/
Arab Health	Dubai, UAE	Healthcare Exhibition & Congress	Jan 27 – 30	http://www.arabhealthonline.com/
LINC	Leipzig	Leipzig Interventional Course	Jan 28 – 31	http://www.linc2014.com/
ISC	San Diego, USA	International Stroke Conference	Feb 12 – 14	http://www.strokeconference.org
Cadeci	Guadalajar, Jalisco, Mexico	Congreso Anual de Cardiologia Internacional	Feb 20 – 22	http://cadeci.org.mx/
ECR	Vienna, Austria	Annual Meeting, European Society of Radiology	Mar 06 – 10	http://www.myesr.org
AAOS	New Orleans, USA	American Academy of Orthopedic Surgeons	Mar 10 – 15	http://www.aaos.org/
CIT	Shanghai, China	China Interventional Therapeutics Conference	Mar 20 – 23	http://www.citmd.com
SIR	San Diego, USA	Society of Interventional Radiologists including sponsorships	Mar 23 – 28	http://www.sirmeeting.org/
China Med	Beijing, China	International Medical Instruments & Equipment Exhibition	Mar 27 – 29	http://www.eventseye.com/fairs/f-china-med-3391-1.html
ACC	San Francisco, USA	American College of Cardiology	Mar 29 – 31	http://www.acc.org
ASCVTS	Istanbul, Turkey	Annual Meeting of the Asian Society for Cardiovascular and Thoracic Surgery	Apr 03 – 06	http://www.ascvts2014.org/en/default.asp
Charing Cross	London, UK	Vascular & Endovascular Consensus Update	Apr 05 – 08	http://www.cxsymposium.com
AANS	San Francisco, USA	Annual Scientific Meeting, American Association of Neuro Surgeons	Apr 05 – 10	http://www.aans.org/annualmeeting.aspx
EAU	Stockholm, Sweden	Annual Congress, European Association of Urology	Apr 11 – 15	http://www.eaustockholm2014.org/
ITEM	Yokohama, Japan	International Technical Exhibition of Medical Imaging	Apr 12 – 14	http://www.j-rc.org/jrc/

Title	Location	Short Description	Date	Contact
CMEF	Shenzhen, China	China International Medical Equipment Fair	Apr 17 – 20	http://en.cmef.com.cn
SOLACI	Buenos Aires, Argentina	Sociedad Latino Americana De Cardiologia Intervencionista	April 23 - 25	http://www.solacicongress.org/
DGK	Mannheim, Germany	Annual Conference, Deutsche Gesellschaft für Kardiologie – Herz- und Kreislaufforschung e.V.	Apr 23 – 26	http://www.dgk.org
ECIO	Berlin, Germany	Cardiovascular and Interventional Radiological Society of Europe	Apr 23 – 26	http://www.ecio.org/?pid=82
AATS	Toronto, Canada	Annual Meeting, American Association for Thoracic Surgery	Apr 26 – 30	http://www.aats.org/
WCC	Melbourne, Australia	World Congress of Cardiology	May 04 – 07	http://www.world-heart-federation.org/congress-and-events/world-congress-of-cardiology-scientific-sessions-2014/
ESC	Nice, France	European Stroke Conferenc	May 04 – 09	http://www.eurostroke.eu/
HRS	San Francisco, USA	Heart Rhythm Society	May 07 – 10	http://www.heartrhythmsupport.org/
WCIO	New York, USA	Interventional Oncology Community	May 12 – 14	http://www.io-central.org/p/cm/ld/fid=169
APCCVIR	Singapore, Singapur	Asian-Pacific Congress of Cardiovascular and Interventional Radiology	May 15 – 18	http://apccvir2014.com/
AUA	Orlando, USA	Annual Meeting, American Urological Association	May 16 – 21	http://www.aua2014.org/
EuroPCR	Paris, France	Cardiovascular Course	May 20 – 23	http://www.europcr.com
AEPC	Helsinki, Finland	Annual Meeting, Association for European Paediatric and Congenital Cardiology	May 21 – 24	http://www.aepc2014.fi/
DRK	Hamburg, Germany	Deutscher Röntgenkongress	May 28 – 31	http://www.roentgenkongress.de/
EFORT	London, UK	European Federation of National Associations of Orthopaedics and Traumatology	Jun 04 – 06	https://www.efort.org/london2014/
SVS	Boston, USA	Vascular Annual Meeting, Society for Vascular Surgery	Jun 05 – 07	http://www.vasculardiseasemanagement.com/events/society-vascular-surgery-vascular-annual-meeting-2014-svs
WLNC	Buenos Aires, Argentina	World Live Neurovascular Conference	Jun 09 – 11	http://www.wlnc.net/en/_WLNC-2014.html
ESTS	Copenhagen, Denmark	European Conference, European Society of Thoracic Surgeons	Jun 15 – 18	http://www.ests.org/council_committee/27/ests_annual_meeting_committee_copenhagen_2014
IMAST	Valencia, Spain	International Meeting on Advanced Spine Techniques	Jun 16 – 19	http://www.srs.org/imast/2013/
Cardiostim	Nice, France	World Congress in Cardiac Electrophysiology and Cardiac Techniques	Jun 18 – 21	http://www.cardiostim.com/
ESC	Barcelona, Spain	European Society of Cardiology	Aug 30 – Sep 02	http://www.escardio.org/congresses
AAST	Philadelphia, USA	American Association for the Surgery and Trauma	Sep 10 – 13	http://www.aast.org/AnnualMeetings/FutureMeetings.aspx
CIRSE	Glasgow, UK	Cardiovascular and Interventional Radiological Society of europe	Sep 13 – 17	http://www.cirse.org/

Siemens Healthcare Publications

Our publications offer the latest information and background for every healthcare field. From the hospital director to the radiological assistant – here, you can quickly find information relevant to your needs.

Medical Solutions
Innovations and trends in healthcare. The magazine is designed especially for members of hospital management, administration personnel, and heads of medical departments.

Heartbeat
Everything from the world of sustainable cardiovascular care.

Imaging Life
Everything from the world of molecular imaging innovations.

MAGNETOM Flash
Everything from the world of magnetic resonance imaging.

SOMATOM Sessions
Everything from the world of computed tomography.

For more information please visit our AXIOM Innovations website

AXIOM Innovations Online
Read online at:
www.siemens.com/axiom-innovations

For this and other magazines from Siemens Healthcare, please visit
www.siemens.com/healthcare-magazine

AXIOM Innovations

Publisher:
Siemens AG
Medical Solutions
Angiography & Interventional
X-Ray Systems
Siemensstr. 1, 91301 Forchheim, Germany

Responsible for Contents:
Heinrich Kolem, PhD

Chief Editor:
Nadine Meru, PhD
nadine.meru@siemens.com

Production:
Michael Brumme, Siemens Healthcare,
Erlangen, Germany

Design:
Agentur Baumgärtner,
Fürth, Germany

Printer:
infowerk GmbH
Wiesentalstr. 40, 90419 Nürnberg

G. Peschke, Druckerei GmbH,
Schatzbogen 35, 81829 München

AXIOM Innovations on the Internet:
www.siemens.com/axiom-innovations

On account of certain regional limitations of sales rights and service availability, we cannot guarantee that all products included in this brochure are available through the Siemens sales organization worldwide. Availability and packaging may vary by country and are subject to change without prior notice. Some / All of the features and products described herein may not be available in the United States or other countries.

The information in this document contains general technical descriptions of specifications and options as well as standard and optional features that do not always have to be present in individual cases.

Siemens reserves the right to modify the design, packaging, specifications and options described herein without prior notice. Please contact your local Siemens sales representative for the most current information.

In the interest of complying with legal requirements concerning the environmental compatibility of our products (protection of natural resources and waste conservation), we recycle certain components. Using the same extensive quality assurance measures as for factory-new components, we guarantee the quality of these recycled components.

Note: Any technical data contained in this document may vary within defined tolerances. Original images always lose a certain amount of detail when reproduced.

For product accessories see:

www.siemens.com/medical-accessories

The statement by Siemens' customers described in this magazine are based on results that were achieved in the customer's unique setting. Since there is no "typical" hospital and many variables exist (e.g., hospital size, case mix, level of IT adoption) there can be no guarantee that other customers will achieve the same results.

Global Siemens Headquarters

Siemens AG
Wittelsbacherplatz 2
80333 Munich
Germany

Global Siemens Healthcare Headquarters

Siemens AG
Healthcare Sector
Henkestrasse 127
91052 Erlangen
Germany
Phone: +49 9131 84-0
www.siemens.com/healthcare

Legal Manufacturer

Siemens AG
Wittelsbacherplatz 2
DE-80333 Muenchen
Germany

Artis one
Siemens Shenzhen Magnetic Resonance Ltd.
Siemens MRI Center,
Gaoxin C. Ave., 2nd,
Hi-Tech Industrial Park
518057 Shenzhen,
China

Global Business Unit

Siemens AG, Medical Solutions
Angiography & Interventional X-Ray Systems
Siemensstr. 1
DE-91301 Forchheim
Germany
Phone: +49 9191 18-0
www.siemens.com/healthcare

Artis one
EU Authorized Representative
Siemens AG
Medical Solutions
Henkestrasse 127
D-91052 Erlangen
Germany

Local Contact Information

Asia/Pacific:
Siemens Medical Solutions
Asia Pacific Headquarters
The Siemens Center
60 MacPherson Road
Singapore 348615
Phone: +65 9622-2026
www.siemens.com/healthcare

Canada:
Siemens Canada Limited
Medical Solutions
2185 Derry Road West
Mississauga ON L5N 7A6
Canada
Phone: +1 905 819-5800
www.siemens.com/healthcare

Europe/Africa/Middle East:
Siemens AG, Medical Solutions
Henkestr. 127,
DE-91052 Erlangen
Germany
Phone: +49 9131 84-0
www.siemens.com/healthcare

Latin America:
Siemens S.A.,
Medical Solutions
Avenida de Pte. Julio A. Roca No 516, Piso 7
C1067ABN Buenos Aires
Argentina
Phone: +54 11 4340 8400
www.siemens.com/healthcare

USA:
Siemens Medical Solutions U.S.A., Inc.
51 Valley Stream Parkway
Malvern, PA 19355-1406
USA
Phone: +1-888-826-9702
www.siemens.com/healthcare

Order No. A91AX-51402-01M1-7600 | Printed in Germany | CC AX 1697 121312. |

www.siemens.com/angiography