

Simultaneous Multi-Slice Accelerated Free-Breathing Diffusion-Weighted Imaging in Abdomen and Pelvis

Chika Obele, M.D.¹; Himanshu Bhat, Ph.D.²; Hersh Chandarana, M.D.¹

¹ Department of Radiology, NYU School of Medicine, New York, NY, USA

² Siemens Healthcare, MR R&D Collaborations, Charlestown, MA, USA

Abstract

Accelerated free-breathing diffusion-weighted imaging of the abdomen and pelvis is feasible with simultaneous multi-slice acquisition with maintained integrity of the diagnostic image quality. In this article we show clinical examples where the accelerated SMS technique was noted to decrease acquisition time by approximately 40%.

Introduction

Diffusion-weighted imaging (DWI) offers many benefits in abdomen and pelvis imaging particularly for evaluation of several abdominopelvic diseases such as focal and diffuse liver disease, prostate cancer, focal renal disease, and uterine cancer [1, 2]. There are also several investigational applications showing the importance of DWI in assessment of tumor response [3, 4] and predicting the aggressiveness of some tumors

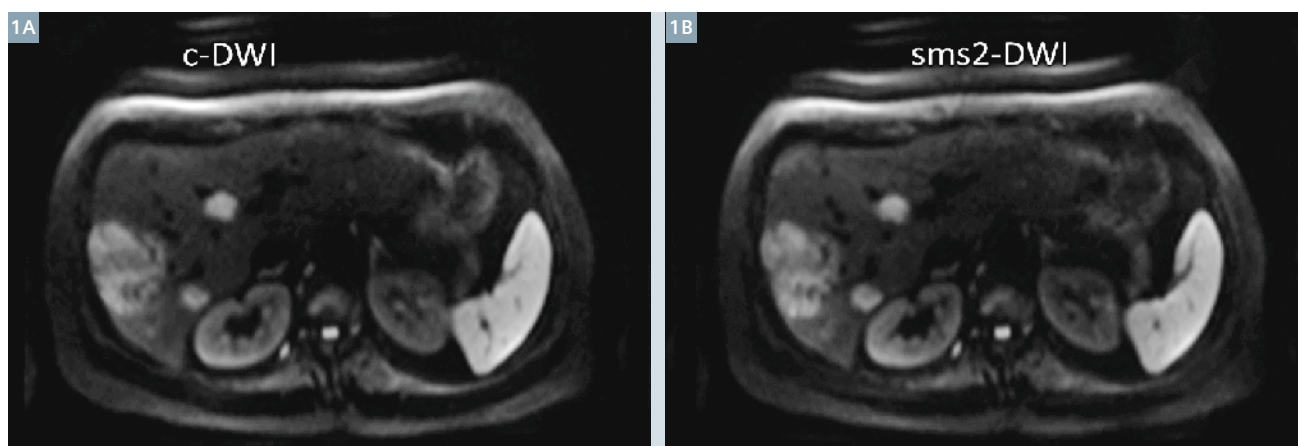
such as bladder cancer [5, 6]. Given the many benefits and potential applications of DWI in the abdomen and pelvis, in addition to the ease in which it can be integrated into existing clinical protocols, DWI has become a commonly used MRI sequence and an integral part of our abdominopelvic MR imaging protocols.

Conventional DWI using single-shot spin-echo echo-planar (SS EPI) technique can be acquired in multiple ways including a free-breathing (FB) technique with or without navigator and with multiple breath-hold (BH) technique [1]. The BH technique is constrained by the breath-hold capacity of the patient and thus is limited in the number of b-values that can be acquired, the resolution that can be achieved, and has low signal-to-noise ratio (SNR) due to inability to acquire multiple averages given the time constraints. The FB techniques are limited due to long

acquisition time and inefficiency of the navigated scheme. FB acquisition with multiple averages (instead of navigator) is a preferred compromise at our institution as this is faster than the navigated acquisition scheme and is shown to have better image quality and higher resolution compared to the breath-hold acquisition. Despite the use of parallel imaging techniques like GRAPPA for in-plane acceleration, there is a need to further accelerate FB DWI acquisition. Recent introduction of the simultaneous multi-slice (SMS) DWI technique has the potential to further speed-up DWI acquisition [7]. We will briefly discuss the SMS technique below and share our clinical experience for abdominal and pelvic DWI imaging with SMS acquisition scheme.

SMS: basics and principle

SMS relies on exciting multiple slices simultaneously and reconstructing them individually using the slice



1 55-year-old female with weight loss. Multiple hyperintense liver lesions are demonstrated on both the DWI acquisition schemes. The acquisition time for SMS2-DWI (**1B**) was approximately 40% shorter than the conventional acquisition scheme (**1A**).

GRAPPA method. Since multiple slices are excited simultaneously the overall TR for a desired spatial coverage is reduced, leading to scan time reduction by the same factor. In order to minimize the g-factor SNR penalty during slice GRAPPA reconstruction, the blipped-CAIPIRINHA scheme is used to impart a relative FOV shift in the phase encoding direction between the simultaneously excited slices [7]. One key aspect of SMS compared with other acceleration techniques is that it does not suffer from the typical square-root of acceleration factor SNR penalty due to data under-sampling. Further technical details about SMS acquisition and reconstruction can be found elsewhere in this publication.

Abdominal SMS diffusion-weighted imaging

Liver MRIs were conducted on a clinical 3T system with peak gradient amplitude of 45 mT/m and slew rate of 200 T/m/s (MAGNETOM Skyra,

Siemens Healthcare, Erlangen, Germany). The scan was performed using an 18-channel body matrix receive coil. A routine liver protocol was utilized including pre-contrast DWI. DWI was performed with transverse free-breathing single-shot echo-planar (EP) acquisitions with monopolar tri-directional trace weighting diffusion gradients (Fig. 1). Two different acquisition schemes were used as below.

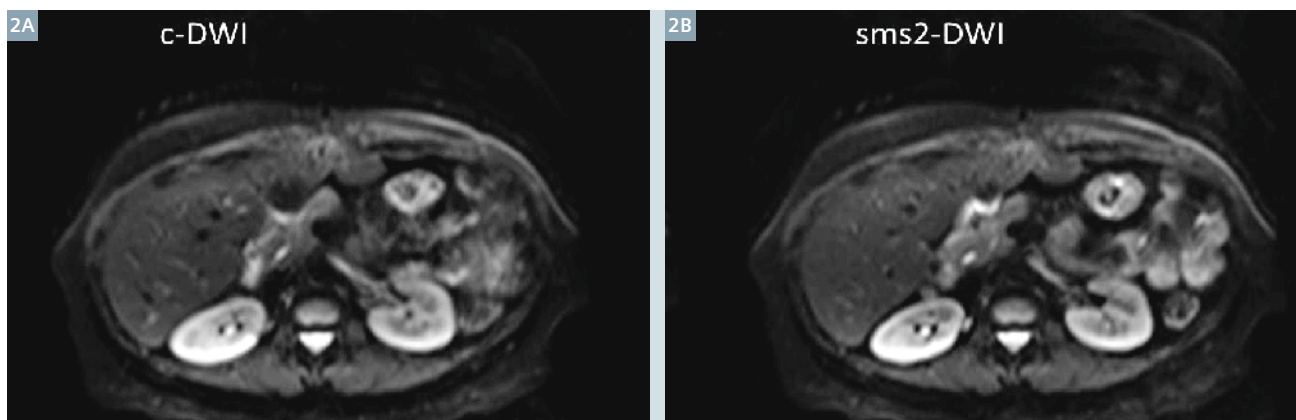
Conventional DWI (c-DWI):

TR 4500 ms, TE 66 ms, matrix 164 x 123, voxel size (interpolated) 2.3 x 2.3 x 5 mm, 34 axial 5 mm slices with inter-slice gap of 0.5 mm, bandwidth 1386 Hz/pix, parallel imaging acceleration factor of 2, 3 b-values (0, 400, and 800 s/mm²), and 4 averages; and acquisition time of 2:29 minutes.

SMS DWI with twofold acceleration (SMS2-DWI): TR 2400 ms, TE 66 ms, matrix 164 x 123, voxel size (interpolated) 2.3 x 2.3 x 5 mm, 34 axial

5 mm slices with inter-slice gap of 0.5 mm, bandwidth 1386 Hz/pix, parallel imaging acceleration factor of 2, 3 b-values (0, 400, and 800 s/mm²), and 4 averages. Two slices were acquired simultaneously using blipped-CAIPIRINHA (slice shift = $FOV_{phase}/3$) and individual slices are reconstructed using slice GRAPPA reconstruction. With SMS2-DWI TR was reduced to 2400 msec (from 4500 msec with conventional DWI), resulting in decrease in acquisition time of approximately 40% to 1:28 minutes.

Clinical scenario 1: A 55-year-old female with weight loss was found to have multiple inconclusive lesions on liver ultrasound. Multiple hyper-intense liver lesions are demonstrated on both DWI acquisition schemes. The acquisition time for SMS2-DWI was approximately 40% shorter than the conventional acquisition scheme (Fig. 1).



2 50-year-old Asian woman post liver transplantation for HBV cirrhosis and hepatocellular carcinoma. MRI of transplanted liver demonstrates comparable image quality between the two acquisition schemes but with 45% shorter scan time with accelerated SMS acquisition (2B).

Clinical scenario 2: 50-year-old Asian woman post liver transplantation for Hepatitis B virus-related (HBV) cirrhosis and hepatocellular carcinoma. MRI of transplanted liver demonstrates comparable image quality between the two acquisition schemes but with 40% shorter scan time with accelerated SMS.

Pelvic SMS diffusion-weighted imaging

Patients underwent pelvis MRI on a clinical 3T system with peak gradient amplitude of 45 mT/m and a slew rate of 200 T/m/s (MAGNETOM Skyra, Siemens Healthcare, Erlangen, Germany). A routine pelvis protocol was utilized including pre-contrast DWI. DWI was performed with trans-

verse free-breathing single-shot echo-planar (EP) acquisitions with monopolar tri-directional trace weighting diffusion gradients (Fig. 3). Two different acquisition schemes were used as below.

Conventional DWI (c-DWI):

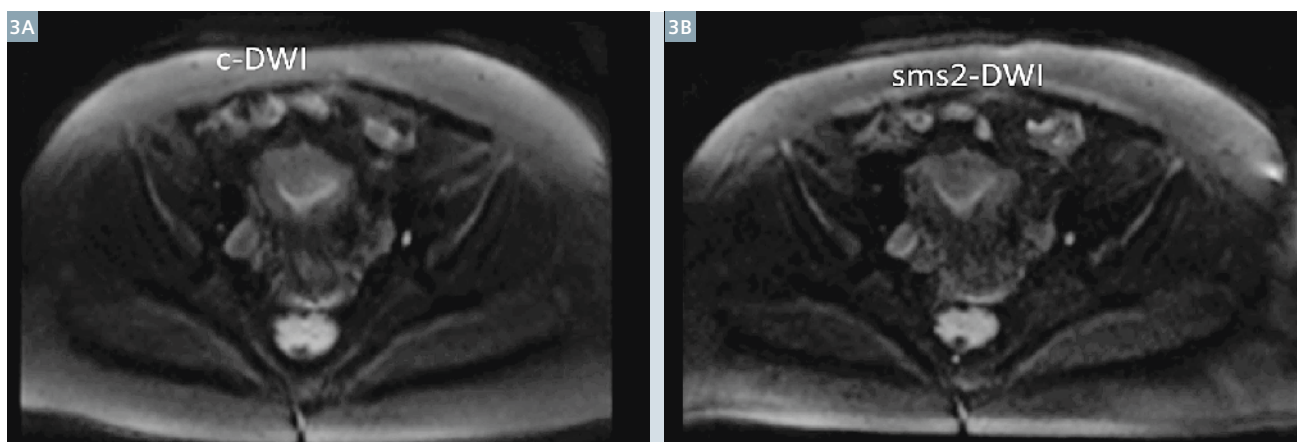
TR 5600 ms, TE 54 ms, matrix 164 x 164, voxel size (interpolated) 2.3 x 2.3 x 6 mm, 25 axial 6 mm slices with inter-slice gap of 0.6 mm, bandwidth 2032 Hz/pix, parallel imaging factor of 2, 5 b-values (0, 50, 100, 400, and 800 s/mm²), and 4 averages for acquisition time of 5:08 minutes.

SMS DWI with twofold acceleration (SMS2-DWI):

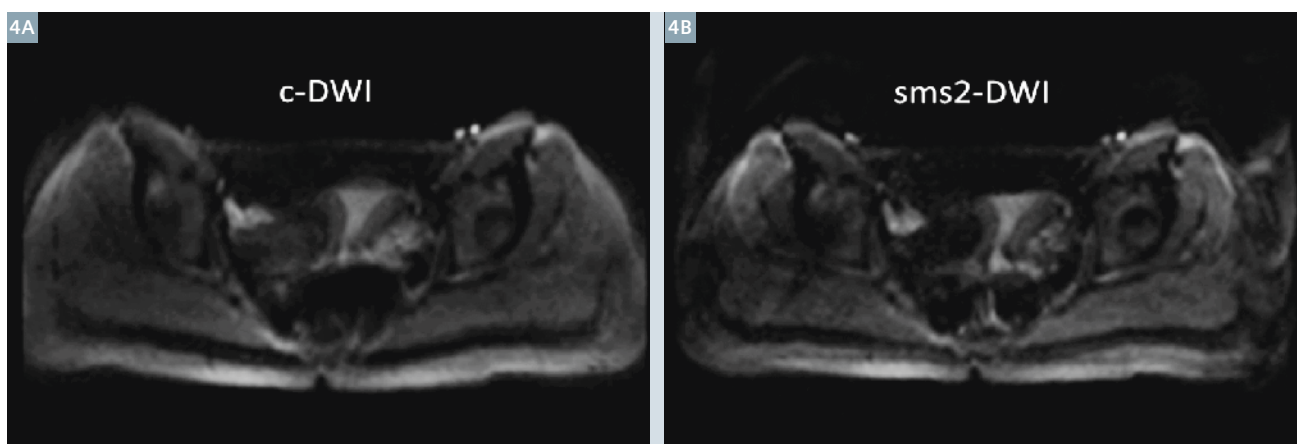
TR 2700 ms, TE 54 ms, matrix 164 x 164, voxel size (interpolated) 2.3 x 2.3 x 6 mm, 25 axial 6 mm slices with inter-slice gap of

0.6 mm, bandwidth 1681 Hz/pix, parallel imaging factor of 2, 5 b-values (0, 50, 100, 400, and 800 s/mm²), and 4 averages, for acquisition time of 2:42 minutes. Two slices were acquired simultaneously using blipped-CAIPIRINHA (slice shift = FOV_{phase}/3) and individual slices are reconstructed using slice GRAPPA reconstruction. With accelerated SMS acquisition TR was reduced to 2700 msec from 5600 msec for conventional acquisition. This resulted in ~ 45% decrease in acquisition time.

Clinical scenario 3: A 42-year-old female with history of endometriosis presented with abdominal pain. The DWI images were similar, with approximately 45% reduction in imaging time with SMS2-DWI (Fig. 3).



3 42-year-old female with history of endometriosis presented with abdominal pain. The image quality of c-DWI (3A) and SMS2-DWI (3B) is similar but with approximately 45% decrease in acquisition time with SMS2-DWI.



4 22-year-old female patient with increasing dysmenorrhea and enlarging left ovary cyst. MRI demonstrates comparable image quality between the conventional DWI (4A) and SMS DWI (4B) technique with near 45% reduction in acquisition time with SMS2-DWI.

Case scenario 4: 22-year-old female patient with increasing dysmenorrhea and enlarging left ovary cyst. MRI demonstrates comparable image quality between the conventional DWI and SMS DWI technique with approximately 45% reduction in acquisition time with SMS-DWI (Fig. 4).

Conclusion

We have incorporated SMS DWI with 2-fold acceleration in our clinical protocol for abdominopelvic imaging which has allowed us to achieve near two-fold acceleration in free-breathing DWI acquisition with multiple averages. These time-savings can be used to either improve volumetric coverage or resolution of the DWI or shorten the overall exam time.

References

- 1 Taouli, B. and D.M. Koh, Diffusion-weighted MR imaging of the liver. *Radiology*, 2010. 254(1): p. 47-66.
- 2 Qayyum, A., Diffusion-weighted imaging in the abdomen and pelvis: concepts and applications. *Radiographics*, 2009. 29(6): p. 1797-810.
- 3 Koh, D.M., et al., Predicting response of colorectal hepatic metastasis: value of pretreatment apparent diffusion coefficients. *AJR Am J Roentgenol*, 2007. 188(4): p. 1001-8.
- 4 Kamel, I.R., et al., Unresectable hepatocellular carcinoma: serial early vascular and cellular changes after transarterial chemoembolization as detected with MR imaging. *Radiology*, 2009. 250(2): p. 466-73.
- 5 Rosenkrantz, A.B., et al., Whole-lesion diffusion metrics for assessment of bladder cancer aggressiveness. *Abdom Imaging*, 2015. 40(2): p. 327-32.
- 6 Kobayashi, S., et al., Diagnostic performance of diffusion-weighted magnetic resonance imaging in bladder cancer: potential utility of apparent diffusion coefficient values as a biomarker to predict clinical aggressiveness. *Eur Radiol*, 2011. 21(10): p. 2178-86.
- 7 Setsompop K., et. al. Blipped-controlled aliasing in parallel imaging for simultaneous multislice echo planar imaging with reduced g-factor penalty. *Magn Reson Med*. 2012 May;67(5):1210-24.
- 8 Obele, C.C., et al., Simultaneous Multislice Accelerated Free-Breathing Diffusion-Weighted Imaging of the Liver at 3T. *Abdom Imaging*, 2015.

Contact

Hersh Chandarana, M.D.
Department of Radiology
NYU School of Medicine
660 First Avenue
New York, NY 10016
USA
hersh.chandarana@nyumc.org

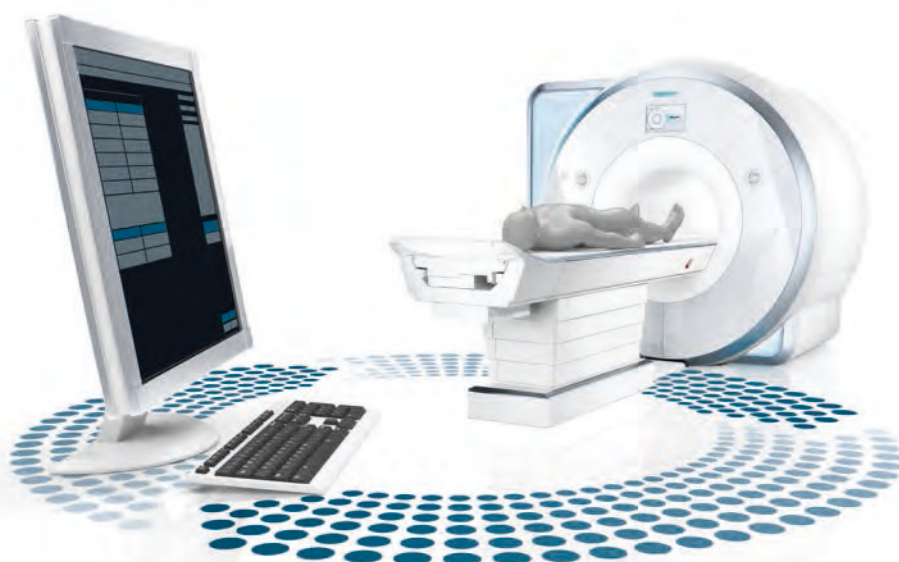

Did you know that ...

“With DotGO it’s going to be so much easier and quicker to build protocols on the fly and not interfere with taking table time away from the patients. Previously, to build a protocol from scratch would take 20 minutes. With DotGO, I was able to create a protocol in 45 seconds. Having consistency in our MRI protocols and examinations is extremely important. Our reputation is to provide the highest quality MRI examinations for our patients and referring physicians. DotGO will help us to do that.”

Anthony Pavone

Zwanger-Pesiri Radiology
(New York, USA)



More clinical articles, tips & tricks, talks
on Siemens unique Dot engines at

www.siemens.com/magnetom-world-dot