Reliable Imaging of Neurovasculature with Dot and T1 SPACE

Michel Paret[1]; Sylvain Doussin, Ph.D.[2]; Pr FG Barral, M.D.[3]; Dr C Boutet, M.D.[3]

[1] GIE IRMAS, Saint-Priest-en-Jarez, France
[2] Siemens Healthcare, Erlangen, Germany
[3] CHU Saint-Etienne, France

Research into the dissection of cervical-cerebral arteries is fundamental to clinical practice.

Any patient admitted to hospital with a suspected stroke should be given the benefit of an MRI. On the one hand this imaging technique allows the physician to diagnose whether the patient is suffering from a stroke, and on the other, it helps to establish the etiological diagnosis. It also affects the evolving prognosis of the patient because it allows the physician to decide on the best strategy for treating the patient. An MRI also allows the physician to detect early signs of vessel wall hematoma in a non-invasive way and to evaluate luminal abnormalities, if any.

Research into parietal hematoma

In the case of dissection of the cervical arteries, a morphological MRI is essential, since its aim is to look for a parietal hematoma.

Different MRI techniques allow the physician to visualize this hematoma: in 2D or 3D, T1 or T2, with or without fat saturation. The flux, the voluntary or involuntary movements of the patient are the source of significant artifacts in this anatomical area.

One protocol seems to be used for the most part: the 2D T1-weighted fat-saturated (FS) spin echo (SE) sequence with physiological synchronization of the pulse, carried out in a perpendicular direction on the vascular flow. At the sub-acute stage (about J3-J5), a rather eccentric hypersignal in the shape of a crescent surrounds the vessel lumen (presence of methemoglobin). At the acute stage, the wall appears thickened as an isosignal.

Cuvinciuc et al. [1] expressed interest in a 3D T1-weighted SPACE (Sampling Perfection with Application optimized Contrasts using different flip angle Evolution) sequence in contrast to a 2D T1w SE FS sequence. This 3D protocol, coupled with a fat saturation of the SPAIR type (SPectral Attenuated Inversion Recovery) and a Dark Blood technique offers robust data collection and good diagnostic sensitivity, even at the acute stage under difficult working conditions (a patient who does not cooperate).

This approach has been shown to have a higher sensitivity relative to the post-contrast T1 MPRAGE for the detection of brain lesions in multiple sclerosis (Fig. 1) [4, 5]. It also has a reliable role in the detection of tumors in the cervical region with its flexibility to enable reformatting in any plane (Fig. 2).

1 Multiple sclerosis brain lesions, color lookup table heart 16 bit.
(1A) t1_space_sag_INJ (green arrow),
(1B) t1_space_MPR TRA_INJ (green arrow),
(1C) t1_MPRAGE_sag_INJ 5' (black arrow),
(1D) t1_MPRAGE_MPR TRA_INJ 5' (black arrow).

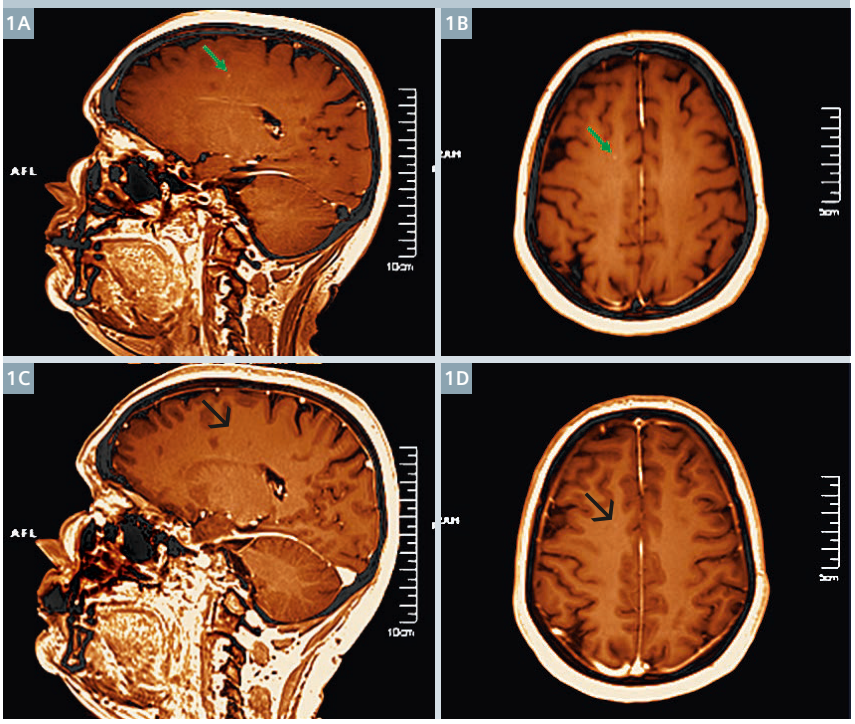

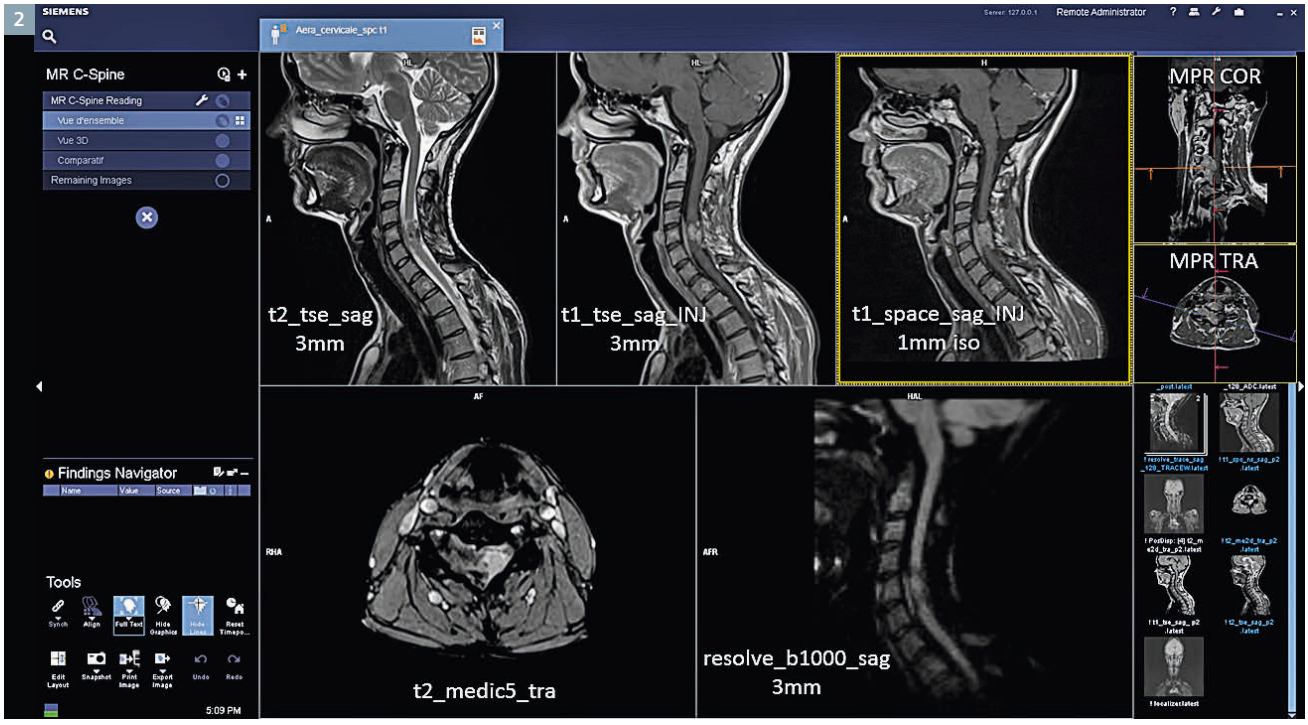

Acquisition protocol

Our doctors are often required to carry out these examinations in emergency cases. At our Regional Stroke Center, two MR systems are capable of collecting this type of data, a MAGNETOM Aera 1.5T and a MAGNETOM Spectra 3T.

In order to provide a service that can meet current demand, we have developed and programmed our own Dot engine from the standard Brain Dot Engine. Neurovascular imaging works in an identical way on the two systems so that we can offer a standardized treatment of patients. This Dot Engine has the same design and notably includes a 'dissection' decision (3D T1 SPACE Spair_db) (Fig. 3). The acquisition parameters are, however, specific to the individual system (contrast parameters, spatial and temporal resolution, etc.) (Fig. 4).

The Dot Engine complies with the official guidelines and enables all our 30 technologists, regardless of their level of experience, to carry out examinations without any difficulty and allows all our 70 radiologists to answer questions posed by our clinicians. For example, the slice positioning is set automatically using the AutoAlign Head>Brain function, the calculation of perfusion maps is automatic using Local AIF (arterial input function).

These examinations are visualized under *syngo*.via VB10A under a basic workflow with specific reading stages.

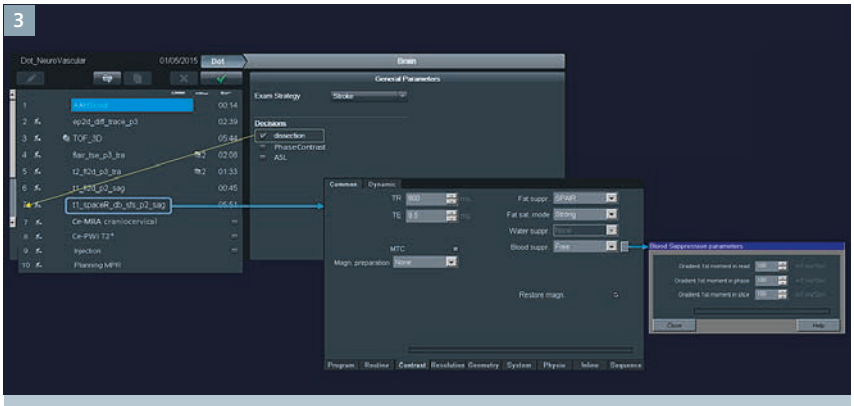

3 DotGO workflow for MAGNETOM Aera and MAGNETOM Spectra.

4 **Parameters 1.5T & 3T**

MR system	Slices per Slab	FOV (mm)	Voxel size	Fat suppr. (Contrast)	Blood suppr. (Contrast)	TR/TE (ms)	TA
Aera 1.5T	192 Excitation > Non-sel	256	1.0x1.0x1.0	SPAIR	Free 100 mT ms^2/m (In read, phase, slice)	550/7.2	5:34
Spectra 3T	192 Excitation > Non-sel	256	1.0x1.0x1.0	SPAIR	Free 100 mT ms^2/m (In read, phase, slice)	600/9.5 Restore pulse	5:51

4 T1_space 3D dissection in sagittal orientation.

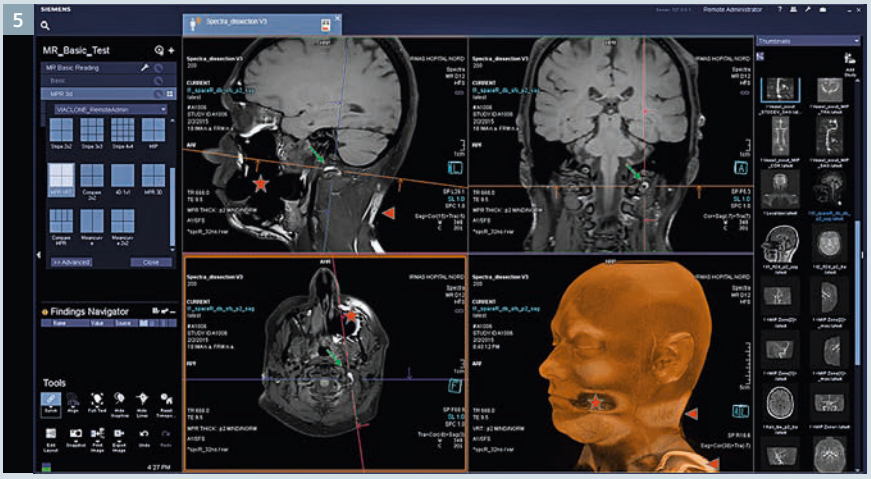

Case 1

45-year-old patient with a previous history of dissection left V3 segment (Fig. 5). Binocular diplopia with possible damage to right VI and of III on both sides. The T1 hyper-intense signal of the left vertebral artery (green arrow) indicates a parietal hematoma at the sub-acute stage of dissection. Reliable acquisition protocol despite the presence of metallic dental materials (red star) and impaired spectral fat saturation (red arrow).

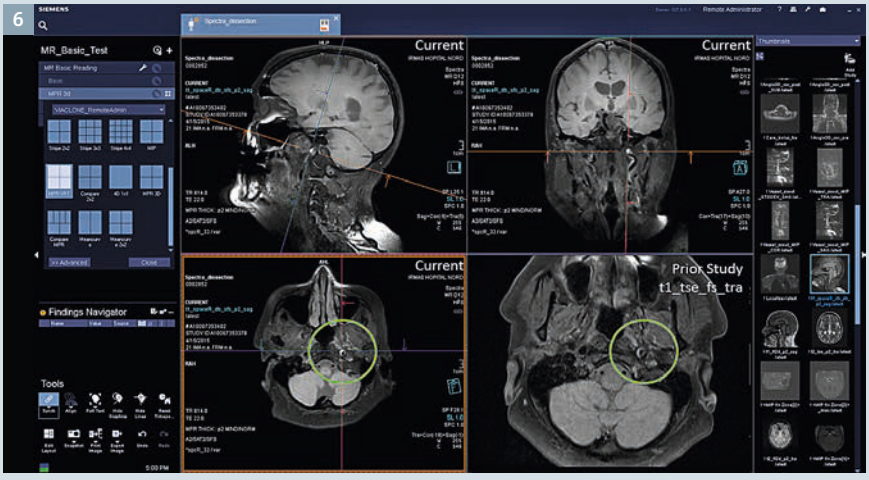

Case 2

80-year-old patient with a previous history of dissection of the left internal carotid (Fig. 6). Examination of the dissection. Prior study: carried out a classic T1w Spin Echo FS sequence with physiological synchronization of the pulse. Current study: carried out a T1-3D-space-SFS-db sequence without physiological synchronization. The SPACE protocol makes it easier to interpret the results because it is possible to evaluate the dissection in 3 dimensions with improved visualization of the dissection of the sub-petrous portion of the internal carotid (green circle).

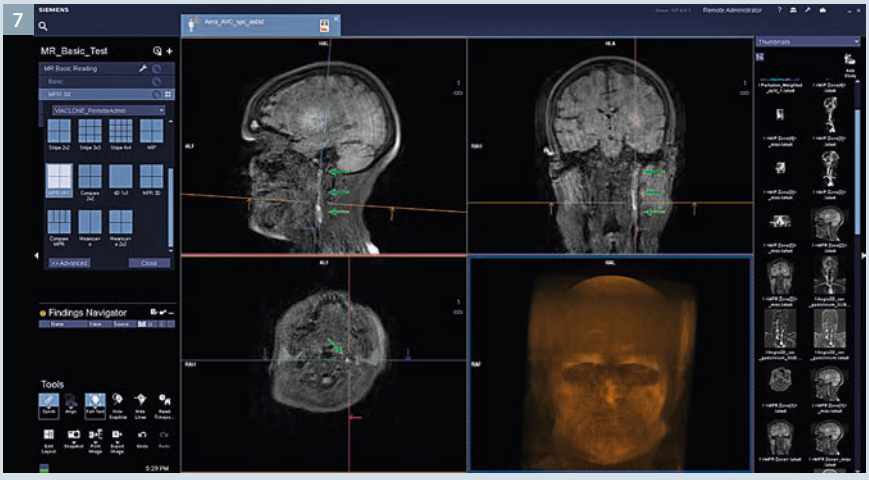

Case 3

60-year-old patient, MRI examination of stroke of left middle cerebral artery (Fig. 7). The patient is not able to keep completely still. Despite patient motion, the T1-3D-space-SFS-db sequence demonstrates its capability and allows the physician to detect a significant T1 hyperintense signal of a sub-acute thrombus which is responsible for causing an occlusion of the left internal carotid artery.

Case 4

70-year-old patient, undergoing MRI examination of vertebral dissection in the course of a clinical examination presenting, among other things, an incomplete Wallenberg syndrome on the left side (Fig. 8). View of thrombosis of the left vertebral artery on the CT.

The CE-MRA sequence shows a left vertebral artery that is not opaque. On the T1-3D-space-SFS-db sequence a thrombosis is visible (Figs. 8A–C green arrow).

The MinIP Thin reconstruction (8H) shows a circulating thread on one portion with an image of very recent thrombosis as an isosignal (characteristic of the acute stage of a parietal hematoma) on the T1-3D-space-SFS-db sequence (blue arrow).

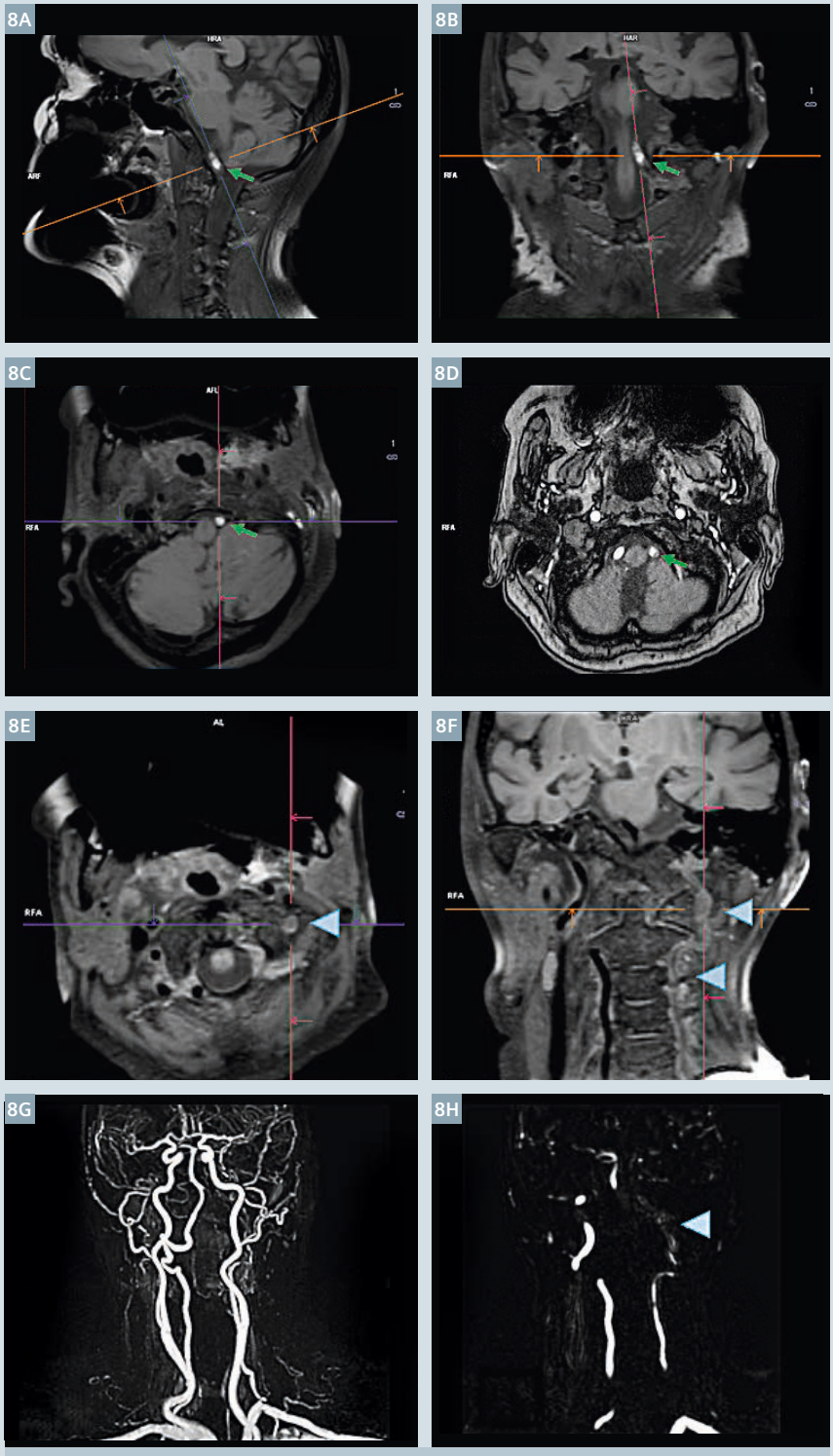

8 **(8A–C)** t1_space_sfs_db_sag (green arrow), slice 1
(8D) TOF (green arrow), slice 1
(8E–F) t1_space_sfs_db_sag (blue arrow), slice 2
(8G) Contrast-enhanced MR Angiography
(8H) MinIP Thin (blue arrow)

Conclusion

With its many benefits, (high reliability in the presence of metallic implants, 3D isotropic reconstruction, its high level of sensitivity, anatomical coverage, etc.), the SPACE T1 sequence has become an essential part of our hematoma research and in our evaluation of arterial wall pathologies.

The implementation and integration of a Dot strategy for neurovascular examinations enables a high degree of reproducibility amongst our MRI technologists within and between our sites. This, in turn, improves our efficiency in the treatment of our patients where time is a precious entity.

Acknowledgements

We would like to thank the team of stakeholders at GIE IRMAS (radiologists, technologists, doctors), and in particular our thanks go to Christophe Barles (MR Product Support Engineer Siemens Healthcare France) for the time he spent passing on his knowledge (technical, application, marketing etc.) on site, and at the Siemens France Users Clubs, which enabled us to share the same passion he has for MRI!

References

1 Victor Cuvinciuc, Magalie Viallon, Isabelle Momjian-Mayor, Roman Sztajzel, Vitor Mendes Pereira, Karl-Olof Lovblad, Maria Isabel Vargas: 3D fat-saturated T1 SPACE sequence for the diagnosis of cervical artery dissection. Neuroradiology (2013) 55:595–602.

2 Magalie Viallon, Victor Cuvinciuc, Benedicte Delattre, Laura Merlini, Isabelle Barnaure Nachbar, Seema Toso-Patel, Minerva Becker, Karl-Olof Lovblad, Sven Haller: State-of-the-art MRI techniques in neuroradiology: principles, pitfalls, and clinical applications. Neuroradiology (2015) 57:441-467.

3 Reichert M, Morelli JN, Runge VM, Tao A, von Ritschl R, von Ritschl A, Padua A, Dix JE, Marra MJ, Schoenberg SO, Attenberger UI: Contrast-enhanced 3-dimensional SPACE versus MP-RAGE for the detection of brain metastases: considerations with a 32-channel head coil. Invest Radiol. 2013 Jan;48(1):55-60.

4 B. Jeevanandham: To compare post contrast 3D T2 FLAIR, T1-SPACE and MP-RAGE sequences to select the ideal sequence for leptomeningeal abnormalities at 3 T MRI. ECR 2015.

5 Franz A. Fellner, Christine M. Fellner, Rene Chapot, Kaveh Akbari: MR Visualization of Spinal Dural Arterio-Venous Fistula Using T2-Weighted 3D SPACE – A Spin-Echo Technique. J. Biomedical Science and Engineering, 2015, 8, 327-332.

6 M. Edjlali, P. Roca, C. Rabrait, O. Naggara, and C. Oppenheim: 3D Fast Spin-Echo T1 Black-Blood Imaging for the Diagnosis of Cervical Artery Dissection. AJNR A3261 (oct-2012) 10.3174.

7 Chul-Ho Sohn, JiHoon Kim, Jaeseok Park, Kee-Hyun Chang, Seunghong Choi, and InSeong Kim: Contrast-Enhanced 3D Brain Black-Blood Imaging for Detection of Intracranial Arterial Unstable Plaque in Acute Ischemic Stroke Patients. ISMRM 2012.

8 Park J, et al. MRM 2007; 58:982.

9 Ling Zhanga, Eugene G. Kholmovski, Junyu Guob, Seong-Eun Kim Choi, Glen R. Morrell, and Dennis L. Parker: HASTE Sequence with Parallel Acquisition and T2 Decay Compensation: Application to Carotid Artery Imaging. Magn Reson Imaging. 2009 January; 27(1): 13–22.

10 Mara M. Kunst, Pamela W. Schaefer: Ischemic Stroke. Radiol Clin N Am 49 (2011) 1-26. enhanced MRI for screening patients at risk for malignant ventricular tachyarrhythmias. J Cardiovasc Magn Reson, 2004. 6(1): p. 84.

Contact

Michel Paret
MR Technologist
GIE IRMAS
110 avenue Albert Raimond
42270 Saint-Priest-en-Jarez, France
mparet@irmas.fr

Did you know that ...

“ With DotGO it’s going to be so much easier and quicker to build protocols on the fly and not interfere with taking table time away from the patients. Previously, to build a protocol from scratch would take 20 minutes. With DotGO, I was able to create a protocol in 45 seconds. Having consistency in our MRI protocols and examinations is extremely important. Our reputation is to provide the highest quality MRI examinations for our patients and referring physicians. DotGO will help us to do that.”

Anthony Pavone

Zwanger-Pesiri Radiology
(New York, USA)

The statements by Siemens’ customers described herein are based on results that were achieved in the customer’s unique setting. Since there is no ‘typical’ hospital and many variables exist (e.g., hospital size, case mix, level of IT adoption) there can be no guarantee that other customers will achieve the same results.

More clinical articles, tips & tricks, talks on Siemens unique Dot engines at

www.siemens.com/magnetom-world-dot