

A photograph of a hybrid operating room. Two surgeons in blue scrubs, masks, and caps are performing a procedure on a patient. A Siemens Artis Zee C-arm is positioned over the patient. The room is equipped with various medical devices and monitors.

SIEMENS

Feels right
at first sight

One-stop hybrid coronary revascularization for multi-vessel disease

Fuwai Cardiovascular Hospital, Beijing, China

Illustrated workflows in hybrid operating rooms, No. 13

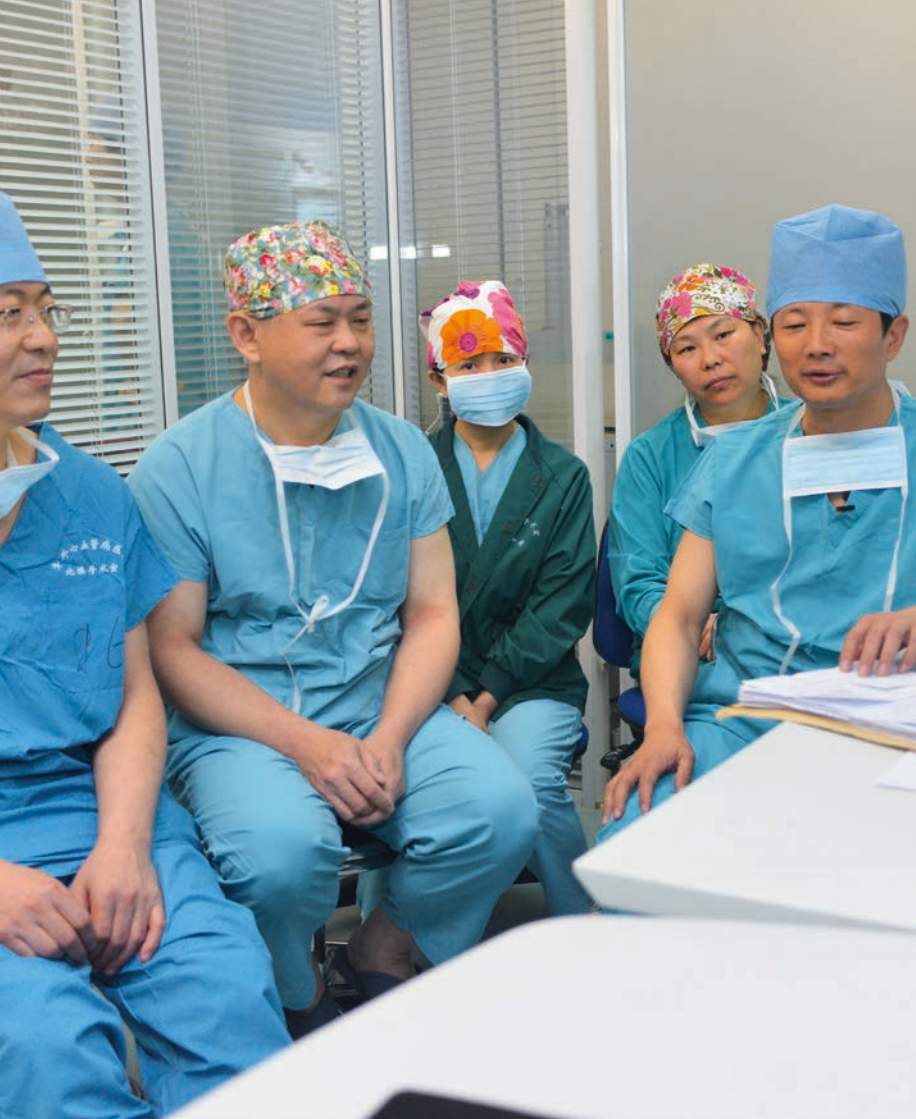Fuwai Cardiovascular Hospital

Fuwai Hospital was founded in 1956 as a government owned public hospital. It is now one of the top cardiovascular surgical centers worldwide.

The hospital has 950 beds and employs 2,500 medical and supporting staff. It owns 20 conventional operating rooms (OR), 4 hybrid ORs (HOR), and 13 cath labs.

Fuwai treats approximately 490,000 patients per year. In 2014, 10,200 open surgery and 13,000 interventional procedures were performed. Advanced techniques and procedures like TAVI and LAA closure have been carried out which proves the importance of the HOR.





Dr. Lv Feng and his heart team

Dr. Lv Feng is professor for cardiac surgery at the Adult Cardiac Surgery Center at Fuwai. He and his colleague, the interventional cardiologist Dr. Wu Yong Jian are specialists in the treatment of complex coronary heart disease.

In the so called hybrid approach they combine minimally invasive off-pump coronary artery bypass grafting (OPCAB) with percutaneous coronary interventions (PCI) in selected patients. Hybrid revascularization aims to restore coronary blood flow and myocardial perfusion by applying bypasses and stents during a single session in the HOR, as opposed to a staged procedure in the OR and the cathlab.

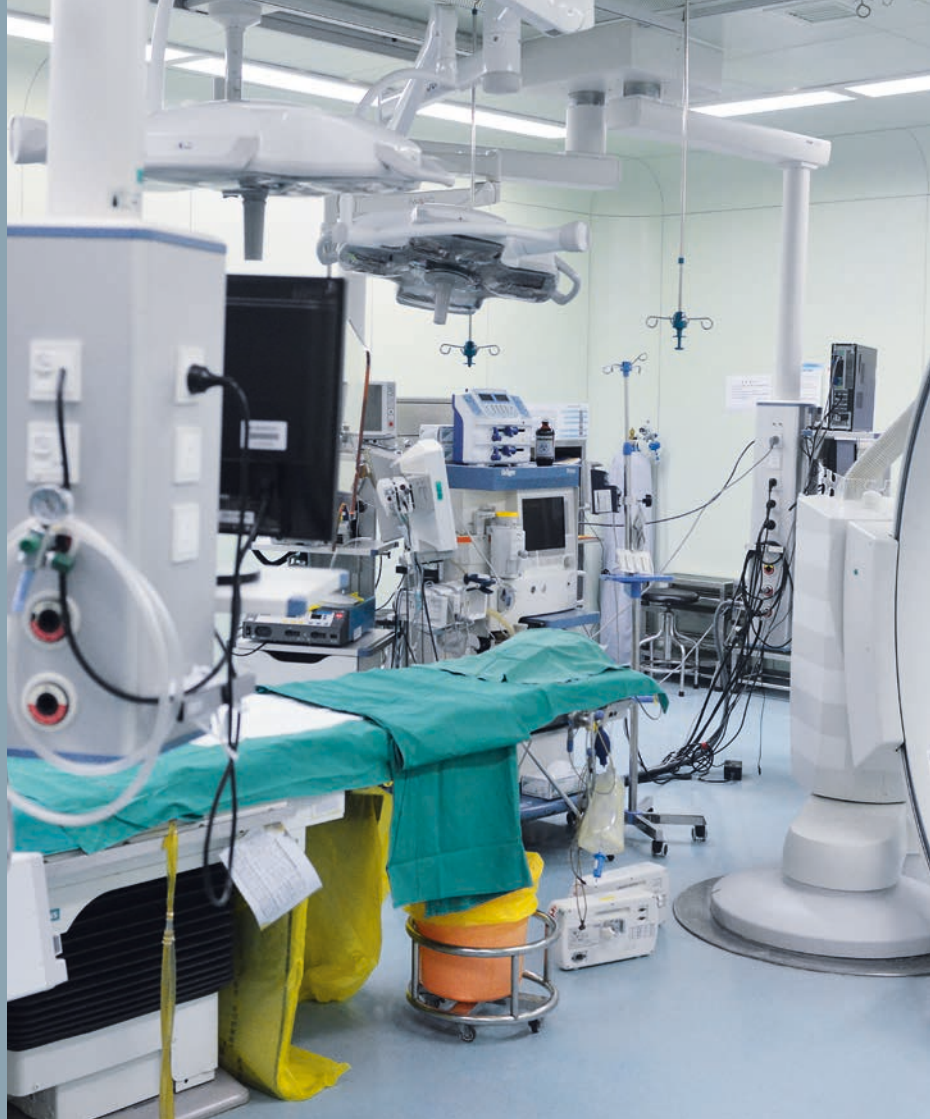Hybrid operating room concept for small rooms

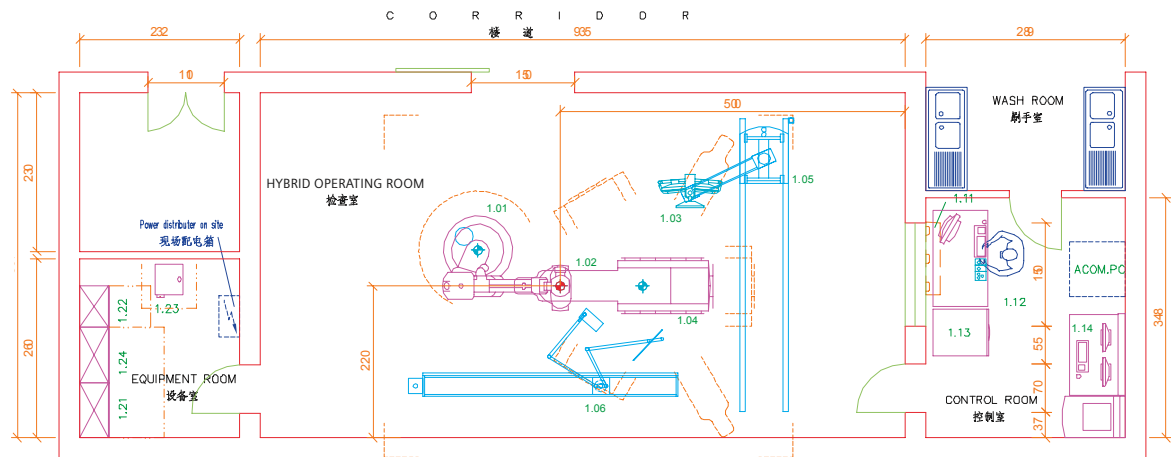
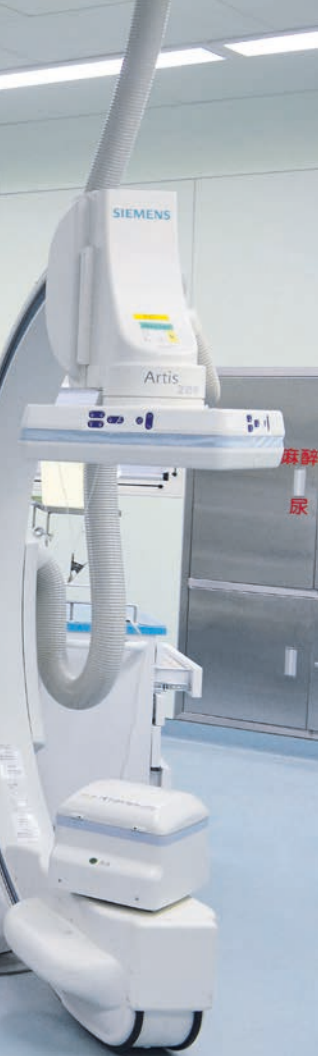The hybrid operating room in the Cardiac Surgery Center at Fuwai Hospital is a cardiac operating room equipped with advanced angiographic imaging enabling complex minimally-invasive procedures. Patients can be treated interventional and surgically in one room and in a single session.

Artis zee floor is an imaging system which even fits into small rooms (min. 38 m²). Although it is a compact system, it is very flexible. Due to its off-center rotatable basis it can cover the whole body (188 cm) which makes the system also suitable for vascular surgery.

The Artis OR table can be tilted and cradled while imaging is still possible. CT-like 3D images can be acquired from the head end with a coverage of 92.5 cm. The large 30 x 40 detector can operate even in steep angulations ($\pm 130^\circ$ LAO/RAO and $+ 55^\circ/- 45^\circ$ CRAN/CAUD).

At Fuwai the room size is about 9.4 m x 5 m. It accommodates a free-floating Artis OR table and a 2 x 2 display unit. The laminar airflow in combination with the floor mounted stand qualifies the room for highest hygienic standards.





Case history

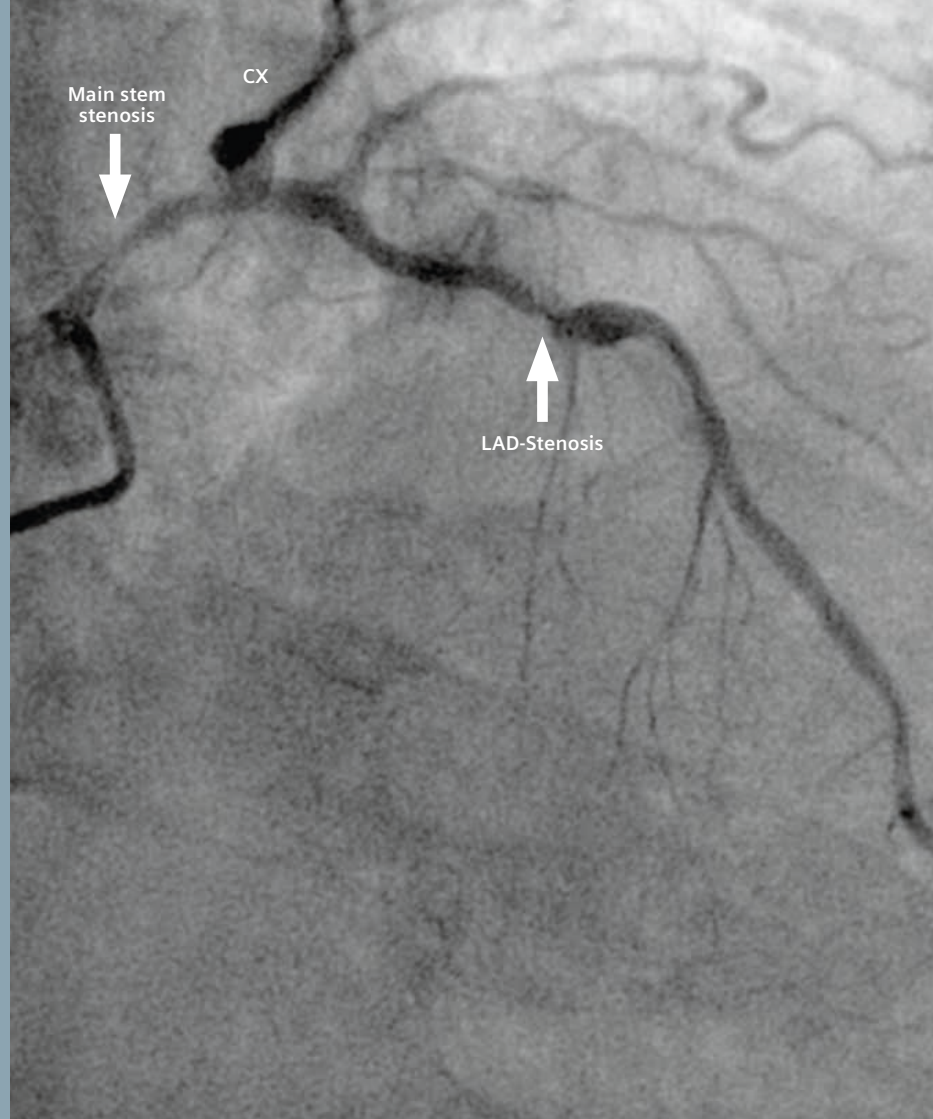The 74 years-old male patient presented with three-vessel coronary artery disease and extensive comorbidities.

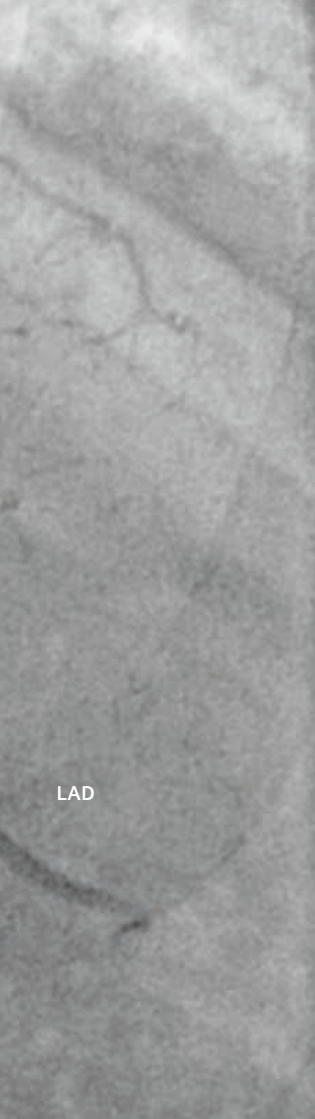
Preoperative coronary angiography showed a severe stenosis in the left main. A second stenosis was observed in the left anterior descending artery (LAD).

In the right coronary artery (RCA) two further stenoses were detected distally. The ejection fraction of the left ventricle was normal.

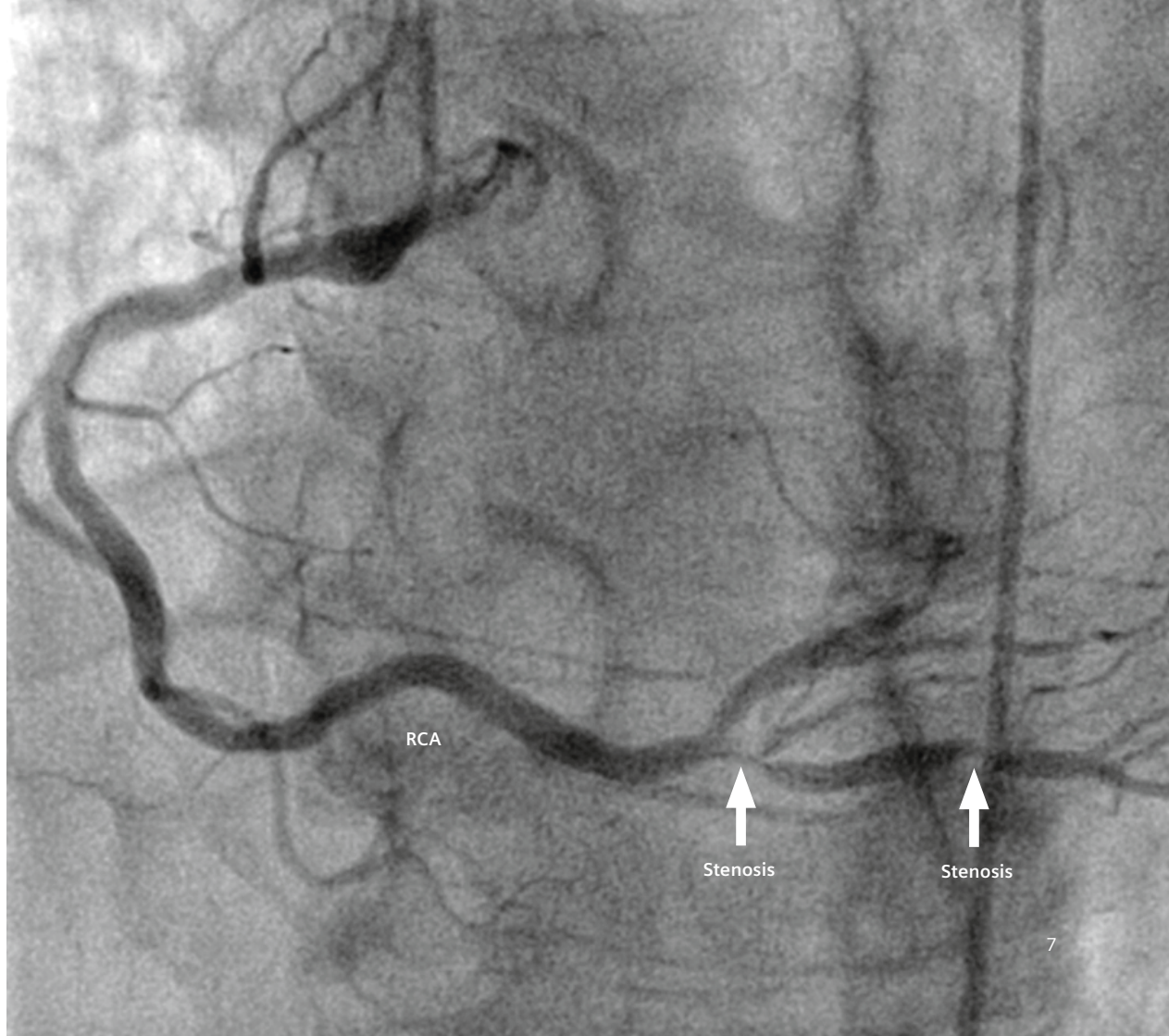
Because the patient was at high risk (EuroSCORE > 6) for isolated off-pump coronary artery bypass grafting (OPCAB) or percutaneous coronary intervention (PCI) he was scheduled for hybrid coronary revascularization. With unobstructed blood flow to the anterior wall provided by a patent LIMA-to-LAD graft, the challenging percutaneous procedure could be done safer.

The stenoses in the RCA were treated percutaneously with drug-eluting stents (DES).





LAD



RCA

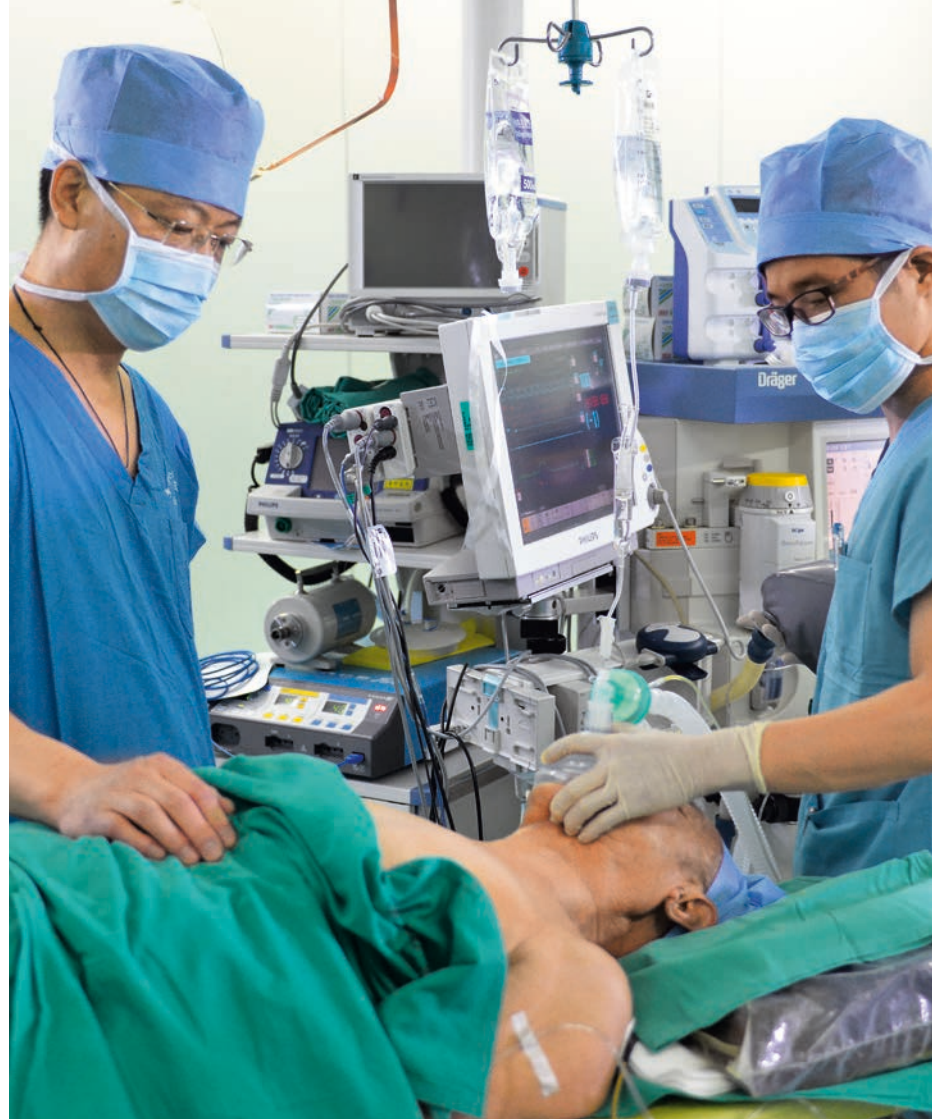↑
Stenosis

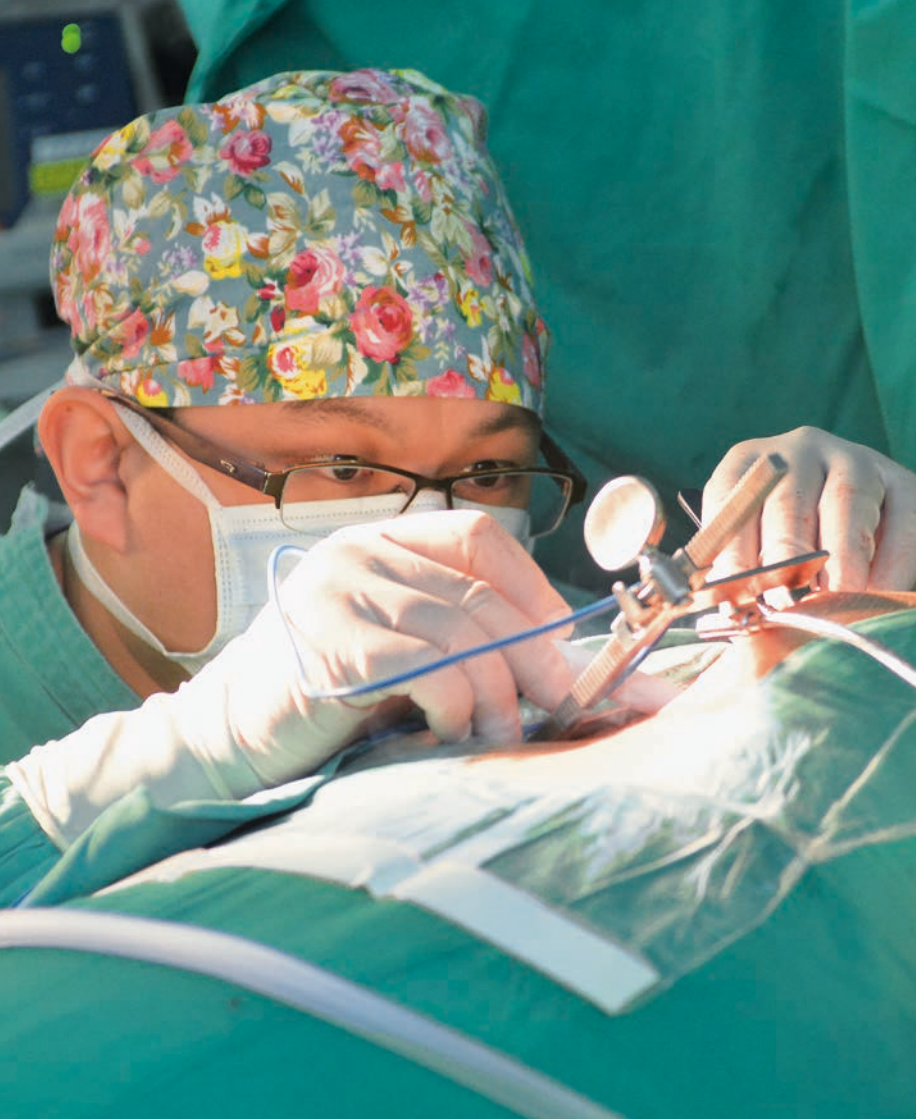↑
Stenosis

Patient positioning

Off-pump CABG aimed to bypass the occlusion of the LAD while the heart is beating. The patient was positioned in supine position. He received general anesthesia and tracheal intubation.

After disinfection of the chest the patient was wrapped in sterile drapes. The draping was applied so that the C-arm of Artis zee floor could still move collision-free around the patient.





Preparation of the LIMA

After lower partial ministernotomy the left internal mammary artery (LIMA) conduit was harvested as a pedicle under direct vision.

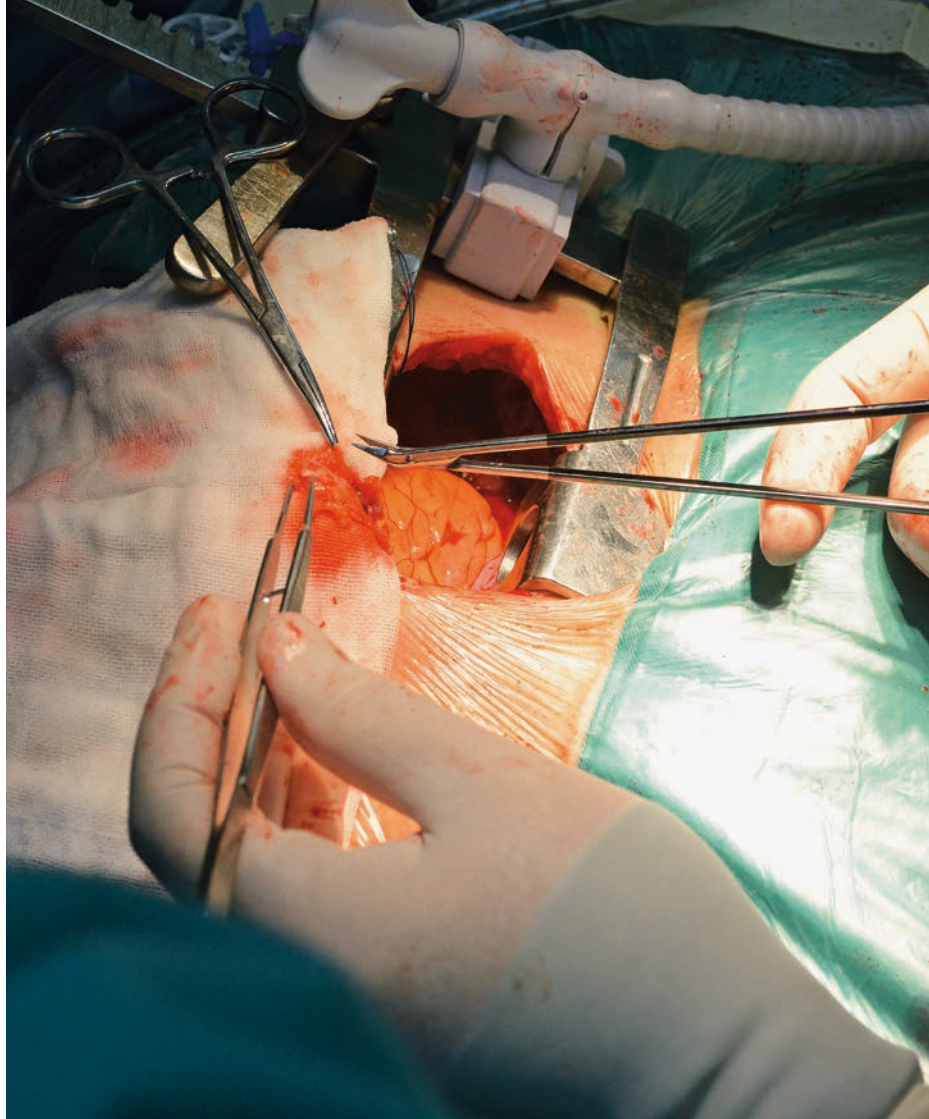
In this phase of the procedure Artis zee floor was in a parking position. Since the system is mounted on an off-center rotatable basis it is possible to create a comfortable space around the table. If, accidentally, a minimally invasive procedure has to be converted into an open one, the system can be retracted quickly. Artis zee floor is integrated with the free-floating Siemens OR table which is optimized for cardiovascular interventions.

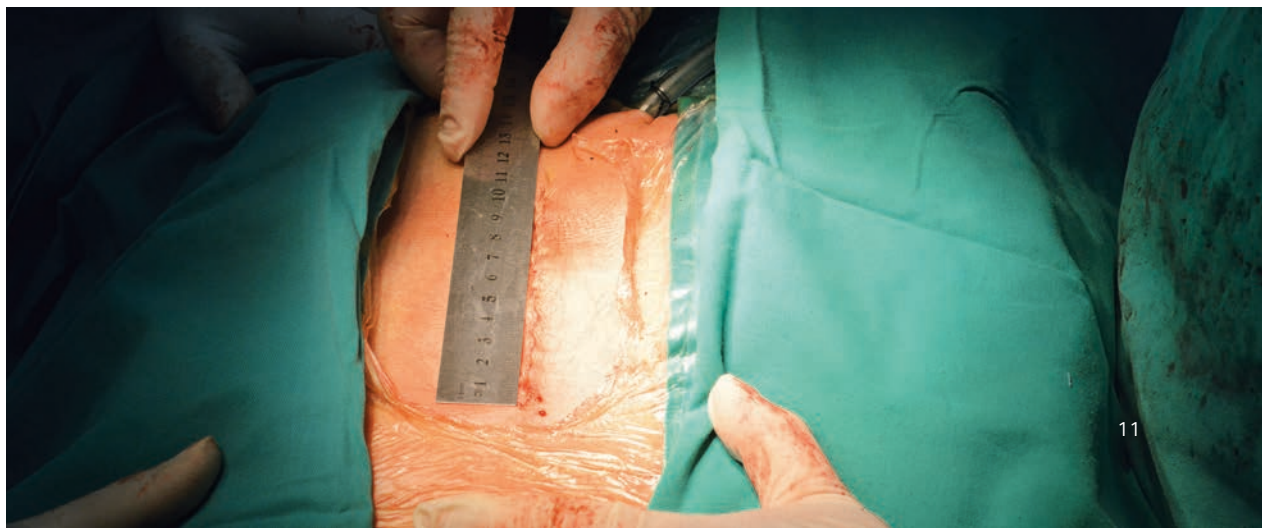
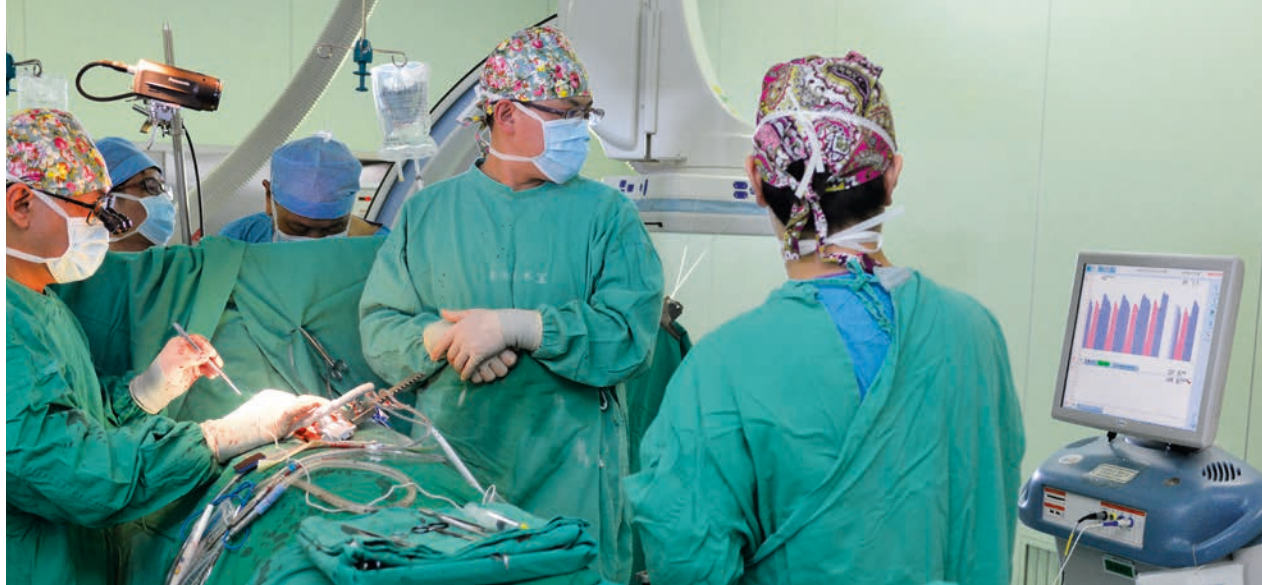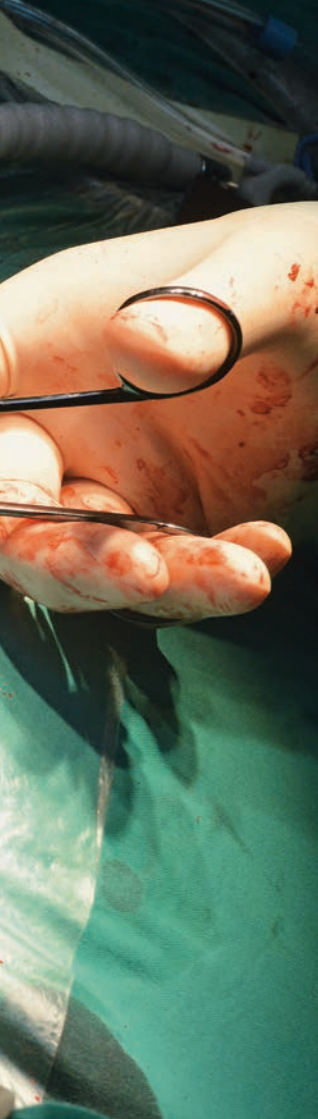Bypass anastomosis

For the anastomosis a stabilization device was used. Dr. Lv Feng sutured the LIMA to the LAD to establish the bypass. Intraoperative ultrasound flow measurement was used to check the patency of the bypass and the anastomosis. The thorax was closed and a pericardial drainage tube was placed.

Anticoagulation protocol

The team followed an antiplatelet protocol with continued administration of 100 mg/d acetylsalicylic acid before the procedure. After the procedure the dose was increased to 300 mg/d for one month and then adjusted again to 100 mg/d. Clopidogrel was paused for seven days before the procedure and 300 mg were applied via a nasogastric tube after the surgical part but before stenting. Heparin was administered to obtain an activated clotting time greater than 300 s before harvesting the LIMA. After the completion of the anastomosis heparin was antagonized by protamine sulfat.

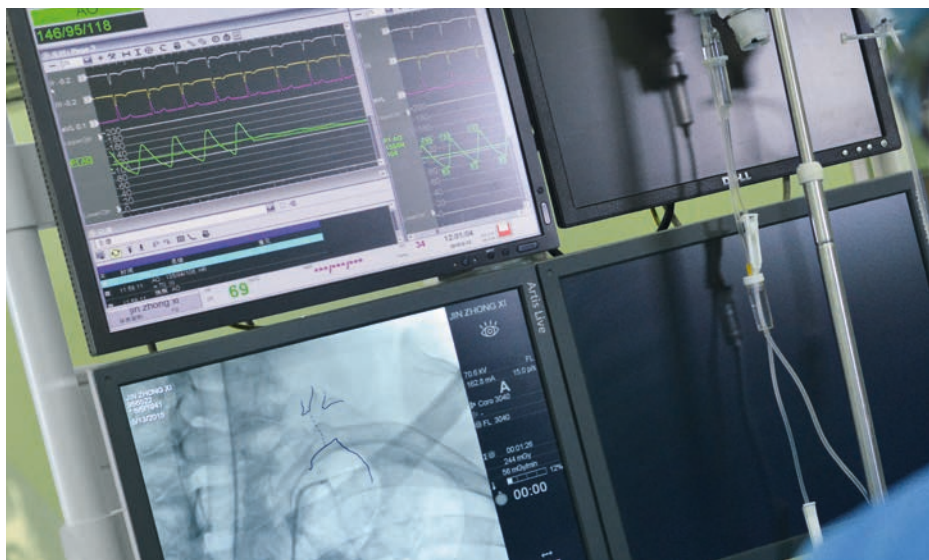
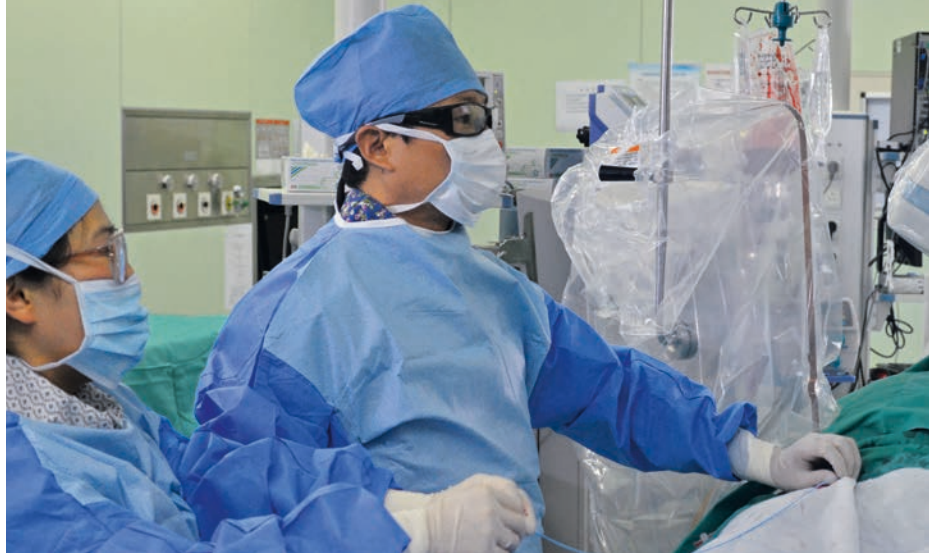
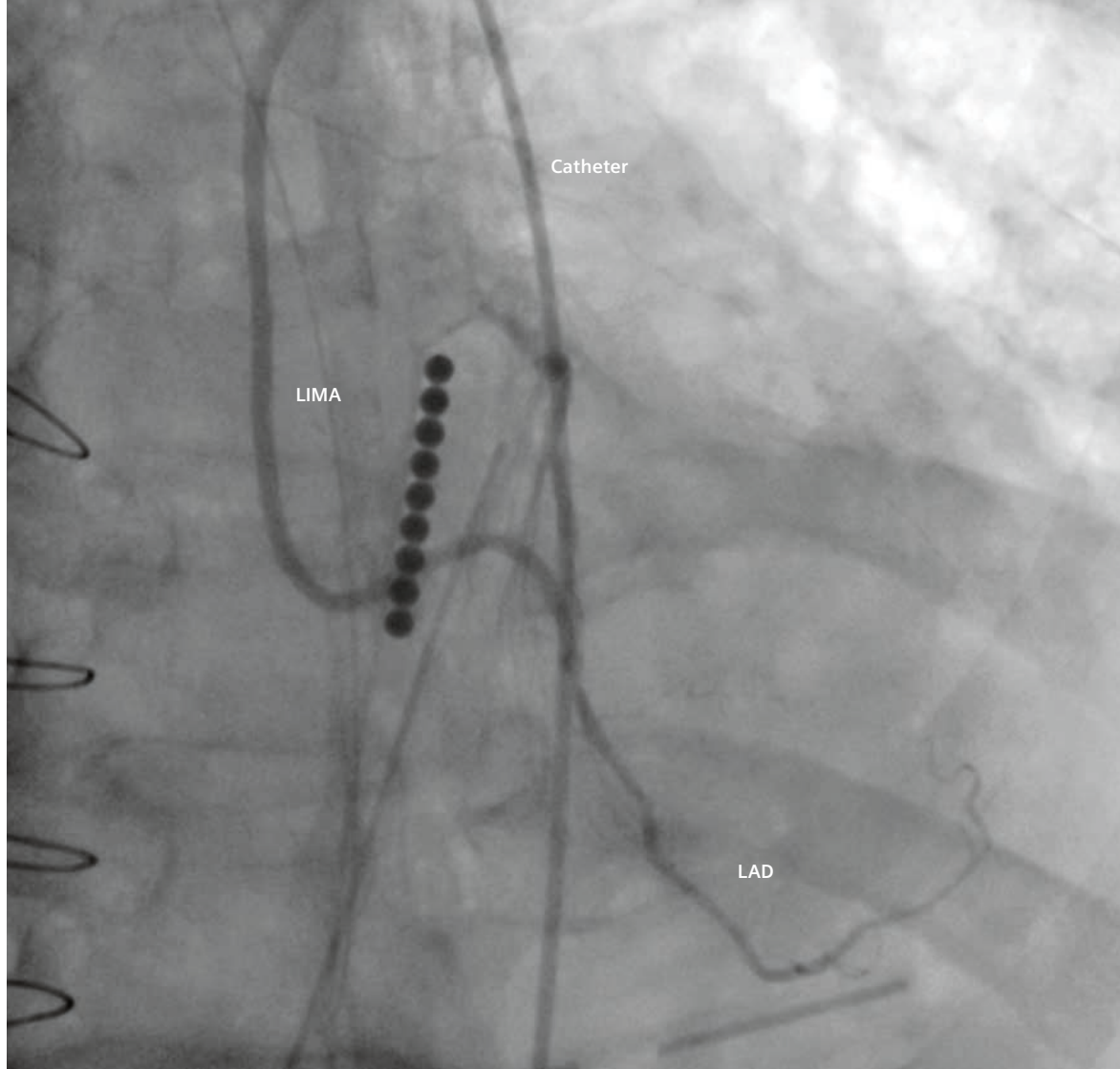


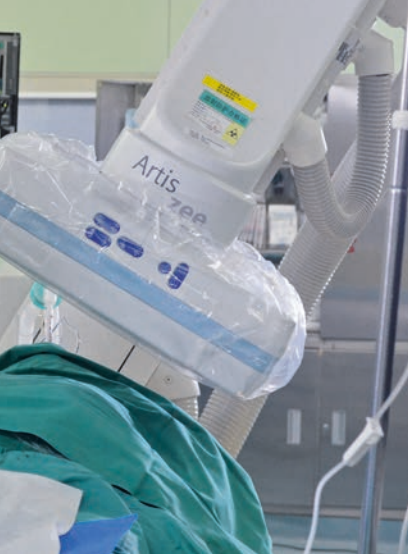Intraoperative completion angiography

During chest closure, the interventional cardiologist was already preparing for the percutaneous intervention (PCI). The responsibility changed from the cardiac surgeon Dr. Lv Feng to the interventional cardiologist Dr. Wu Yong Jian.

The cardiologist started with an angiography to evaluate the LIMA flow and the LAD anastomosis. The angiographic images demonstrated a good blood supply from the LIMA to the LAD and an unobstructed anastomosis.



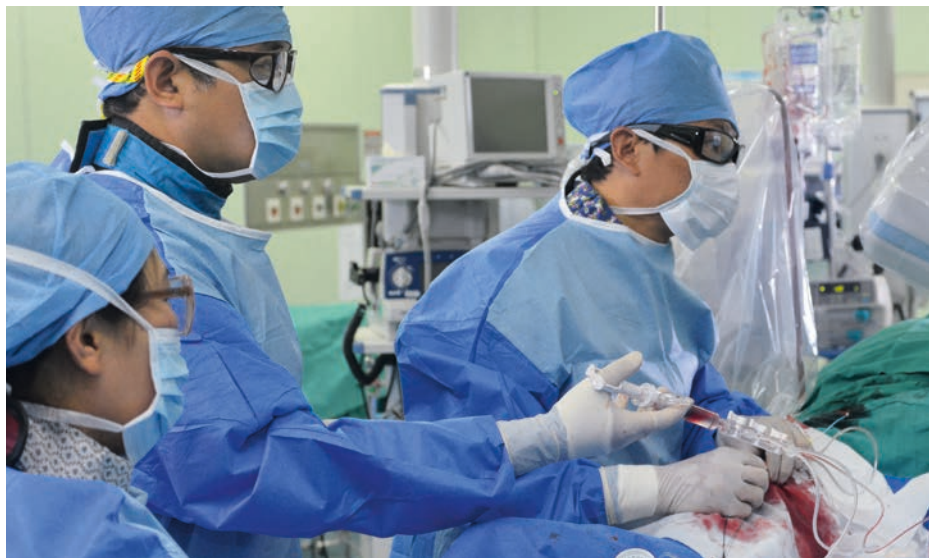
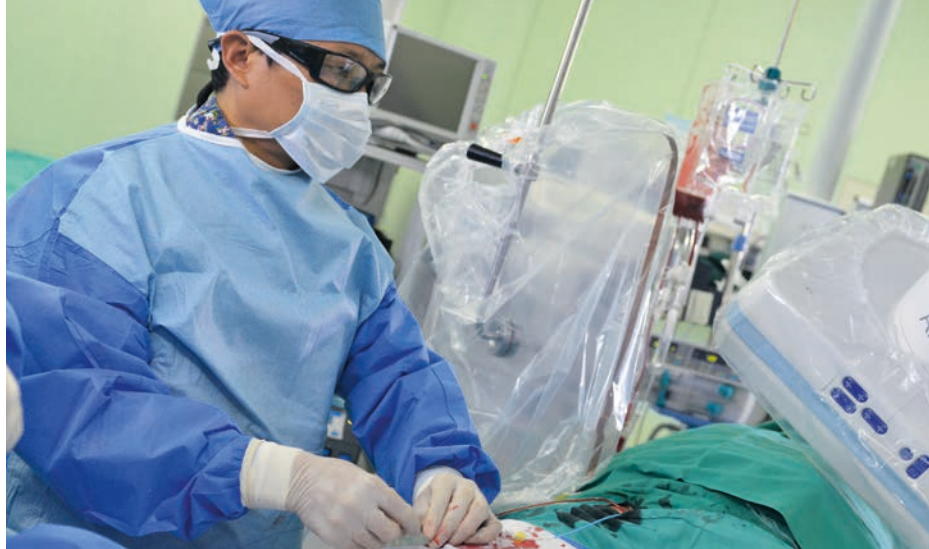
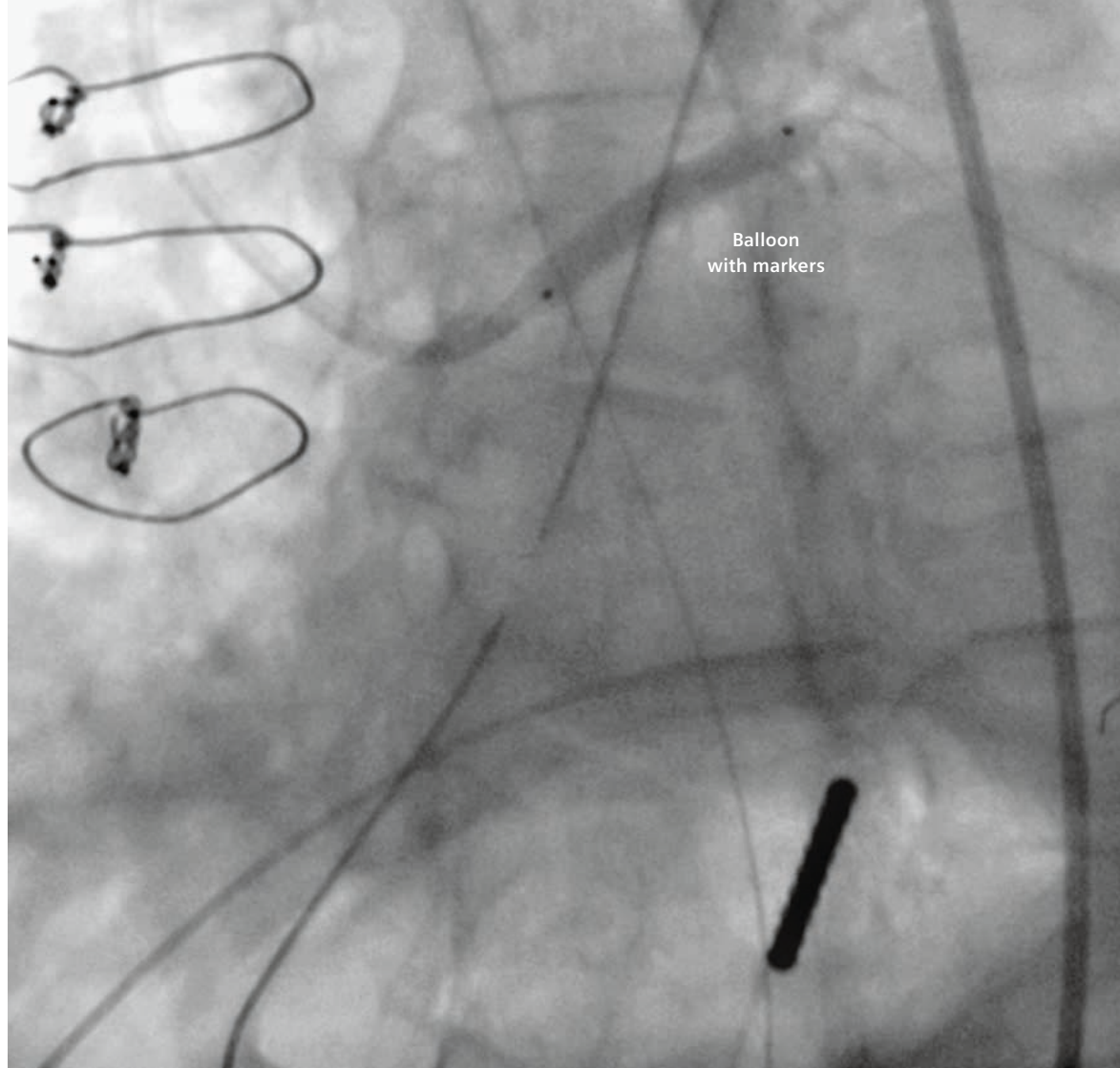
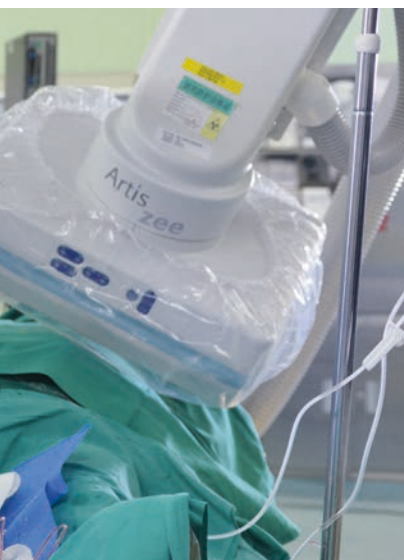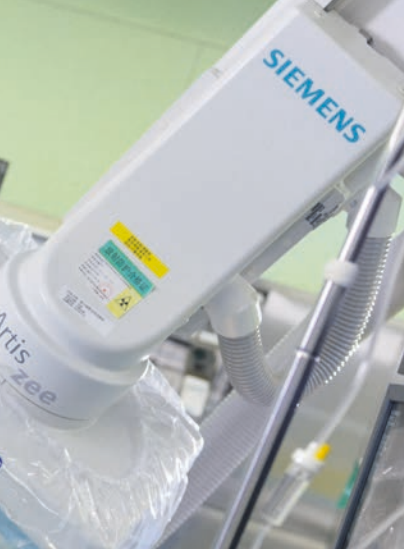Percutaneous coronary intervention (PCI)

Dr. Wu Yong Jian treated the stenoses in the RCA with drug-eluting stents (DES). During the PCI heparin was given to maintain an activated clotting time greater than 300 s.

For the PCI fluoroscopic control and high quality imaging is essential. Markers on the wire show the interventional cardiologist the position of the stent. Artis zee floor is controlled comfortably from the table side through the sterile cover.

With unobstructed blood flow provided by the LIMA-to-LAD graft the stenosis in the left main was also treated with PCI. The intra-operative blood loss was 290 ml. The patient was dismissed after nine days without major bleedings or other complications.





Balloon
with markers

Clinical outcomes

Evaluations from Fuwai hospital showed that the 5-year MACCE rate of the hybrid coronary revascularization patient group was significantly lower than that in the stand-alone PCI group (6.6% vs. 22.7%; $p < 0.001$), but similar to that in the CABG group (6.6% vs. 13.5%; $p = 0.14$).

The surgeons concluded that hybrid coronary revascularization may provide a promising alternative to stand-alone CABG and PCI for patients with high Euro or Syntax scores.

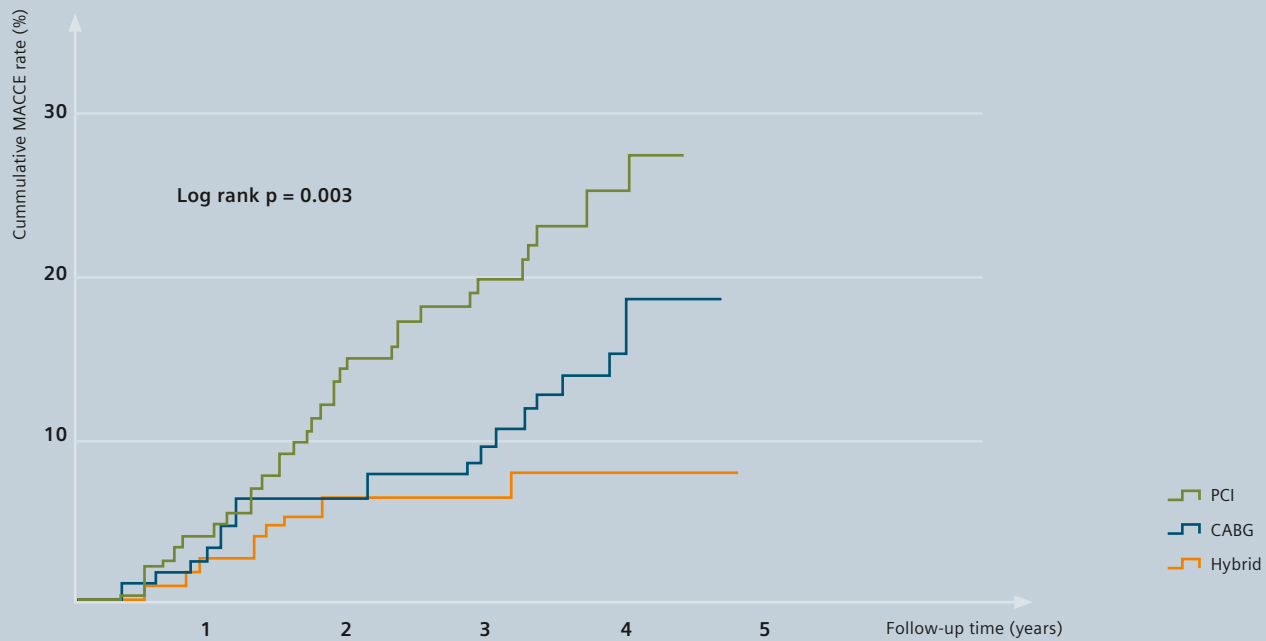
Furthermore, Dr. Hu Shengshou from Fuwai showed that the in-hospital cost for hybrid coronary revascularization is about ¥ 11,000 lower ($p = 0.14$) compared to stand-alone PCI due to the number of stents. Compared to stand-alone OPCAB the hybrid approach saved approximately 16 ICU hours ($p = 0.019$).

References

Shen et al., JACC, 2013(61)
Hu et al., Ann Thorac Surg, 2011(91)
Gao et al., Platelets, 2010(21)
Harskamp et al., Ann Thorac Surg, 2013(96)

	Hybrid	CABG	PCI	p value
Low	n = 60	n = 58	n = 53	
Death	0	0	0	
Myocardial infarction	0	0	2	0.143
Neurologic event	1	2	0	0.389
Repeat revascularization	1	0	3	0.167
Any MACCE	2	2	5	0.336
Medium	n = 52	n = 50	n = 53	
Death	1	2	1	0.829
Myocardial infarction	0	0	2	0.154
Neurologic event	0	0	1	0.641
Repeat revascularization	4	2	7	0.259
Any MACCE	5	5	11	0.206
High	n = 29	n = 33	n = 35	
Death	0	2	4	0.214
Myocardial infarction	0	3	2	0.290
Neurologic event	1	6	2	0.163
Repeat revascularization	1	1	8	0.015
Any MACCE	2	12	16	0.030

The hybrid group shows significantly lower MACCE rate in the high EuroSCORE risk tertile.

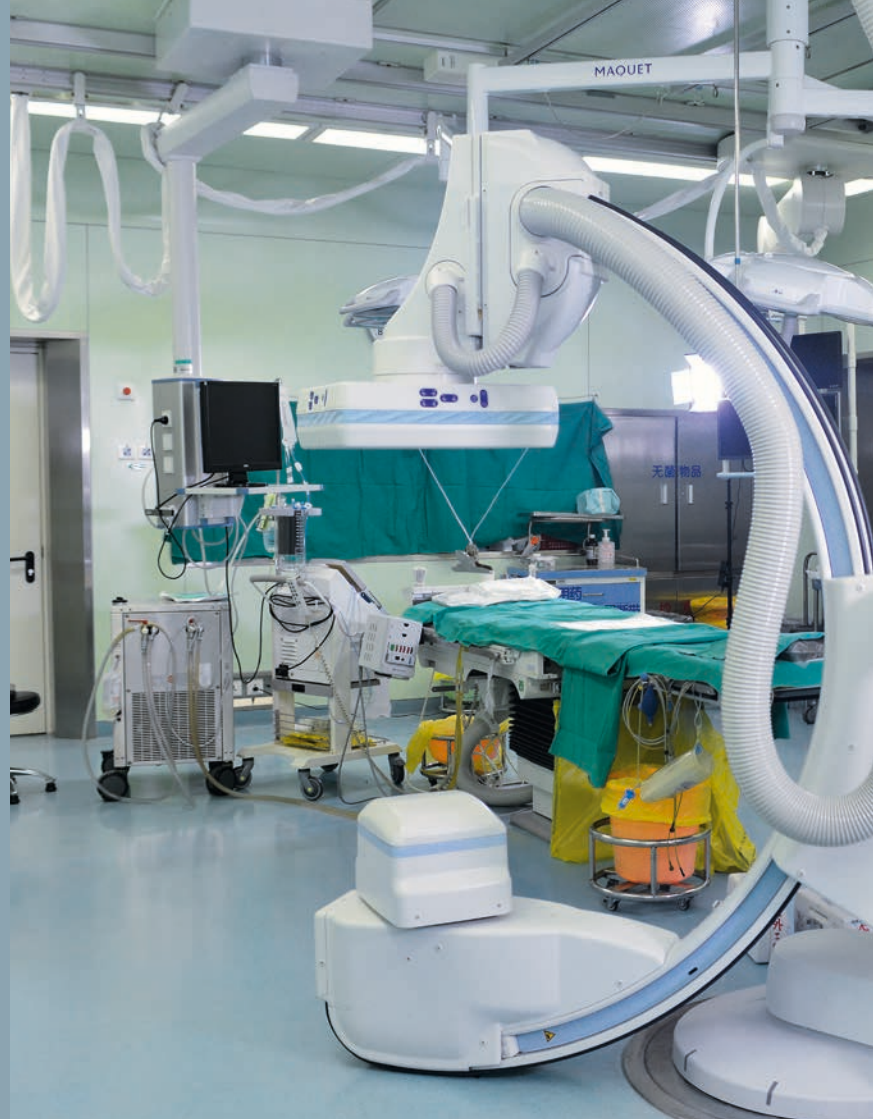

Cumulative MACCE rates in the hybrid, CABG and PCI group.

Configuration of the hybrid operating room

Fuwai Cardiovascular Hospital

- Artis zee floor imaging system with 30 x 40 large detector
- Free-floating Artis OR table
- Artis Workplace
- 2 x 2 monitor unit
- VeriQ intraoperative Transit Time Flow Measurement (TTFM) system
- Dräger Primus anesthetic workplace
- Dräger Agila supply unit
- 2 Maquet X'ten surgical lights
- Mavig protective shield
- 2.5 m x 2.7 m laminar airflow field





The Benefits

- Hybrid coronary revascularization provides lower mid-term MACCE rate and in-hospital cost compared to stand-alone CABG and PCI
- More confidence and less malpositionings through completion angiography after CABG
- Artis zee floor even fits in rooms with limited space (min. 38 m²)
- Off-center rotatable basis provides high flexibility
- Full-body coverage in 2D and AP for joint usage with vascular surgery
- Excellent image quality for completion angiography and dedicated applications for PCI
- Intra-operative 3D imaging for minimal invasive procedures like TAVI and EVAR
- Floor mounted stand in combination with laminar airflow provides highest hygienic standard



Scan this code
to find out
more about
our portfolio in
cardiac surgery.

On account of certain regional limitations of sales rights and service availability, we cannot guarantee that all products included in this brochure are available through the Siemens sales organization worldwide. Availability and packaging may vary by country and are subject to change without prior notice. Some/All of the features and products described herein may not be available in the United States.

The information in this document contains general technical descriptions of specifications and options as well as standard and optional features which do not always have to be present in individual cases.

Siemens Healthcare Headquarters

Siemens Healthcare GmbH
Henkestr. 127
91052 Erlangen
Germany
Phone: +49 9131 84-0
[siemens.com/healthcare](https://www.siemens.com/healthcare)

Siemens reserves the right to modify the design, packaging, specifications, and options described herein without prior notice.

Please contact your local Siemens sales representative for the most current information.

The statements by Siemens' customers described herein are based on results that were achieved in the customer's unique setting. Since there is no "typical" hospital and many variables exist (e.g., hospital size, case mix, level of IT adoption) there can be no guarantee that other customers will achieve the same results.