Accelerated Segmented Cine TrueFISP of the Heart on a 1.5T MAGNETOM Aera Using *k-t*-sparse SENSE

Maria Carr[1]; Bruce Spottiswoode[2]; Bradley Allen[1]; Michaela Schmidt[2]; Mariappan Nadar[4]; Qiu Wang[4]; Jeremy Collins[1]; James Carr[1]; Michael Zenge[2]

[1] Northwestern University, Feinberg School of Medicine, Chicago, IL, USA
[2] Siemens Healthineers
[3] Siemens Corporate Technology, Princeton, United States

Introduction

Cine MRI of the heart is widely regarded as the gold standard for assessment of left ventricular volume and myocardial mass and is increasingly utilized for assessment of cardiac anatomy and pathology as part of clinical routine. Conventional cine imaging approaches typically require 1 slice per breath-hold, resulting in lengthy protocols for complete cardiac coverage. Parallel imaging allows some shortening of the acquisition time, such that 2–3 slices can be acquired in a single breath-hold. In cardiac cine imaging artifacts become more prevalent with increasing acceleration factor. This will negatively impact the diagnostic utility of the images and may reduce accuracy of quantitative measurements. However, regularized iterative reconstruction techniques can be used to considerably improve the images obtained from highly undersampled data. In this work, L1-regularized iterative SENSE as proposed in [1] was applied to reconstruct under-sampled *k*-space data. This technique[1] takes advantage of the de-noising characteristics of Wavelet regularization and promises to very effectively suppress sub-sampling artifacts. This may allow for high acceleration factors to be used, while diagnostic image quality is preserved.

The purpose of this study was to compare segmented cine TrueFISP images from a group of volunteers and patients using three acceleration and reconstruction approaches: iPAT factor 2 with conventional reconstruction; T-PAT factor 4 with conventional reconstruction; and T-PAT factor 4 with iterative *k-t*-sparse SENSE reconstruction.

Technique

Cardiac MRI seems to be particularly well suited to benefit from a group of novel image reconstruction methods known as compressed sensing [2] which promise to significantly speed up data acquisition. Compressed sensing methods were introduced to MR imaging [3, 4] just a few years ago and have since been successfully combined with parallel imaging [5, 6]. Such methods try to utilize the

[1] 510(k) pending. Compressed Sensing Cardiac Cine is not commercially available. Future availability cannot be guaranteed.

Table 1: MRI conventional and iterative imaging parameters

Parameters	Conventional iPAT 2	Conventional T-PAT 4	Iterative T-PAT 4
Iterative recon	No	No	Yes
Parallel imaging	iPAT2 (GRAPPA)	TPAT4	TPAT4
TR/TE (ms)	3.2 / 1.6	3.2 / 1.6	3.2 / 1.6
Flip angle (degrees)	70	70	70
Pixel size (mm²)	1.9 × 1.9	1.9 × 1.9	1.9 × 1.9
Slice thickness (mm)	8	8	8
Temp. res. (msec)	38	38	38
Acq. time (sec)	7	3.2	3.2

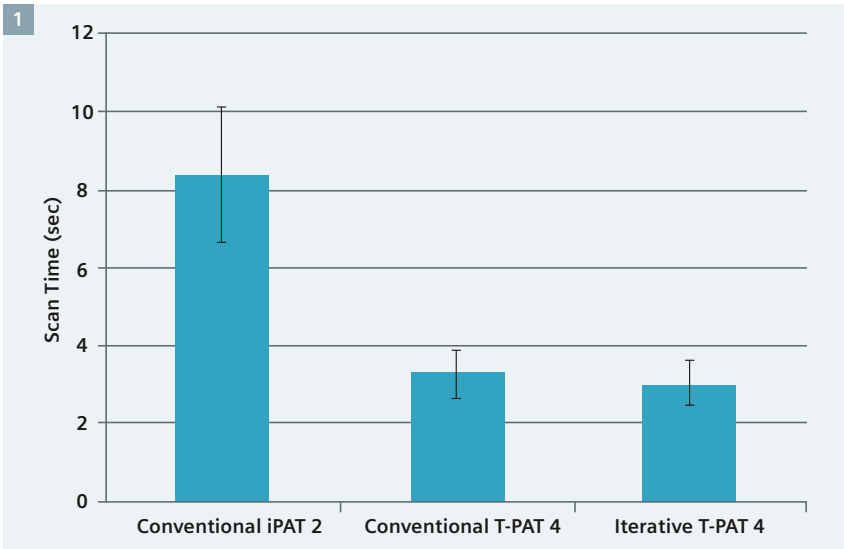

1 Single slice scan time in patients and volunteers. There was a statistically significant reduction in scan time compared to the standard iPAT2 for both TPAT4 acceleration and iterative reconstruction TPAT4 acceleration.

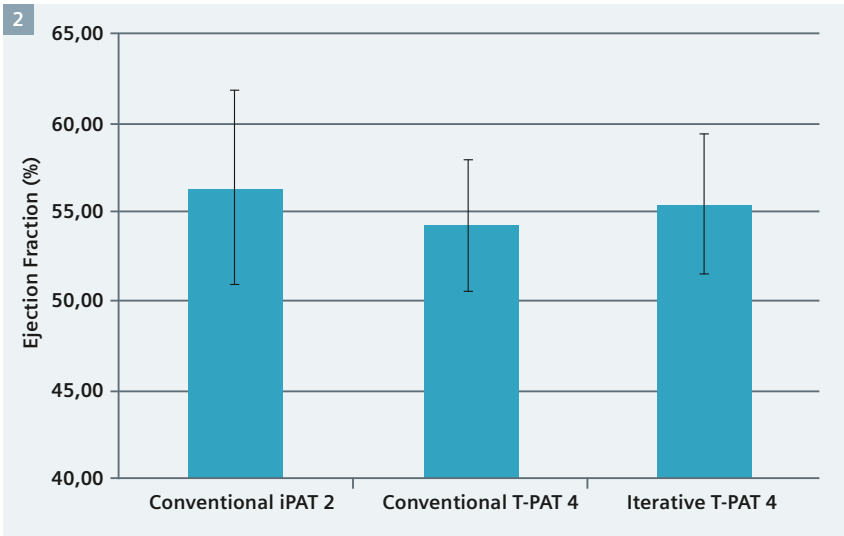

2 Ejection fraction in volunteers. Quantitatively measured ejection fractions were comparable across all three techniques.

full potential of image compression during the acquisition of raw input data. In the case of highly subsampled input data, a non-linear iterative optimization avoids sub-sampling artifacts during the process of image reconstruction. The resulting images represent the best solution consistent with the input data, which have a sparse representation in a specific transform domain. In the most favorable case, residual artifacts are not visibly perceptible or are diagnostically irrelevant.

As outlined by Liu et al. in [1], the image reconstruction can be formulated as an unconstrained optimization problem. In the current implementation, this optimization is solved using a Nesterov-type algorithm [7]. The L1-regularization with a redundant Haar transform is efficiently solved using a Dykstra-type algorithm [8]. This allowed a smooth integration into the current MAGNETOM platform and, therefore, facilitates a broad clinical evaluation.

Materials and methods

Nine healthy human volunteers (57.4 male/56.7 female) and 20 patients (54.4 male/40.0 female) with suspected cardiac disease were scanned on a 1.5T MAGNETOM Aera system under an approved institutional review board protocol. All nine volunteers and 16 patients were imaged using segmented cine TrueFISP sequences with conventional GRAPPA factor 2 acceleration (conventional iPAT 2) T-PAT factor 4 acceleration (conventional T-PAT 4), and T-PAT factor 4 acceleration with iterative *k-t*-sparse SENSE reconstruction (iterative T-PAT 4). The remaining 4 patients were scanned using only conventional iPAT 2 and iterative T-PAT 4 techniques. Note that the iterative technique is fully integrated into the standard reconstruction environment.

The imaging parameters for each imaging sequence are provided in Table 1. All three sequences were run in 3 chamber and 4 chamber views, as well as a stack of short axis slices.

Quantitative analysis was performed on all volunteer data sets at a *syngo* MultiModality Workplace (Leonardo) using Argus post-processing software (Siemens Healthcare, Erlangen, Germany) by an experienced cardiovascular MRI technician. Ejection fraction, end-diastolic volume, end-systolic volume, stroke volume, cardiac output, and myocardial mass were calculated. In all volunteers and patients,

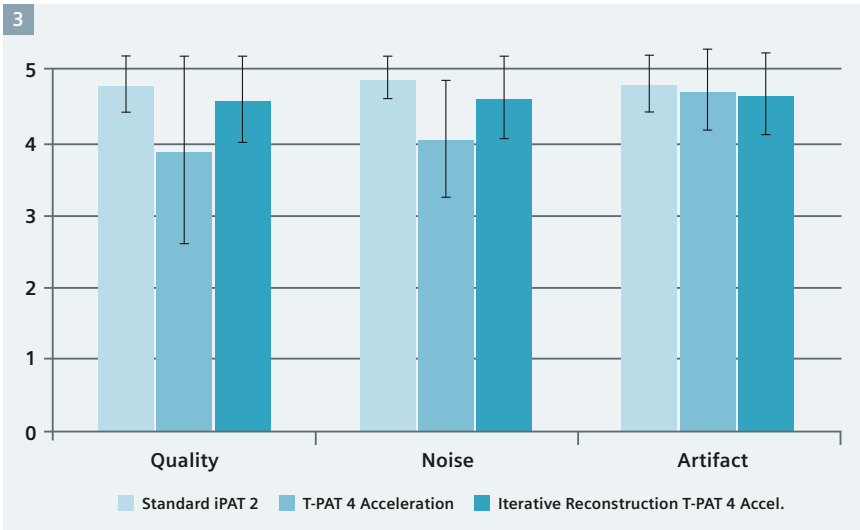

3 Qualitative scores in patients and volunteers. Image quality was highest and noise and artifact were lowest with iterative T-PAT 4 and conventional iPAT 2 compared to conventional T-PAT 4.

blinded qualitative scoring was performed by a radiologist using a 5 point Likert scale to assess overall image quality (1 – non diagnostic; 2 – poor; 3 – fair; 4 – good; 5 – excellent). Images were also scored for artifact and noise (1 – severe; 2 – moderate; 3 – mild; 4 – trace; 5 – none).

All continuous variables were compared between groups using an unpaired t-test, while ordinal qualitative variables were compared using a Wilcoxon signed-rank test.

Results

All images were acquired successfully and image quality was of diagnostic quality in all cases. The average scan time per slice for conventional iPAT 2, conventional T-PAT 4 and iterative T-PAT 4 were for patients 7.7 ± 1.5 sec, 5.6 ± 1.5 sec and 2.9 ± 1.5 sec and for the volunteers 9.8 ± 1.5 sec, 3.2 ± 1.5 sec and 3.0 ± 1.5 sec, respectively. The results in scan time are illustrated in Figure 1. In both patients and volunteers, conventional iPAT 2 were significantly longer than both conventional T-PAT 4 and iterative T-PAT 4 techniques ($p < 0.001$ for each group).

The results for ejection fraction (EF) for all three imaging techniques are provided in Figure 2. The average EF for conventional T-PAT 4 was slightly lower than that measured for conventional iPAT 2 and iterative T-PAT, but the group size is relatively small (9 subjects) and this difference was not significant ($p = 0.34$ and $p = 0.22$ respectively).There was no statistically significant difference in ejection fraction between the conventional iPAT 2 and the iterative T-PAT 4 sequences ($p = 0.48$).

The results for image quality, noise and artifact are provided in Figure 3. The iterative T-PAT 4 images had comparable image quality, noise and artifact scores compared to the conventional iPAT 2 images. The conventional T-PAT 4 images had lower image quality, more artifacts and higher noise compared to the other techniques.

Figures 4 and 5 show an example of 4-chamber and mid-short axis images from all three techniques in a patient with basal septal hypertrophy. In both series', the conventional iPAT 2 and iterative T-PAT 4 images are comparable in quality, while the conventional T-PAT 4 image is visibly noisier.

Discussion

This study compares a novel accelerated segmented cine TrueFISP technique to conventional iPAT 2 cine TrueFISP and T-PAT 4 cine TrueFISP in a cohort of normal subjects and patients. The iterative reconstruction technique provided comparable measurements of ejection fraction to the clinical gold standard (conventional iPAT 2). The accelerated segmented cine TrueFISP with T-PAT 4, which was used as comparison technique, produced slightly lower EF values compared to the other techniques, although this was not found to be statistically significant. The iterative reconstruction produced comparable image quality, noise and artifact scores to the conventional reconstruction using iPAT 2. The conventional T-PAT 4 technique had lower image quality and higher noise scores compared to the other two techniques.

The iterative T-PAT 4 segmented cine technique allows for greater than 50% reduction in acquisition time for comparable image quality and spatial resolution as the clinically used iPAT 2 cine TrueFISP technique. This iterative technique could be extended to permit complete heart coverage in a single breath-hold thus greatly simplifying and shortening routine clinical cardiac MRI protocols, which has been one of the biggest obstacles to wide acceptance of cardiac MRI. With a shorter cine acquisition, additional advanced imaging techniques, such as perfusion and flow, can be more readily added to patient scans within a reasonable protocol length.

There are currently some limitations to the technique. Firstly, the use of SENSE implies that aliasing artifacts can occur if the field-of-view is smaller than the subject, which is sometimes difficult to avoid in the short axis orientation. But a solution to this is promised to be part of a future release of the current prototype. Secondly, the image reconstruction times of the current implementation seems to be prohibitive for routine clinical use. However, we anticipate future algorithmic improvements with increased computational power to reduce the reconstruction time to clinically acceptable values.

Of course, iterative reconstruction techniques are not just limited to cine imaging of the heart. Future work may see this technique applied to time intense techniques such as 4D flow phase contrast MRI and 3D coronary MR angiography, making them more clinically applicable. Furthermore, higher acceleration rates might be achieved by using an incoherent sampling pattern [9].

With sufficiently high acceleration, the technique can also be used effectively for real time cine cardiac imaging in patients with breath-holding difficulties or arrhythmia. Figure 6 shows that real-time acquisition with T-PAT 6 and *k-t* iterative reconstruction still results in excellent image quality.

In conclusion, cine TrueFISP of the heart with inline *k-t*-sparse iterative reconstruction is a promising technique for obtaining high quality cine images at a fraction of the scan time compared to conventional techniques.

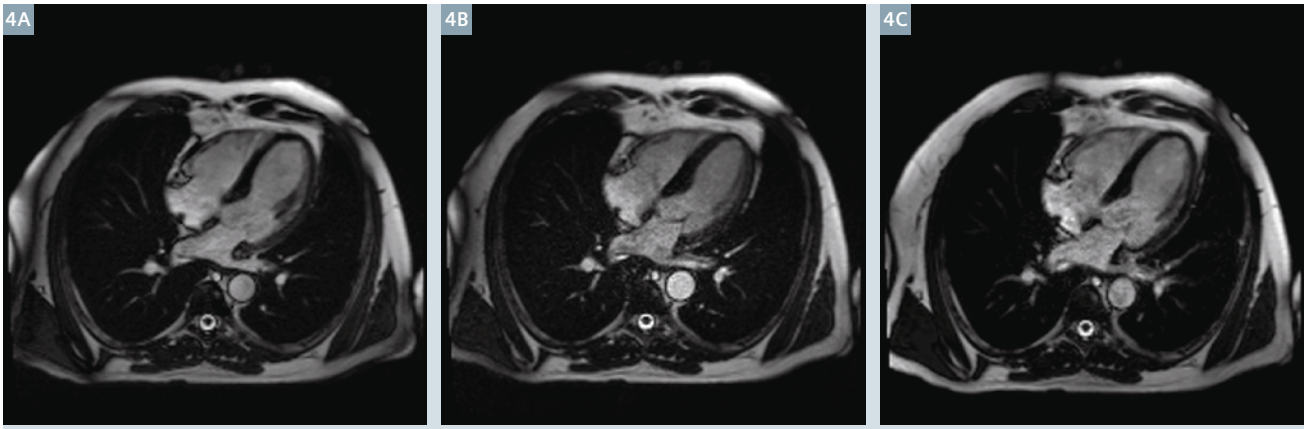

4 Four chamber cine TrueFISP from a normal volunteer. **(4A)** Conventional iPAT 2, acquisition time 8 s. **(4B)** Conventional T-PAT 4, acquisition time 3 seconds. **(4C)** Iterative T-PAT 4, acquisition time 3 seconds.

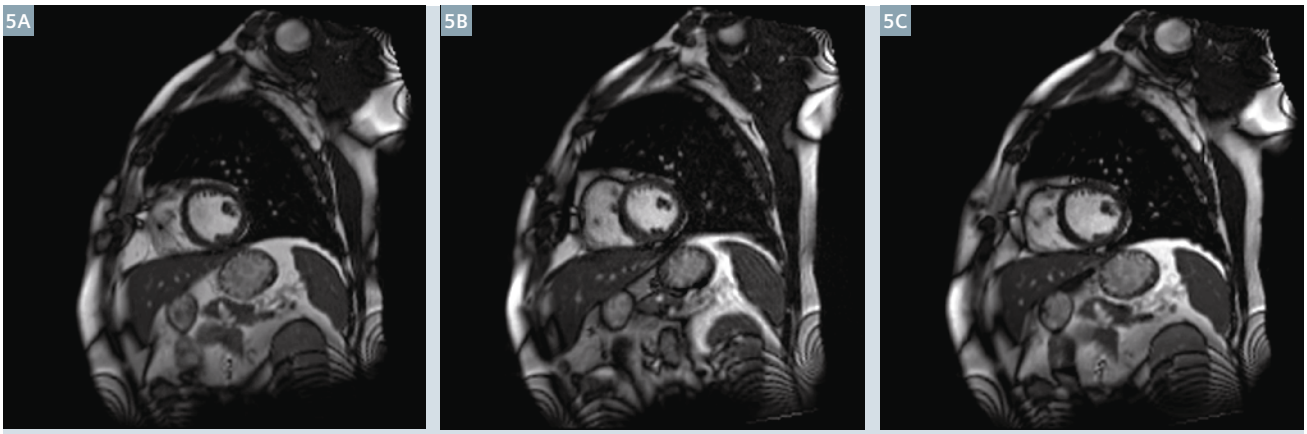

5 End-systolic short axis cine TrueFISP images from a patient with a history of myocardial infarction. A metal artifact from a previous sternotomy is noted in the sternum. There is wall thinning in the inferolateral wall with akinesia on cine views, consistent with an old infarct in the circumflex territory. **(5A)** Conventional iPAT 2, **(5B)** conventional T-PAT 4, **(5C)** iterative T-PAT 4.

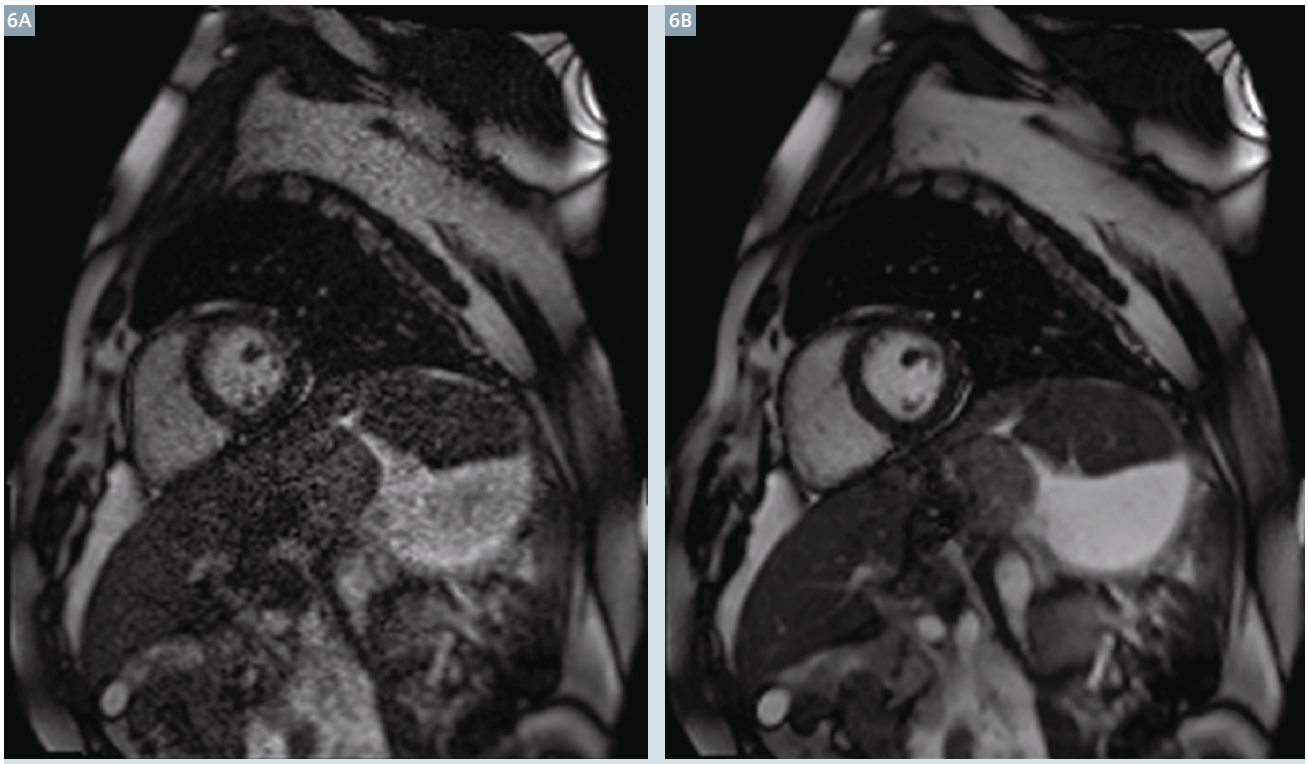

6 Real-time cine TrueFISP T-PAT 6 images reconstructed using **(6A)** conventional, and **(6B)** iterative techniques.

Acknowledgement

The authors would like to thank Judy Wood, Manger of the MRI Department at Northwestern Memorial Hospital, for her continued support and collaboration with our ongoing research through the years. Secondly, we would like to thank the magnificent Cardiovascular Technologist's Cheryl Jarvis, Tinu John, Paul Magarity, Scott Luster for their patience and dedication to research. Finally, the Resource Coordinators that help us make this possible Irene Lekkas, Melissa Niemczura and Paulino San Pedro.

References

1 Liu J, Rapin J, Chang TC, Lefebvre A, Zenge M, Mueller E, Nadar MS. Dynamic cardiac MRI reconstruction with weighted redundant Haar wavelets. In Proceedings of the 20th Annual Meeting of ISMRM, Melbourne, Australia, 2002. p 4249.

2 Candes EJ, Wakin MB. An Introduction to compressive sampling. IEEE Signal Processing Magazine 2008. 25(2):21-30. doi: 10.1109/MSP.2007.914731.

3 Block KT, Uecker M, Frahm J. Undersampled Radial MRI with Multiple Coils. Iterative Image Reconstruction Using a Total Variation Constraint. Magn Reson Med 2007. 57(6):1086-98.

4 Lustig M, Donoho D, Pauly JM. Sparse MRI: The application of compressed sensing for rapid MR imaging. Magn Reson Med 2007. 58(6):1182-95.

5 Liang D, Liu B, Wang J, Ying L. Accelerating SENSE using compressed sensing. Magn Reson Med 2009. 62(6):154-84. doi: 10.1002/mrm.22161.

6 Lustig M, Pauly, JM. SPIRiT: Iterative self-consistent parallel imaging reconstruction from arbitrary k-space. Magn Reson Med 2010. 64(2):457-71. doi: 10.1002/mrm.22428.

7 Beck A, Teboulle M. A fast iterative shrinkage-thresholding algorithm for linear inverse problems. SIAM J Imaging Sciences 2009. 2(1): 183-202.

8 Dykstra RL. An algorithm for restricted least squares regression. J Amer Stat Assoc 1983 78(384):837-842.

9 Schmidt M, Ekinci O, Liu J, Lefebvre A, Nadar MS, Mueller E, Zenge MO. Novel highly accelerated real-time CINE-MRI featuring compressed sensing with *k-t* regularization in comparison to TSENSE segmented and real-time Cine imaging. J Cardiovasc Magn Reson 2013. 15(Suppl 1):P36.

Contact

Maria Carr, RT (CT)(MR)
CV Research Technologist
Department of Radiology
Northwestern University
Feinberg School of Medicine
737 N. Michigan Ave.
Suite 1600
Chicago, IL 60611
USA
Phone: +1 312-926-5292
m-carr@northwestern.edu