

# Whole-body MR Image Reading and Bone Assessment with syngo.via Frontier MR Bone Scan

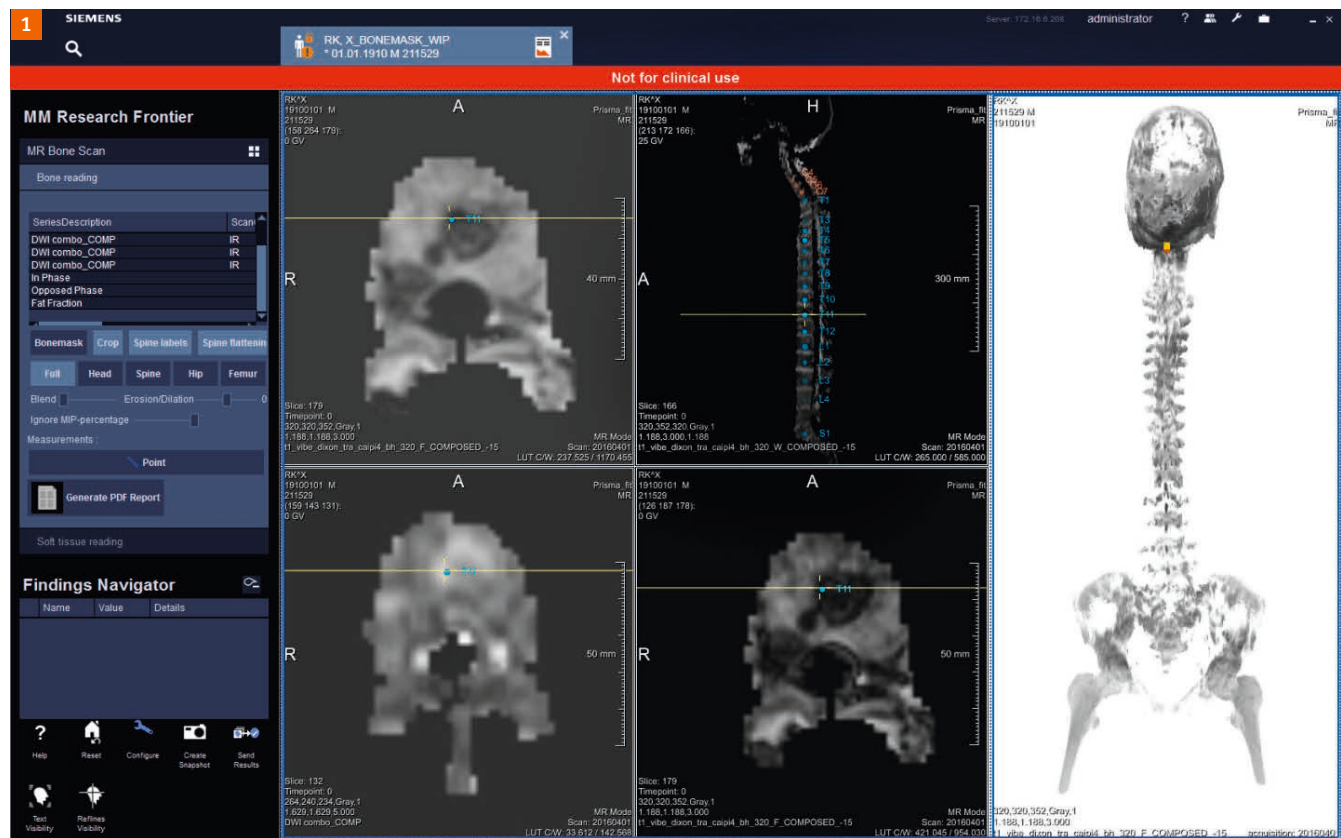
Matthias Fenchel<sup>1</sup>; Anwar R. Padhani<sup>2</sup>

<sup>1</sup> Siemens Healthineers, Erlangen, Germany

<sup>2</sup> Paul Strickland Scanner Centre, Mount Vernon Hospital, Northwood, Middlesex, UK

Whole-body MRI with diffusion imaging has gained a lot of attention as a promising technique for the assessment of multifocal bone disease, such as multiple myeloma and bone metastases from breast and prostate cancer [1–3]. Diffusion-weighted MRI in combination with other MRI contrasts has a high sensitivity and specificity for disease

detection [4], without exposing patients to ionizing radiation. However, one challenge is the relatively large effort in image interpretation, due to the number of images that are generated, and the lack of available tools for efficient evaluation.



**Figure 1:** The figure shows a snapshot of the bone reading step of the application with the cropping and the spine unrolling/flattening and spine labeling features activated. The cursor is centered at the T11 vertebral body.

Siemens has implemented a novel MR whole-body image reading prototype with a specific focus on metastatic bone disease. The vision behind this *syngo.via* Frontier MR Bone Scan<sup>1</sup> is to leverage MR and MR-PET bone reading and make it as efficient as in the *syngo*.CT Bone Reading application. As a central feature, the application computes segmentations of the axial skeleton based on Dixon input images, using an atlas based algorithm [5].

The bone segmentations can be used in several ways:

- 1) Bone segmentations can be applied to remove all other tissues on any given image contrast, thus directing the reader's attention directly to the bone and the bone marrow. When this is done with high b-value images, rotating maximum intensity projections (MIPs) can be generated that provided a focused overview of the state of the disease in the skeleton. This enables assessments of abnormalities within the bones at a single glance. The ability to automatically remove soft tissues and other extraneous signals increases metastatic conspicuity on inverted MIPs on the segmented volume. This is of advantage in metastatic prostate cancer where lesion conspicuity may be obscured by surrounding tissue signal.

The ability to isolate bones on multiple, registered image sequences such as DWI, ADC maps, in- and opposed phase Dixon, Fat Fraction and T1- and T2-weighted images with combined MIP images, enables focused, efficient multiparametric evaluations of the bones without signals and artefacts from surrounding soft tissues.

- 2) Bone segmentations can help to support visualizations like unrolling bones into a plane to simplify the geometric complexity for complete and easy assessment with few scroll moves through a reduced number of slices. In particular, the *syngo.via* Frontier MR Bone Scan allows for projecting the spine to a plane, displaying all vertebra at a single glance as a straightened flattened spine. All other image contrasts can also be warped accordingly in the unrolled spine mode.
- 3) Bone segmentations provide useful additional anatomic orientations, which helps to facilitate reporting. The vertebra of the segmented spine can be labelled, with labels presented to the user as overlays.
- 4) Bone segmentations from DWI independent image contrasts could support unbiased, quantitative multiparametric evaluation of the bone marrow also. Co-registered bone segmentations of image contrasts

such as fat fraction, ADC, high b-value signals can enable the separation of normal yellow marrow, mixed marrow, viable tumor regions, microscopic necrosis, macroscopic necrosis voxels. Co-registered voxels can be evaluated in *syngo.via* Frontier Total Tumor Load and Scatter Plot software for these purposes.

- 5) In addition, separate evaluations of the different bones are supported. For instance, the pelvic bone and its voxels can be isolated and evaluated. Quantitative values could be evaluated independently thus enabling therapy response assessment and evaluation of spatial heterogeneity if required.

*syngo.via* Frontier MR Bone Scan supports standard tools for reading and reporting such as automatic configuration of hangings, automatic scrolling and synching of the segments as well as measurement tools.

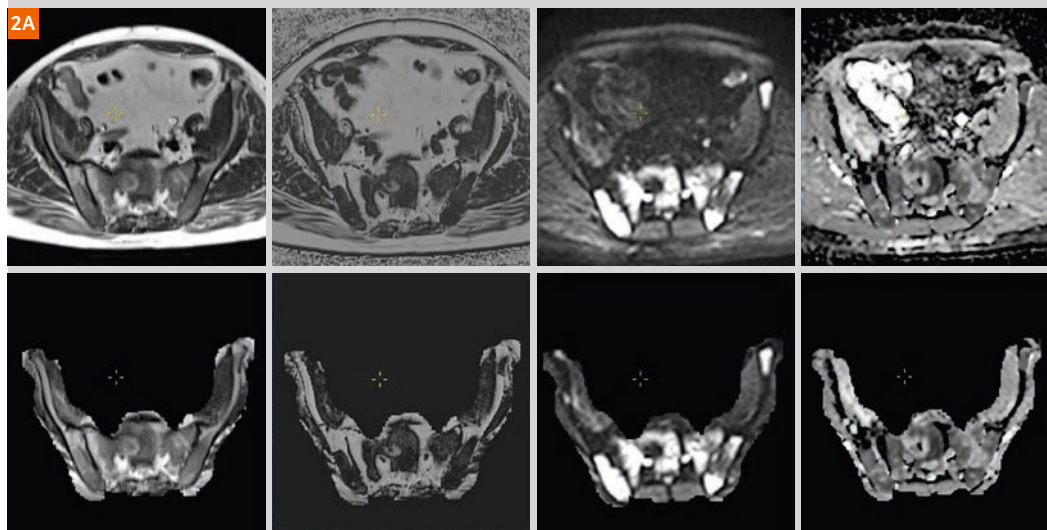
The workflow of the application is structured into two steps.

- 1) Bone reading step: Layout, hangings and tool configuration are set up for the assessment of bone metastases. The bone segmentation runs in the background and yields the bone mask that allows for the usage of the advanced visualization tools mentioned above to support the reading process.
- 2) Soft tissue reading: Layout, hangings and tool configuration are set up to assess the status of soft tissues including primary tumors, lymph node and visceral organs.
- 3) In a final step, results and findings can be exported in a report pdf sheet.
- 4) The computed bone mask can be stored back to the patient image database and be made available for secondary (quantitative) evaluation tools like *syngo.via* Frontier Total Tumor Load as an independent bone mask.

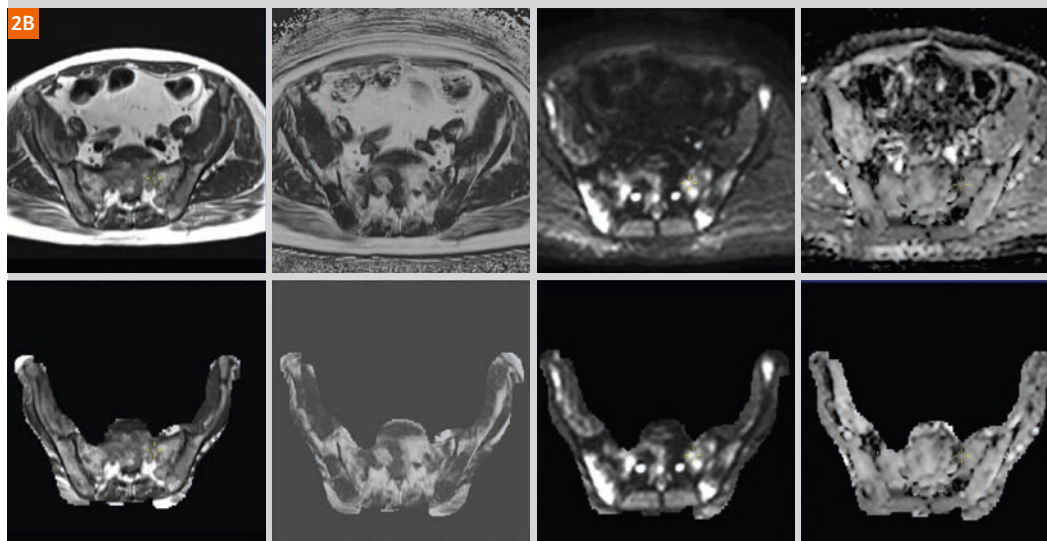
Figure 1 shows a snapshot of *syngo.via* Frontier MR Bone Scan.

The clinical case in Figure 2 shows a 70-year-old man with castrate resistant prostate cancer who has failed hormonal therapy and docetaxel chemotherapy, and is now undergoing a novel therapy that targets the prostate specific membrane antigen (PSMA) receptor. Pre- and post-therapy assessments were undertaken on a 3T MAGNETOM Prisma scanner. Note that assessments of the bone status on the whole-body inverted b800 MIP images is impaired due to signals from soft tissues, including the swollen right leg (new hip fracture on the post therapy), kidneys and bowel on both studies. After automated cropping and removal of the soft tissue signals, the response of the disease becomes easier to evaluate.

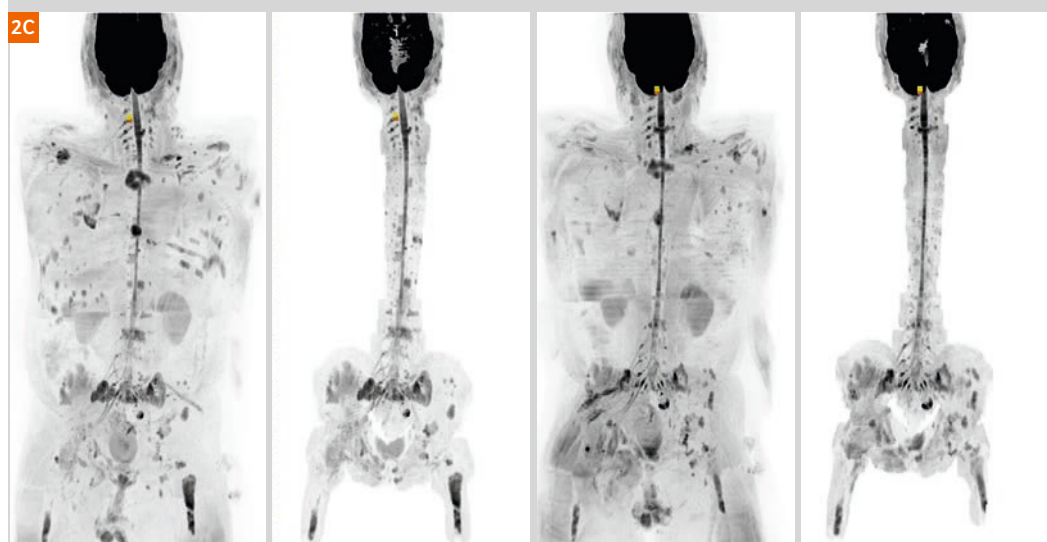<sup>1</sup> *syngo.via* Frontier is for research only, not a medical device.



**Figure 2:**  
**2A:** From left to right axial T2-weighted, fat fraction, b-value 800 mm<sup>2</sup>/s, ADC images through the sacrum before therapy. Top row before cropping and bottom row after cropping. After cropping, focused evaluations of the bones can be undertaken.



**2B:** From left to right axial T2-weighted, fat fraction, b-value 800 mm<sup>2</sup>/s, ADC images through the sacrum after therapy. Top row is before cropping and bottom row after cropping. Note increased artifacts in the anterior abdomen on the b800 images related to bowel motion. These artifacts are removed by cropping, thus allowing focused evaluations of bone response. Note decreases in b800 signal intensity and extent, with increasing ADC values are consistent with therapy response.



**2C:** Whole-body b800 MIP images (inverted scale) of the same patient as in 2A, B before and after cropping – frontal projection. Columns 1 and 2 are pre-treatment. Columns 3 and 4 after treatment. Note improved depiction of metastatic bone disease status at both time points when signals from overlying soft tissues are automatically removed. The increased soft tissue signal over the right hip after therapy is due to a new impacted hip fracture.

before therapy

after therapy



In summary, *syngo.via* Frontier MR Bone Scan is a promising application for whole-body reading enabling unbiased qualitative and quantitative assessments of bone marrow and bone lesions, with potential applications in therapy monitoring. However, it should be noted that it is still an evolving application, requiring optimizing the reading workflow for therapy response assessment in metastatic bone disease. Future developments will include layouts and tools for parallel evaluation of several time points. It is also planned to include features for direct quantitative evaluation as described in the Total Tumor Load (see article by Grimm and Padhani in this issues of MAGNETOM Flash) and seamless interactions with other *syngo.via* Frontier oncology prototypes.

#### References

- 1 Pawlyn C, Fowkes L, Otero S, et al. Whole-body diffusion-weighted MRI: a new gold standard for assessing disease burden in patients with multiple myeloma? Leukemia. 2016;30(6):1446-1448. doi:10.1038/leu.2015.338.
- 2 Padhani AR, Lecouvet FE, Tunariu N, Koh DM, De Keyzer F, et al. (2016) Rationale for Modernising Imaging in Advanced Prostate Cancer. European Urology Focus, Available online. doi:10.1016/j.euf.2016.06.018.
- 3 Padhani AR and Tunariu N, Metastatic response system in using whole body MRI for prostate cancer in practice – also in this issue of MAGNETOM Flash.
- 4 Li B, Li Q, Nie W, Liu S. Diagnostic value of whole-body diffusion-weighted magnetic resonance imaging for detection of primary and metastatic malignancies: a meta-analysis. European Journal of Radiology 2014; 83(2): 338-344.
- 5 Paulus DH, Quick HH, Geppert C, Fenchel M, Zhan Y, Hermosillo G, Faul D, Boada F, Friedman KP, Koesters T. Whole-Body PET/MR Imaging: Quantitative Evaluation of a Novel Model-Based MR Attenuation Correction Method Including Bone. J Nucl Med. 2015 Jul;56(7):1061-6.

#### Contact




Matthias Fenchel, Ph.D.  
Siemens Healthcare GmbH  
HC DI MR PI TIO ONCO  
  
Postbox 32 60  
91050 Erlangen  
Germany  
Phone: +49 (0) 9131 84-2113  
matthias.fenchel@siemens.com

## Watch Cancer Develop Multidrug Resistance

In this video Professor Padhani shows how quantitative whole-body MRI is used to monitor therapy response in metastatic breast cancer. Watch the video at

[www.siemens.com/magnetom-world](http://www.siemens.com/magnetom-world)



**Watching cancer develop multidrug resistance**

Quantitative whole-body MRI to monitor therapy response in metastatic breast cancer

Professor Anwar R. Padhani, MB, BS, FRCP, FRCP  
Paul Strickland Scanner Centre, Mount Vernon Hospital, Northwood, Middlesex, UK

**ADC classes and cellular states**  
Cellular tumor, microscopic cell death, macroscopic necrosis

MR Total Tumor Load 12.8

Cellular tissue: 72%  
Microscopic cell death: 95 centile of baseline study  
Macroscopic necrosis: 1500  $\mu\text{m}^2/\text{s}$

**Response Sept 2012 Visceral disease: Liver**

1<sup>st</sup> line Rx

2012 2013 2014 2015 2016

Exemestane, Herceptin  
Herceptin, Pertuzumab, Docetaxel

90%  
95 centile of baseline study  
1500  $\mu\text{m}^2/\text{s}$