

# Metastatic Prostate Cancer in Practice – the MET-RADS-P Imaging Response System Using Whole-body MRI

Anwar R. Padhani<sup>1</sup>; Nina Tunariu<sup>2</sup>

<sup>1</sup> Paul Strickland Scanner Centre, Mount Vernon Hospital, Northwood, Middlesex, UK

<sup>2</sup> Royal Marsden NHS Foundation Trust & Institute of Cancer Research and Cancer Research UK Cancer Imaging Centre, Sutton, Surrey, UK

## Introduction

Whole-body MRI (WB-MRI) is an increasingly used, radiation-free imaging method for assessing bone and soft tissue pathology, and for evaluating response to therapy [1]. WB-MRI has been developed to overcome the limitations of Bone Scintigraphy (BS) and Computed Tomography (CT) for detection and therapeutic response assessments in bone metastases [2]. Although increasingly used and recommended by international guidelines for multiple myeloma [3], WB-MRI usage has been confined mainly to expert centers, causing some concerns about its broader applicability. While WB-MRI can be performed on almost all modern MRI scanners, inconsistencies in WB-MRI acquisition protocols and reporting standards have prevented its widespread testing and implementation, beyond the indication for multiple myeloma.

Recently, a group of oncologic imaging specialists teamed with a leading urologist and oncologist, to develop recommendations on the minimum requirements for WB-MRI acquisition protocol as well as standardized reporting guidelines. They recognized that for this promising method to become mainstream it is vital to enforce some uniformity in acquisition, interpretation, and reporting. The authors have named their formulation for metastatic disease response and diagnostic system for prostate cancer as MET-RADS-P (METastasis Reporting And Data System for Prostate cancer) [4].

## Why MET-RADS is needed

BS/CT scans are widely used and endorsed by international guidelines as the standard imaging investigations in the staging and follow-up of metastatic prostate cancer, thereby affecting patient management [5, 6]. However, it is increasingly clear that currently used imaging methods are limited in their effectiveness in directing therapy and may no longer be relevant in the era of high-precision medicine, where an increasing number of cytostatic and novel therapies are becoming available [2]. For example, the accepted minimum lymph node diameter (10 mm – short axis) on CT scan as measure of involvement is only modestly correlated with the presence of malignant disease, and CT cannot accurately evaluate the presence or the therapeutic response in bone

metastases, the commonest metastatic site in prostate cancer. Conversely, increased BS uptake in number and extent of lesions can equally occur with the osteoblastic healing (FLARE reaction) associated with tumor response and with the osteoblastic progression associated with tumor burden increase, thus creating confusion between response and progression, when response to therapy is being assessed. Next generation whole-body imaging tools such as PET with targeted tracers and WB-MRI with diffusion-weighted sequences are emerging as powerful alternatives; however, the challenge remains in validating these newer imaging approaches, so that their use can be justified in the clinical routine.

An important step in this process is to ensure uniformity in the acquisition, interpretation, and reporting of next generation whole-body imaging methods, so that multicenter trials leading to validation of these methods can be more easily performed and evaluated. An important step for WB-MRI is the new MET-RADS-P standard for use in patients with advanced prostate cancer [4]. The standard establishes minimum acceptable technical parameters for imaging acquisitions built with sequences already available on most modern scanners. Of the sequences recommended, it is acknowledged that whole-body diffusion-weighted sequences are the most challenging to implement across imaging platforms. These sequences have been grouped to enable fast, high-quality examinations for tumor detection and response assessments (core and comprehensive protocols respectively). Image quality control and quality assurance procedures are also detailed by the standard. The MET-RADS-P standard is designed to offer day-to-day reporting guidance, paired with a detailed reporting tool that describes the disease phenotype based on anatomic patterns of metastatic spread thus, enabling systematic collection of analyzable data for research purposes.

Comprehensive response criteria for bone and soft tissue metastases and local disease have been proposed, with the ability to summarize the likelihood of a response to treatment, using a Likert-like 1–5 scale. It is important to note that the summarized likelihood of response in bone, uses newly developed MET-RADS criteria, but the response in soft-tissues continues to be based on long established

1A

Physician

Exam date current

Exam date comparator

Soft tissues RECIST	MET-RADS Prostate Report							Bones MET-RADS
<b>Primary</b> Involved Y N RAC 1+ 2+ Comment								<b>Skull</b> Involved Y N RAC Comment
<b>Pelvic nodes</b> Involved Y N RAC 1+ 2+ Comment								<b>Cervical spine</b> Involved Y N RAC 1+ 2+ Comment
<b>Retroperitoneal</b> Involved Y N RAC 1+ 2+ Comment								<b>Dorsal spine</b> Involved Y N RAC 1+ 2+ Comment
<b>Other nodes</b> Involved Y N RAC 1+ 2+ Comment	<b>OVERALL ASSESSMENT</b>							<b>Lumbosacral spine</b> Involved Y N RAC 1+ 2+ Comment
		No dis	CR	PR	SD	PD	DISCORD	
	Primary							
	Nodes						No/minor/major only for PR/SD categories	
<b>Liver</b> Involved Y N RAC 1+ 2+ Comment	Viscera							<b>Pelvis</b> Involved Y N RAC 1+ 2+ Comment
	Bones			RAC 1/2	RAC2	RAC 4/5		
	Comments							<b>Thorax</b> Involved Y N RAC 1+ 2+ Comment
<b>Lungs</b> Involved Y N RAC 1+ 2+ Comment								<b>Limbs</b> Involved Y N RAC 1+ 2+ Comment
<b>Other sites</b> Involved Y N RAC 1+ 2+ Comment								

Response assessment categories (RAC): 1 Highly likely to be responding; 2 Likely to be responding; 3 No change; 4 Likely to be progressing; 5 Highly likely to be progressing. Single lesion 1+ RAC only; ≥2 lesions/diffuse disease use both RACs

METastasis Reporting and Data System for Prostate Cancer: Practical Guidelines for Acquisition, Interpretation, and Reporting (MET-RADS-P) of Whole-body MRI Evaluations of Metastatic Involvement in Advanced Prostate Cancer. Eur Urol. 2017 Jan;71(1):81-92.

Radiologist

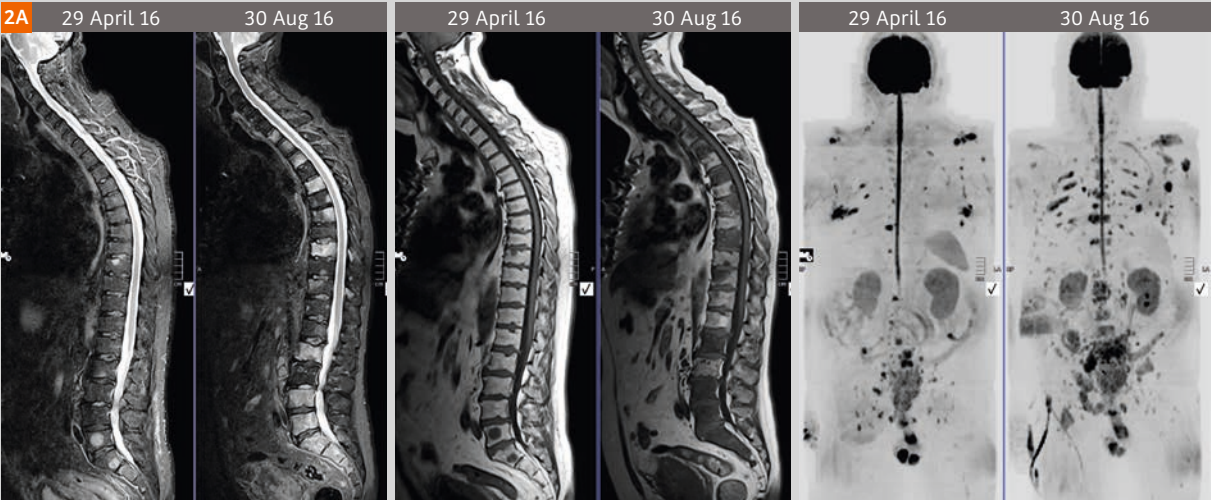
Date

1B	RAC	Region Local, nodal and visceral	MET-RADS-P Description
			Consistent with RECIST v1.1/PCWG criteria for unequivocal response (partial/complete).
1	Highly likely to be responding	Bone	<p>Return of normal marrow in areas previously infiltrated by focal/diffuse metastatic infiltration</p> <p>Decrease in number/size of focal lesions</p> <p>Evolution diffuse neoplastic pattern to focal lesions</p> <p>Decreasing soft tissue associated with bone disease</p> <p>Dense lesion sclerosis (edge to edge), sharply defined, very thin/disappearance of hyperintense rim on T2W-FS images</p> <p>The emergence of intra/peri-tumoural fat within/around lesions (fat dot/halo signs)</p> <p>Previously evident lesion shows increase in ADC from <math>\leq 1400 \mu\text{m}^2/\text{s}</math> to <math>&gt;1400 \mu\text{m}^2/\text{s}</math></p> <p><math>\geq 40\%</math> increase in ADC from baseline with corresponding decrease in high b-value SI; and morphological findings consistent with stable or responding disease</p>
2	Likely to be responding	Local, nodal and visceral  Bone	<p>Changes depicting tumour response that do not meet RECIST v1.1/PCWG criteria for partial or complete response (see below)</p> <p>Evidence of improvement, but not enough to fulfil criteria for RAC 1. For example: Previously evident lesions showing increases in ADC from <math>\leq 1000 \mu\text{m}^2/\text{s}</math> to <math>&lt;1400 \mu\text{m}^2/\text{s}</math></p> <p><math>&gt;25\%</math> but <math>&lt;40\%</math> increase in ADC from baseline with corresponding decrease in high b-value SI; and morphological findings consistent with stable or responding disease</p>
3	No change	All	No observable change
4	Likely to be progressing	Local, nodal and visceral  Bone	<p>Changes depicting tumour progression that do not meet RECIST v1.1/PCWG criteria for progression</p> <p>Evidence of worsening disease, but not enough to fulfil criteria for RAC 5.</p> <p>Equivocal appearance of new lesion(s)</p> <p>No change in size but increasing SI on high b-value images (with ADC values <math>&lt;1400 \mu\text{m}^2/\text{s}</math>) consistent with possible disease progression</p> <p>Relapse disease: re-emergence of lesion(s) that previously disappeared or enlargement of lesion(s)</p> <p>Lesions that had partially regressed/stabilized with prior treatments</p> <p>Imaging depicted bone lesions that might be clinically significant (therefore excludes asymptomatic fractures in non-critical bones)</p> <p>Soft tissue in spinal canal causing narrowing not associated with neurological findings and not requiring radiotherapy</p>
5	Highly likely to be progressing	Local, nodal and visceral  Bone	<p>Tumour progression that meet RECIST v1.1/PCWG criteria for unequivocal progression</p> <p>New critical fracture(s)/cord compression requiring radiotherapy/surgical intervention -&gt; only if confirmed as malignant by MRI signal characteristics</p> <p>Unequivocal new focal/diffuse area(s) of metastatic infiltration in regions of prior normal marrow</p> <p>Unequivocal increase in number/size of focal lesions</p> <p>Evolution of focal lesions to diffuse neoplastic pattern</p> <p>Appearance/increasing soft tissue associated with bone disease</p> <p>New lesions/regions of high signal intensity on high b-value images with ADC value between 600-1000 <math>\mu\text{m}^2/\text{s}</math></p>
Response Assessment Criteria (RAC) allocation rules – compare to relevant baseline scan			
<p>The primary RAC value is based on the dominant response of more than half of the disease within the region; The secondary RAC value is for the second most frequent pattern of response.</p> <p>For a single lesion in a region only the primary number category is assessed. Regions with multiple lesions/diffuse disease, all with the same RAC, both the primary and secondary have the same values;</p> <p>When equal numbers of lesions are of higher and lower RACs then the primary pattern allocation is reserved for the higher RAC</p>			
RECIST v1.1 categories			
<ul style="list-style-type: none"> <li>Complete Response (CR): Disappearance of all target lesions</li> <li>Partial Response (PR): At least a 30% decrease in the sum of the longest diameter (LD) of target lesions, taking as reference the baseline sum LD</li> <li>Stable Disease (SD): Neither sufficient shrinkage to qualify for PR nor sufficient increase to qualify for PD, taking as reference the smallest sum LD since the treatment started</li> <li>Progressive Disease (PD): At least a 20% increase in the sum of the LD of target lesions, taking as reference the smallest sum LD recorded since the treatment started or the appearance of one or more new lesions</li> </ul>			
Progression of local prostate disease: Use RECIST v1.1 for progression criteria above applied to local disease			
Progression of nodes (short axis)			
<ul style="list-style-type: none"> <li><math>&lt;1.0</math> cm nodes have to have grown by at least 5mm in from baseline or treatment nadir and be <math>\geq 1</math> cm to be considered to have progressed</li> <li>For nodes that are 1.0-1.5 cm that have grown by at least 5 mm from baseline or treatment nadir and are <math>\geq 1.5</math> cm in short axis can be considered to have progressed</li> <li>For nodes <math>\leq 1.5</math> cm short axis use RECIST v1.1 progression criteria</li> </ul>			
Progression of visceral disease: Use RECIST v1.1 progression criteria above applied to visceral disease			

**Figure 1B:** Criteria for regional response assessment categories (RACs) that summarize likelihood of response in bone disease employ the newly developed MET-RADS criteria, but RACs for response in soft-tissues uses established standards already prescribed by RECIST v1.1 and PCWG guidance [7, 8]. Response assessment is indicated on a 1–5 scale indicating the likely RAC for each location, comparing to the baseline study (RAC-1, indicates highly likely to be responding, up to RAC-5, indicating highly likely to be progressing).



**Figure 2: Primary resistance to hormonal therapy**  
67-year-old male with metastatic castrate resistant prostate cancer (mCRPC).  
WB-MRI examinations before and on androgen deprivation therapy (Abiraterone and Goserelin).



**Figure 2A:** Marked disease progression can be seen on morphology T1-weighted and STIR sequences and on WB b900 MIP images and confirmed by ADC measurements (see Fig. 2D also). Disease progression is seen in the prostate gland with extensive bladder invasion together with rectal invasion. There is disease progression in pelvic and retroperitoneal lymph nodes with nodal enlargement in the left axilla also. There is bone disease progression throughout the spine with extra-osseous soft tissue disease with new and enlarging deposits. No liver or lung disease is seen. The spinal stenosis at L3/L4 is degenerative in nature.

2B

30/08/2016 MRI Whole body

**Clinical details:** mCRPC. Restaging post urinary diversion. On Abiraterone and zoledex.

**Technique:** A whole-body MRI scan with whole body diffusion sequences. Comparison is made to the previous whole-body MRI scan dated 29/04/2016.

**Findings:**

**Cervical and dorsal spine:**

The intervertebral bony alignment is normal. Regrettably, there is marked disease progression. New metastases are seen throughout the cervical and dorsal spine with multifocal lesions. No interval loss of vertebral height. The craniocervical junction is normal. The cervical and dorsal cord outline normally.

**Lumbosacral spine:**

The intervertebral bony alignment remains normal with no interval loss of vertebral height. Degenerative spinal stenosis at L3/L4 as noted on the previous occasion. Regrettably, there is marked disease progression in the lumbosacral spine since the previous study.

**Body scan:**

No skull vault deposits have emerged. Normal sinonasal airways.

No supraclavicular fossa lymphadenopathy. Progressive left axillary lymphadenopathy also.

There is marked disease progression left scapula bone with extra osseous soft tissue disease now visible. Marked disease progression the ribs bilaterally also. There are artefacts are sternotomy wires.

The central mediastinal and hilar regions are normal. No lung abnormalities are detected.

The liver and spleen are homogeneous. Normal pancreas and adrenal glands. Both kidneys are unobstructed with bilateral renal stents in situ. Small retroperitoneal lymph nodes are also detected.

Extensive metastatic bone disease is present in the sacrum predominantly on the left side, right and left hemipelvis bone disease also.

Nodal disease in the common iliac regions bilaterally. Right obturator region with extra nodal tumour spread.

There is large locally advanced prostate carcinoma with bladder and ureteric involvement. No tumour involvement of the rectum or rectosigmoid junction.

Metastatic disease in the right proximal femur also.

**Impression:**

There is marked disease progression since 29/04/2016. Disease progression is seen locally the prostate gland with extensive bladder invasion. There is disease progression within pelvic and retroperitoneal lymph nodes with extra nodal tumour spread. There is disease progression in the left axilla also. Bone disease progression additionally throughout the spine with extra-osseous soft tissue disease also visible. No new visceral relapse of disease.

Please see graphical MET-RADS-P report also.

2C

Physician PO

Exam 30/8/16

Exam 29/4/16

Soft tissues	MET-RADS Prostate Report						Bones
RECIST							MET-RADS
Primary Involved Y							Skull Involved N
RAC 3/5							RAC N
Rectal and bladder involvement							Comment
Pelvic nodes Involved Y							Cervical spine Involved N
RAC 3/5							RAC N
Comment							Comment
Retroperitoneal lymph nodes Involved Y							Dorsal spine Involved Y
RAC 3/5							RAC N
Comment							Comment
Other nodes							Lumbosacral spine Involved Y
Involved Y							Involved N
RAC 3/5							RAC N
Comment							Comment
Left axilla							Pelvis Involved Y
							Involved N
							RAC N
							Comment
Liver							Thorax Involved Y
Involved N							Involved N
RAC N							RAC N
Comment							Comment
Lungs							Limbs Involved Y
Involved N							Involved N
RAC N							RAC N
Comment							Comment
Other sites							
Involved N							
RAC N							
Comment							

**OVERALL ASSESSMENT**

	No dis	CR	PR	SD	PD	DISCORD
Primary					✓	
Nodes					✓	No/minor/major only for PR/SD categories
Viscera					✓	
Bones	✓					

Comments: Bladder and rectal involvement by primary tumor.

**Response assessment categories (RAC):** 1 Highly likely to be responding; 2 Likely to be responding; 3 No change; 4 Likely to be progressing; 5 Highly likely to be progressing. Single lesion 1\* RAC only; a2 lesions/diffuse disease use both RACs

MET-RADS Reporting and Data System for Prostate Cancer: Practical Guidelines for Application, Interpretation, and Reporting (MET-RADS-P) of Whole-body MRI Evaluations of Multisite Involvement in Advanced Prostate Cancer, Eur Urol. 2017 Jan;71(1):85-92.

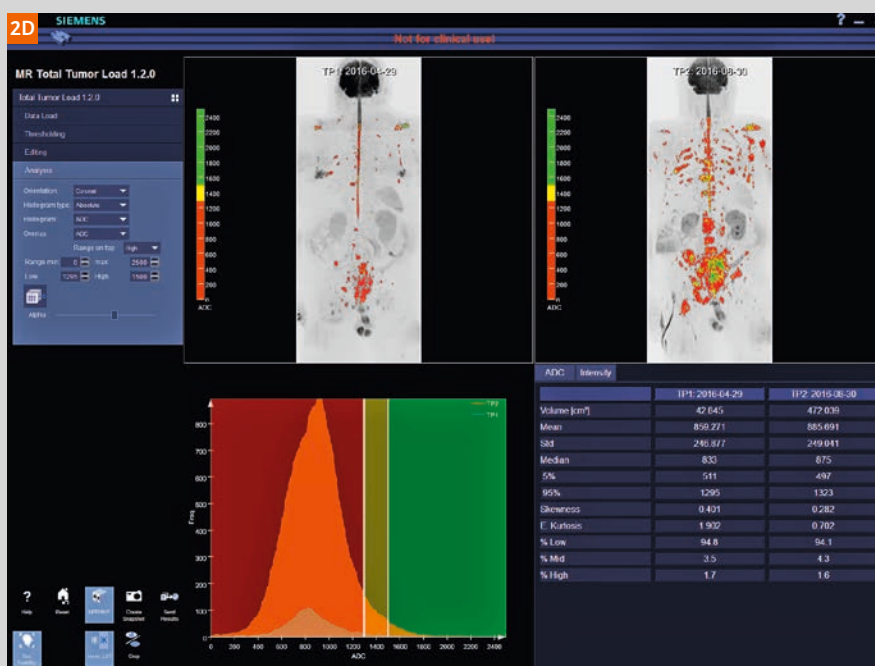**Figure 2B:** Original text report for the follow-up examination that accompanies the MET-RADS-P template report.

**Figure 2C:** Completed MET-RADS-P template report indicating sites of disease and RACs at each anatomical location compared to the baseline study. The presence of unequivocal identified disease is indicated together with primary and secondary RACs at each site using the criteria set out in Figure 1B. Short relevant comments are included for clarification purposes where needed.

**Figure 2D:** WB-tumor load segmentation undertaken on syngo.via Frontier MR Total Tumor Load software (Siemens Healthcare; released research prototype – not part of the MET-RADS-P standard) for illustrative purposes only.

The whole-body b900 images are segmented using computed high b-value images of 1200 s/mm<sup>2</sup> and signal intensity threshold of approximately 100 AU. Extraneous signals (such as the brain, kidneys, bowel, gonads) are removed to leave only recognizable disease sites. The color the b900 MIP images are overlaid with ADC value classes using the thresholds indicated. The green voxels are values  $\geq 1500 \mu\text{m}^2/\text{s}$  (representing voxels that are 'highly likely' to be responding). The yellow voxels are set to lie between the 95<sup>th</sup> centile ADC value of the pre-treatment histogram (1295  $\mu\text{m}^2/\text{s}$ ) and 1500  $\mu\text{m}^2/\text{s}$  thus representing voxels 'likely' to be responding. Red-voxels represent mostly untreated disease.

43 mL of tumor are segmented before therapy and 472 mL on therapy. Note that there is no significant global increase in ADC values (859  $\mu\text{m}^2/\text{s}$  and 885  $\mu\text{m}^2/\text{s}$ ) on the corresponding absolute frequency histograms. There is also no increase in the standard deviation of the histogram (247 and 249  $\mu\text{m}^2/\text{s}$ ). Note increased extent and volume of red-voxels consistent with disease progression (95% before therapy and 94% after therapy).



standards, prescribed by RECIST v1.1 and PCWG, the Prostate Cancer Working Group [7, 8] for clinical research. Discordant responses in which progressing and responding lesions are seen at same time point, are increasing seen with the use of targeted therapies and are a recognized manifestation of tumor heterogeneity. MET-RADS-P proposes methods to record the presence, location and extent of discordant responses between and within body parts. The use of MET-RADS-P enables for the first time to categorize bone disease response into 3 categories (progressive disease, stable disease and response), rather than the clinically recommended categories (progression/no progression) when using BS/CT scans [8], thus mirroring response assessments in soft tissues disease.

The benefits of using a standardized approach include enhanced data collection for outcomes monitoring in clinical trials and from patient registries, enhancing the education of radiologists to reduce variability in imaging interpretations, and for improving communication with referring clinicians. The MET-RADS-P authors state that the new way of response categorization from 2 categories used currently, to 3 categories when assessing bone disease response, could lead to a paradigm shift from the current concept of treating patients to documentable progression (when tumor volume could be substantially greater than baseline), to being guided

by the presence or absence of benefit to therapy thus introducing more nuanced delivery of patient care.

## MET-RADS-P template form

### Response assessment categories (RACs)

An updated MET-RADS-P template form can be found in Figure 1 and is available as a pdf document at: [www.siemens.com/magnetom-world](http://www.siemens.com/magnetom-world).

The use of MET-RADS-P system starts by allocating the presence of unequivocal identified disease based on morphology and signal characteristics on all acquired images to 14 predefined regions of the body (primary disease, seven skeletal and three nodal regions, lung, liver and other soft tissue sites) at baseline and on follow-up assessments (see page 1 of the MET-RADS-P template form Figure 1A).

For follow-up studies, a response assessment on a scale of 1–5 indicating the likely response assessment category (RAC) for each location is recorded, comparing to the baseline study (RAC-1, indicating highly likely to be responding, up to RAC-5, indicating highly likely to be progressing).

The reporting guideline provides detailed explanations of the imaging criteria to be used to classify the likelihood of response in bones. Thus, RACs that summarize likelihood

of response in bone disease employ the newly developed MET-RADS criteria (Fig. 1B), but RACs for response in soft-tissues continues to use established standards already prescribed by RECIST v1.1 and PCWG guidance [7, 8].

For each region, only 2 RACs are needed to account for heterogeneity of responses that may occur in different anatomic areas. The primary RAC value (1–5) is based on dominant pattern of response within the region (that is, the response shown by more than half of the lesions within the region). A secondary RAC value (1–5) is assigned to the second most frequent pattern of response seen within the region.

A tertiary RAC value (4–5) maybe assigned to the region to illustrate progressing disease (i.e. RAC 4–5), if not already captured by the primary or secondary RAC values but this is not usually necessary in clinical practice.

When assessing a single lesion in a region, only the primary number category is used. Regions with multiple lesions all with the same pattern of response will have the same RAC value assigned as both the primary and secondary RACs. When equal numbers of lesions are category RAC 4/5 (progressing) as RAC 1/2/3 (responding & stable), then the primary pattern allocation is reserved for RAC 4/5 (the higher category). Similarly, when equal numbers of lesions are category RAC 1/2 as RAC 3, then the primary pattern allocation is reserved for RAC 3 (the higher category).

### Overall response

The final response assessment consists of separately assessing the status of the primary disease, bones, nodes, and viscera without an overall patient response result. The overall patient assessment should be summarized in the text report which should accompany the MET-RADS-P template report (Figs. 2B, C).

Unlike regional response assessments which allocate RACs, the overall response for the primary tumor, nodal and visceral disease should be categorical, thus following established guidelines [7, 8], to improve communication with clinicians who are already familiar with this format. The following categories should be assigned: no disease (ND), complete response (CR), partial response (PR), stable disease (SD) and progressive disease (PD).

In contradistinction, the overall response of bone disease should be categorized on a scale of 1–5 indicating the likely overall response category: (1) highly likely to be responding, (2) likely to be responding, (3) stable, (4) likely to be progressing and (5) highly likely to be progressing.

Discordance or mixed response indicates the presence of progressing bone/soft tissue disease, not meeting definite progression criteria in the primary category, that is, when the majority of disease is stable or responding.

Discordant response should also be separately reported for primary, nodal, viscera and bone; evaluation of regional responses will enable the specific identification of the anatomic sites of mixed responses.

When discordant response is observed, the degree of discordance should be indicated major or minor to indicate in the evaluators opinion on whether alternative therapy options should be considered.

ADC value measurements should be made using a region-of-interest (ROI) technique on ADC images. Due to the lower spatial resolution of WB-MRI compared to CT scans, a 1.5 cm diameter threshold for bone lesions ROI is recommended for ADC measurements.

ADC measurements in bone disease should only be obtained from lesions that have sufficient signal intensity detected on all b-value images (including b0); otherwise the ADC values will be erroneous, reflecting only the noise in the images. Note that the absence of tissue signal on highest b-value images does not exclude tissues from ADC measurements because signal maybe present at lower b-values (thus, low or intermediate b-value images should be chosen instead for ROI placements).

### Research components

Because of the need to unequivocally identify disease and to cope with the lower spatial resolution of WB-MRI compared to CT scans, a 1.5 cm diameter threshold for lesion size assessments is advised. Lesion size should be measured on anatomic T1-weighted images where possible.

Note that progression assignments for soft tissues, if based on measurements should be from baseline or the treatment induced summed measurement nadir, whichever is lower as per the RECIST v1.1 guidelines [7].

The type of progression (new disease versus growth of existing lesions) should be separately recorded; the location of progression can be accessible from the regional response assessments.

RACs at each time point should be compared to the baseline (pre-treatment) study for clinical use, but maybe referenced to the immediate prior study for research purposes if needed.

Whole-body tumor segmentations and histogram analysis are not part of the MET-RADS-P standard but can be used as ancillary tools if available (and are used in this paper for illustrative purposes only).

### Worked up examples

An updated MET-RADS-P template form and detailed bone response assessment criteria can be found in Figure 1 and is available as a pdf document at [www.siemens.com/magnetom-world](http://www.siemens.com/magnetom-world).

Figures 2–4 illustrate the use of the MET-RADS-P standard in advanced, metastatic prostate cancer illustrated with examples of disease progression, responding and discordant responses.

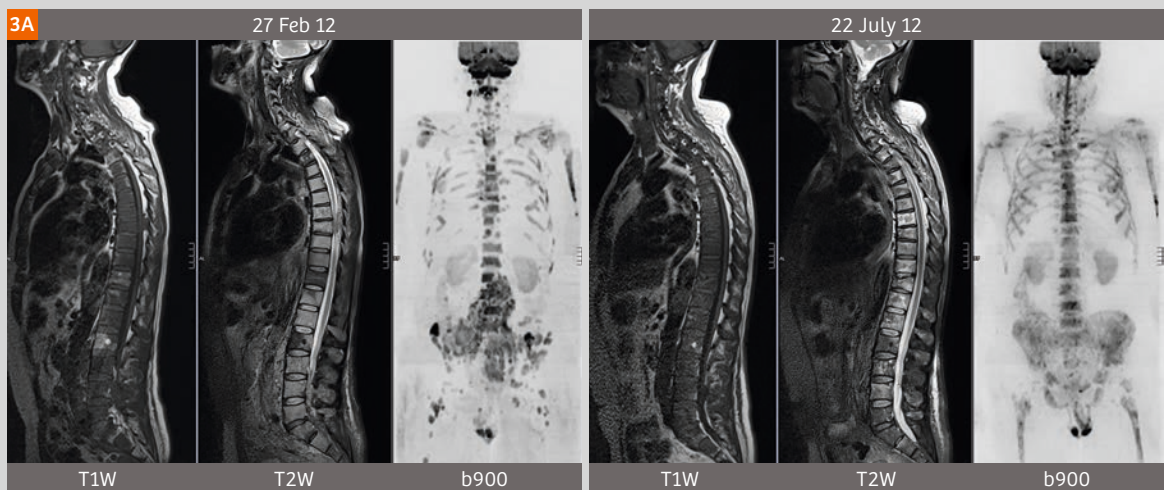
The figures also demonstrate the utility of the WB-tumor load segmentation which is undertaken with the MR Total Tumor Load prototype, a released research software tool available on [syngo.via](http://syngo.via) Frontier (Siemens Healthcare,



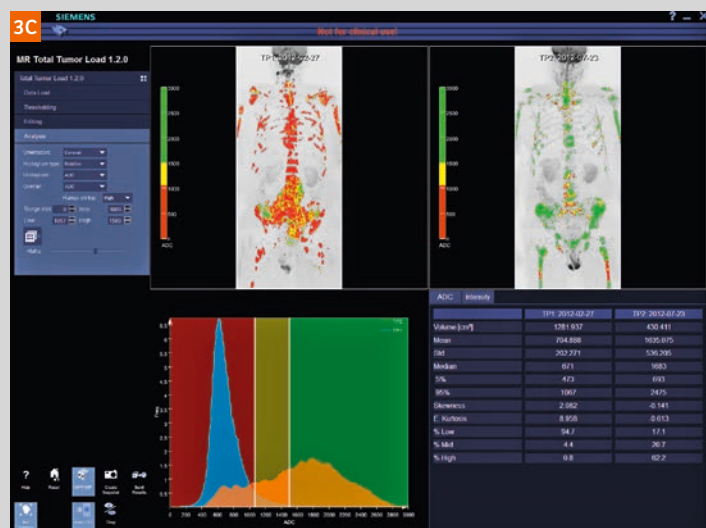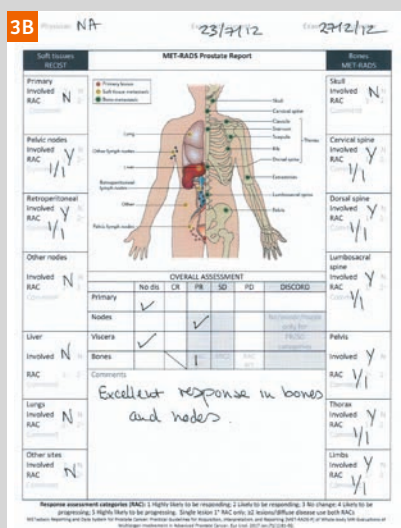
### Figure 3: Excellent response to chemotherapy

65-year-old male with metastatic castrate naive prostate cancer (mCNPC).  
WB-MRI examinations before and after 4 cycles of docetaxel, goserelin and prednisolone therapy.

**Figure 3A:** There is improvement in the spinal canal narrowing in the mid-dorsal and lumbar spine on the T2W-FS images. The T1-weighted images are essentially unchanged or possibly minimally worse. There is also marked improved appearances of the bone and nodal disease on the paired WB b900 MIP images (inverted scale) and confirmed by significant increase in ADC values (see Figure 3C) of the bone lesions and reduction in size of the nodes.



**Figure 3B:** Completed MET-RADS-P template report indicating sites of disease and RACs at each anatomical location compared to the baseline study. Note how the overall response at the primary tumor is indicated as no disease (previous radiotherapy). The overall pelvic nodal and retroperitoneal disease is excellent indicated as partial response (PR). The bone disease response is indicated by category 1 (highly likely to be responding).



**Figure 3C:** WB-tumor load segmentation undertaken on syngo.via Frontier MR Total Tumor Load software (Siemens Healthcare; released research prototype – not part of the MET-RADS-P standard) for illustrative purposes only.

The whole-body b900 images are segmented using computed high b-value images of 1000 s/mm<sup>2</sup> and signal intensity threshold of approximately 30 AU. Extraneous signals (such as the brain, kidneys, bowel, gonads) are removed to leave only recognizable disease sites. The thresholded mask is overlaid with ADC value classes using the thresholds indicated and superimposed onto the b900 MIP images. The green voxels are values  $\geq 1500 \mu\text{m}^2/\text{s}$  (representing voxels that are 'highly likely' to be responding). The yellow voxels are set to lie between the 95<sup>th</sup> centile ADC value of the pre-treatment histogram ( $1067 \mu\text{m}^2/\text{s}$ ) and  $1500 \mu\text{m}^2/\text{s}$  thus representing voxels 'likely' to be responding. Red-voxels represent mostly untreated disease.

1281 mL of bone marrow and retroperitoneal nodal disease were segmented before therapy and 430 mL on therapy. Note that there is marked global increase in ADC values ( $705 \mu\text{m}^2/\text{s}$  and  $1635 \mu\text{m}^2/\text{s}$ ) on the corresponding relative frequency histograms. There is a marked decrease in excess kurtosis of the histograms (9.0 and -0.60). Note decreased extent and volume of red-voxels consistent with disease response (95% before therapy and 17% after therapy). The residual red regions on the post therapy scan are presumed to represent residual disease with low ADC values in the lower lumbar spine and in the left proximal femur.

**Figure 4: Discordant response to Radium-223 therapy**

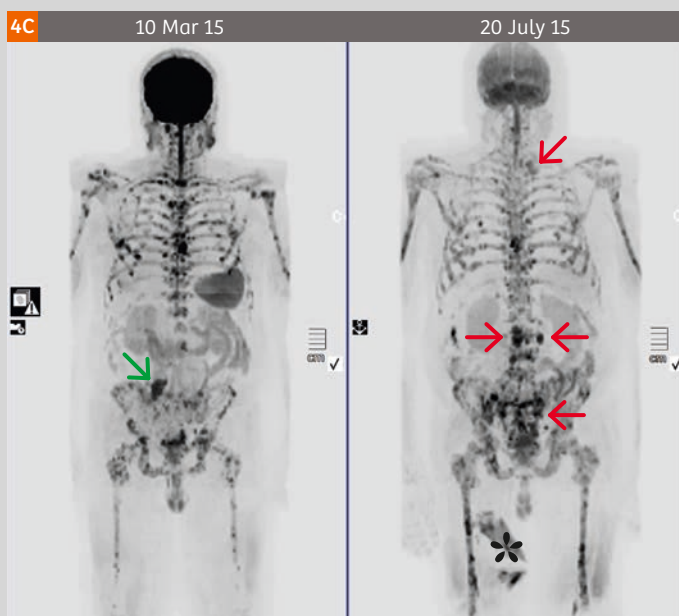
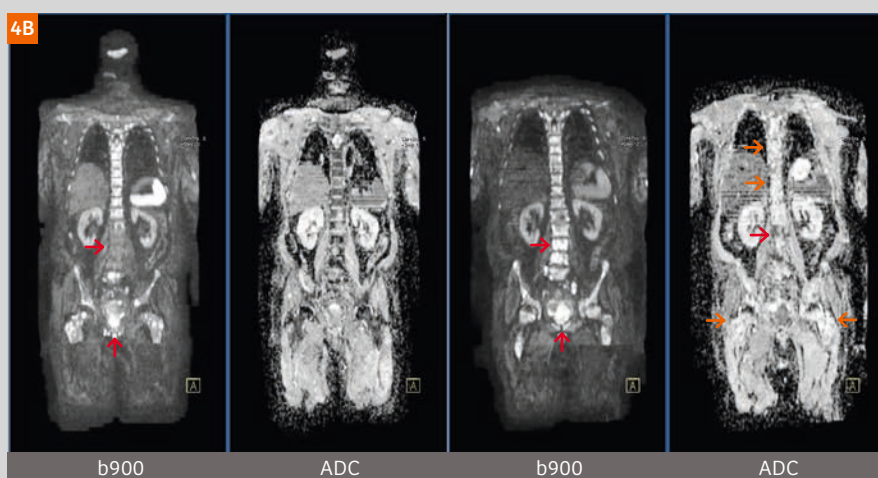
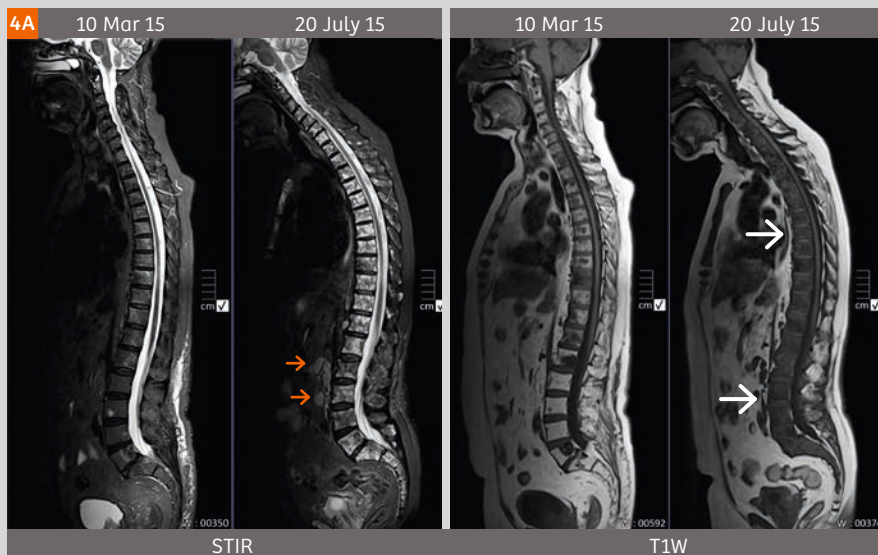
55-year-old male with metastatic castrate resistant prostate cancer (mCRPC). Previously failed treatments include docetaxel chemotherapy and abiraterone. Previously lumbar spinal radiotherapy. WB-MRI scans were obtained before and after Radium-223 treatment. Symptomatically the patient is worse with increasing bone pain and has become blood transfusion dependent; however PSA values are improved from 792 ng/mL to 167 ng/mL thus creating diagnostic confusion on the effectiveness of Radium-223 therapy.

**Figure 4A:** T1-weighted spine images show increased abnormal signal in the cervical, dorsal and lumbosacral spine suggestive of disease progression using the criteria in Figure 1B. However, the STIR sequence shows higher signal intensities in the cervical and dorsal spine indicating increased tissue water. Note increase in size of retro-peritoneal nodes (orange arrows).

**Figure 4B:** Responding disease in femora & dorsal spine, new disease in lumbar spine

Coronal b900 and ADC maps show decreased b900 signal intensities and increased ADC values in the dorsal spine and proximal femora (orange arrows) indicating responding disease (T1w-pseudo-progression in the dorsal spine). However, the opposite is seen in the lumbar spine where b900 signal intensity is increased (red arrows) and with low ADC values indicating new disease (true progression). Note some enlargement of the primary prostate tumor also (vertical red arrows).

**Figure 4C:** Paired b900 MIP images (inverted scale) showing new nodal disease in the left hemipelvis, retroperitoneum and in the left supraclavicular fossa (red arrows). On the other hand, the enlarged lymph nodes in the right common iliac region is improved (green arrow). There seems to be an increase in extent of bone marrow signal intensity. The high signal geographic lesion over the right thigh on the follow-up examination is a dipper pad (\*). Note lower signal intensity of the brain on follow-up examination due to the absence of the head coil.





**Figure 4D:** Completed MET-RADS-P template report indicating sites of disease and RACs at each anatomical location compared to the baseline study. Note how the RAC of response at the primary tumor is mostly stable with some progression (RAC 3/4). The RAC of the pelvic nodes is indicated as 5/2 meaning that there is progression in the majority of the nodes although a single lymph node has responded (see also Figure 4E). Overall the bone disease is scored as 2 (likely to be responding in the majority of regions) with major discordance due to progression in lumbo-sacral spine and pelvis (both with RAC scores of 5/5).

**4D** Physician *Po* Exam date *20/1/15* Exam time *15:31/15*

**MET-RADS Prostate Report**

**Soft tissues RECIST**

Primary Involved RAC *Y* *3/4*

Pelvic nodes Involved RAC *Y* *5/2*

Retroperitoneal Involved RAC *Y* *5/5*

Other nodes Involved RAC *Y* *5/5*

Liver Involved *N* *0/0*

Lungs Involved *N* *0/0*

Other sites Involved *N* *0/0*

**Bones MET-RADS**

Skull Involved RAC *N* *0/0*

Cervical spine Involved RAC *Y* *2/3*

Dorsal spine Involved RAC *Y* *2/3*

Lumbosacral spine Involved RAC *Y* *5/5*

Pelvis Involved RAC *Y* *5/5*

Thorax Involved RAC *Y* *3/5*

Limbs Involved RAC *Y* *5/2*

**OVERALL ASSESSMENT**

Primary: No dis, CR, PR, SD, PD, DISCORD

Nodes: No/minor/major, PD/SD, Category

Viscera: *✓*

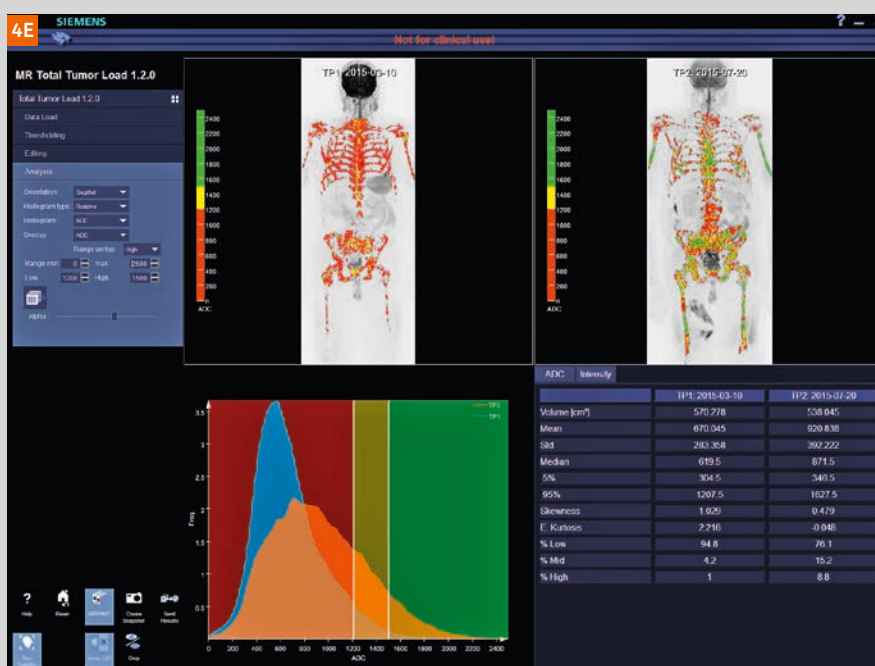Bones: *2*

Comments: *Progression in nodes. Response (stable/progressive) in dorsal spine but true progression in lumbar spine.*

Response assessment categories (RAC): 1 Highly likely to be responding; 2 Likely to be responding; 3 No change; 4 Likely to be progressing; 5 Highly likely to be progressing. Single lesion 1" RAC only; 22 lesions/diffuse disease use both RACs

**Figure 4E:** WB-tumor load segmentation undertaken on syngo.via Frontier MR Total Tumor Load software (Siemens Healthineers; released research prototype – not part of the MET-RADS-P standard) for illustrative purposes only.

The whole-body b900 images are segmented using computed high b-value images of 1000 s/mm<sup>2</sup> and signal intensity threshold of approximately 100 AU. Extraneous signals (such as the brain, kidneys, bowel, gonads) are removed to leave only recognizable disease sites. The color the b900 MIP images are overlaid with ADC value classes using the thresholds indicated. The green voxels are values  $\geq 1500 \mu\text{m}^2/\text{s}$  (representing voxels that are 'highly likely' to be responding). The yellow voxels are set to lie between the 95<sup>th</sup> centile ADC value of the pre-treatment histogram (1208  $\mu\text{m}^2/\text{s}$ ) and 1500  $\mu\text{m}^2/\text{s}$  thus representing voxels 'likely' to be responding. Red-voxels represent mostly untreated disease.



570 mL of bone marrow and nodal disease are segmented before therapy and 538 mL on therapy. Note that there is moderate global increase in ADC values (670  $\mu\text{m}^2/\text{s}$  and 920  $\mu\text{m}^2/\text{s}$ ) on the corresponding relative frequency histograms. There is a decrease in excess kurtosis of the histograms (2.2 and -0.05). Note decrease extent and volume of red-voxels consistent with disease response (95% before therapy and 76% after therapy). Heterogeneity of response in the spine (more red voxels in the lumbar spine and more green voxels in the dorsal spine) and in the pelvis is appreciable on these color projected images. This heterogeneity of response emphasizes the need to evaluate all the relevant WB-MRI images and to apply regional responses using the MET-RADS-P criteria.



Erlangen, Germany; released research prototype). Note that tumor load and ADC histogram analysis is not part of the MET-RADS-P standard, and is included for illustrative and cross-correlations purposes only. Detailed working of the *syngo.via* Frontier MR Total Tumor Load software is described in an accompanying article by Robert Grimm and Anwar R. Padhani in this issue of MAGNETOM Flash.

### Conclusions and future developments

The MET-RADS-P system provides the minimum standards for whole-body MR with DWI image acquisition, interpretation, and reporting of both baseline and follow-up monitoring examinations of men with advanced, metastatic prostate cancer. MET-RADS-P is suitable for guiding patient care in practice (using the regional and overall assessment criteria), but can also be incorporated into clinical trials when accurate lesion size and ADC measurements become more important (thus, recording of measurements is not mandated for clinical practice). MET-RADS-P enables the evaluation of the benefits of continuing therapy to be assessed, when there are signs that the disease is progressing (discordant responses).

MET-RADS-P requires validation within clinical trials initially in studies that assess the effects of known efficacious treatments, such as those targeting the androgen axis, cytotoxic chemotherapy, Radium-223 and PARP inhibitors. MET-RADS-P measures should be correlated to other tumor response biomarkers delineated by PCWG (such as PSA declines), quality of life measures, rates of skeletal events, radiographic progression free survival and overall survival. The latter will be needed for the introduction of WB-MRI into longer term follow-up studies that will allow objective

assessments of whether WB-MRI is effective in supporting patient care. Thus, we recommend that MET-RADS-P is now evaluated in clinical care and trials, to assess its impact on the clinical practice of advanced prostate cancer.

### References

- 1 Lecouvet FE. Whole-Body MR Imaging: Musculoskeletal Applications. *Radiology*. 2016;279:345–365.
- 2 Padhani AR, Lecouvet FE, Tunariu N, et al. Rationale for Modernising Imaging in Advanced Prostate Cancer. *Eur Urol Focus*. European Association of Urology; 2016;44:198–205.
- 3 Dimopoulos M a., Hillengass J, Usmani S, et al. Role of magnetic resonance imaging in the management of patients with multiple myeloma: a consensus statement. *J Clin Oncol*. 2015;33:657–664.
- 4 Padhani AR, Lecouvet FE, Tunariu N, et al. METastasis Reporting and Data System for Prostate Cancer : Practical Guidelines for Acquisition , Interpretation , and Reporting of Whole-body Magnetic Resonance Imaging-based Evaluations of Multiorgan Involvement in Advanced Prostate Cancer. *Eur Urol*. European Association of Urology; 2017;71:81–92.
- 5 Mottet N, Bellmunt J, Bolla M, et al. EAU-ESTRO-SIOG Guidelines on Prostate Cancer. Part 1: Screening, Diagnosis, and Local Treatment with Curative Intent. *Eur Urol*. 2016;1–12.
- 6 Cornford P, Bellmunt J, Bolla M, et al. EAU-ESTRO-SIOG Guidelines on Prostate Cancer. Part II: Treatment of Relapsing, Metastatic, and Castration-Resistant Prostate Cancer. *Eur Urol*. 2016;1–13.
- 7 Eisenhauer EA, Therasse P, Bogaerts J, et al. New response evaluation criteria in solid tumours: revised RECIST guideline (version 1.1). *Eur J Cancer*. 2008/12/23. 2009;45:228–247.
- 8 Scher HI, Morris MJ, Stadler WM, et al. Trial Design and Objectives for Castration-Resistant Prostate Cancer: Updated Recommendations From the Prostate Cancer Clinical Trials Working Group 3. *J Clin Oncol*. 2016;34:1402–1418.

#### Contact

Professor Anwar R. Padhani  
MB, BS, FRCP, FRCR  
Paul Strickland Scanner Centre  
Mount Vernon Hospital

Rickmansworth Road  
Northwood, Middlesex HA6 2RN  
United Kingdom  
anwar.padhani@stricklandscanner.org.uk



#### Contact

Nina Tunariu  
MD MRCP FRCR MDR  
Royal Marsden NHS Foundation Trust &  
Institute of Cancer Research  
Cancer Research UK Cancer Imaging Centre

Downs Road, Sutton, Surrey, SM2 5PT  
United Kingdom  
Nina.Tunariu@icr.ac.uk



Visit us at

**[www.siemens.com/magnetom-world](http://www.siemens.com/magnetom-world)**

to download the MET-RADS-P template form.

