

Performing Gynecologic Brachytherapy in the Medical Innovation Technical Expert Center

Cindy P. M. Frentz¹; Ruud van Leeuwen²; Angelo van Wagendorff van Ryn³; Jurgen J. Fütterer¹; Lia Verhoef²

¹ Department of Radiology and Nuclear Medicine, Radboud University Medical Center, Nijmegen, the Netherlands

² Department of Radiation Oncology, Radboud University Medical Center, Nijmegen, the Netherlands

³ Siemens Healthineers, Siemens Healthcare Nederland B.V., The Hague, the Netherlands

Keypoints

In this article we describe our procedure of positioning brachytherapy applicators and catheters in cervical carcinoma. The procedure is performed with the support of intra operative MRI in the Medical Innovation Technical expert Center (MITeC) of the Radboud University Medical Center, Nijmegen.

Introduction

The Medical Innovation Technical expert Center (MITeC) of the Radboud University Medical Center is a multi-operation room setting utilized for minimal invasive surgical procedures supported by MRI, CT, or X-ray intervention technologies. In 2015 a wide-bore 3T MAGNETOM Skyra Combi Suite MRI scanner (Siemens Healthcare, Erlangen, Germany) was installed for MRI-guided procedures.

MR-guided adaptive brachytherapy (MRGABT) is a local radiotherapy treatment, employing after-loading techniques, that treats tumors by positioning a radioactive source, through hollow catheters placed in or near the tumor. The radioactive source is programmed to stay at pre-specified positions in the applicator and catheters, during a varying time. In this way it is possible to give a high dose to tumor tissue while minimizing the radiation dose to the vital organs in the environment of the tumor.

For Radiation Oncology, one of the great opportunities of the combination of MRI in an operating room is the possibility to perform an MRI scan directly after positioning brachytherapy catheters into a tumor in order to reposition or return to the OR if additional intervention is necessary. MRGABT can be performed based on the MR images, as soft tissue contrast allows to customize treatment plans to accurately deliver therapeutic doses to tumor tissue, while minimizing dose to the normal structures in the vicinity of the tumor, potentially resulting in fewer treatment related complications.

In our hospital, cervical carcinoma patients routinely undergo MRGABT in the MITeC since October 2015. In this article we will describe the application procedure in a patient with cervical carcinoma and the way to perform MRI-scanning in an OR setting.

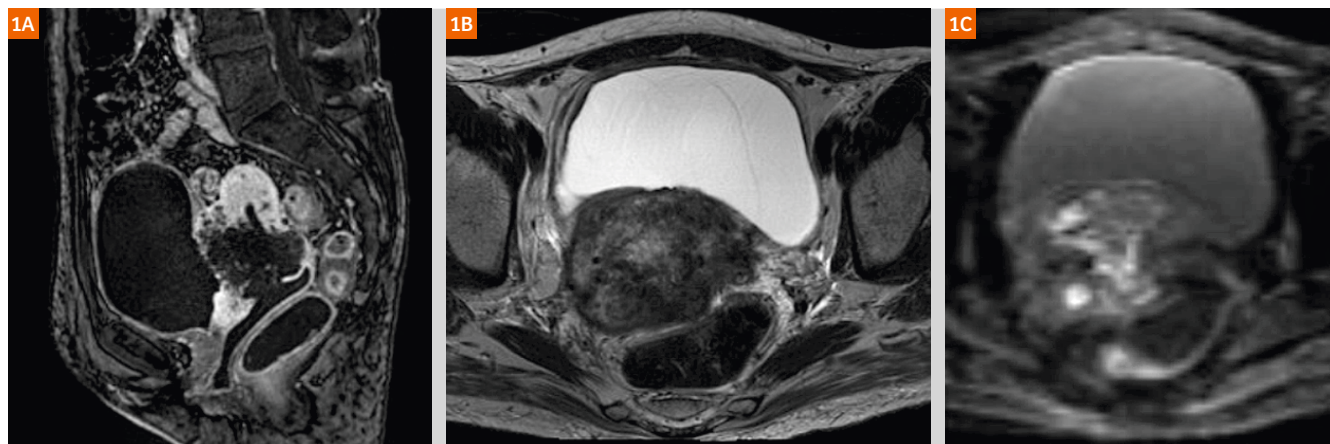

Figure 1: Diagnostic sagittal T1-weighted VIBE post Gd-contrast (1A) of a cervix carcinoma in situ. Transversal T2-weighted image (1B) showing a large tumor with extensive diffusion restriction on transversal TraceW diffusion-weighted image (1C).

Procedure

For patients with locally advanced cervical carcinoma, external beam radiotherapy combined with weekly cisplatin, followed by high dose brachytherapy is the treatment of choice [6–8].

A case in clinical routine: a 50-year-old woman with a large squamous cell carcinoma of the cervix uteri. The diagnostic abdominal MRI shows a tumor of 8.8 x 10 x 11 cm that penetrates through the bladder, the urethra, the cervix, the apical vagina, and the myo- and endometrium uteri and is also fixed to the sigmoid (Fig. 1). This unresectable tumor was treated by chemo- and radiotherapy: after 25 fractions of large-field external beam radiotherapy, combined with weekly cisplatin, the remaining tumor was treated with brachytherapy. By doing it this way the tumor could be treated with a much higher dose than would have been possible with external beam radiotherapy only. The healthy tissue in the area of the tumor received a much lower dose than it would with external beam radiotherapy, as the radiation source is positioned inside the tumor.

For this treatment an applicator with guided catheters (Elekta Utrecht Interstitial Applicator Set) was used. The applicator system consists of an intra-uterine catheter and two ovoid shaped devices that allowed the placing of additional needles in the tumor (Fig. 2A) [2]. A template made in-house was used to position and adjust the needles (Fig. 2B).

As tumor sizes vary in patients the addition of a template allows the placing of extra needles outside the range of the applicator and their catheters.

The insertion of the applicator, template, and catheters was done in the OR of the MITeC under general anesthesia. The catheters were positioned in the tumor using the applicator, its ovoids, and template to guide the needles. The needles could be individually repositioned and locked for treatment. After positioning and fixing the device an MRI took place next to the OR where the catheters were placed. The patient remained under general anesthesia during the transport to the MRI-room and during the scan. Transport of the patient was easily performed using the Combi Dockable MRI table [3].

The Combi Dockable MRI table is a trolley that can be undocked from the scanner in order to transport the patient. The trolley contains a rail and a sliding table top. Connecting the MRI table to the OR table enables you to slide the table top safely on to the OR table (Fig. 3A). The table top of this MRI table will stay under the patient throughout the procedure.

The table top will be on the OR table and can easily slide on the MRI table whilst the patient remains on the table top. The rails of the table top prevent the use of a conventional spine coil. As an alternative, to receive signal from the posterior side, a 4-channel Siemens flex large coil is positioned among the rails on the MRI table before shifting the table top on it. The coils are placed along the length of

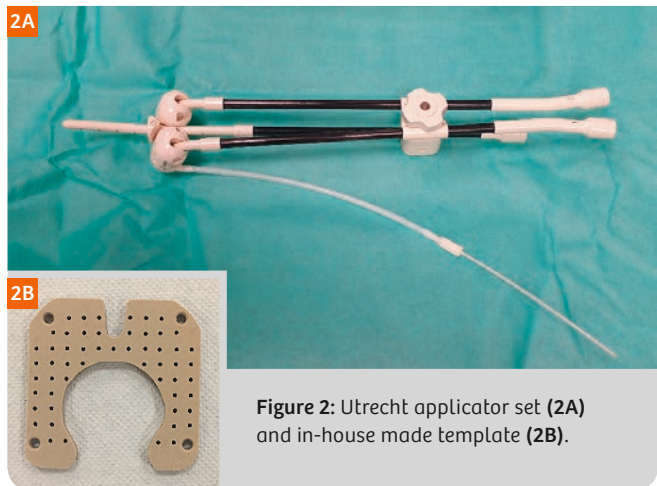


Figure 2: Utrecht applicator set (2A) and in-house made template (2B).

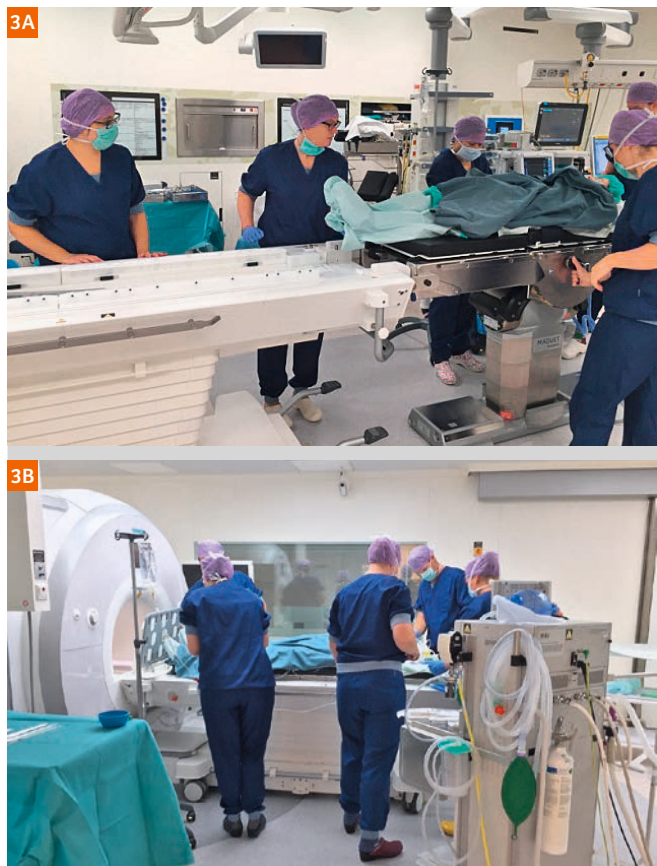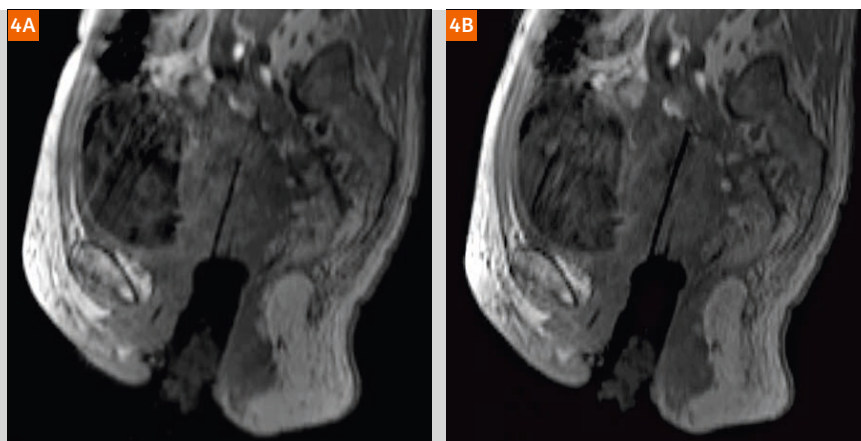


Figure 3: Patient transport from operation room (3A) to MRI room (3B) on the table top of the Combi Dockable MRI table.

the patient to facilitate full field-of-view MRI of the anatomy and catheters.

We used markers on the MRI-compatible trolley to mark the position of the 4-channel flex coil so that we could easily position the pelvic region on top of the coil. After an MRI safety check, the team transported the patient through the MRI entrance and the table was docked to the MRI-scanner.

Figure 4: Example of repositioning of a catheter. **(4A)** Sagittal reconstruction of 3D T1 VIBE: one of the catheters in situ. **(4B)** Catheter placed 15 mm deeper in the tumor.



MRI-scans were made when the patient was still under general anesthesia using MRI compatible respiratory equipment and MRI-compatible monitoring equipment to monitor patient condition during scanning. The patient was positioned in feet first position to allow a good level of respiratory control. Over the abdomen an 18-channel body coil was placed for good signal of the lower abdomen.

The scanning protocol contains a transversal 3D T1-weighted VIBE sequence (TE 2.46 ms, TR 4.57 ms, voxel size 1.2 x 1.2 x 2.0 mm, acquisition time 2:08 min) to visualize the location and depth of applicator and catheters in the cervix and tumor. On both sides of the tunnel there is enough space for adapting the catheters in a sterile way.

After repositioning the catheters the 3D T1 VIBE was repeated in order to check the location and depth (Fig. 4). After obtaining the correct position high-resolution T2 TSE sequences (TE 90 ms, TR 5020, voxel size 0.6 x 0.6 x 3.0 mm, acq. time 5:13 min) were performed in 3 directions aligned to the tip of the applicator to obtain good image contrast between normal tissue and tumor. The T2 sequences were used for contouring of the tumor and organs, and for planning of the brachytherapy dose. Normally, water filled tubes (Elekta MR line marker set) can be placed inside the applicator to have a better visualization of the applicator on the T2w images [2].

Safety issues

Because of the strong magnetic field and the radiofrequency pulses in the MRI room it is important to double-check patient and personnel for ferromagnetic and conductive materials. The patient was screened for contra-indications on the day of the intake, and again at the arrival at the OR. Before entering the MRI room there was a safety check moment planned, where personnel were checked and ferromagnetic material was removed. The applicator is MRI safe. The needles used for the positioning and replacing of the catheters are safe to use in the MRI room, but not safe to leave inside the catheters during scanning. Therefore the needles were taken out of the catheters before entering the MRI room. The template is MRI safe.

The door between the OR and the MRI room was locked. After the safety check the MRI technician unlocked the door and the patient could be transported to the MRI room. The door was automatically locked after a few minutes. To minimize risks, a minimal number of personnel were in the MR room: the anesthesiologist, the assistant anesthesiologist, and the MRI technician. All other personnel remained in the adjacent operation room or in the MRI control room.

Treatment

After the optimal placement of the applicator and catheters and the final MRI, the patient was transported back to the OR on the undocked MRI table. There she was brought to conscious, administered pain medication and transported to the recovery room. Meanwhile, dose planning was performed in the radiation oncology department. An accurate definition of the source positions relative to the anatomy is critical. Thus, evaluation of patient movements, artifacts of the applicator, and distortion should be taken into account. The bladder and bowel are organs in the direct area of the tumor. It is important for quality of life and tumor induction to spare these organs from as much radiation as possible. The optimal location of the radioactive source inside the catheters and applicator and the time they should stay inside were determined using Oncentra Brachy software (Elekta, Veenendaal, the Netherlands) [2].

After finalizing the optimal treatment planning the patient was transported to the treatment room in the department of radiation oncology, where the catheters and applicator were connected to the treatment device (Flexitron, Elekta, Veenendaal, the Netherlands) and radiation was performed [2]. After the radiation the applicator and catheters were taken out.

For effective treatment with high tumor dose and good recovery of healthy tissue the procedure of brachytherapy was carried out a total of four times during two consecutive weeks. Each time (fraction) the applicator and catheters were placed MRI-guided in the optimal way in relation to the tumor. In between the brachytherapy treatments two or three days were planned for recovery of healthy tissue [4, 5].

Figure 5: Dose plans of two sequential fractions in the same patient. The red line denotes 100% of the prescribed dose, the green line 50% of the prescribed dose, the red dotted line denotes the tumor. In an ideal situation the red line should exactly follow the red dotted line. **(5A)** Utrecht applicator plus template, 15 needles, target dose 7.4 Gray. MRI after check position and MRI guided reposition. **(5B)** Utrecht applicator and template, 5 needles; 2 free. Target dose 7.8 Gray. MRI after check position and repositioning using MRI.

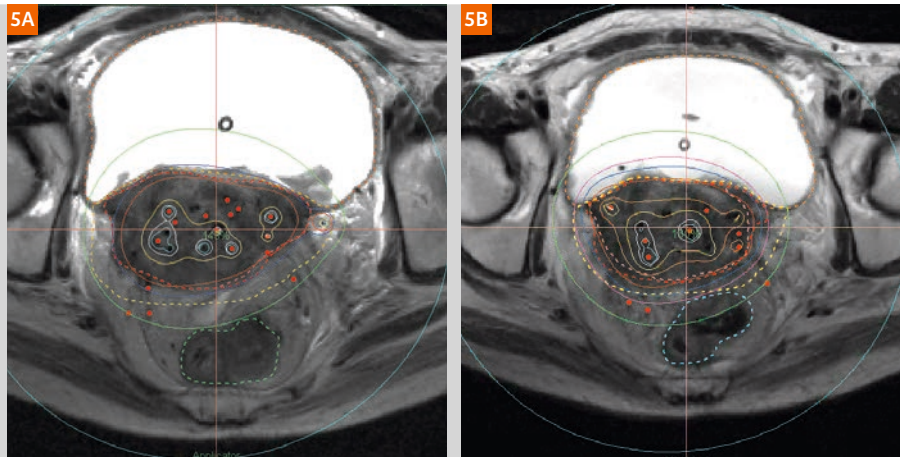
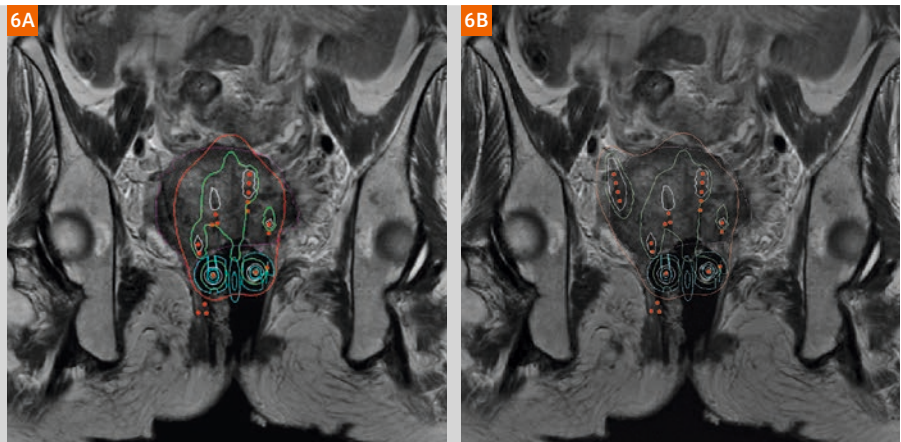


Figure 6: Dose plans on coronal T2w image in Oncentra brachy treatment planning software. Pink dotted line: tumor. Red line: 100% dose, green line: 200% dose, white line: 300% dose. Insufficient radiation dose in the outer part of the tumor (6A). Good coverage of 100% radiation dose thanks to a catheter placed free-hand in the outer part of the tumor when conventional device is not applicable for large tumors (6B).



In Figure 5 the planned dose distribution of two fractions is shown, showing high dose inside the tumor and lower dose in the surrounding organs. Panel 5A shows insufficient coverage of the tumor, especially in the ventral and right side of the tumor; panel 5B shows markedly improved coverage after MRI-guided needle adjustment.

Future perspective

In the future real-time MRI during needle shifting would be an effective way of repositioning the catheters using MRI-safe needles. Real-time imaging also allows free-hand positioning or repositioning of needles, especially in large tumors where the applicator and guided catheters are not close enough to certain parts of the tumor, resulting in under dosage. In Figure 6A you find a part of the tumor (pink dotted line) outside the 100% radiation dose (red line). In this case this part of the tumor is out of reach of the applicator. A catheter was therefore positioned free-hand in this area (Fig. 6B). This extra catheter enables you to treat this part of the tumor as it should have been. To minimize risks such as perforation, MRI-guided positioning would be a great improvement of optimal positioning of free-hand placed needles. Good visualization of an MRI safe needle needs to be available, but is not yet a clinical possibility in our hospital.

The MRI-guided procedure we described might also be applied for brachytherapy treatment in other cancer types, e.g. vagina, prostate or rectal tumors.

Conclusion and discussion

In order to prepare a patient for brachytherapy on cervix carcinoma it is good to have the availability of an MRI facility in the OR. This may offer the opportunity to effectively position and reposition applicator and catheters in a sterile way using MRI when the patient is in controlled general anesthesia. An additional advantage of the anesthesia is the reduction of motion artifacts caused by patient movement. The sliding table top of the Combi Dockable MRI table ensures easy patient transportation. Safety issues should be taken into account because of the high field strength, gradient field and radiofrequency pulses.

The option of real-time scanning during needle shifting would be an effective way of repositioning the catheters using MRI compatible needles. The treatment depends on size and position of the tumor. Different MRI compatible devices can be used. Real-time MRI can give you the ability to place or reposition needles free-hand in the tumor. This is not yet used in these procedures.

References

- 1 Joan I. Priscaandaro, James M. Balter, et al, MR-guided Gyneacological High Dose Rate (HDR) Brachytherapy, MAGNETOM Flash (S9)4/2014: 32-37.
- 2 <https://www.elekta.com/dam/jcr:bac0f2d8-1b55-43ee-bb96-2073cbf9f2eb/brachytherapy-applicator-guide.pdf#page=26>
- 3 <https://www.healthcare.siemens.nl/magnetic-resonance-imaging/mri-guided-therapy/cardiovascular-interventions/features>
- 4 www.embracestudy.dk
- 5 <https://www.embracestudy.dk/UserUpload/PublicDocuments/EmbraceProtocol.pdf>
- 6 Pötter, Richard et al.: Clinical outcome of protocol based image (MRI) guided adaptive brachytherapy combined with 3D conformal radiotherapy with or without chemotherapy in patients with locally advanced cervical cancer Radiotherapy and Oncology , Volume 100, Issue 1 , 116 – 123.
- 7 Dimopoulos J.C., Schard G., Berger D. Systematic evaluation of MRI findings in different stages of treatment of cervical cancer: potential of MRI on delineation of target, pathoanatomic structures, and organs at risk. Int J Radiat Oncol Biol Phys. 2006;64:1380–1388.
- 8 Viswanathan A.N., Dimopoulos J., Kirisits C., Berger D., Pötter R. Computed tomography versus magnetic resonance imaging-based contouring in cervical cancer brachytherapy: results of a prospective trial and preliminary guidelines for standardized contours. Int J Radiat Oncol Biol Phys. 2007;68:491–498.

Contact

Dr. C. G. Verhoef, Radiation oncologist
Department of Radiation oncology
Radboud University Medical Center

Geert Grooteplein zuid 32
6525GA Nijmegen
The Netherlands
Phone: +31(0)2436 86457
Lia.Verhoef@radboudumc.nl



Lia Verhoef



Cindy Frentz

MR-integrated workflows in Radiation Therapy for MAGNETOM Systems

We have compiled a series of study protocols and practical tips and tricks for several body sites from experts for both experts and novice users, so that everyone can benefit from each-other.

Download the booklet with tips & tricks and the .edx and .exar1 files at

www.siemens.com/magnetom-world-rt

Not for distribution in the US


Yue Qiao, Ph.D.
University of Michigan, Ann Arbor, USA

Eric Paulson, Ph.D.
Medical College of Wisconsin, Milwaukee, USA

Maja Sahlin, Ph.D.
Sahlgrenska University Hospital, Gothenburg, Sweden

Rohita Rai, MPhilSc and Gary Linzy, Ph.D.
Liverpool and Macarthur Cancer Therapy Centre, Ingham Institute for Applied Medical Research, Sydney, Australia

Cynthia Ménard, M.D., FRCPC and David Roberge, M.D., FRCPC
Centre hospitalier de l'Université de Montréal, Canada



MR-integrated Workflows in Radiation Therapy

for MAGNETOM Systems

siemens.com/magnetom-world-rt

SIEMENS
Healthineers