

Spectroscopic MRI for dose-escalated radiation therapy

Saumya S. Gurbani, MS^{1,2}; Eric Mellon, M.D., Ph.D.³; Brent Weinberg, M.D., Ph.D.⁴; Eduard Schreibmann, Ph.D.¹; Andrew A. Maudsley, Ph.D.⁵; Lee A. D. Cooper, Ph.D.^{2,6}; Hui-Kuo G. Shu, M.D., Ph.D.¹; Hyunsuk Shim, Ph.D.^{1,2,4}

¹ Department of Radiation Oncology, Winship Cancer Institute of Emory University, Atlanta, GA, USA

² Department of Biomedical Engineering, Emory University and Georgia Institute of Technology, Atlanta, GA, USA

³ Department of Radiation Oncology, University of Miami Miller School of Medicine, Miami, FL, USA

⁴ Department of Radiology and Imaging Sciences, Emory University School of Medicine, Atlanta, GA, USA

⁵ Department of Radiology, University of Miami Miller School of Medicine, Miami, FL, USA

⁶ Department of Biomedical Informatics, Emory University School of Medicine, Atlanta, GA, USA

Glioblastoma is the most common primary adult brain tumor in the US, with over 10,000 cases diagnosed each year [1]. The current standard of care for these patients is the removal of as much tumor as possible via neurosurgery followed by radiation therapy (RT) and concurrent chemotherapy (typically with temozolomide) [2–5]. Two radiation doses are commonly used. High dose radiation (60 Gy) is targeted to the post-surgical cavity and residual disease defined by areas of enhancement on T1-weighted gadolinium contrast-enhanced (CE-T1w) MRI, which represents highly aggressive tumor which has broken through the blood-brain barrier. A lower dose of radiation (51–54 Gy) is targeted towards areas of hyperintensity on T2-weighted fluid-attenuation inversion recovery (FLAIR) MRI [6], which corresponds to a combination of tumor and non-tumor pathologies, including inflammation and

edema [7]. The enhancing regions on CE-T1w are also the target for surgical resection, and with advancements in neurosurgical methods, there is often little enhancement left; thus, much of the high dose radiation ends up treating the empty cavity.

Despite aggressive treatment, glioblastomas continue to progress and recur – sometimes inside the initial 60 Gy isodose cloud but often times outside it – within months of treatment, and median survival remains poor at 15 months [8, 9]. Two conclusions can be drawn from this poor prognosis. First, radiation doses higher than 60Gy may be needed for long-term control of disease. Second, we are unable to fully identify all at high risk for tumor recurrence at the time of treatment. Currently, the NRG Oncology cooperative group is evaluating the

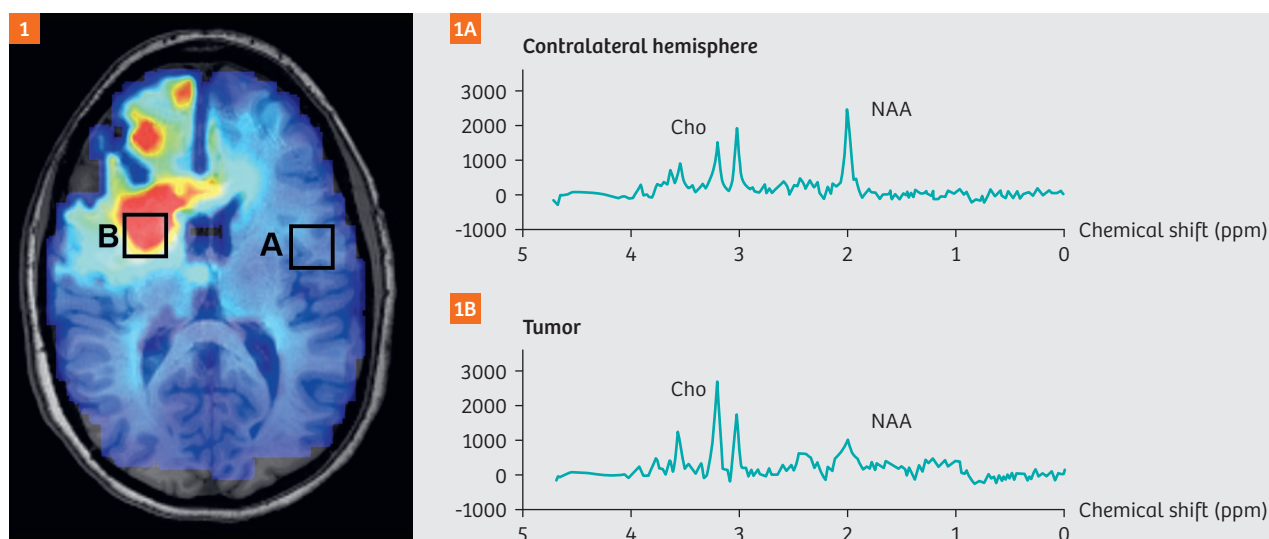


Figure 1: sMRI identifies metabolic changes in glioblastoma in vivo.

Spectroscopic MRI (sMRI) is a quantitative modality that measures whole-brain endogenous metabolism in vivo. In patients with glioblastoma, the ratio of choline to N-acetylaspartate (Cho/NAA) differentiates healthy tissue (**1A**) from tumor (**1B**) due to a simultaneous increase in choline and a decrease in N-acetylaspartate.

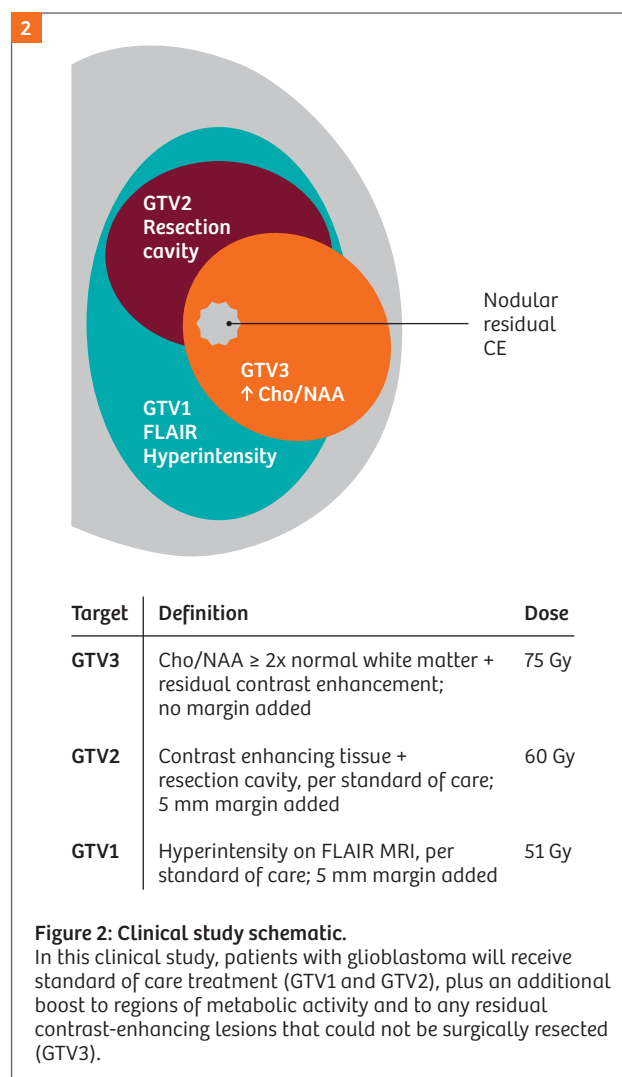
risks and benefits of dose escalating radiation to 75 Gy in conjunction with standard concurrent and adjuvant temozolomide [10], but using conventional targeting with much of the boosted dose going to the resection cavity. Therefore, even if successfully locally, there are concerns that conventionally targeted doses will fail to control regions at high risk for recurrence elsewhere in the brain – after all, we can't treat what we can't identify. Thus, better approaches are needed for targeting both enhancing and non-enhancing tumor to maximize the benefits of high dose radiation.

Proton spectroscopic magnetic resonance imaging (sMRI) is an advanced imaging modality that enables in vivo acquisition of 3D whole-brain volumes of metabolic activity [11, 12] (Fig. 1). Two metabolites are of particular interest in patients with glioblastoma. Choline-containing compounds (Cho), the building blocks of the cell membrane, increase in proliferating tumor cells; N-acetylaspartate (NAA), a biomarker found in healthy neurons, diminishes due to neuronal displacement and death due to glial infiltration [11, 13]. It has been previously shown via histological correlation that the ratio of Cho to NAA is significantly elevated in glioblastoma due to the opposing changes in these metabolites. In particular, a two-fold increase in Cho/NAA compared to normal-appearing tissue in contralateral white matter was able to correctly identify tumor in 100% of cases, even when tissue samples were biopsied from regions outside of contrast-enhancement per CE-T1w or even FLAIR hyperintensity [14]. This indicates that conventional MRI targeting does not identify all of the areas of tumor at high risk of recurrence. Further, a simulation study of patients with newly-diagnosed glioblastoma identified that two-fold elevated Cho/NAA in addition to CE-T1w identified future sites of disease recurrence in nine out of eleven patients [15].

However, using sMRI data in clinical care requires specialized software, a local MR spectroscopist with years of expertise, and many hours of manual imaging processing. This has been a barrier to the clinical validation and implementation of sMRI. To address this need, we have developed a software package which seeks to automate these tasks and facilitate the use of sMRI to target RT in a multisite clinical study. The Brain Imaging Collaboration Suite (BrICS) is a web-based software designed specifically to integrate sMRI with clinical imaging, enabling physicians to evaluate metabolic activity, review underlying spectra on a voxel-basis, and delineate target volumes for RT planning [16]. BrICS consists of two components: a central server which performs computationally intensive image processing, and a lightweight browser client that can run on any modern computer or tablet. Users can also co-register sMRI volumes with other clinical imaging

via a DICOM importer, and edit contours manually similar to standard software, with the advantage that all data are stored centrally and readily shared to other users. A demo is available for public use at our group's website at <https://brainimaging.emory.edu>.

To assess the feasibility of sMRI-guided radiation therapy across institutions in a group setting, a multisite clinical study has begun at Emory University, the Johns Hopkins University, and the University of Miami, with the goal of enrolling a total of 30 patients with glioblastoma. In this trial, patients will first undergo surgical resection of their tumor. Next, prior to RT, patients will receive a sMRI scan on a Siemens 3T scanner (either a MAGNETOM Prisma with a 32-channel head coil, or a MAGNETOM Skyra with a 20-channel head coil) using a 15 minute echo planar spectroscopic imaging (EPSI) pulse sequence. Shimming is performed using the built-in auto shim capability of the Siemens scanners. Raw EPSI data is transformed into



a 3D spatial volume and metabolite concentrations are calculated via spectral fitting using the MIDAS software suite, developed by Dr. Maudsley's team at the University of Miami [17, 18].

Patients in this multisite study will also receive standard-of-care imaging in the clinic, including CE-T1w and FLAIR MRI; these volumes are then imported into BrICS where all volumes are co-registered into the same image space. Contours including areas of brain with a two-fold increase in Cho/NAA and residual contrast enhancement are generated as target volumes. MR spectroscopists from at least two institutions review the underlying spectra within the contours to ensure data are of good enough quality to use. A neuroradiologist then reviews and edits the contours to ensure accuracy. Finally, the Cho/NAA and contrast-enhancing contours are merged to form a single target volume, and two radiation oncologists make final edits based on anatomy and dose safety concerns (i.e. removing voxels near organs-at-risk), and validate the volume. The final contour is exported from BrICS into the radiation therapy planning system by a board-certified medical physicist at the treating institution, and is targeted for an escalated dose of 75 Gy. The remainder of the brain is

treated per the standard of care – 60 Gy to the surgical cavity and 51 Gy to areas of FLAIR hyperintensity (Fig. 2). All doses are delivered over 30 fractions (five days per week x six weeks, same as standard of care). We present in Figure 3 the contours from our first patient, who underwent our dose escalated protocol in late 2017. As can be seen, there was only a small, nodular residual contrast-enhancing island on the surgical cavity, but the Cho/NAA abnormality expanded much further out, including regions that crossed the midline of the brain, which is not apparent even in the FLAIR volume.

In addition to RT planning, sMRI can also be used to monitor the metabolic response to treatment. Traditional monitoring modalities, such as FLAIR and DWI, are sensitive to physiologic changes arising from radiation and chemotherapy, e.g. hyperintensity in FLAIR due to an inflammatory response to treatment. sMRI, however, is robust to these other physiologic changes and remains specific in the detection of proliferative disease. For this reason, we acquire a second sMRI two weeks into RT to evaluate whether sMRI could be an early marker of treatment response enabling adaptations of RT during the therapy course.

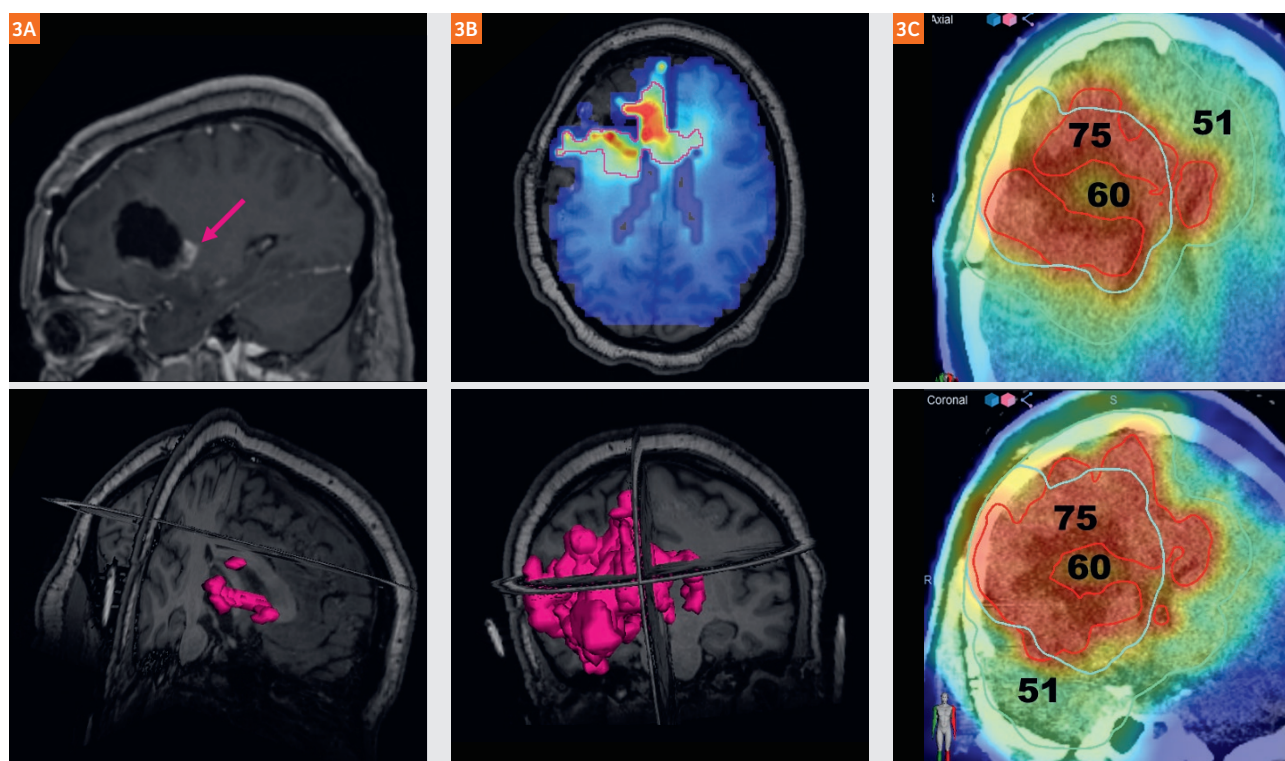


Figure 3: Sample patient.

The first patient enrolled in this trial was a young, 21-year-old female, who underwent surgical removal of her glioblastoma. **(3A)** While only a small nodule of contrast-enhancing tumor remains, **(3B)** sMRI identifies a much larger region of metabolically active tumor which should be targeted for high dose radiation. **(3C)** The escalated dose RT plan was successfully carried out on a standard linear accelerator setup.

In this project, we are able to bring together the multi-institutional team via a web app to collectively manage a patient's RT plan. This is normally very difficult to do (just try getting multiple physicians in the same room on a busy clinic day, let alone from different cities!), but with the BrICS infrastructure, we are able to accomplish the entire pipeline, from scanner to final treatment plan, in less than two days per patient. Furthermore, the addition of the EPSI sequence is only 15 minutes, and data processing is as fast as other modalities such as PET; the majority of the two days comes from treatment planning. In the past, sMRI has been shown to be a useful modality in identifying metabolically active tumor, but has thus far been difficult to incorporate into clinical practice due to the complexity of integrating its information with clinical volumes and the necessity of having spectroscopy experts available locally. BrICS solves these issues, enabling clinicians from multiple institutions to use sMRI for treating patients. Through our initial ongoing clinical study, we seek to validate the feasibility of sMRI guidance for radiation therapy, and to pave the way for a future consortium-level trial to ultimately assess the benefits of targeting high-risk, metabolically active tumor.


In conclusion, we seek to develop sMRI technology to improve radiation therapy guidance in patients with glioblastoma. Our hope is that by making whole brain sMRI more accessible for clinical decision-making and treatment decisions through an easy-to-use, collaborative web application, we can improve patient outcomes and drive future of state-of-the-art glioblastoma care.

References

- Ostrom QT, Gittleman H, Liao P, Rouse C, Chen Y, Dowling J, et al. CBTRUS Statistical Report: Primary Brain and Central Nervous System Tumors Diagnosed in the United States in 2007–2011. *Neuro Oncol*. 2014;16(suppl_4):iv1-iv63. doi: 10.1093/neuonc/nou223.
- Wen PY, Macdonald DR, Reardon DA. Updated response assessment criteria for high-grade gliomas: response assessment in neuro-oncology working group. *Journal of Clinical Oncology*. 2010. doi: 10.1200/JCO.2009.26.3541.
- Stupp R, Hegi ME, Gilbert MR. Chemoradiotherapy in malignant glioma: standard of care and future directions. *Journal of Clinical Oncology*. 2007. doi: 10.1200/JCO.2007.11.8554.
- Stupp R, Hegi ME, Mason WP, van den Bent MJ. Effects of radiotherapy with concomitant and adjuvant temozolomide versus radiotherapy alone on survival in glioblastoma in a randomised phase III study: 5-year *The Lancet oncology*. 2009.
- Stupp R, Mason WP, Bent VMJ. Radiotherapy plus concomitant and adjuvant temozolomide for glioblastoma. *England Journal of* 2005. doi: 10.1056/NEJMoa043330.
- Wernicke AG, Smith AW, Taube S, Mehta MP. Glioblastoma: Radiation treatment margins, how small is large enough? *Practical radiation oncology*. 2016;6(5):298-305.
- Tsuchiya K, Mizutani Y. Preliminary evaluation of fluid-attenuated inversion-recovery MR in the diagnosis of intracranial tumors. *American Journal of* 1996.
- Stupp R, Hegi ME, Gilbert MR, Chakravarti A. Chemoradiotherapy in malignant glioma: standard of care and future directions. *J Clin Oncol*. 2007;25(26):4127-36. doi: 10.1200/JCO.2007.11.8554.
- Stupp R, Hegi ME, Mason WP, van den Bent MJ, Taphoorn MJB, Janzer RC, et al. Effects of radiotherapy with concomitant and adjuvant temozolomide versus radiotherapy alone on survival in glioblastoma in a randomised phase III study: 5-year analysis of the EORTC-NCIC trial. *Lancet Oncol*. 2009;10(5):459-66. doi: 10.1016/S1470-2045(09)70025-7.
- RTOG. Randomized Phase II Trial of Hypofractionated Dose-Escalated Photon IMRT or Proton Beam Therapy Versus Conventional Photon Irradiation With Concomitant and Adjuvant Temozolomide in Patients With Newly Diagnosed Glioblastoma. *Radiat Ther Oncol Gr NRG-BN001 Protoc Inf*. 2014.
- Law M. MR spectroscopy of brain tumors. *Topics in Magnetic Resonance Imaging*. 2004;15(5):291-313. doi: 10.1097/00002142-200410000-00003.
- Maudsley AA, Domenig C, Sheriff S. Reproducibility of serial whole brain MR Spectroscopic Imaging. *NMR in Biomedicine*. 2010. doi: 10.1002/nbm.1445.
- Law M, Cha S, Knopp EA, Johnson G, Arnett J, Litt AW. High-grade gliomas and solitary metastases: differentiation by using perfusion and proton spectroscopic MR imaging. *Radiology*. 2002;222(3):715-21. doi: 10.1148/radiol.2223010558.
- Cordova JS, Shu H-KG, Liang Z, Gurbani SS, Cooper LAD, Holder CA, et al. Whole-brain spectroscopic MRI biomarkers identify infiltrating margins in glioblastoma patients. *Neuro Oncol*. 2016;18(8):1180-9. doi: 10.1093/neuonc/now036.
- Cordova JS, Kandula S, Gurbani S, Zhong J, Tejani M, Kayode O, et al. Simulating the Effect of Spectroscopic MRI as a Metric for Radiation Therapy Planning in Patients with Glioblastoma. *Tomography : a journal for imaging research*. 2016;2(4):366-73. doi: 10.18383/j.tom.2016.00187. PubMed PMID: PMC5241103.
- Gurbani SS, Schreibmann E, Sheriff S, Cooper LAD, Shu HKG, Holder CA, et al. A Software Platform for Collaborative Radiation Therapy Planning Using Spectroscopic MRI. *International Journal of Radiation Oncology • Biology • Physics*. 2017;99(2):E667. doi: 10.1016/j.ijrobp.2017.06.2209.
- Maudsley AA, Domenig C, Govind V, Darkazanli A, Studholme C, Arheart K, et al. Mapping of brain metabolite distributions by volumetric proton MR spectroscopic imaging (MRSI). *Magn Reson Med*. 2009;61(3):548-59. doi: 10.1002/mrm.21875.
- Sabati M, Sheriff S, Gu M, Wei J, Zhu H, Barker PB, et al. Multivendor implementation and comparison of volumetric whole-brain echo-planar MR spectroscopic imaging. *Magn Reson Med*. 2015;74(5):1209-20. doi: 10.1002/mrm.25510.

Contact

Hyunsuk Shim, Ph.D.
Department of Radiation Oncology
Winship Cancer Institute of Emory University
1701 Uppergate Drive
Atlanta, GA 30322, USA
hshim@emory.edu



From the left: Hui-Kuo Shu, MD, PhD (Radiation Oncologist); Saumya Gurbani, MS (MD/PhD student); Hyunsuk Shim, PhD; Brent Weinberg, MD, PhD (Neuroradiologist); Eduard Schreibmann, PhD (Medical Physicist).