

Heartbeat

The Magazine for Efficiency in Cardiovascular Care

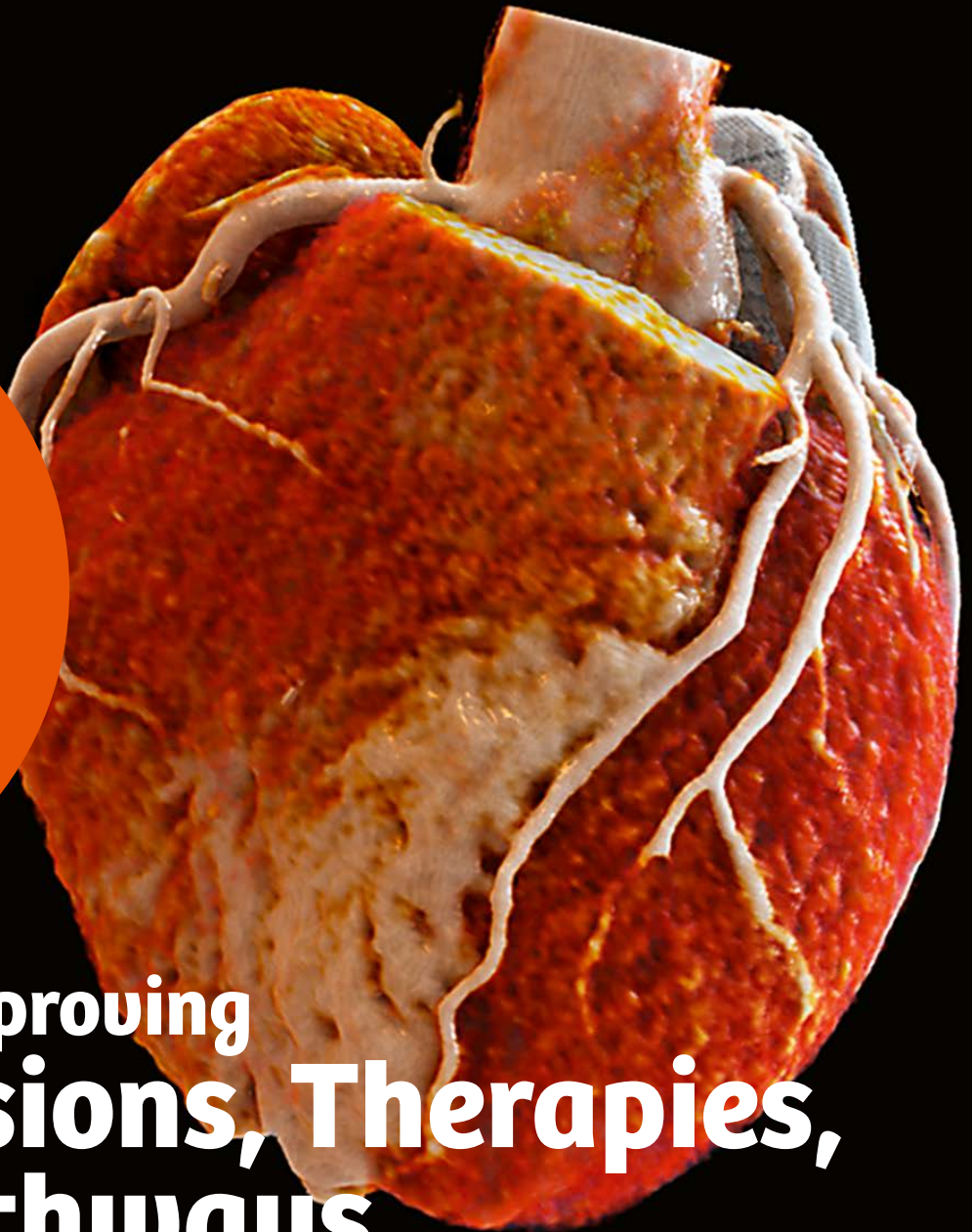
10 • Structural Heart Disease
Valvular Heart Disease Treatment
in Challenging Patients

.....

16 • Coronary Artery Disease
Leveraging Patient Data Analytics

.....

24 • Coronary Artery Disease
Effective Exclusion of Myocardial
Ischemia with Cardiovascular MRI



Improving
Decisions, Therapies,
and Pathways
to Enable Better Outcomes

Heartbeat

© Siemens Healthcare GmbH, 2018

Local Contact Information:

Siemens Healthcare GmbH
Advanced Therapies
Siemensstr. 1
91301 Forchheim
Germany

Responsible for Content:

Philipp Fischer, MD,
General Manager for Global Cardiovascular Care

Chief Editor:

Kathrin Schindler,
kathrin.schindler@siemens-healthineers.com

Project Management:

Nadine Meru, PhD,
nadine.meru@siemens-healthineers.com

Copy Editing:

Sheila Regan, Jen Metcalf
UNIWORKS, www.uni-works.org

Editorial Team:

Gaia Banks, Andrea Beulcke, Doris Pommi,
Petra Schlichtner, Petra Veit

Includes text & photographic contributions from

Primafila AG, CH-Zurich /
independent Medien-Design, D-Munich

Layout:

Claudia Oehm, Stefanie Schubert,
Agentur Baumgärtner, Fürth, Germany

Production and Prepress:

Clemens Ulrich,
Siemens Healthcare GmbH

Printer:

G. Peschke, Druckerei GmbH, Taxetstraße 4,
85599 Parsdorf b. München, Germany

Olaf Göing, MD,
Cardiology Center, Sana Klinikum Lichtenberg,
Berlin, Germany

Nikos Werner, MD,
Heart Center,
University Hospital Bonn, Germany

Holger Nef, MD,
University Hospital of Giessen and Marburg,
Germany

Stephanie Funk, MD, Edyta Blaszczyk, MD,
Agnieszka Toepper, MD, Jeanette Schulz-Menger, MD,
Charité Medical Faculty, Max Delbrück Center for
Molecular Medicine, HELIOS Clinic Berlin-Buch,
Berlin, Germany

Fabiola B. Sozzi, MD, Ospedale Policlinico IRCCS Cà
Granda, Milan, Italy; Nicolas Hugues, MD,
Laura Iacuzio, MD, and Francois Bourlon, MD,
Monaco Cardiothoracic Centre, Monaco

Drug and Material Disclaimer:

The mention of trade names, commercial products organizations, and the inclusion of advertisements in the journal does not imply endorsement by the European Heart Journal, the editors, the editorial board, Oxford University Press or the organization to which the authors are affiliated. The editors and publishers have taken all reasonable precautions to verify drug names and doses, the results of experimental work and clinical findings published in the journal. The ultimate responsibility for the use and dosage of drugs mentioned in the journal and in interpretation of published material lies with the medical practitioner, and the editors and publisher cannot accept liability for damages arising from any error or omissions in the journal. Please inform the editors of any errors.

The opinions expressed in the European Heart Journal are those of the authors and contributors, and do not necessarily reflect those of the European Society of cardiology, the editors, the editorial board, Oxford University Press or the organization to which the authors are affiliated.

Published on behalf of the European Society of Cardiology © The Author 2018.

For permissions, please email: journals.permissions@oup.com

All rights reserved; no part of this publication may be reproduced, stored in a retrieval system, or transmitted in any form or by any means, electronic, mechanical, photocopying, recording, or otherwise without the prior written permission of the Publishers.

Note in accordance with Section 33 paragraph 1 of the Federal Data Protection Law: Dispatch is made using an address file which is maintained with the aid of an automated data processing system. We remind our readers that, when printed, X-ray films never disclose all the information content of the original. Artifacts in X-ray, CT, MR, and ultrasound images are recognizable by their typical features and

are generally distinguishable from existing pathology. As referenced above, healthcare practitioners are expected to utilize their own learning, training, and expertise in evaluating images. Partial reproduction in printed form of individual contributions is permitted, provided the customary bibliographical data such as author's name and title of the contribution as well as date and pages of "Heartbeat" are named,

but the editors request that two copies be sent for their attention. The consent of the authors and editors is required for the complete reprint of an article. Manuscripts submitted without prior agreement as well as suggestions, proposals, and information are always welcome; they will be carefully assessed and submitted to the editorial board for review.

Improving Decisions, Therapies, and Pathways to Enable Better Outcomes

Contents

02 Imprint

03 Contents, News & Stories

Structural Heart Disease

06 Image Fusion Applications: Precision
Medicine for Structural Heart Diseases

10 Valvular Heart Disease Treatment
in Challenging Patients

Coronary Artery Disease

16 Leveraging Patient Data Analytics

24 Effective Exclusion of Myocardial Ischemia
with Cardiovascular Magnetic Resonance
Imaging

Congenital Heart Disease

30 Multimodality Case of Giant
Coronary-cameral Fistula 10 Years
After Percutaneous Closure



News & Stories

In-depth information. Convincing facts
and figures.

This online news channel features compelling
customer experiences, case reports, and market
insights to provide you with unbiased insightful
information. Go online for more information.

healthcare.siemens.com/news

Structural Heart Disease

Over the past 10 years, the number of new devices used in structural heart disease has grown enormously. Heart centers around the globe are treating more and more valve diseases minimally invasively.

We have also seen advanced developments in minimally invasive mitral valve treatments. The mitral valve presents a huge challenge due to the complex cardiac anatomy and difficult fixation, especially when it comes to valve replacement. Attracting increasing interest is the new-kid-on-the-block in minimally invasive treatment – the tricuspid valve. With today's highly complex procedures, effective patient triage, planning, and pooled information is a must.

Reliable imaging of patient anatomy and physiology is required to determine device access, positioning, and anchoring. Detailed images support clinical decisions and become the eyes of the interventionalist. Just one system or one unique feature is not enough to enable optimal outcomes along the whole pathway. And more than ever, patients, clinicians, and hospitals are demanding better outcomes.

Along the entire clinical journey – before, during, and after the procedure – optimal treatment relies on having critical information at the right time.

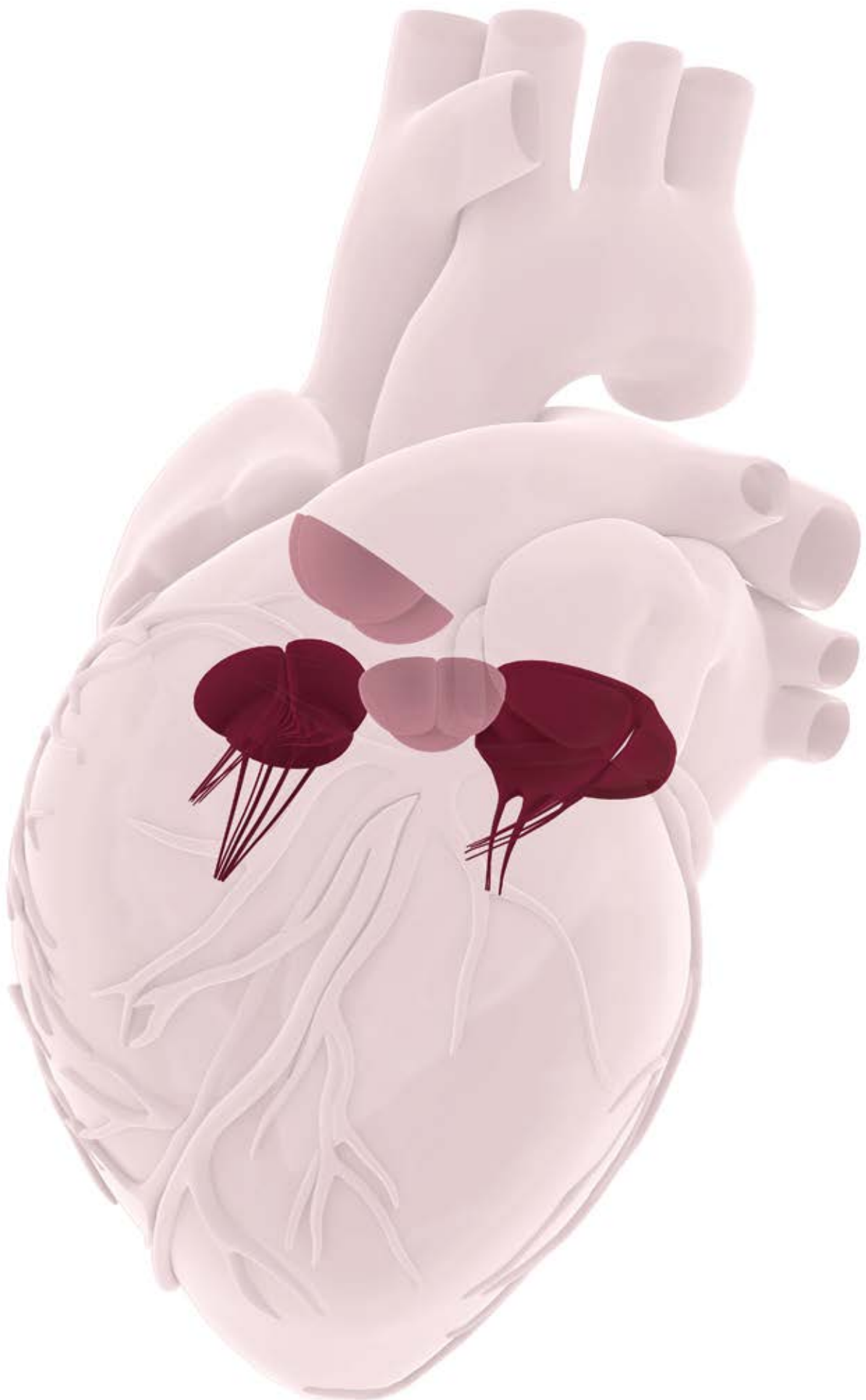


Image Fusion Applications: Precision Medicine for Structural Heart Diseases

.....

Modern catheter technology allows patients with defective heart valves or other types of structural heart disease to be treated successfully, even at an advanced age. The best possible ultrasound diagnostics before and during procedures enable optimum interventions while also reducing radiation dose and supporting maximum safety.

Text: Philipp Grätzel von Grätz

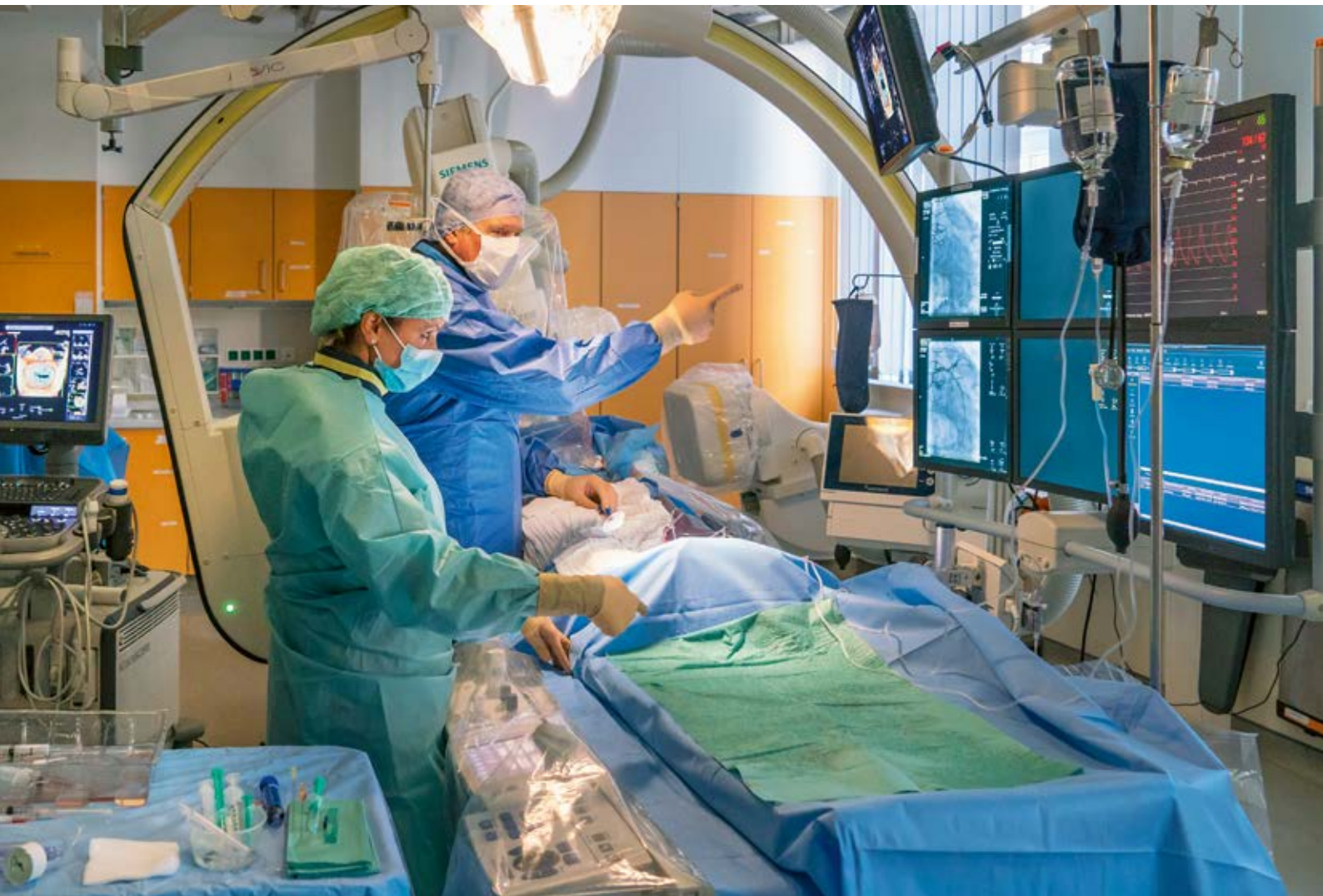When Olaf Göing, MD, Head of Cardiology at Sana Klinikum Lichtenberg in Berlin, performs a mitral clip procedure on a patient with mitral valve insufficiency to repair the leaking valve, he leaves nothing to chance: Starting in the right atrium, he leads the instruments through the interatrial septum and into the left atrium at precisely the right position for an optimum mitral valve procedure. Passing the instruments along a guidewire toward the roof of the atrium, he keeps some distance from the roof and the left atrial appendage to avoid causing any damage. Once in the middle of the atrium, he angles the instruments and navigates them through the center of the mitral valve toward the left ventricle. Throughout the procedure, he takes care not to damage the neighboring aorta. Finally, he opens the clips to grasp the mitral valve leaflets. If everything works as planned, the mitral valve will close tightly again – and the 75-year-old grandmother, who

used to be so short of breath she could barely walk, can go back to enjoying everyday life with her grandchildren.

Interventional valve procedures for people of all ages

In Lichtenberg, catheter-guided mitral valve procedures have become an important additional mainstay of interventional cardiology. Every year, Göing and his colleagues treat around 5,000 cardiology patients with all types of indication on an inpatient basis, in addition to around 4,500 outpatient cases. “These numbers have been increasing for years and will continue to rise,” says the cardiologist. “The population is aging, and the capabilities we have to treat patients with typical age-related cardiological diseases in a minimally invasive manner are constantly improving.”





Intraprocedural image fusion applications enable minimally invasive therapy of defective heart valves.

This applies to cardiac arrhythmias such as atrial fibrillation, where the rates of diagnosis are steadily improving. Since the publication of the CASTLE-AF trial in summer 2017, catheter-guided procedures to treat atrial fibrillation is gaining increasingly acceptance as a further method of improving heart function. It also applies to structural heart disease, and valve defects especially, where catheter-guided procedures have been perfected to the extent that symptom-relieving interventions can now be offered even to patients for whom a surgical valve operation is out of the question.

This is most evident in aortic valve procedures. Transcatheter aortic valve implantation (TAVI) is now used to treat over 15,000 patients a year in Germany, almost all of whom would not have been eligible for heart surgery. Mitral valve defects are rarer, but the number of corresponding interventions is also on the rise. "We'll soon also see clip repairs on the tricuspid valve in the right

heart," says Göing. All of these patients are elderly; many of them aged between 75 and 80, and some even older.

High-performance imaging is essential

Unlike aortic valve interventions, procedures to clip the mitral and tricuspid valves can be performed even without a cardiac surgeon present – following coordination within the surgical team. Sana Klinikum Lichtenberg has realized it can help greater numbers of seriously ill patients than it originally thought and is therefore investing in imaging technology – a basic prerequisite for complex interventions of this kind. "Every heart is slightly different," says Göing. "To reach our target, we need the best possible information about the anatomy and geometry of the heart; not only before the intervention but also in real time during the procedure itself."

For this, the cardiologists in Lichtenberg rely entirely on echocardiography using the ACUSON SC2000 ultrasound system from Siemens Healthineers. To allow optimum planning of each procedure, the valves and chambers of the heart are measured as precisely as possible in two and three dimensions prior to the intervention: "We need to see what exactly is wrong with the valves. Is it a problem with the posterior or anterior leaflet? Have the affected leaflets become too short or stiff? This is vital information that we must have at our disposal."

During the procedure a transesophageal echocardiography (TEE) probe is inserted into the esophagus in order to deliver three-dimensional ultrasound information about cardiac anatomy and heart valve function in real time. In a technique known as *syngo TrueFusion*, this detail is combined with live fluoroscopy from the Artis angiography system so that the cardiologist can judge the position of the instruments not only within a fluoroscopic 2D projection but also embedded within an echocardiograph of the heart's 3D anatomy.

Faster interventions with reduced radiation exposure via high-end echocardiography

Göing is convinced that this method pays dividends for patients: "High-end echocardiography makes our interventions faster and ultimately reduces exposure to radiation. Thanks to more-accurate navigation, it also reduces complications during the procedure. And it genuinely helps us to achieve the desired clinical outcome thanks to enhanced strategic planning of the intervention."

Giving a concrete example, he explains that intraprocedural fusion imaging reduces the risk of injury to key heart structures or adjoining blood vessels: "For example, there's a guidewire that we need to place inside the vena pulmonalis. If we accidentally insert it into the left atrial appendage, there's a serious risk of perforation," Göing says. Fusion imaging also helps the cardiologist to guide the instruments through the interatrial septum and into the left atrium at precisely the right position for an optimum clip procedure.

Olaf Göing, MD, Head of
Cardiology at Sana Klinikum
Lichtenberg in Berlin
.....

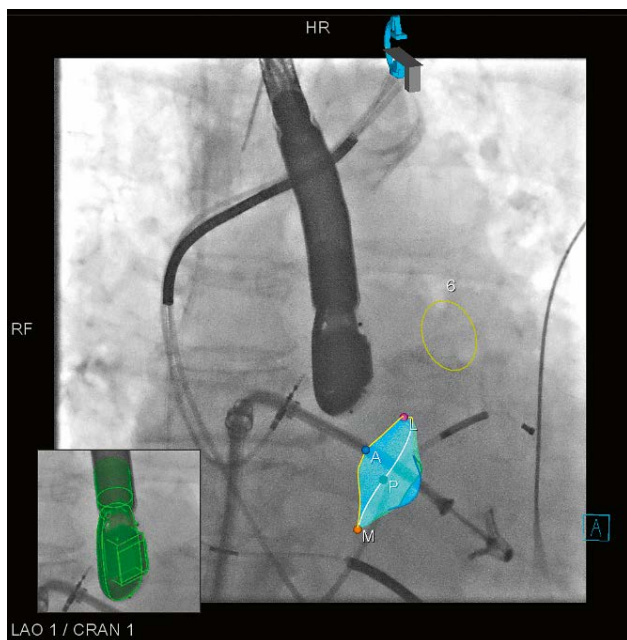


syngo TrueFusion

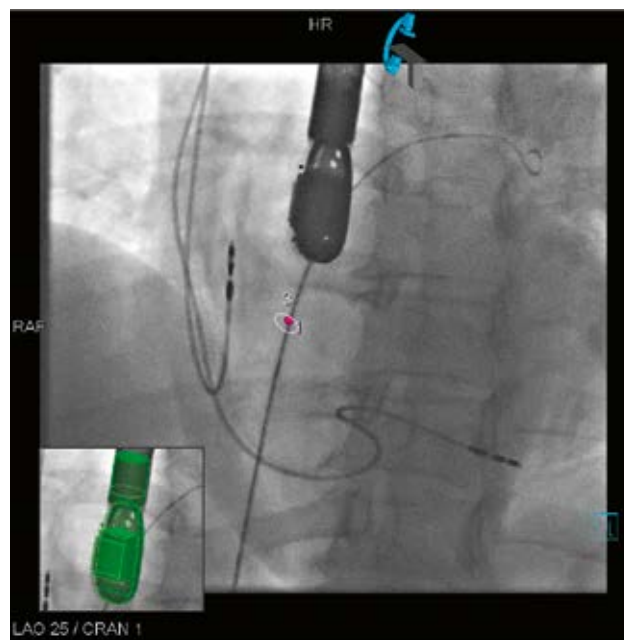
- Automated co-registration of TEE and angiography with artificial intelligence of eSie Sync
- Efficient workflow through export of fusion landmarks directly from the ACUSON SC2000 ultrasound system
- Scope for contrast and fluoro time-savings

Artis zee with PURE

In-room control of relevant functionalities via context-sensitive on-screen menu



Fusion of eSie Valves model for optimal orientation of the clip device.



Fused TEE landmarks of PFO to guide the intervention.

Broad potential for applications beyond the mitral valve

The benefits of fusion imaging that combines high-end echocardiography and angiography are currently at their most evident in mitral valve clipping, but this is not the only area of application. In the future, Göing believes that real-time fusion imaging will also be indispensable in clipping procedures on the tricuspid valve: "The overall geometry of the right ventricle is totally different, so we'll need to learn everything from scratch. Live TEE will provide valuable support for this process."

Image fusion could, Göing says, also be of assistance in other procedures, such as left atrial appendage closure (LAAC) in cases of atrial fibrillation: "Our aim

is to ensure that this method is available whenever it's needed. It could also be an effective training tool for less-experienced colleagues."

Nowadays, image fusion can already be activated quickly during a procedure, and the process is set to become even faster in the future. Moreover, although it is not yet possible to adapt three-dimensional echocardiography datasets to the movement of a beating heart, this problem will likely be overcome at some point. Cardiologists will then be able to maneuver their instruments inside patients' hearts even more safely – and help older people, in particular, achieve greater quality of life. Göing sees this as nothing short of his duty: "If an 80-year-old grandmother is still at the heart of the family and can no longer breathe easily, then it's our job to ensure she can still play with her grandchildren. That's how I see it." ●

ACUSON SC2000 PRIME with real-time True Volume TEE and eSie Valves

Comprehensive analysis of valve function

The statements by customers of Siemens Healthineers described herein are based on results that were achieved in the customer's unique setting. Since there is no "typical" hospital and many variables exist (e.g., hospital size, case mix, level of IT adoption) there can be no guarantee that other customers will achieve the same results.

Contact

Andrea Beulcke
andrea.beulcke@siemens-healthineers.com

Valvular Heart Disease Treatment in Challenging Patients

.....

Until recently, surgical therapies such as valve replacement or valve reconstruction have been recommended for most severe valvular diseases. For many patients, however, surgery was not a viable option due to the high risks of advanced age or the existence of concomitant diseases. Interventional valve therapies can offer an alternative as demonstrated here by a complex case from the Heart Center at University Hospital Bonn.

Courtesy: University Hospital Bonn, Heart Center, Germany

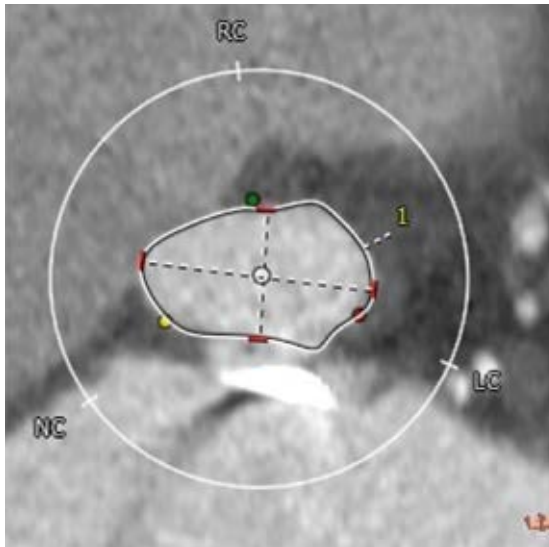
Interventional treatments such as interventional valve therapies are saving lives and improving quality of life for many patients. This is especially true of patients at high risk who cannot undergo surgical valve therapies. In most cases, however, the guidelines still recommend these as the preferred treatment. Advanced age and the existence of severe concomitant diseases such as heart failure, chronic obstructive lung disease, diabetes mellitus or renal failure are the most important contributors to high surgical risk.

Precise and rapid cardiac imaging technologies combined with analytical guidance software – including applications that overlay critical clinical information on real-time images – are making it easier for cardiologists to plan and carry out treatment strategies with greater confidence in challenging cases, reducing risk and improving clinical outcomes. A case study from the Heart Center Bonn in Germany demonstrates how an integrated set of advanced tools was used to improve diagnosis, evaluation, and treatment of a high-risk patient.

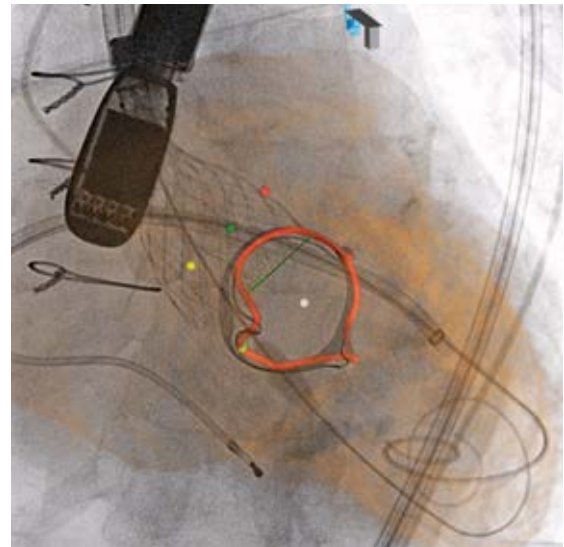
Patient history

A 74-year-old female patient presented to the Heart Center Bonn with severe dyspnea (NYHA class III). She was suffering from two-vessel CHD with a history of PCI RCA (1/2018) and CABG (2014). In 2014, she underwent surgical mitral valve replacement with implantation of a Perimount 27 prosthesis. She was also suffering from atrial fibrillation with elevated risk of stroke (CHADS-VASC score 5), chronic obstructive lung disease, and terminal kidney failure with chronic transplant failure after renal transplantation in 1999. Since then, she has been on hemodialysis.

Initial diagnostic evaluation with echocardiography found a normal-sized LV with an EF of 68%, combined aortic valve disease with leading stenosis (AVA 0.7 cm²) and deterioration of the mitral valve prosthesis with a residual valve opening area of 1.4 cm². These findings were confirmed using real-time 3D TEE. Coronary angiography excluded progress of the known CAD and no significant coronary stenoses were present.

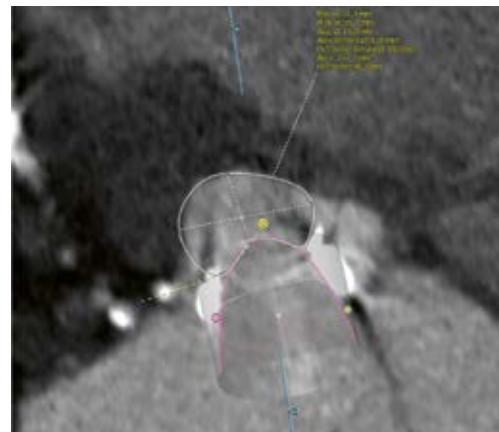
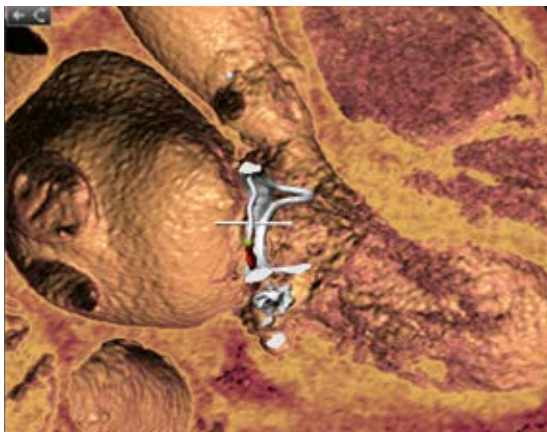
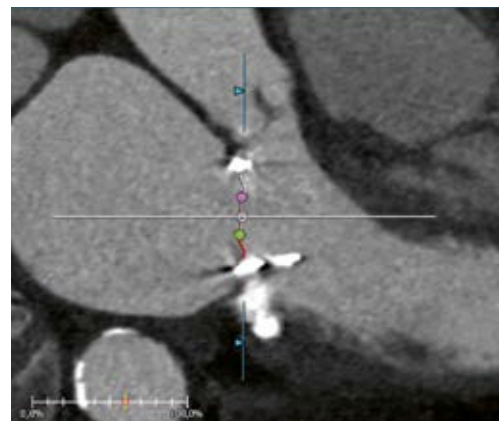
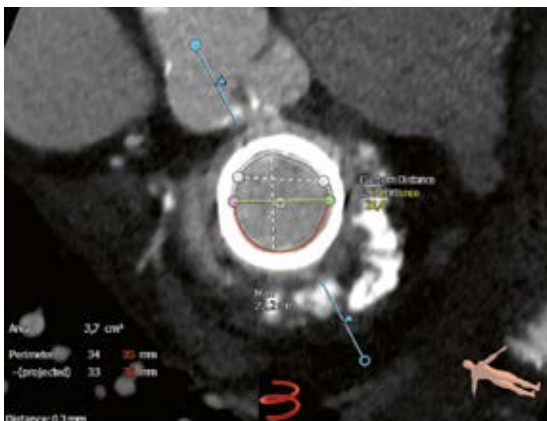


Preprocedural assessment of the aortic valve using CT imaging.



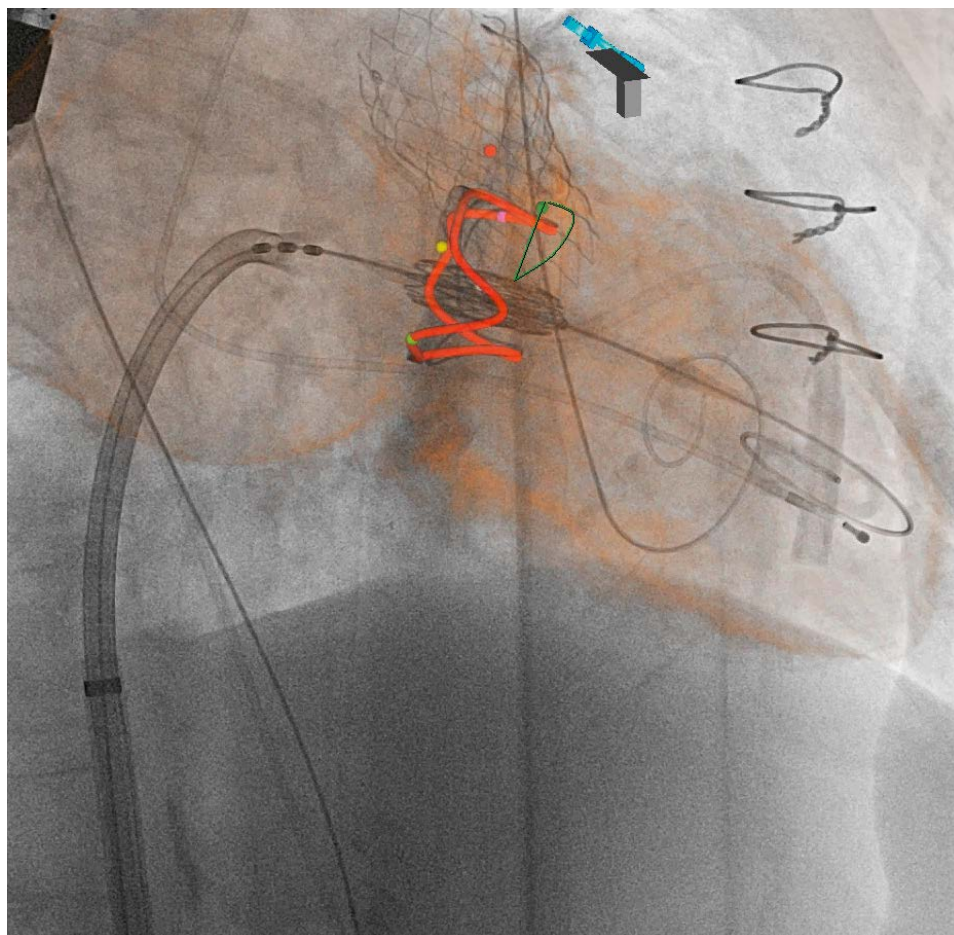
Positioning and deployment of the aortic valve prosthesis (Medtronic CoreValve) with optimized guidance through overlay of CT-derived landmarks.

Assessment of the mitral valve with 3mensio structural heart software. Preprocedural planning for TMViV.

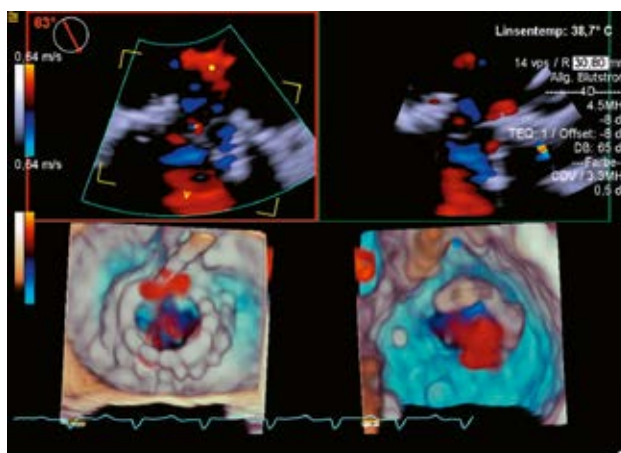


Neo left ventricular outflow tract (LVOT) simulated in an area of 227 mm².

Fusion with preprocedural CT data and annotation of LVOT and 3mensio planning results to guide the mitral valve-in-valve implantation.



Postprocedural real-time volume color Doppler TEE shows good result without indication of paravalvular leakage.



Artis zeego with PURE

In-room control of relevant functionalities via context-sensitive on-screen menu

syngo 2D/3D Fusion

- Enables fusion of preprocedural CT images including 3mensio landmarks with live fluoroscopy
- Improves orientation and helps determine the most appropriate angulation with the potential to reduce contrast and radiation dose

Diagnosis and evaluation

Based on the patient's history, the surgical risk was assessed as too high with a STS score of 19.8 and a STS score of 48.8. Therefore, the cardiac team proposed simultaneous TAVI and a mitral valve-in-valve (ViV) procedure. A combined cardiac and vascular CT scan was performed for further planning. The medical team used CT imaging along with TEE and eSie Valves advanced analysis software, which automatically provides key clinical parameters based on modeling of the mitral or aortic valve.

The CT scan showed calcifications of the iliac arteries; however, there was no contraindication to femoral access (TAVI). CT and 3mensio planning software were used to select the optimal prosthesis size, both for TAVI and mitral ViV intervention. As part of the planning process, the residual LVOT after TAVI and mitral ViV was simulated and showed no significant impairment. The cardiac team chose a Medtronic Evolut Pro (29 mm, TAVI) and an Edwards Sapien 3 (26 mm) for the mitral ViV intervention.

Treatment

The team began with the TAVI in order to clear the aortic stenosis before moving on to the more challenging mitral valve replacement. Positioning and deployment of the aortic valve implantation was guided by fusing CT images and landmarks for the aortic cusp points. Immediate post-procedural real-time 3D TEE demonstrated a good result without indication of paravalvular leakage.

With the aortic valve implantation complete, the team moved on to the mitral valve. The mitral ViV implantation was performed without complications via a venous access

route and transseptal puncture. Real-time 3D TEE and the fusion of live fluoroscopy with the 3mensio planning results guided the team with additional visualization of the LVOT while the valve was positioned and deployed.

Follow-up

Postprocedural fluoroscopy and real-time 3D TEE with color Doppler demonstrated a good result of the ViV implantation without evidence of paravalvular leakage. The LVOT was also not obstructed.

Comments

This successful procedure shows how innovative technologies – both devices and imaging – can help to enable cardiac interventions even in the most challenging, high-risk cases. The team at the Heart Center Bonn was confident that they could plan and perform valve replacement, improving the quality of this patient's life.

When performing complex procedures like dual TAVI and mitral ViV implantation in cases such as this one, multimodality imaging is key to supporting a successful outcome. Ultra-fast acquisition provided high temporal resolution, which freezes cardiac motion and therefore allows for accurate diagnosis of the mitral valve anatomy without breath-hold or heart-rate control. This is especially important for patients like in this case, who suffer from dyspnea.

In addition, the ability to fuse CT images with 3mensio guidance landmarks gave the team more confidence that they could position the prosthetic devices optimally for both TAVI and mitral ViV implantation. ●

The outcomes by customers of Siemens Healthineers described herein are based on results that were achieved in the customer's unique setting. Since there is no "typical" hospital and many variables exist (e.g., hospital size, case mix, level of IT adoption) there can be no guarantee that other customers will achieve the same results.

Contact

Andrea Beulcke
andrea.beulcke@siemens-healthineers.com
Friedrich Fuchs
friedrich.fuchs@siemens-healthineers.com



ACUSON SC2000 PRIME with real-time True Volume TEE and eSie Valves

Comprehensive analysis of valve function



Dual Source CT scanner SOMATOM Force

- Offers ultra-fast acquisition and low kV protocols for CT studies with a minimum of contrast media
- Freezes cardiac motion for accurate diagnostic scans without the need for breath-holding or beta-blockers

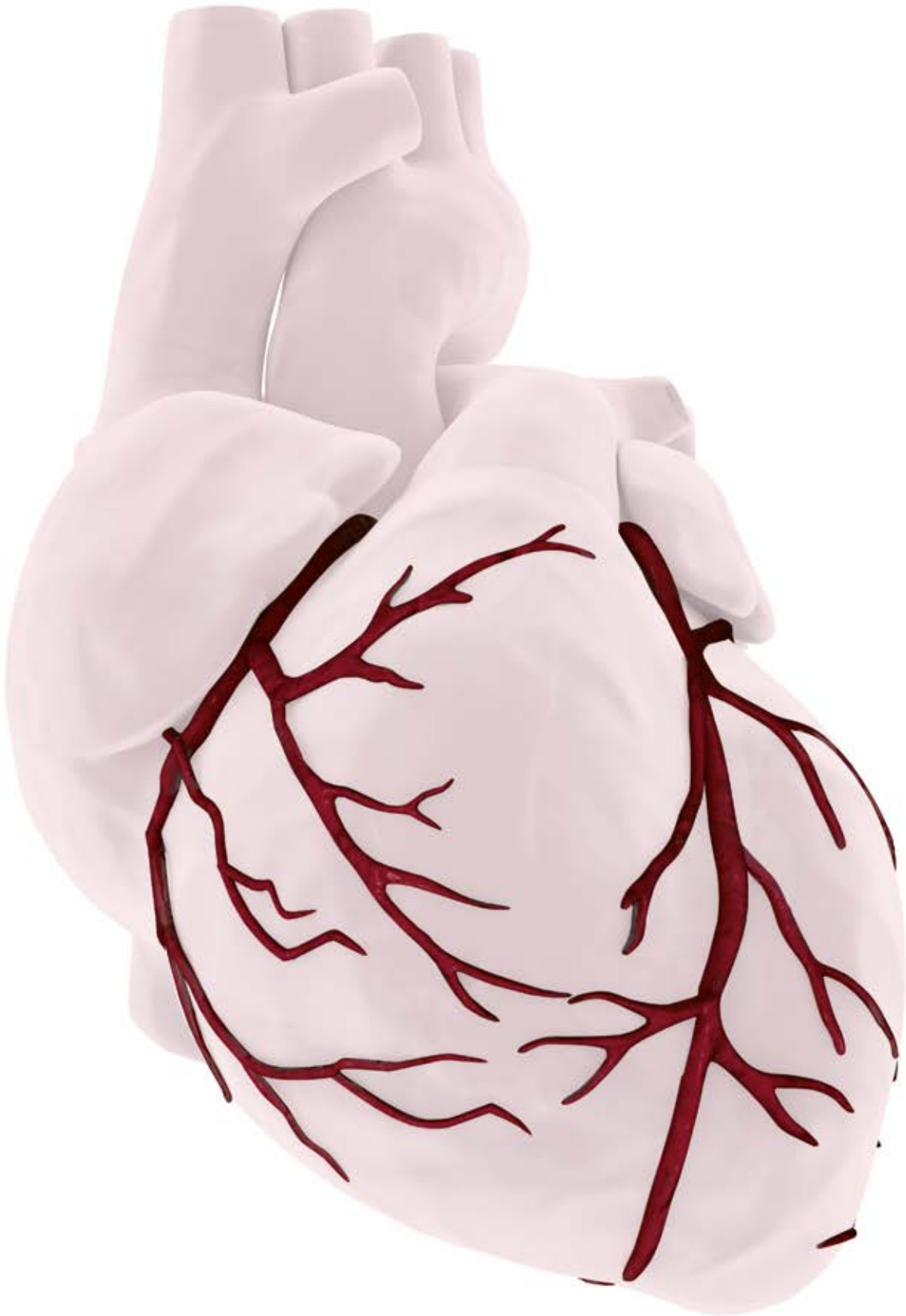
Coronary Artery Disease

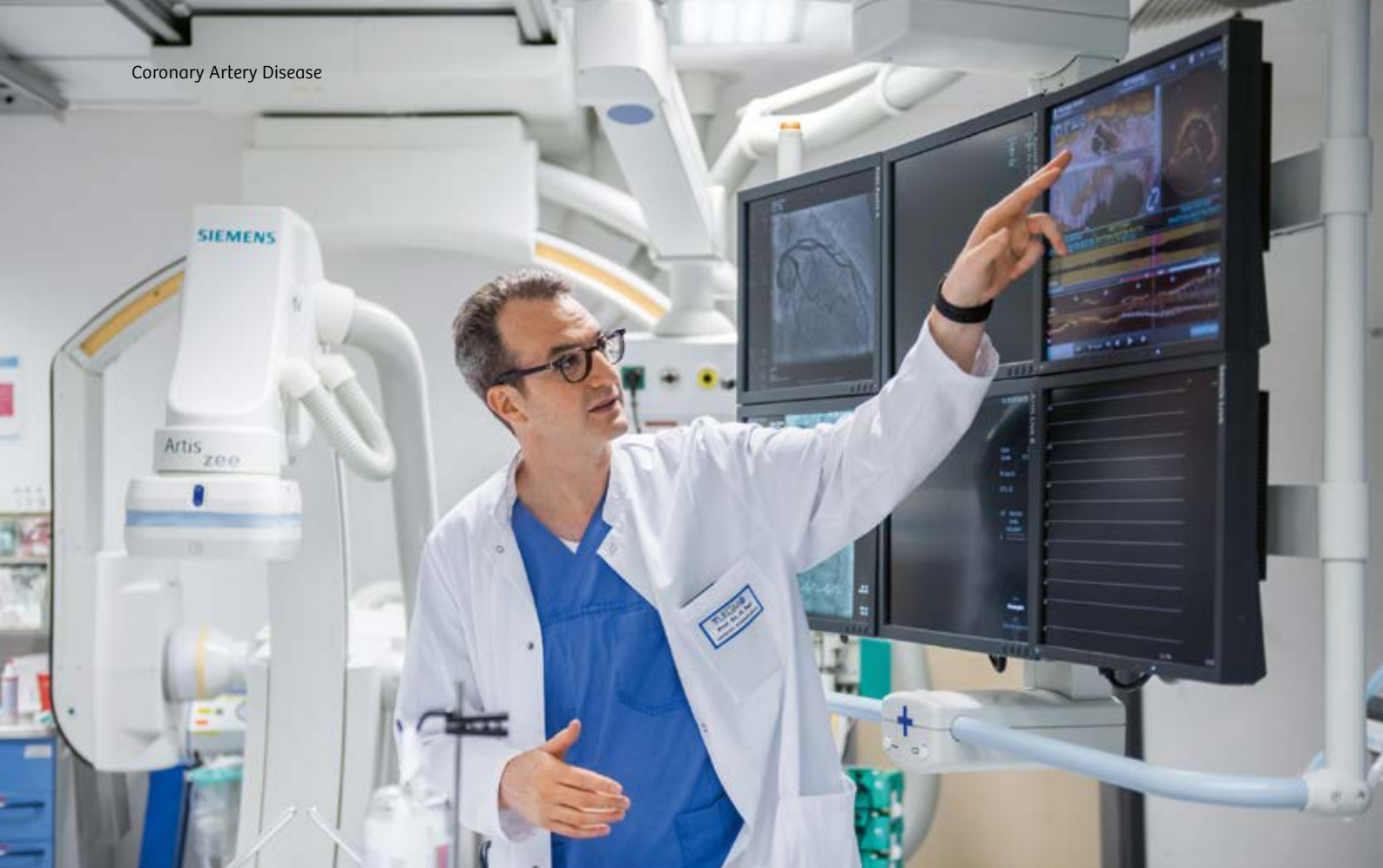Around 14.1 million coronary artery disease procedures are performed annually worldwide.¹ Acute cases require fast and accurate patient assessment to determine the treatment path. This includes ECGs and laboratory or point-of-care diagnostics. In certain cases, ultrasound, CT, MI, PET, and MRI scans help to plan the intervention.

While advanced cardiac implant devices herald a bright future for patient outcomes, they demand more and more from interventional imaging. Modern cardiac devices can be hard to visualize on X-ray due to their delicate structure and material composition. In addition, the complexity of percutaneous coronary interventions is increasing; patient anatomy can be a challenge when it comes to image quality.

In complex procedures, for example to treat chronic total occlusion, imaging for planning and guidance is critical for showing the detail of structures. Medical technology now has the ability to guide and check stent deployment in real time.

¹ Siemens Healthineers procedure data tool based on registries and market reports.



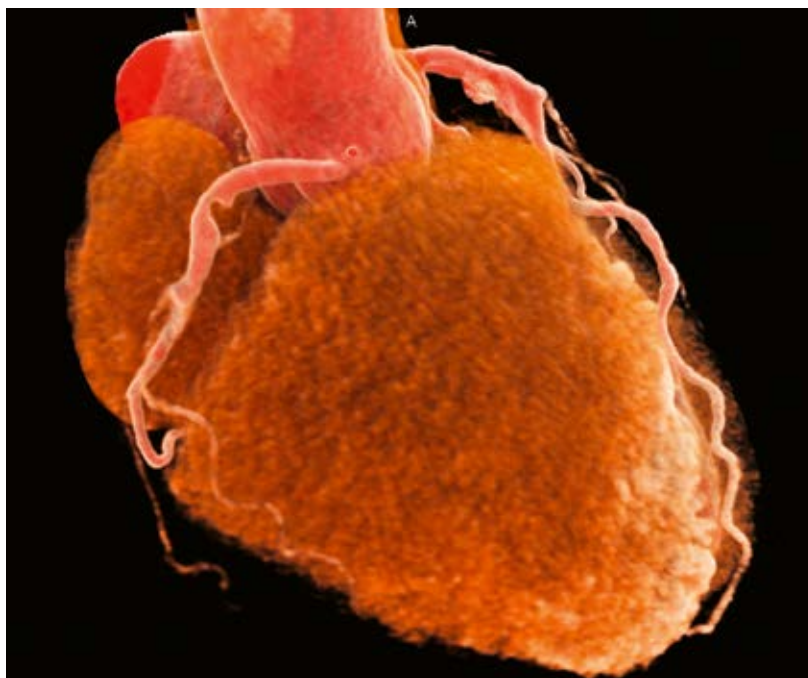

Leveraging Patient Data Analytics

.....

Holger Nef, MD, is one of the world's leading interventional cardiologists. Besides relying on established and innovative intravascular imaging procedures and noninvasive ischemia testing solutions, he also advocates combining all available relevant information to create a comprehensive clinical picture of the patient. The aim is to enhance the quality of treatment in the long term. In this interview, the associate director of the University Hospital of Giessen and Marburg's Cardiovascular Center discusses trends in interventional cardiology, the strengths and weaknesses of intravascular imaging, and his ideas for training new professionals.

Text: Philipp Braune | Photos: Sebastian Bullinger



Cinematic VRT offers a photorealistic view of the cardiac anatomy and the stenosis of the RCA.
.....

Dr. Nef, in your view, how has cardiology changed in recent years?

Nef: The field of medicine in general has been heavily influenced by growing cost pressure on the one hand, and rising quality standards on the other. Striking the right balance between these two factors is the name of the game right now. In regards to cardiology, I think the most striking change is the succession of technological developments we have seen in recent years: For instance, whereas in 2008 TAVI was still in its infancy, it has now become a standard procedure, performed some 17,000 times a year in Germany. Or think of percutaneous AV treatments, where major developments have occurred at a very fast pace. We are now able to perform a mitral valve annuloplasty by applying a band in a way that emulates certain aspects of cardiac surgical procedures, enabling us to provide treatment in almost the same way as cardiac surgeons, but in a noninvasive manner.

How have diagnosis, treatment, and follow-up of coronary heart disease changed in this period?

Nef: In my opinion, the key changes concerning diagnosis of coronary heart disease relate to the functional measurement of stenosis. The ability to measure functional flow reserve is a major step forward in the detection of coronary stenosis requiring treatment. As regards the treatment of coronary heart diseases, we have seen substantial improvements above all in catheter and stent systems.

Developments in stents are not limited to material changes; also notable is the use of narrower stent struts. This has led to significant improvements in our patients' clinical outcomes. Nevertheless, this has not completely eliminated the risks arising from implantation, so we were naturally very excited about the development of bioresorbable scaffolds.

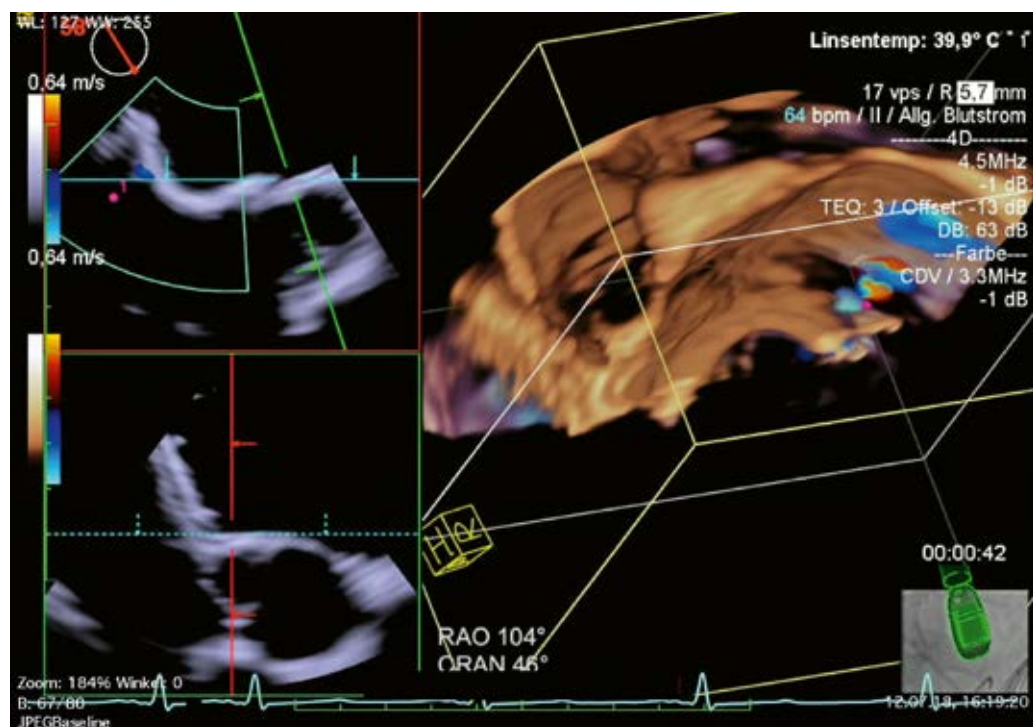


Artis zee biplane

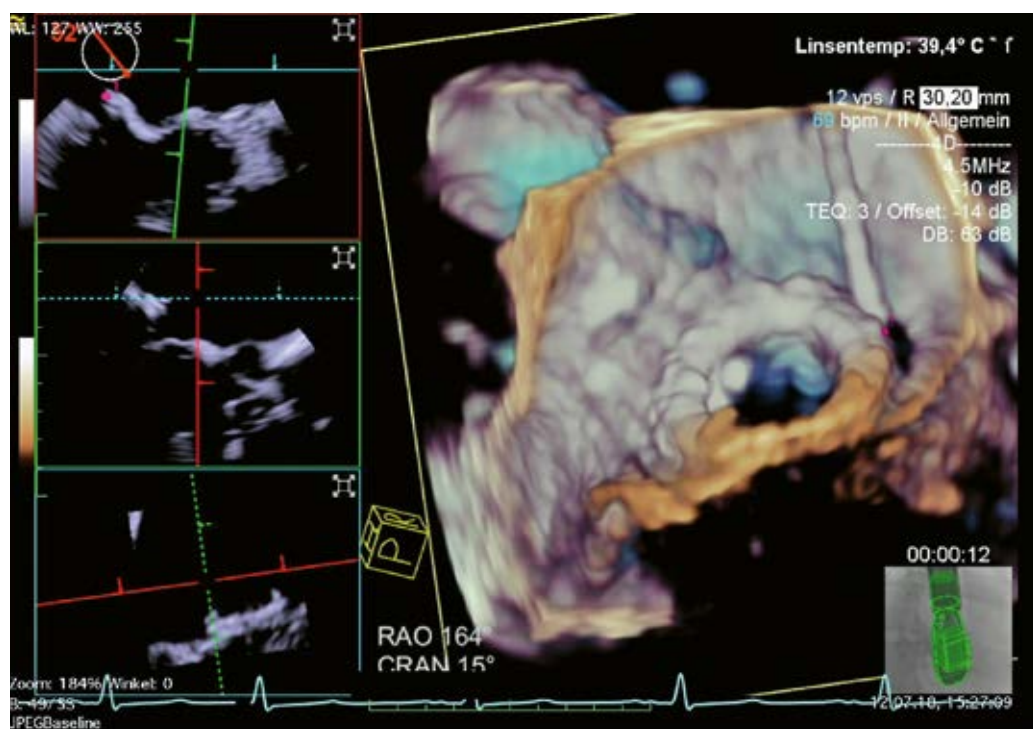
Excellent image quality at low dose levels especially with small detector size within coronary artery disease

Artis zeego with PURE

Dedicated robotic Hybrid OR system with more flexibility for structural heart interventions and 3D acquisitions



TrueFusion landmark
visualized in TEE and
live fluoroscopy enabled
efficient device
navigation to PVL.



Live synchronized fusion of TEE information and
angio image for improved navigation and
anatomical orientation with scope for contrast
and fluoro time-savings

“My own experience shows that intracoronary imaging allows us to perform stent implants much more safely and efficiently.”

Holger Nef, MD

Associate Director of University Hospital of Giessen and Marburg's Cardiovascular Center



However, as a profession, we were not aware that these new scaffolds called for special techniques during implantation in order to ensure a positive long-term outcome. Accordingly, the latest available results are somewhat discouraging. That said, an improved version of the scaffolds that could potentially replace metal in future is currently being tested.

How do you assess your hospital's position in the field of diagnostic imaging?

Nef: For a university cardiac center like ours in Giessen, it is crucial to be able to offer state-of-the-art diagnostic imaging technology. We were among the first centers in Germany to acquire the advanced computed tomography system SOMATOM Force. This meant we could offer our patients a particularly mild form of coronary CT diagnosis at a very early stage. Besides providing a reliable way to rule out coronary heart disease, this technology can also be used to verify treatment results in certain cases. Meanwhile, the latest developments and systems in the field of cardiac MRI can answer the questions regarding surrounding myocardial ischemia/disease with a high degree of precision.

What can you gain from superimposing ultrasound and fluoroscopy images?

Nef: We have only been using the new syngo TrueFusion imaging technology in clinical practice for a short time. Nevertheless, we can already say that the combined information from echocardiography and fluoroscopy gives us precisely the anatomical details that we need to position our implants even more accurately and safely. For the new mitral valve annuloplasty procedure in particular, we gain valuable additional information that can considerably reduce examination times – and therefore radiation exposure for both patients and examining physicians.



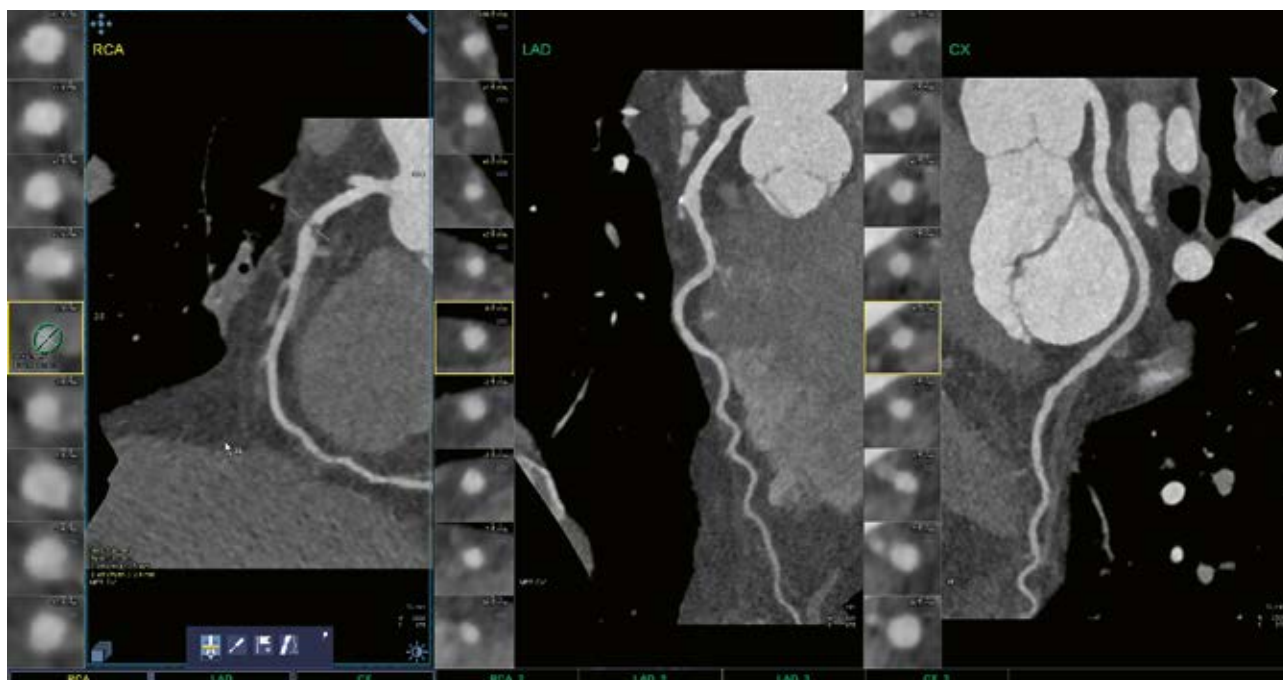
MAGNETOM Avanto 1.5 T

1.5T diagnostic MRI imaging for optimal evaluation of myocardial perfusion and tissue viability



ACUSON SC2000 PRIME

Intraprocedural 3D imaging for added safety



Curved Multiplanar Reformations (CPRs) of coronaries for a quick and reliable rule-out of coronary heart disease with syngo.CT Coronary Analysis.

What specific challenges do you see in noninvasive CT imaging?

Nef: The great strength of CT imaging lies in its specificity. Yet, assessing the extent of a stenosis on the basis of plaque morphology remains difficult. In such cases, divergent findings are still very common, but that does not diminish the huge predictive value of a CT scan. And our goal is quick, early rule-out of coronary heart disease in patients with medium pretest probability. A significant step forward will be noninvasive flow measurement, which will help distinguish a relevant coronary stenosis from an insignificant one.

How important is the issue of dose reduction in your work, and how do you implement the ALARA principle?

Nef: This is an extremely important issue for us. These days, we always begin our X-ray-based examinations with low-dose scans, and are often amazed at how high the image quality is, even with the lowest possible dose. Nevertheless, some examinations naturally require a higher level of radiation. The main thing is that we learn to work with as little radiation as possible, and I think that Siemens Healthineers provides us with effective support in this regard.

You have some experience with stent enhancement solutions such as CLEARstent. What benefits do you think these technologies have to offer?

Nef: The focus of these technologies is on enabling better stent positioning. Stent enhancement solutions help prevent inaccurate



Dual Source CT scanner SOMATOM Force

Freezes cardiac motion for accurate diagnostic scans without the need for breath-hold or beta-blockers



CLEARstent

Stent visualization tool enhancing stent visibility even under difficult conditions

“I think that we should no longer implant stents at all without prior ischemia testing. Not just because our guidelines say so, but because it leads to demonstrably higher-quality results.”

Holger Nef, MD

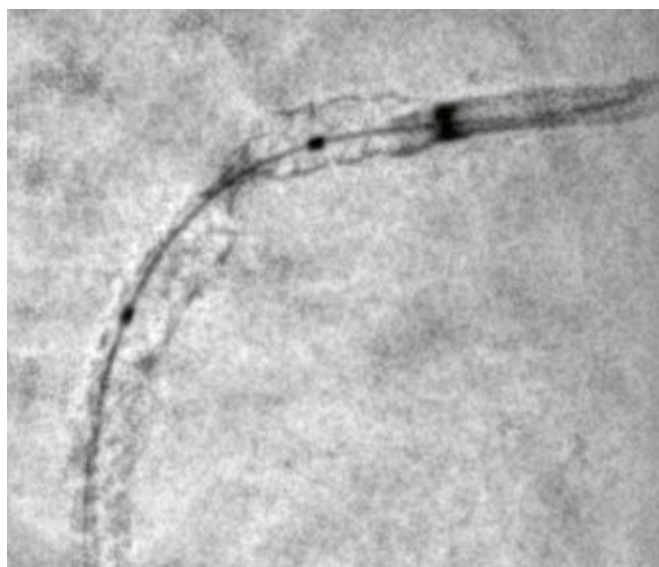
Associate Director of University Hospital of Giessen and Marburg's Cardiovascular Center

stent positioning. Furthermore, they allow us to assess the overall expansion of the stent. I like to compare CLEARstent to assisted parking technology: It is incredibly helpful, but of course it can't completely replace looking over your shoulder. In short, I am an avid user of stent enhancement technologies, and I think they can help us position stents with greater overall safety and accuracy, which is obviously a good thing for our patients.

What are the benefits of intracoronary imaging in your view?

Nef: I think that procedures such as optical coherence tomography (OCT) or intravascular ultrasound (IVUS) offer enormous benefits, at least as far as evaluation of plaque morphology and strategy planning are concerned. Here, too, there is a shortage of good randomized studies on actual patient outcomes. But my own experience shows that intracoronary imaging allows us to perform stent implants much more safely and efficiently, because we know immediately after placing the stent whether it is properly positioned and whether any vessel damage has occurred. In clinical practice, we use OCT and IVUS in a complementary fashion, as both methods have their strengths and weaknesses. OCT offers significantly higher resolution than

IVUS, but requires a contrast agent, which limits usability in patients with renal insufficiency. Furthermore, it only offers a penetration depth of around 2 mm, making it less suitable for larger vessels. In other words, we use OCT wherever possible, and in all other cases we are glad to be able to fall back on IVUS.

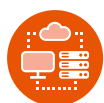

CLEARstent helps to visualize stent expansion – like in this case of an under-deployed stent.



syngo DynaCT

Creates cross-sectional 3D images of the beating heart / the left atrium by rotational angiography



Sensis

Reduces administrative effort and standardizes documentation and reporting

Do you make use of the possibilities arising from co-registration of angiography and OCT?

Nef: Absolutely. This option has made OCT even safer, as angiography gives us the precise location of our OCT catheter at all times. Furthermore, by combining the two images we can evaluate the lesion much more accurately than without co-registration.

What do you think of the potential of noninvasive FFR measurement?

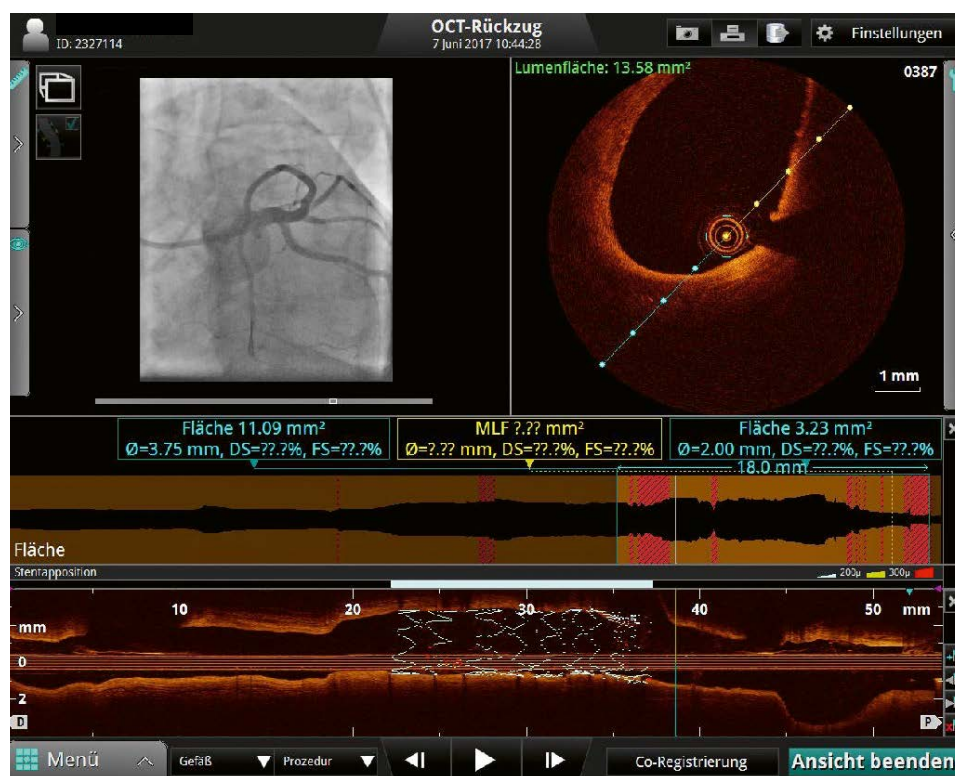
Nef: I think that we should no longer implant stents at all without prior ischemia testing. Not just because our guidelines say so, but because it leads to demonstrably higher-quality results. This is supported above all by the results of the FAME 2 study. I think it would be desirable in future to be able to perform the steps to

determine FFR in parallel and in a largely automated manner – this would give us a kind of live analysis, supporting faster decision-making.

What developments do you anticipate in the field of diagnostic imaging?

Nef: In future, there will be less of a focus on imaging and much more on information itself. Big Data is a concept I am not particularly fond of, but it neatly captures where the field is headed. In future, we will collect and automatically analyze images, medical history, lab data, and information on cardiac function and previous conditions. New systems will suggest treatment methods or offer strategy recommendations for us to adapt to the patient setup. I think this will also present a major opportunity for interdisciplinary cooperation: Putting the patient at the center and connecting

OCT imaging (optical coherence tomography) looks at structures in the arteries and offers very accurate measurements about lesion length and lumen size. This enables better planning for better outcomes.





The University Hospital of Giessen and Marburg, part of the Rhön Klinikum AG hospital group, was formed by the merger between the university hospitals of Justus Liebig University Giessen and Philipps University Marburg. The Cardiology and Angiology Clinic at the Giessen site alone performs more than 4,000 catheter-based interventions a year.

the various dots to form a comprehensive overall picture will substantially facilitate decision-making in everyday practice.

What are your expectations of an industry partner like Siemens Healthineers for future technological developments?

Nef: I don't think that developers, engineers, and medical practitioners can cooperate closely enough for our practical needs to be implemented in products and solutions. Take the continued fusion of intravascular imaging with fluoroscopy, for example. Here we need solutions for automatic transmission of stent dimensions onto the angiography image so that the stent marker can be automatically recognized and the system can tell me when the stent is in the right position. Another issue is training new professionals. I think there is a huge need for simulation tools on which interventions can

be practiced. A trainee pilot doesn't simply sit behind the controls of an A380, take off in San Francisco then land in Hong Kong. I believe that the field of medicine also needs good simulation-based training programs to give young professionals the best possible preparation for the huge responsibilities they are to be entrusted with. ●

The statements by customers of Siemens Healthineers described herein are based on results that were achieved in the customer's unique setting. Since there is no "typical" hospital and many variables exist (e.g., hospital size, case mix, level of IT adoption) there can be no guarantee that other customers will achieve the same results.

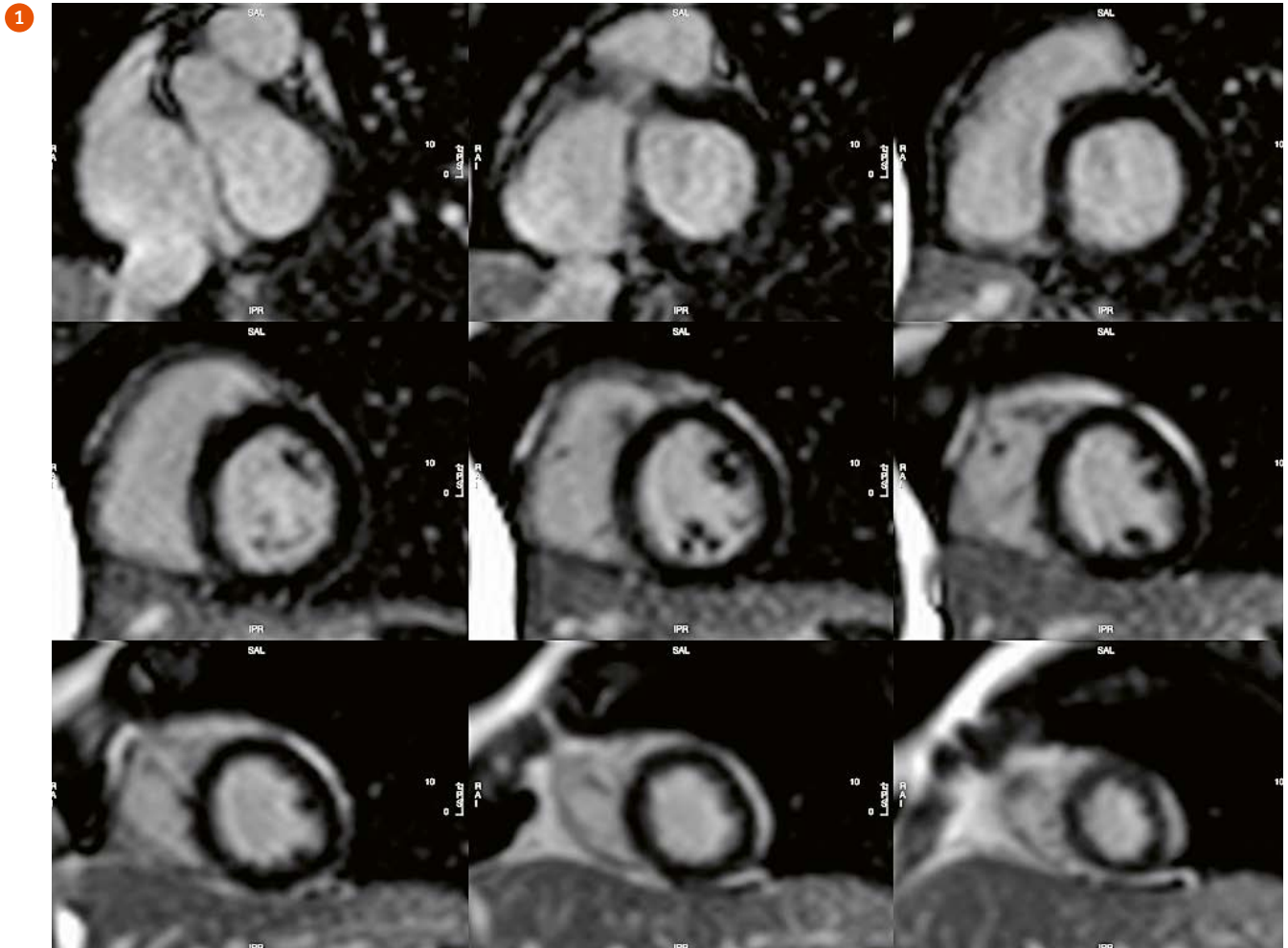
Contact

Petra Schlichtner
petra.schlichtner@siemens-healthineers.com

Effective Exclusion of Myocardial Ischemia with Cardiovascular Magnetic Resonance Imaging

.....

Stephanie Funk, MD, Edyta Blaszczyk, MD, Agnieszka Toepper, MD, Jeanette Schulz-Menger, MD, Working Group Cardiac MRI, Experimental and Clinical Research Center, a cooperation between Charité Medical Faculty Berlin, Max Delbrück Center for Molecular Medicine, and Helios Clinic Berlin-Buch, Department of Cardiology and Nephrology, Berlin, Germany



Background

Cardiovascular magnetic resonance (CMR) imaging provides unique information regarding myocardial tissue differentiation as well as a comprehensive examination of basic cardiac function. Today, it is included in as many as 29 guidelines from the European Society of Cardiology. Nevertheless, it is not yet routinely used in all institutions nor is its versatility fully exploited.

One obstacle facing CMR is the perception that it is difficult and lengthy. However, the development of more robust and faster imaging techniques has significantly reduced scan times in recent years. Depending on the indication, cardiac scan times can range from 5 to 45 minutes (see Table 1). Of course, complex or unusual cases, such as congenital heart disease, may take longer.

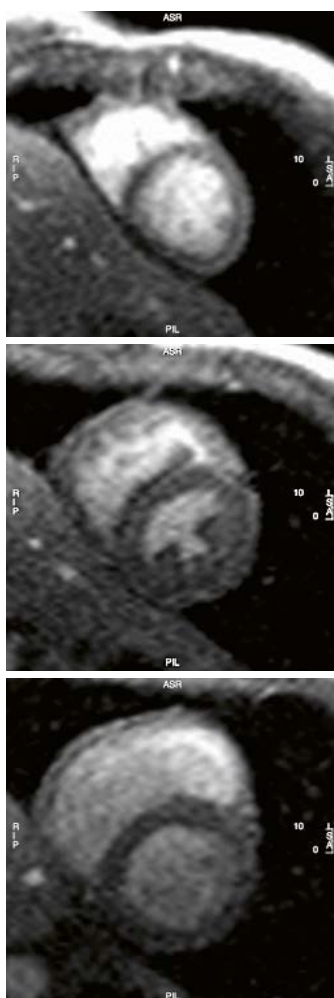Medical doctors often mistakenly believe that CMR is unsuitable for very sick patients even though it can provide unique information for further therapy guidance. New technologies such as real-time imaging, Compressed Sensing, and motion correction algorithms now make CMR imaging available to patients with arrhythmias and those unable

to hold their breath. Currently, even though image quality may be slightly impaired, most diagnostic requests can be covered. Real-time cine imaging is already available in clinical routine. Furthermore, multislice late gadolinium enhancement (LGE) images are now possible without breath-holds. Motion-corrected perfusion imaging allows for stress perfusion with free breathing.

Today cardiovascular MR is included in more than 25 guidelines from the European Society of Cardiology.

CMR is a recognized technique to assess coronary artery disease (CAD) [1]. What is more, CMR is the only imaging modality that can differentiate myocardial tissue, including the detection of irreversible changes such as necrosis, fibrosis, and fat infiltration, as well as reversible injury such as edema. Quantitative parametric mapping techniques such as MyoMaps technology have added significantly to other contrast-enhanced and non contrast-enhanced imaging techniques to clearly discriminate between tissue types and thereby inform treatment decisions. [2–4]

2



- 1 The late gadolinium enhancement (LGE) CMR imaging technique without breath-hold showed no fibrosis or scarring.
- 2 It was possible to rule out myocardial ischemia using stress perfusion imaging without breath-hold in 15 minutes.

A significant advantage of CMR is that it enables the early detection of myocardial injury in preserved ejection fraction, allowing a decision on the course of therapy to be taken sooner. The following case illustrates the potential speed of a CMR examination and its high-quality differentiation of tissue. The scan was performed on a 1.5T MAGNETOM Avanto^{fit} at Helios Clinics in Berlin-Buch.

Patient history

A 42-year-old female with shortness of breath and atypical thoracal pain was referred to the MR unit for adenosine stress CMR to exclude significant coronary artery disease.

The patient anatomy did not allow stress echocardiography and ionizing radiation was avoided due to her age.

Cardiovascular MR provides information on function, ischemia and viability in a short scan without ionizing radiation.

Treatment

Due to claustrophobia-related self-premedication with cumulative 20 mg oral Diazepam and persistent anxiety she was not able to follow the breathing instructions. The MRI protocol was shortened to the essential steps as follows: localizer, cardiac function (long axis), adenosine stress, cardiac function (short axis) and LGE in overview technique (multislice, free-breathing) after a single dose of contrast medium. The whole examination with free breathing was completed in 15 minutes (see Table 2).

In the examination we saw no signs of cardiac ischemia fibrosis or scarring (Figs. 1, 2). Therefore, we could rule out coronary artery disease.


Table 1: Average scan times for routine CMR indications*

Indication	Average scan time
Left and right ventricular function	5–10 min
Angiography	10 min
Inflammatory disease	20–30 min
Viability assessment	20–30 min
Adenosine perfusion	15–30 min
Valvular disorders	10–30 min

* Data on file: Helios Clinics Berlin-Buch, Department of Cardiology and Nephrology, Berlin, Germany.

Table 2: Scan protocol to assess myocardial ischemia

Scan	Scan times
Localizer	1 min
Function LAX	3 min
Stress perfusion	6 min
Function SAX	4 min
LGE overview	1 min
Total scan time	15 min



Example: 15-minute CMR scan to rule out coronary artery disease

Conclusion

We perform over 3,000 clinical CMR examinations per year, mainly on a 1.5T scanner on in- and out-patients alike. Both groups include patients with arrhythmias including atrial fibrillation and many patients who cannot hold their breath. In nearly all cases, we achieve diagnostic image quality. Preparation of ICU patients is more time-consuming, but we keep scan time short since we focus on the main clinical questions.

At a recent meeting of the Society for Cardiac Magnetic Resonance board, members concluded in a position statement that CMR provides more

definitive, relevant, and actionable answers than other noninvasive imaging techniques. Moreover, a CMR exam provides comprehensive information and has superior diagnostic and prognostic power, without the need for radiation.

Given the fact that fast and robust CMR imaging techniques are now available, the benefits of CMR can be extended to more patients, including those with cardiac arrhythmias and dyspnea. Standardized protocols and guidance tools such as the Cardiac Dot Engine are equally paving the way for the use of CMR imaging in clinical routine. ●

References

- [1] Kramer CM, Barkhausen J, Flamm SD, Kim RJ, Nagel E, Society for Cardiovascular Magnetic Resonance Board of Trustees Task Force on Standardized P. Standardized cardiovascular magnetic resonance (CMR) protocols 2013 update. *Journal of cardiovascular magnetic resonance: official journal of the Society for Cardiovascular Magnetic Resonance*. 2013;15:91. doi: 10.1186/1532-429X-15-91. PubMed PMID: 24103764; PubMed Central PMCID: PMC3851953.
- [2] Moon JC, Messroghli DR, Kellman P, Piechnik SK, Robson MD, Ugander M, et al. Myocardial T1 mapping and extracellular volume quantification: a Society for Cardiovascular Magnetic Resonance (SCMR) and CMR Working Group of the European Society of Cardiology consensus statement. *Journal of Cardiovascular Magnetic Resonance : official journal of the Society for Cardiovascular Magnetic Resonance*. 2013;15:92. doi: 10.1186/1532-429X-15-92. PubMed PMID: 24124732; PubMed Central PMCID: PMC3854458.
- [3] Bulluck H, Maestrini V, Rosmini S, Abdel-Gadir A, Treibel TA, Castelletti S, et al. Myocardial T1 mapping. *Circulation journal: official journal of the Japanese Circulation Society*. 2015;79(3): 487-94. doi: 10.1253/circj.CJ-15-0054. PubMed PMID: 25746524.
- [4] Wassmuth R, Schulz-Menger J. Cardiovascular magnetic resonance imaging of myocardial inflammation. *Expert review of cardiovascular therapy*. 2011;9(9):1193-201. doi: 10.1586/erc.11.118. PubMed PMID: 21932962.

The outcomes by customers of Siemens Healthineers described herein are based on results that were achieved in the customer's unique setting. Since there is no "typical" hospital and many variables exist (e.g., hospital size, case mix, level of IT adoption) there can be no guarantee that other customers will achieve the same results.

Contact

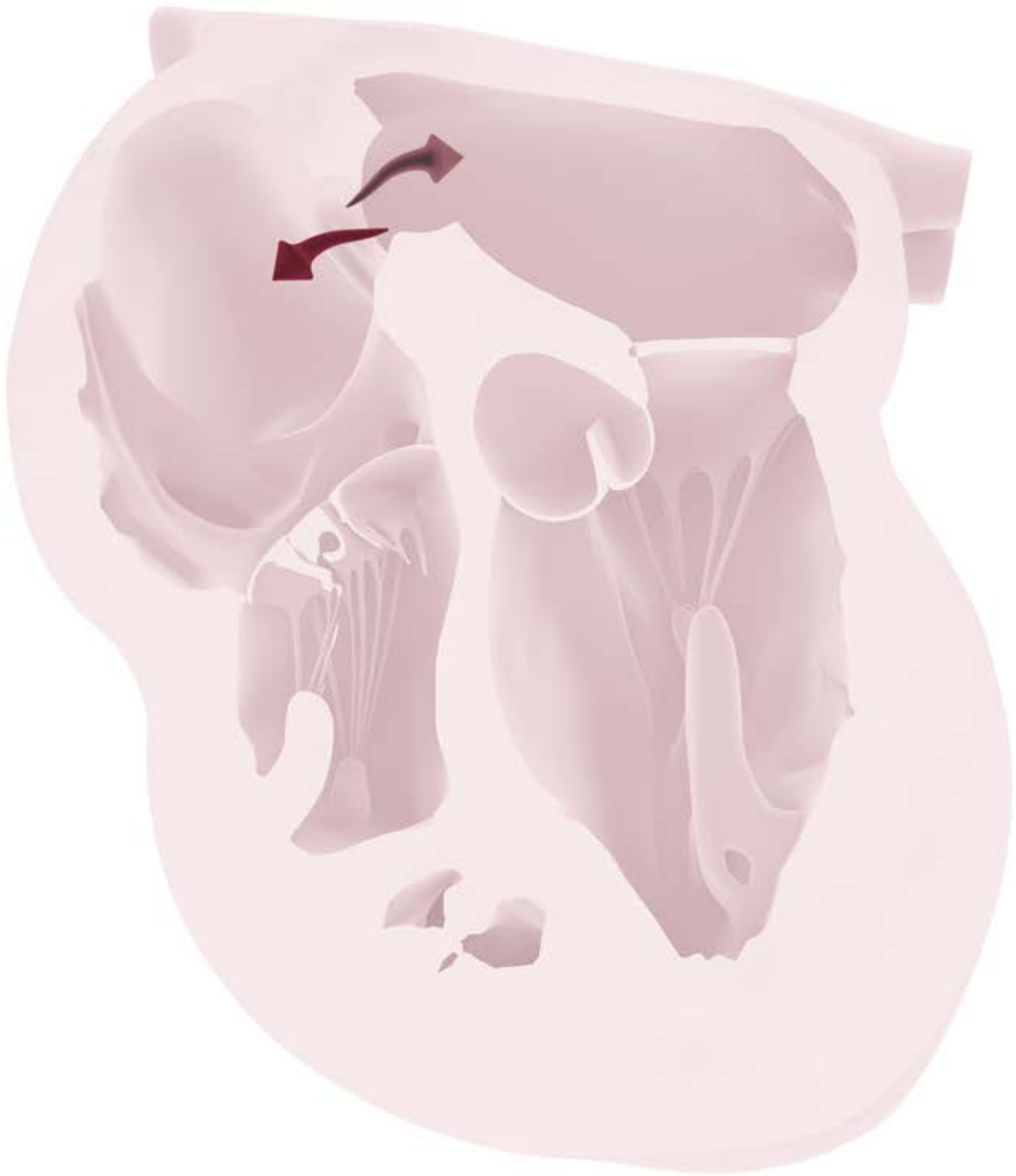
Gaia Banks
gaia.banks@siemens-healthineers.com

Congenital Heart Disease

Around one in 100 children is born with congenital heart defects. Certain defects are so severe that the neonate's life is in immediate danger. Most patients with congenital heart defects, however, survive well into adulthood. On average, 85 to 90 percent of patients born with CHD in the last two decades are expected to survive beyond 18 years of age.¹ Treatment and monitoring, however, involve frequent scans with repeated exposure to radiation.

For vulnerable patients with chronic conditions, minimizing radiation dose is of paramount importance. Treatment of congenital heart disease demands a high level of accuracy in imaging, especially in critical cases of newborns with their minute and delicate vascular systems. With anxious parents and young patients, ultra-low-dose imaging and scans that require no sedation or breath-hold are of enormous benefit.

¹ <http://www.cdc.gov/ncbddd/heartdefects/data.html>



Multimodality Case of Giant Coronary-Cameral Fistula 10 Years After Percutaneous Closure

Fabiola B. Sozzi, MD, Ospedale Policlinico IRCCS Cà Granda, Milan, Italy; Nicolas Hugues, MD, Laura Iacuzio, MD, and Francois Bourlon, MD, Monaco Cardiothoracic Centre, Monaco

Patient history

An 8-year-old girl with a giant congenital isolated coronary-cameral fistula was severely symptomatic for heart failure. The fistula originated from the left anterior descending coronary artery that was aneurysmal, and drained into the right ventricle (RV) (Fig. 1). She was successfully treated with a transcatheter closure using the Amplatzer duct occluder (protheses AGA-CIA 4 mm). The procedure provided sustained clinical improvement as the patient remained asymptomatic and in NYHA class I during follow-up.

A multimodality imaging evaluation was performed. Currently, there is no standardized consensus on the treatment of these fistulas, as this type of vascular anomaly is extremely rare. The percutaneous closure is a safe and effective procedure, though results on its long-term follow-up are still needed.

Evaluation

Ten years later, the patient was extensively reevaluated. The chest X-ray showed a left paracardiac mass (Fig. 2). The echocardiogram confirmed a significantly enlarged RV with prominent trabeculations in its distal part as a component of the giant fistula (four-chamber and parasternal short-axis view: Fig. 3–4). The coronary malformation was partially invading the RV outflow tract without generating a significant flow gradient. The left cardiac chambers were normal. With cardiac magnetic resonance imaging, the apical part of the RV was replaced by the arteriovenous malformation with a deprived function in the involved myocardial wall (Fig. 5). The cardiac computed tomography defined the fistula with its efficient prosthesis well. After contrast injection, the shunt blockage was replaced by a darker RV cavity compared to the whiter coronary artery (Fig. 6).

A coronary angiography confirmed minor blood passage at the prosthesis level.

Comments

Giant, symptomatic congenital coronary fistulas such as the one presented are extremely rare anomalies. There is no standardized consensus on treatment. The prognosis of the percutaneous closure is still not well documented. ●

Reference

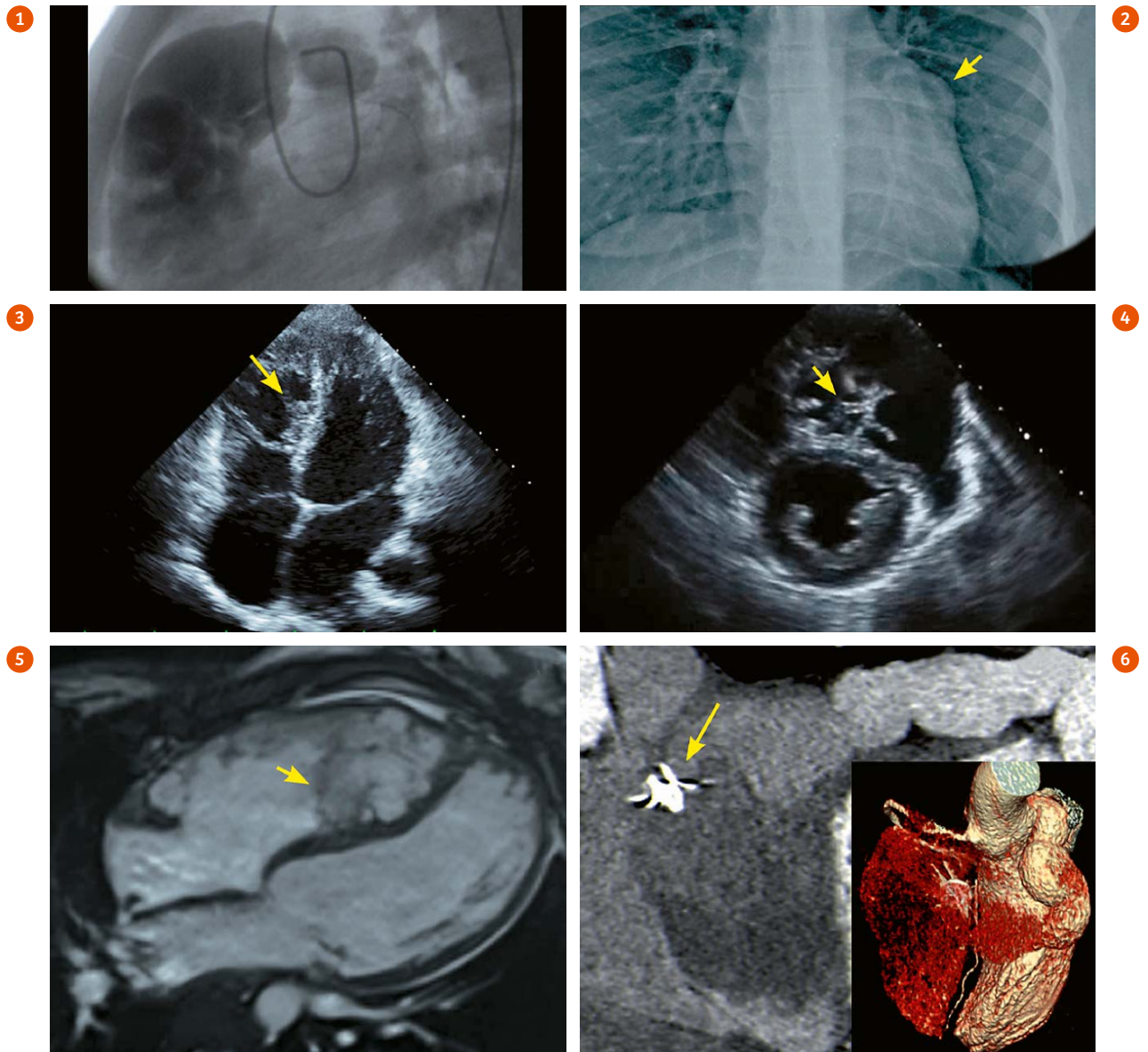
Fabiola B Sozzi et al; Giant coronary-cameral fistula: 10 years after the percutaneous closure, *European Heart Journal* 2017; 38 (20): 1547, doi:10.1093/eurheartj/ehw647. Adapted and reprinted by permission of Oxford University Press on behalf of the European Society of Cardiology.

All rights reserved; no part of this publication may be reproduced, stored in a retrieval system, or transmitted in any form or by any means, electronic, mechanical, photocopying, recording, or otherwise without the prior written permission of the Publishers.

The outcomes by customers of Siemens Healthineers described herein are based on results that were achieved in the customer's unique setting. Since there is no "typical" hospital and many variables exist (e.g., hospital size, case mix, level of IT adoption) there can be no guarantee that other customers will achieve the same results.

Contact

Petra Veit
Veit.petra@siemens-healthineers.com



Dual Source CT scanner SOMATOM Force

- 4D imaging at half of the regular dose
- Preoperative planning for hybrid and conventional surgery



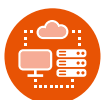MAGNETOM Skyra

- Comprehensive evaluation of cardiovascular status
- Workflow support for cardiac assessment



ACUSON SC2000 PRIME

- Fully automated 3D left ventricle
- Automated flow quantification for advanced preoperative and follow-up cardiac assessment
- Mitral and aortic valve reconstruction and assessment



Imaging IT *syngo.plaza* and *syngo.via*

- Integrated multimodality workspace
- Assessment of multimodality images
- Automated 3D reconstruction, processing, and reporting



Hybrid OR/CathLab ARTIS pheno with Sensis Vibe

- Hybrid endoprosthesis procedures
- Percutaneous interventions and hybrid aortic therapies
- Minimally invasive treatment of congenital malformations

Not for distribution/use in the U.S.

On account of certain regional limitations of sales rights and service availability, we cannot guarantee that all products included in this brochure are available through the Siemens sales organization worldwide. Availability and packaging may vary by country and is subject to change without prior notice. Some/All of the features and products described herein may not be available in the United States.

The information in this document contains general technical descriptions of specifications and options as well as standard and optional features which do not always have to be present in individual cases.

Siemens reserves the right to modify the design, packaging, specifications and options described herein without prior notice. Please contact your local Siemens sales representative for the most current information.

Note: Any technical data contained in this document may vary within defined tolerances. Original images always lose a certain amount of detail when reproduced.

.....
Siemens Healthineers Headquarters

Siemens Healthcare GmbH
Henkestr. 127
91052 Erlangen, Germany
Phone: +49 9131 84-0
siemens-healthineers.com