November 2017

InterventionalNews

EDUCATIONAL SUPPLEMENT

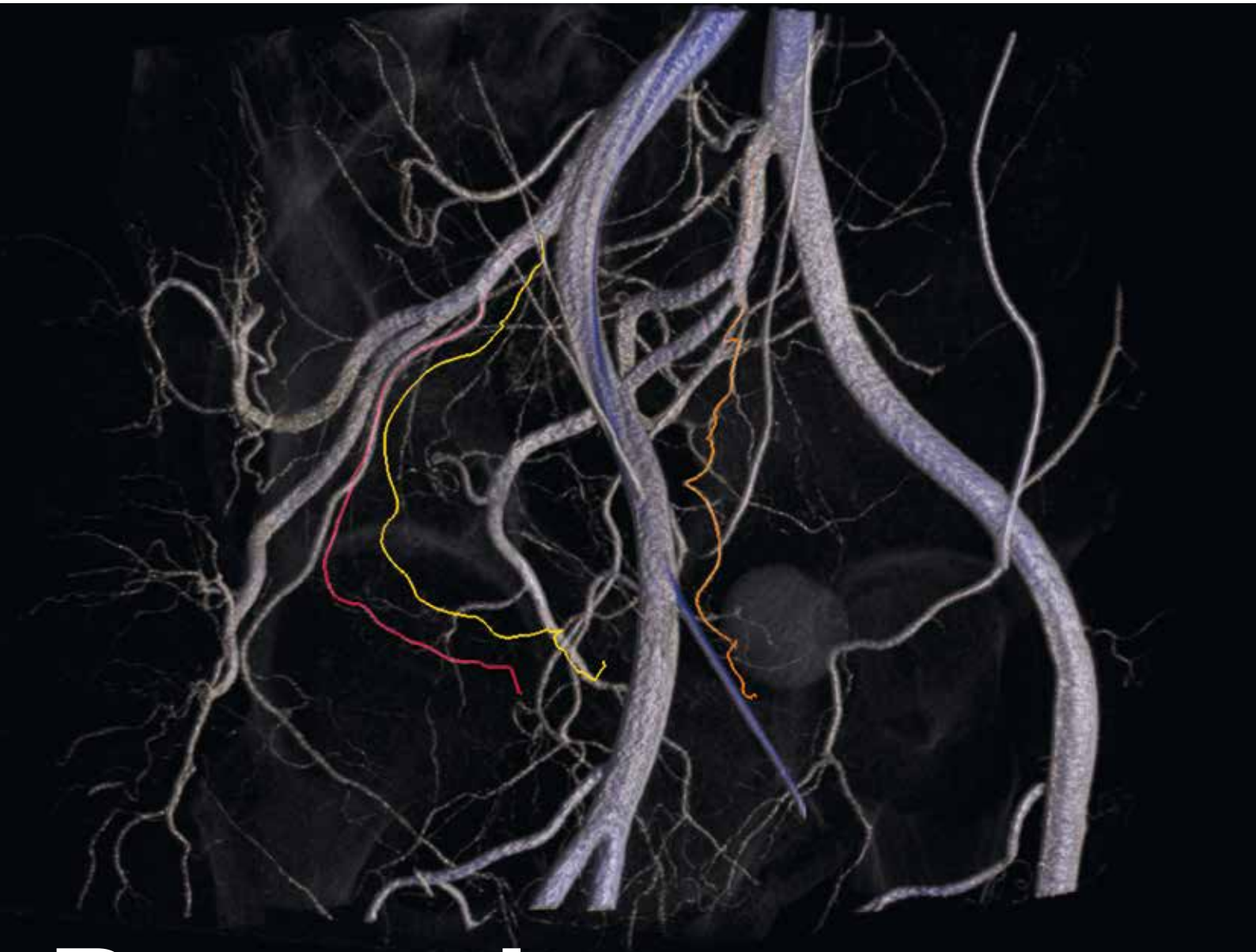

Prostatic artery embolization

Imaging for success

Prostatic artery embolization benefits patients and hospitals

Francisco Cesar Carnevale, associate professor of Medicine, University of São Paulo, São Paulo, Brazil, one of the pioneers of prostatic artery embolization (PAE), speaks to *Interventional News* about why this new procedure benefits both patients and hospitals. Carnevale has just received the *CardioVascular and Interventional Radiology* (*CVIR*) Editor's Medal for his research in PAE.

FRANCISCO CESAR CARNEVALE

University of São Paulo, São Paulo, Brazil

PAE—an attractive treatment alternative for BPH

PAE is being used all over the world as an attractive alternative to medical and surgical treatments for patients suffering from benign prostatic hyperplasia (BPH) because it is a minimally invasive procedure, performed under local anaesthesia on an outpatient basis, with no reported cases of urinary incontinence, retrograde ejaculation and erectile dysfunction. That is why embolization has gained a lot of support from patients and from medical specialists even outside interventional radiology.

Since the first case was performed by our team in June 2008, we have received recognition and support from the Urology and Radiology Departments at the University of São Paulo Medical School in Brazil. This was vital for clinical research in order to continue to prove that PAE is a safe and effective therapy. From our initial reports, published in 2009 in *CVIR*, several studies have been performed to improve the technique and identify the best candidates for the procedure. The fact that other international centres have adopted our PAE technique (the PErFecTED [Proximal Embolization First, Then Embolize Distal] technique) shows that we are moving in the right direction.

Multidisciplinary board must decide on surgical vs. minimally-invasive approach

Patient selection is crucial for any therapy. In our institution, every single patient who has undergone PAE was discussed with a team of urologists before the procedure. Urologists make the final decision regarding indications and contraindications for treatment. We have received patients from urologists and other medical specialties. Nowadays, the vast majority of patients comes directly to the urologist or interventional radiologist, after reading about the procedure on the internet or talking to other patients who have been previously treated. Awareness is essential and patients are usually very satisfied after undergoing PAE.

The business case

PAE is a very attractive option to hospitals as well. With PAE, a hospital can show that it is up-to-date regarding emerging therapies in modern medicine. They can obtain accolades for pioneering treatments, research and teaching activities. National and international recognition stems from that. PAE is also an outpatient procedure and hospitals are on the lookout for highly complex procedures that do not require patients to be in hospital for long periods in order to have a high rotation of beds. In addition, the opportunity to advertise the hospital using a new therapy is a strong promotion for the hospital.

Patients positive about PAE

I have performed PAE all over the world in clinical practice and in teaching and research programmes, and have participated in more than 500 PAE procedures. It has been an amazing experience with patients, physicians and medical institutions. The vast majority of patients have provided positive feedback about embolization. I feel proud to be recognised as one of the fathers of PAE.

PAE has regulatory approval in Brazil

In March 2016, healthcare authorities in Brazil decided to accept PAE as a treatment alternative to transurethral resection of the prostate (TURP). Obtaining this was like "a war with several battles on many fronts". We had to compile a range of data from the animal studies performed in 2007 to preclinical and clinical studies carried out at the University of São Paulo Medical School. This helped the Federal Council of Medicine in Brazil to approve of and recognise PAE as another treatment alternative for patients with lower urinary symptoms related to BPH. We had strong support from the Urology and Radiology Departments, especially from the respective chairmen, who have been my mentors for the last 10 years, professors Miguel Srougi and Giovanni Cerri.

In Brazil, PAE does not yet have a specific code of reimbursement for "BPH embolization". It is often necessary to deal with individual health insurance companies, but some have approved of and pay for the procedure.

Future trends

In the last decade, we have observed many new treatment alternatives for symptomatic patients who are suffering from prostate enlargement. Minimally invasive treatments like stents, ablation, vapourisation, lifting and lasers have been offered. Taking a "helicopter view" this offers a chance that any of these therapies could offer patients a good quality of life, as well as be safe and effective. With embolization, we are offering another minimally invasive treatment to patients, one that appears not to put a patient's sexual life and urinary continence at risk. I believe it is now time to acknowledge PAE and internationally recognise it as a new treatment alternative for these patients.

The cover image is courtesy of Bernhard Meyer, Interventional Radiology, Hannover Medical School, Hannover, Germany.

Planning ahead makes all the difference

Leading us through his pre-intervention planning, Glen Schlaphoff, director of Interventional Radiology, Liverpool Hospital, Sydney, Australia, tells *Interventional News* that the Artis zeego robotic system is highly suitable for prostatic artery embolization (PAE) as it allows total body coverage from the radial artery to the groin, without having to move the table.

GLEN SCHLAPHOFF
Liverpool Hospital, Sydney, Australia

Background

We started the prostatic artery embolization programme about two and a half years ago at Liverpool Hospital, which has a strong interventional radiology programme. We receive patients who are self-referred, referred by general practitioners, or by urologists, who particularly refer patients who are unable to undergo transurethral resection of the prostate (TURP), or those who are still symptomatic after TURP and/or UroLift. We work together with the urology team on a daily basis, and attend multidisciplinary meetings, although these are primarily geared at cancer treatments, rather than focusing on benign disease. The patient cohort in Australia that we see are well-educated men who have widely read around the subject of PAE and have often travelled overseas. Our PAE programme complements the treatments offered by our urology colleagues.

Careful planning is key

This treatment demands good outcomes, especially in the early stage of development. So like any interventional procedure performed, we take immense care in preparing patients for the procedure. This includes careful consideration as to the indications and inclusion criteria for this procedure. The patient is assessed for general medical conditions, anticoagulation, family history, allergies and renal function. Urological evaluation, a urodynamic study (or Qmax) and a prostate specific antigen test are also done at the time of consultation. After the consultation, the patient undergoes assessment for vascular access, and assessment of the gland itself. We take great care in assessing the radial access portal as well as the vascularity of the pelvis and prostate. We also want to assess the gland for possible underlying pelvic disease, including cancer of the prostate or bladder abnormalities. Careful treatment planning is very important as this ensures a good outcome.

Pre-interventional imaging

Once the decision to embolize is made, the patient will have a duplex Doppler ultrasound assessment of the left upper limb; a CT angiogram of the lower abdomen and pelvis; as well as an MRI of the prostate.

Benefits of CT vs. MR vs. ultrasound

The question is, what is the strength of each modality? Having an independent study of the urinary flow by urologists is always good and the patient also has a point of return, should there be a complication, or should they require further treatment or assessment. From pre-interventional imaging, the detailed assessment of the upper limb allows us to have a well-planned programme of radial artery access. We will have predetermined the catheter length and size, assessed whether we should use a groin approach, and we will also decide this from the CT scan. The next modality would be CT angiography (CTA). This is a very specific study of the prostate. We do this on a really high-quality CT scan that provides us with a large coverage and well-timed bolus to the pelvis, which is slightly delayed compared to the normal arterial phase to allow visualisation of prostate arteries. We use thin slices and actually appraise the arterial tree. The important things are good classification of all the vessels including the prostate arteries. We assess basic normal anatomy, prostate artery and variance, anomalous supplies or other things that we need to know about. So CT gives us excellent image, spatial resolution and 3D data that can be fused to the digital subtraction angiography (DSA).

CTA datasets are fantastic at assessing the vascular anatomy. The most important aspect is to assess access to the prostatic arteries. We assess for general atheromatous disease and look at the bifurcation of the aorta and the common iliac arteries, gauge tortuosity and examine whether a radial or a femoral approach (unilateral or bilateral) may be required, and whether a steerable microcatheter or a standard low calibre catheter is needed. We also assess what type of guiding catheters may be required based on the CTA. We actually plan the entire path before the procedure and the dataset is then uploaded into the Siemens angiography system for procedure road mapping. We then proceed confidently with the procedure, once everything has been mapped and the datasets are registered with the current geometry of the angiography system. Then, we also get an MRI which forms the basis of the pre-imaging volume. From the MRI, we get a volumetric assessment on a work station, as well as excellent tissue characteristics for benign disease, including any unilaterality of the benign growth. In addition, the MRI helps us determine whether we are likely to get a good embolization based on the vascularity of the gland. Finally, we obviously need to exclude tumours of the prostate or bladder. The MRI also allows us to evaluate the bladder. We do not yet do a dynamic MRI of the bladder filling and emptying, which may be considered at some institutions.

Ruling out cancer before performing PAE

It is vitally important to do a good quality MRI of the prostate, which is our practice, before embolization. All the prostate MRIs are independently assessed and if we find something that is suspicious and requires active management, this will be referred to the urologists who are part of our team. Then, a biopsy (and ultimately, treatment) may need to be prescribed. However, if it is a low risk gland, we will go ahead with the PAE noting that follow-up imaging in this case is vital, and follow-up MRIs will be arranged for the patient pre-emptively.

Major imaging requirements to perform PAE in the angiosuite

The first requirement is for a dedicated interventional unit that has access to nursing pre-operatively, peri-operatively and during recovery. We then need a machine, preferably an Artis zeego, which allows total body coverage without moving the table. We have found this to be really important, having used a couple of different systems in the past. In my opinion, this robotic angiography system is highly suitable for prostatic artery embolization as it allows total body coverage from the radial artery to the groin, without having to move the table. This is crucial because there are very delicate catheter positions that can be altered if the patient moves. In addition, we actually fix the table height by using an additional

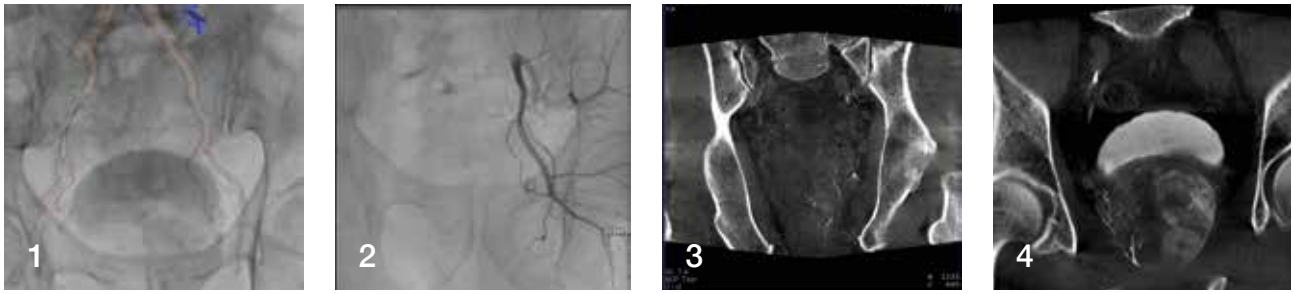

(1) 3D roadmap for guidance during catheter navigation. Here a processed (ie, one that has bone removed and irrelevant vessel structures cropped) pre-interventional CT angiography volume is overlaid on live fluoroscopy **(2)** Low dose 2D acquisition showing left vessel anatomy **(3)** *syngo* DynaCT before release of embolic material to left prostatic gland with catheter in therapy position shows potential non-targeted embolization **(4)** *syngo* DynaCT with catheter in right prostatic artery shows distal feeders to the gland. In addition, tissue enhancement of left prostatic gland confirms coverage of prior left prostatic artery embolization.

height-adjustable operating table on wheels that is placed in between the arm board and the patient table. This is placed at the patient's head end at the same height as the patient's radial artery to place the catheter that was introduced through radial artery. This ensures that any movement of the table that could displace the catheter and jeopardise a good outcome, is avoided. We also want to practice radiation hygiene both to the patient and to the operator so any method to improve coverage in a quick and optimal way reduces radiation to the staff and to the patient, and is incredibly valuable. We also need access to a good workstation, rapid 3D assessment, rapid synchronisation of datasets, both CT and angiography, during the procedure. DynaCT (cone-beam CT performed on the angiography system) must be efficient; we need a very good arm support in the radial position.

Image guidance and dose reduction

We use DynaCT to confirm the catheter postion, not so much to create a roadmap. We prefer to have high quality CT angiography before the procedure, which allows us to plan everything, and even demonstrate what we are going to do to the patient. And then, at the time of the procedure, we use that as our roadmap. Our DynaCT then allows us to confirm that we are in the prostate artery and that embolization will be safe. Also, it allows us to do some problem-solving if we are missing an artery, shows where to look for another one and how to further navigate tortuous vessels in the prostate region. DynaCT also helps define the arteries that feed the peripheral and central parts of the gland and is an essential part of the workflow.

Our whole procedure is designed around keeping radiation as low as possible, so we use DynaCT with cranial-caudal collimation (ie in "slab mode"). A couple of things to note: anteroposterior (AP) view is far less dose intensive than oblique angles, so we make every effort to utilise or watch our embolization in the AP position. Also, the fluoroscopy and the acquisitions are set at a frame rate that maximises clinical safety but also minimises radiation. With regard to Artis zeego's specific DynaCT protocols that are useful for PAE, we can use actually relatively short, fast acquisitions so that we minimise the amount of radiation. We can tailor our imaging to suit the circumstance. Basically the CT and MRI datasets can be fused, manipulated, made into far better angiographic roadmaps and then integrated into the angio system for treatment. This means that comparisons after DynaCT are immediately available to show the percentage of the gland that has been treated.

Use of DynaCT can help avoid complications

"*syngo* DynaCT can be essential in mapping the anastomic connections between prostate arteries and small non-target vessels," says Nigel Hacking, a consultant interventional radiologist at Southampton General Hospital, Southampton, UK. He is the clinical lead for the Register Of Prostate Embolisation for Lower Urinary Tract Symptoms (UK-ROPE) that was designed to compare the results of prostatic artery embolization (PAE) with conventional surgery.

NIGEL HACKING

Southampton General Hospital, Southampton, UK

Clinical success with PAE

Until the UK's health watchdog, National Institute of Health and Care Excellence (NICE), approves PAE, it is performed within a research setting only. There have been more than 200 cases performed in the UK as part of UK-ROPE. At Southampton Hospitals, we have offered the treatment since 2012, performed over 50 cases within UK-ROPE registry and over 150 further cases in other ongoing studies. We basically perform around five cases every month. We set very strict inclusion and exclusion criteria for our initial pilot study. These were then incorporated into the UK-ROPE study and we have continued with the same protocols for our post-registry ongoing studies. All patients are seen by both urologists and interventional radiologists.

Imaging

We perform our treatment planning on pre-interventional images. These are full high-resolution CT angiograms with maximum intensity projection (MIP) and 3D reconstructions to fully understand the anatomy of each internal iliac arterial tree with particular reference to the prostate arteries bilaterally and any important anastomoses. With regard to imaging modalities to assess the prostate anatomy, whilst ultrasound scans are typically used to assess prostate volume, CT angiography is vital to accurately identify prostatic arterial anatomy. MRI is used if there is any concern about malignancy, but MRA has lower spatial resolution than CTA. From the CT angiogram we draw out the arterial anatomy on each side on to a proforma arterial map which is referred to during the PAE procedure itself.

The spatial resolution of CTA is sufficient for assessment of vascular anatomy and even

for detailed planning of catheter navigation and determination of therapy position of the microcatheter, as long as the technique is strictly adhered to. We use bolus-tracked sub mm scanning techniques after sublingual glyceryl trinitrate (2 puffs) and full strength contrast (350 mgI/ml) are delivered at 6 ml/sec intravenously. We use thick MIP reconstructions in the sagittal (15–25 mm thick) and axial (4–6 mm thick) planes to achieve the best results.

We use superselective DynaCT once our microcatheter is placed in what we believe to be the prostatic artery on each side.

Managing complications

In PAE practice today, there have been no deaths and only one case of bladder ischaemia that required a small surgical bladder patch excision and repair. Imaging, such as DynaCT (cone-beam CT performed on the angiography system), can be absolutely essential in mapping out small anastomotic connections between the prostate arteries and small non-target vessels, particularly to the penis, rectum and bladder.

In around 60–70% of sides, I probably use 3D soft-tissue imaging (*syngo* DynaCT) for both left and right prostatic artery to search for suspicious enhancements in order to avoid non-targeted embolization. In a small number of cases, it is very clear that there are no worrying connections and so non-target embolization is not a concern. I use DynaCT with the c-arm positioned to the left of the patient.

Reducing dose

By using Siemens' newest angiographic equipment, we have seen a steady reduction in radiation dose. When using DynaCT, I use low dose settings where these are available. A modern angiography system can result in radiation doses coming down dramatically. In our first 50 cases, when using an older set-up, the air kerma dose exceeded 4 Gy in three cases. In the newer rooms, for our last 150 cases, it has rarely exceeded 1 Gy and never exceeded 2 Gy, even with DynaCT. In 3D imaging, I routinely use low dose protocols such as *syngo* DynaCT Body CARE (that has less projections than *syngo* DynaCT Body). In 2D, I go for both the low dose 2D acquisition and also explicitly reduce frame rates during PAE. I routinely utilise 1 frame per second (fps) DSA rather than any faster rates, with low pulse rates at fluoroscopy. I also always use the "Store Fluoroscopy" functionality instead of specifically acquiring 2D DSA/2D acquisitions for reporting. Of course, DSA (1) is still needed for finer detail when accessing the tiny prostate arteries.

Acquiring good *syngo* DynaCT images

I employ a 0.5 ml/sec injection rate with half strength contrast (1/2 of 300=150 mgI/ml). I generally use an X-ray delay of 6 s. I do my own post processing using both MIP and MPR in several planes.

Images from a 70-year-old patient with lower urinary tract symptoms. **(1)** DSA of left superior vesical branch **(2)** DynaCT of left superior vesical branch shows minor anterior prostatic supply and penile collateral. **(3)** DynaCT shows the filling of a little wedge of the prostate.
Since embolization from this position is not safe, the interventionist should reposition the catheter, re-confirm the therapy position, and only then embolize the prostatic branch.

Training vital to ensure effective PAE treatment

Marc R Sapoval, head of the Vascular and Oncological Interventional Radiology Department, Hôpital Européen Georges-Pompidou, Paris, France, who first performed a prostatic artery embolization (PAE) in 2013 and has trained more than 100 interventional radiologists, explains why undergoing an extensive and step-by-step training before offering the procedure is essential. He also reveals how exciting new research in the area of functional imaging could impact PAE's future.

MARC R SAPOVAL
Hôpital Européen Georges-Pompidou, Paris, France

Explosion of interest in PAE

PAE is a very interesting procedure, the demand for which looks likely to grow and grow. From my observations at conferences and from our training programme in Paris, there is an explosion of interest in learning how to safely do PAE. As of today, we have pretty good proof that PAE is an effective and safe treatment for patients. At the recent Cardiovascular and Interventional Radiological Society of Europe (CIRSE) meeting in September, we heard data from a randomised controlled trial and results from the UK registry that provided further evidence in favour of the procedure. We still lack level one evidence that compares the results of embolization with those of best medical treatment, but to remedy this we are currently enrolling patients in a randomised controlled trial in France (the PARTEM trial; funded by the French Ministry of Health) that is designed to gather this data.

Cone-beam CT essential

Our interventional suite is equipped with cone-beam CT, which is a very important requirement to perform PAE. With regard to room set-up, ours is similar to the regular set-up for any other embolization procedures achieved via femoral access. While we mostly use the femoral approach for PAE, we have also done a small number of radial cases. We use MRI as pre-interventional imaging to assess the prostate anatomy, but do not routinely use CT angiography. We use conventional angiography and cone-beam CT for guidance during the procedure. Siemens Healthineers' Embolization Guidance that we use to target the appropriate artery is very useful.

"See one, do one, teach one" not enough for PAE

Training is mandatory before offering PAE due to the high-risk nature of the intervention. It should be a step-by-step process. When I first learned the procedure, we did not have

as many opportunities as we have today of proctorship and access to simulators. We first went to "see" a case in another institution, because seeing—really—is believing. When you see the first case, you understand the overall intricacies of the technique, and the difficulties but also the rewards that you get from helping patients with this procedure. This is very important, because we need to be passionate about the procedure.

We also offer training at our institution to physicians who want to begin offering PAE. We usually train six or seven people at a time. These interventional radiologists come into the angiosuite and we then perform three cases. They are positioned near the table, see the entire preparation, flow injection, observe the discussion and see the cone-beam CT. At the end of the day, this is a great starting point.

The next step is to have a proctor onsite. This is where an expert comes to the trainee's institution. You can then schedule two to three cases in a day and the expert can guide you through these. You can also attend one- or two-day courses that are available from many vendors. There is now also a simulator-based training package for prostatic artery embolization and I would recommend several sessions of practice on a wide variety of cases with the view to improving your metrics with respect to radiation protection; radiation dose; the number of attempts made; the time required to reach the appropriate artery; and the mistakes made with regard to anatomy.

As part of your training, it is very important to bring your urologist into the loop. My take-home point is that if your urologist can go to the training centre with you, he will refer cases to you. It is important to remember that urologists may not be entirely familiar with embolization. Some might even believe that embolization entails the release of embolic particles from the aortic bifurcation. When they realise that we go so deeply into the vasculature, use cone-beam CT to understand the anatomy so well and see us at work, urologists are usually reassured.

Using the optimal technique

Ensuring excellent technique and offering a "complete" treatment is vital. In order to obtain the best response with embolization so that the patient can observe a maximum reduction of symptoms, we use Francisco Carnevale's PErFecTED technique, which stands for Proximal Embolization First, Then, Embolize Distal. The most important aspect is to completely embolize all the arteries that go to the prostate, and to try to go as distally as possible.

As of today, there is no way to guess the efficacy of the intervention, based on the angiographic results obtained after the procedure. Sometimes, intraprocedurally we may fail to catheterise a key vessel, and this, of course, will mean that the procedure is unsuccessful. However, there are cases when we obtain angiographic success and great post-procedure images, but then, this does not go on to correlate entirely with clinical success and symptomatic improvement for the patient.

Role of functional imaging

It is exciting to research the role of functional imaging and to see if it has any intra-procedural role to help make PAE more effective. Functional imaging definitely has a future, but we probably need more time to correctly identify its application in the procedure.

Ideally, we would like to use functional imaging to understand the volume of tissue in which the blood flow was actually blocked, and the volume of the transitional zone that was actually reached by particles. We might also be able to achieve this with radiopaque particles, morphologically, if not in terms of function.

The objective of using intraprocedural blood volume imaging is to work on assessing the overall blood volume to the right lobe and left lobe before and after the procedure as a surrogate for perfusion; as a surrogate for tissue function; or as a surrogate for volume reduction, in order to try and foresee what volume reduction we will go on to achieve. However, all these remain research questions at this stage. With critical limb ischaemia, the aim of endovascular intervention is revascularisation, so the change in blood flow might be measurable with functional imaging. With embolization, the aim is devascularisation and I think we do block the blood flow, at least at the macrovascular level. At the level of capillaries and microvascularisation, we are not entirely clear where we create ischaemia, so these are all interesting questions for the future.

Actively reducing radiation dose crucial for complex procedures

Is it imperative that a complex procedure must equate to high overall dose? No, radiation dose can be reduced for both the patient and operator even for complex procedures, says Goetz Richter, Clinic for Diagnostic and Interventional Radiology, Katharinenhospital Stuttgart, Germany. Richter's team has succeeded in significantly lowering the dose for both uterine fibroid embolization (UFE) and prostate artery embolization (PAE). Siemens Healthineers has a Combined Applications to Reduce Exposure (CARE) system functionality for all relevant modalities.

GOETZ RICHTER
Katharinenhospital Stuttgart, Germany

The beginning

We started offering PAE around five years ago. Katharinenhospital is a centre for multidisciplinary uterine fibroid treatment and we have vast experience with UFE, which we began offering to patients in 1999. There are significant similarities between the male and female vascular anatomies, although the uterine artery is usually a much larger vessel than the arterial supply to the prostate gland. PAE is similar to UFE, but much more complex. Still, we have found very high rates of patient satisfaction with the procedure as it is virtually painless for patients and the hospital stay is very short. The improvement in clinical symptoms, although slower than with resection, is clear and the procedure is satisfactory to patients in around 90% of cases as measured using several objective parameters.

For PAE, DAP should be below 5,000 cGy·cm²

Last year, as published, our dose area product (DAP) for UFE procedures and our average values were a little over 1100 cGy·cm². This year, having included 43 patients (with an average body mass index of 21.7), it was calculated to be

961 cGy·cm² This significant reduction was achieved by reducing the number of digital subtraction angiography (DSA) runs and replacing them with fluoroscopy. In order to position the catheter, we can then use 2D overlay techniques after choosing a well-contrasted image from the fluoro run as provided by our Artis zeego system.

In PAE patients, the DAP is usually higher as we apply cone-beam CT prior to the procedure, so we reach an average of around 6,500 cGy·cm². We do not perform prior pelvic CT examinations, as some other institutions do, because this contributes to a higher radiation dose.

I would strongly recommend that beginners first perform either a high quality pelvic CT or use cone-beam CT, as we do, to identify the vascular anatomy. Furthermore, high frequency fluoroscopy and DSA should be avoided and collimation should be perfect. Then the DAP of the procedure alone (ie, when the dose of cone-beam CT is not taken into account), can and should be below 5,000 cGy·cm².

Dose reduction

Before embarking on dose reduction strategies, first and foremost, operators need to achieve an adequate expertise with the pelvic vascular anatomy. Once this is achieved, it is important to set a low frame rate for fluoroscopy (4/s); low frame rate for DSA (1/s or 0.5/s) and the best possible collimations. Additionally, it is critical to avoid DSA whenever possible by using fluoroscopy overlay technology and to use a minimum number of oblique projections. Whenever possible, it is also useful to employ image fusion guidance. All these measures will result in dose reductions for both the operator and the patient.

Workflow

Our workflow is highly standardised and includes pre-interventional imaging, lab values, objective and symptomatic urologic assessment, which are based on the applicable guidelines. Then during the procedure (Foley catheter) DynaCT is used to identify the pelvic vascular anatomy. Embolization is performed with a microcatheter (2–2.7 F) using embolic particles <400 microns.

A recipe for dose reduction

Standardised procedural steps in a high-volume setting

These are the most relevant procedural steps for a typical PAE procedure as performed in the Clinic for Diagnostic and Interventional Radiology at Klinikum Stuttgart.

1 Patient preparation

Placement of a Foley catheter on the morning of the procedure.

2 Premedication 30 minutes prior to puncture

Intravenous application of 250 mg prednisolone, 4 mg ondansetron, 1.25 mg midazolam, 1 g novamine and 7.5 mg piritramide.

3 Angiography system parameters

Selection of the "low-dose pelvis" preset with low-frequency pulsed-fluoroscopy (4 pulses/s) and a low frame rate for digital subtraction angiography (DSA) acquisitions (0.5 or 1 image/s).

4 Maintenance of analgesia

This is not necessary.

5 Vascular access

Short 5 F sheath from the right side.

6 Catheterisation of the left iliac artery

After reviewing the MRI and MRA (dynamic visualisation of pelvic vascular anatomy) and under fluoroscopy guidance (field-of-view of 22 cm; collimation; no tube angulation), catheterisation of the main stem of the left internal iliac artery applying a 5 F ROC catheter and a soft glidewire with an angulated tip.

7 Identification of the prostate vessels

DynaCT: delay 6–8 sec; 30 ml contrast at 2 ml/sec.

8 Reaching the embolization position

Selection of appropriate vessels and application of Embolization Guidance to advance a 2 F coaxial microcatheter system. Intra-arterial spasmolysis (eg 0.5 mg nitroglycerine) to the target position.

9 Embolization

Flow-controlled injection of biocompatible calibrated microspheres (Embozene microspheres, CeloNova BioSciences/Boston Scientific) with a size of 250 µm until stasis. Angiographic documentation of stasis.

10 Catheterisation of the right iliac artery and prostate vasculature, only if necessary

Before this, there should be careful evaluation of prostate opacification during DynaCT from the left iliac artery to identify collateral flow. If present, there is no need for bilateral embolization.

11 Vascular access management

Removal of catheters, sheath, and needle. Patient receives compression and sterile bandages.

12 Follow-up

Removal of the Foley catheter the next morning. MRI for evaluation of devascularisation after 10 days. Patient satisfaction and clinical evaluation using standardised questionnaires.