

Improving Resolution, Productivity, and Diagnosis. SMS TSE and GO Protocols in an Optimized Clinical Workflow.

Johan Dehem, M.D.

VZW Jan Yperman, Ypres, Belgium

SMS TSE for shorter scan times and thinner slices

Simultaneous Multi-Slice (SMS) acquisition is a technique that we know from EPI DWI that delivers consistently good results. SMS enables faster scan times and thinner slices, leading to an increase in resolution, better diagnosis, and more productivity at the scanner. The value of SMS is known from extensive experience with the MAGNETOM Aera system. Since SMS TSE (turbo spin echo) is an integral part of MAGNETOM Sola, we were eager to start using SMS in TSE imaging.

Using SMS with a factor 2 on MAGNETOM Sola renders twice the amount of slices in the same time. So, you can either scan faster (halving the number of

concatenations in T1 for example), or scan 50% thinner slices, or achieve 200% coverage with the same slice thickness, or combine all of them. Numerous thin slices are especially beneficial in the axial plane; however, where you need many coronal or sagittal slices, SMS is also the best option since it does not consume time or signal.

Using SMS in small joint imaging like wrist, elbow, and ankle, we are able to achieve large coverage with really thin slices. Also it allows us to scan the complete pelvis/both hips with thin slices – as thin as 3 or even 2 mm. This would have required a prohibitive amount of time before SMS TSE. It can also be employed whenever you need the combination of large coverage and thin slices, e.g., to examine the course of a peripheral nerve.

Looking at our initial experiments with SMS TSE, we began by simply ticking the checkbox SMS factor 2 in the acceleration subcard of the resolution card in a coronal T1 TSE sequence and using that SMS factor to bring the number of concatenations from 2 to 1:

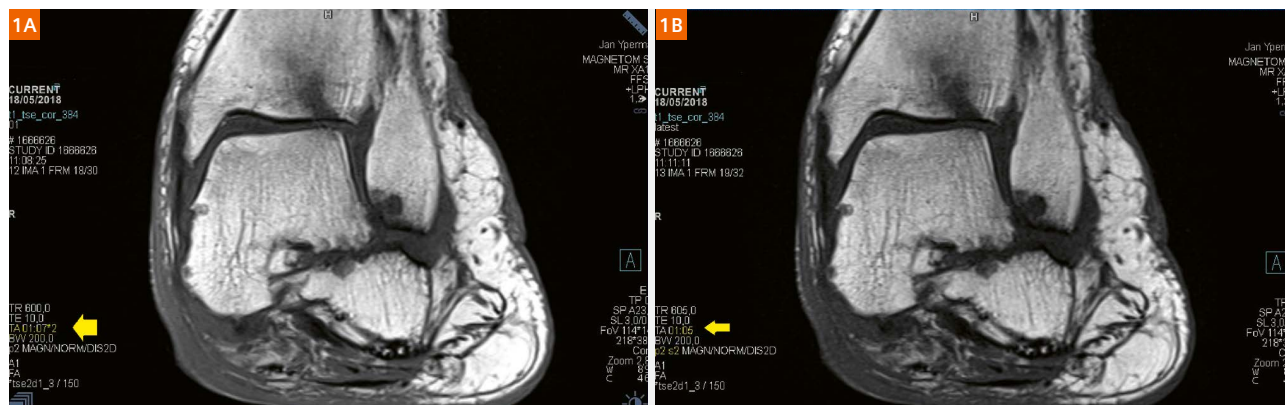


Figure 1:

Corresponding image of the first attempt at SMS: Simply ticking SMS factor 2 halves the number of concatenations from 2 to 1. This effectively halves the acquisition time from 02:14 min to 01:05 min (yellow arrow) without discernable loss in signal or image quality.

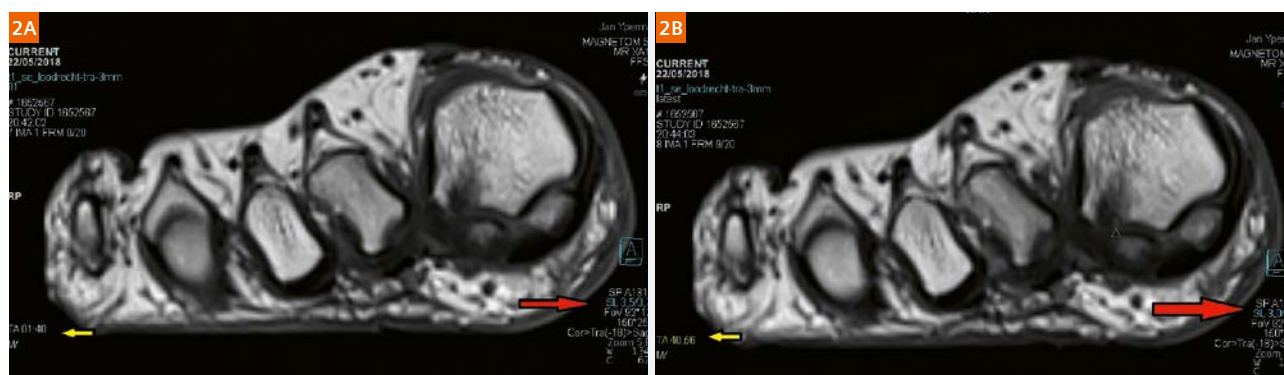


Figure 2:

Another early experiment using SMS to scan with a thinner slice thickness (red arrow). This actually leads to better depiction of osteochondral lesion (top of yellow triangle) and 60% reduction in acquisition time (yellow arrow). (2A) 3.5 mm in 100 seconds, (2B) 3 mm slice thickness in 40 seconds.

This early experimenting was quite convincing and SMS TSE was subsequently adopted in most of our 2D TSE MSK sequences early on. The only exception was in regions where there is already enough coverage with thin slices, e.g., coronal slices of distal extremities (fingers, toes ...), where only a small number of slices are needed. Our main goal is to scan quickly (SMS halves the number of concatenations in T1; halves the TR in intermediate-weighted sequences) and/or increase resolution by scanning thinner slices where SMS halves the TR. This eliminates the time penalty one normally gets by increasing the number of slices. One can also use SMS to remaster and optimize sequences from scratch to combine thinner slices, more coverage, and a shorter acquisition time. SMS is yet another degree of freedom to further optimize your imaging.

Some examples from our clinical routine in the following cases:

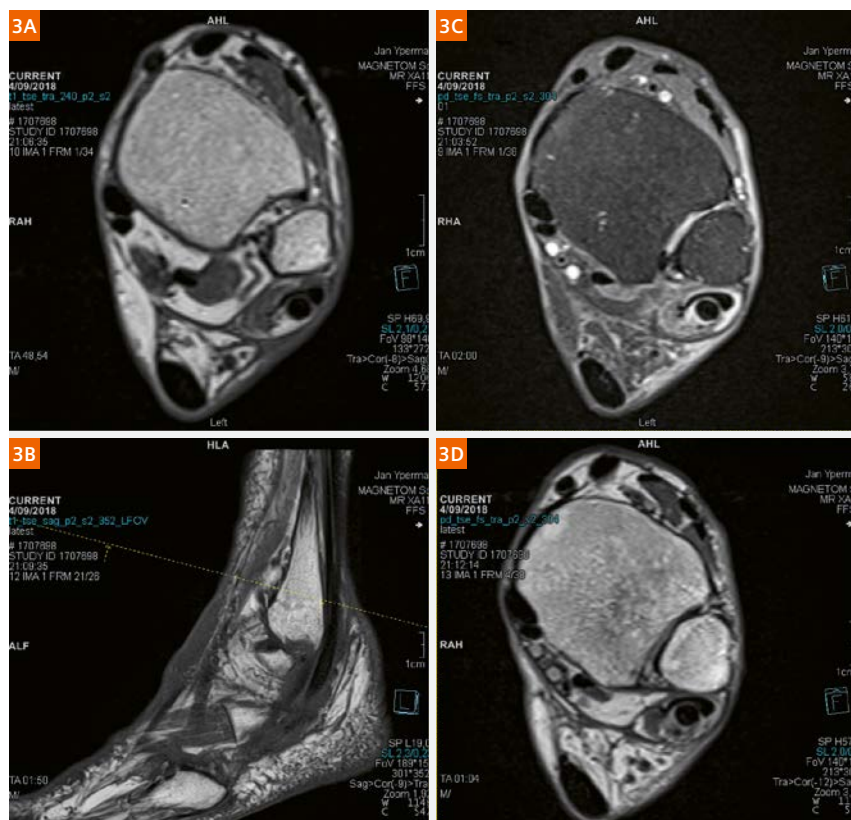


Figure 3:

Example of SMS in an ankle exam. Sagittal and axial T1, 2 mm slices (3A, B) and axial PD and PD fatsat 2 mm images (3C, D) in high resolution and short imaging times nicely demonstrating peroneal tendon rupture.

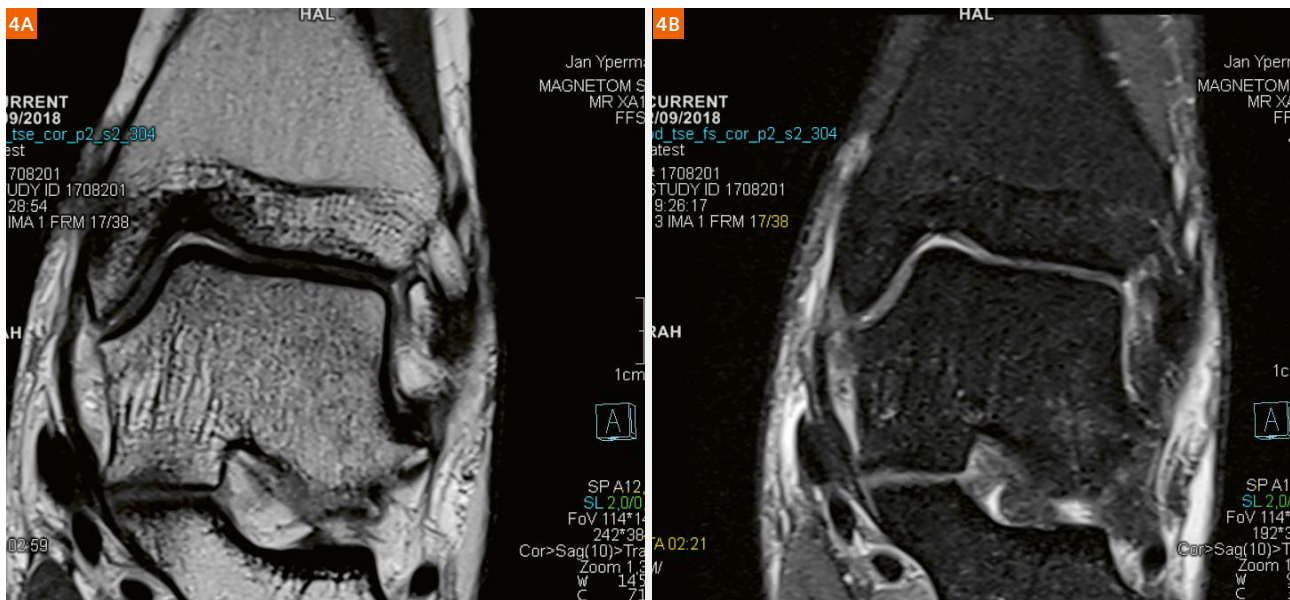


Figure 4:

Coronal PD and PD fatsat 2 mm slice thickness, 0.5 mm in-plane resolution and 38 slices in 2.21 seconds for the PD fatsat. Great delineation of cartilage in talar dome and distal tibia; at 1.5T.

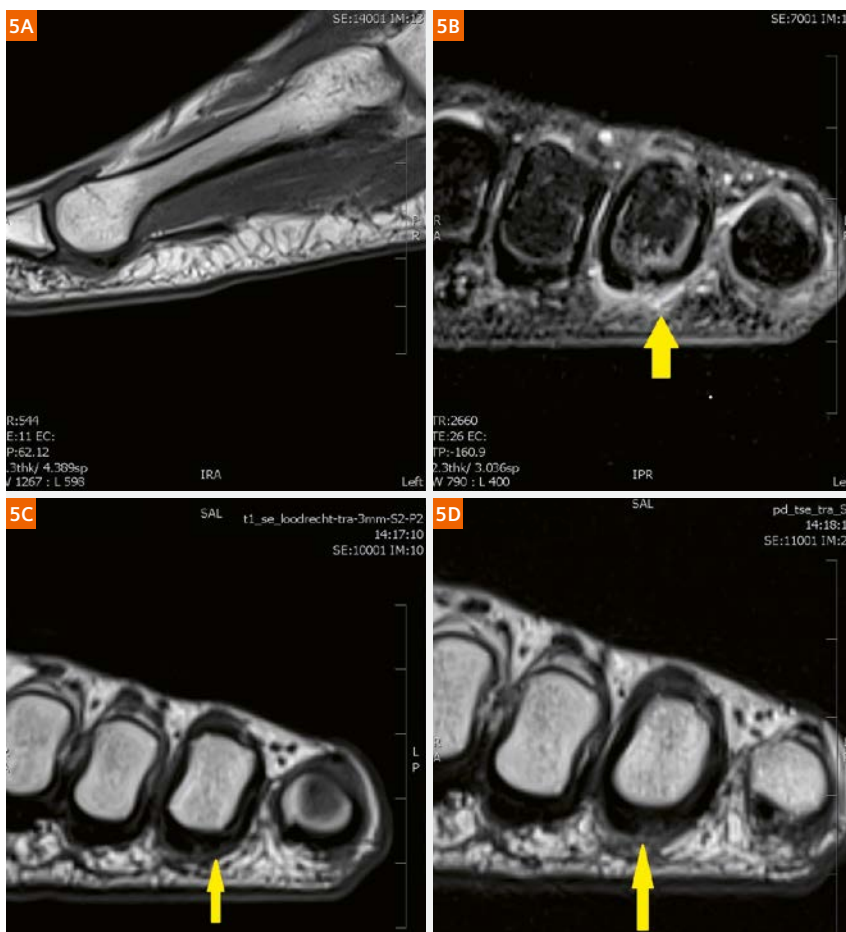


Figure 5:

Plantar plate tear (yellow arrow) easily depicted on thin slice imaging: Fast and with many thin slices is the new adage in foot imaging!

In hip imaging, standard full coverage of both hips and complete pelvis was formerly done with 5 mm slice thickness, since thinner slices would demand more TR and or concatenations, making it impossible to fit this exam into our 20-minute timeslot. Again, SMS imaging is the solution to scan more and thinner slices in the same or shorter acquisition time, leading to standard use of SMS for standard hip/pelvis imaging (Fig. 6).

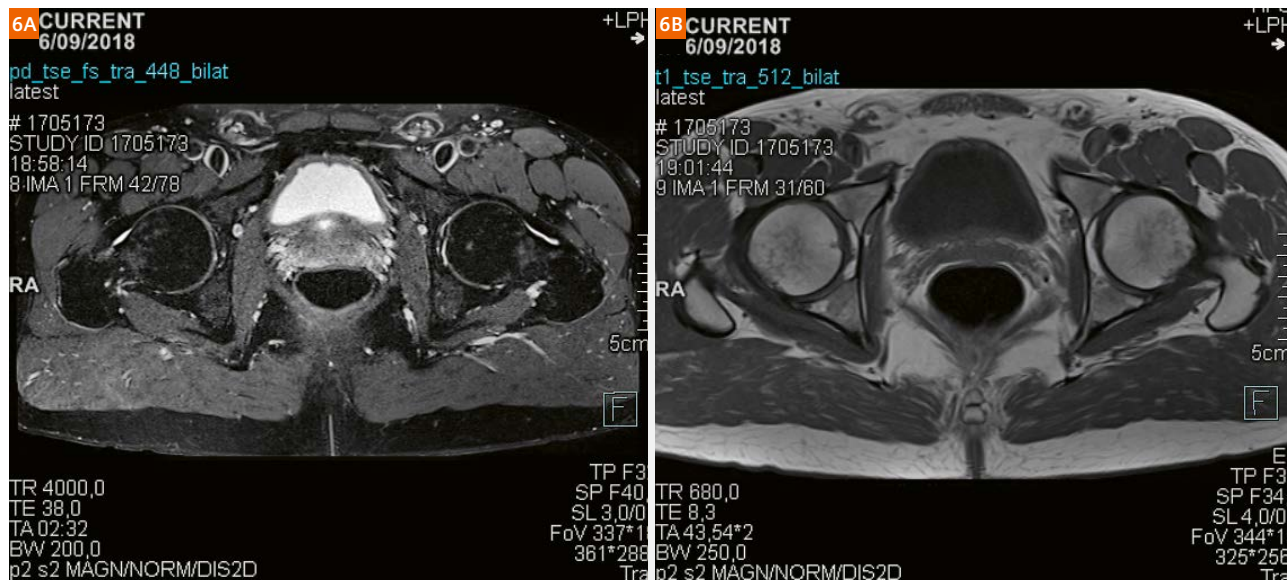


Figure 6:

Standard imaging of both hips: standard SMS PD fatsat 3 mm thick slices covers complete pelvis with 78 slices two and a half minutes and standard SMS T1 4 mm with 60 slices in one and a half minutes.

The combination of large coverage in the z-axis with thin axial slices can be especially challenging, e. g., scrutinizing the course of small peripheral nerves like the gluteal branches of the nervus cutaneus femoralis dorsalis, which is still considered to be a 3T indication. Thin-slice SMS with this convincing image quality in a reasonable time (4 minutes for 90 slices of 2 mm) improves the reputation of your facility by allowing you to say, "Of course we can because Sola is better than the 3T results we have seen in various studies." It takes some nerve, however MAGNETOM Sola and SMS thin slices allow you to perform these scans with confidence.

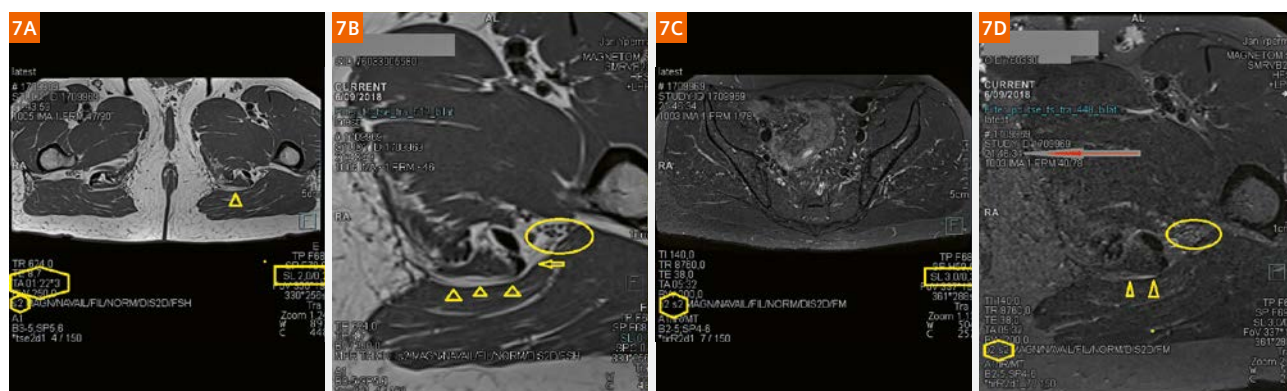


Figure 7:

SMS T1 TSE (7A, B): 2 mm slices, 90 slices in 4 minutes. SMS PD fatsat 3 mm slices thickness (7C, D). The images 7B and 7D are magnified. The yellow arrows point at the upper gluteal branch of the nervus cutaneus femoralis dorsalis dorsal to the semitendinosus, ventral to the gluteus maximus just caudal to tuber ischiadicum. Red arrow points to time in the evening. Sciatic nerve fascicles in yellow circle.

In the wrist, tendons run a long way. A great many thin slices are required to image them properly. SMS handles this task with ease and accuracy, in short acquisition times.

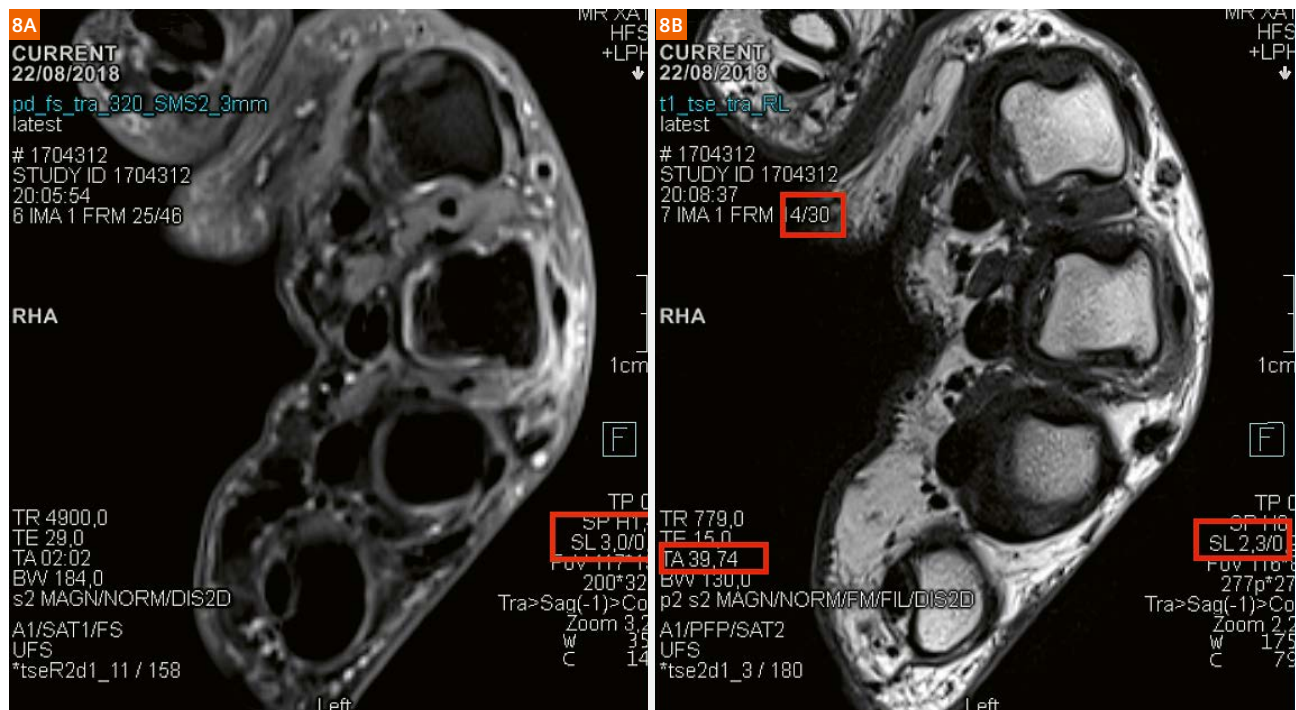


Figure 8:

Axial PD FS 46 slices 3 mm thick in 2 minutes, axial T1 TSE 30 slices 2.3 mm thick in 40 seconds. Ultra Flex Small 18-channel coil, imaged off center. SMS factor 2.

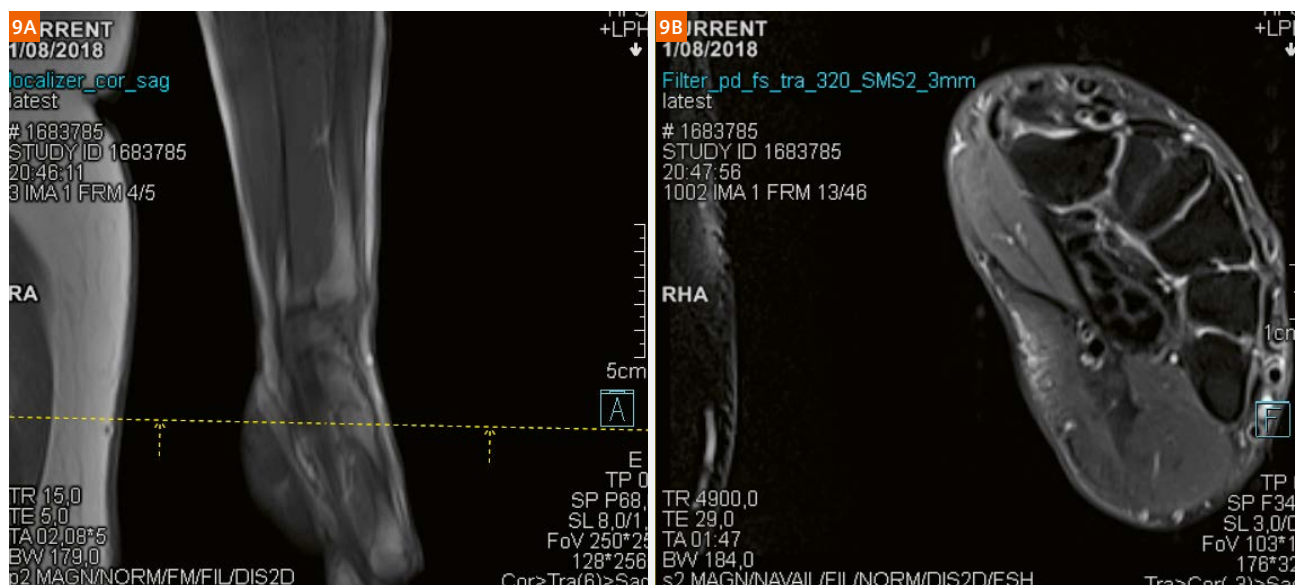
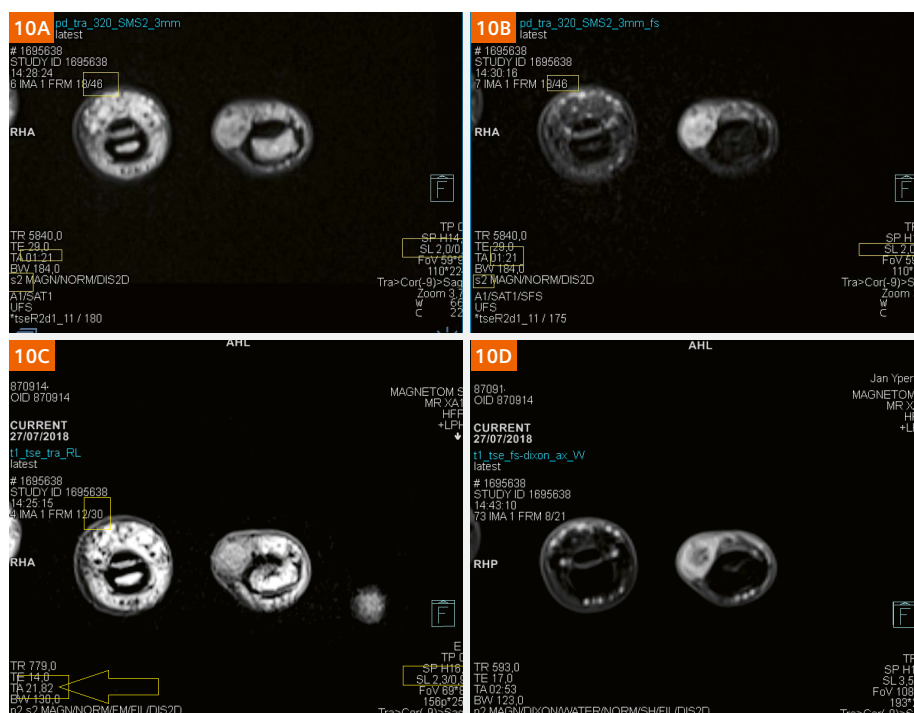


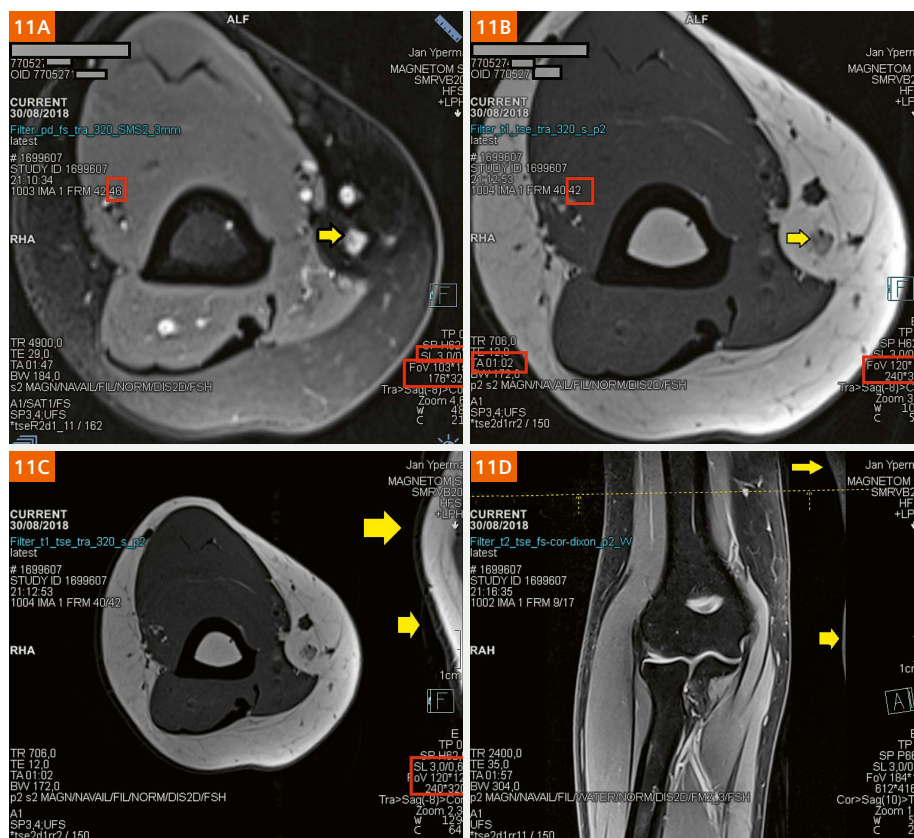
Figure 9:

The days of the superman position are over. Since we have had a MAGNETOM Sola, all wrist exams are done with the wrist comfortably resting next to the body, and the dedicated wrist coil is more often replaced by the comfortable Ultra Flex Small 18-channel coil.

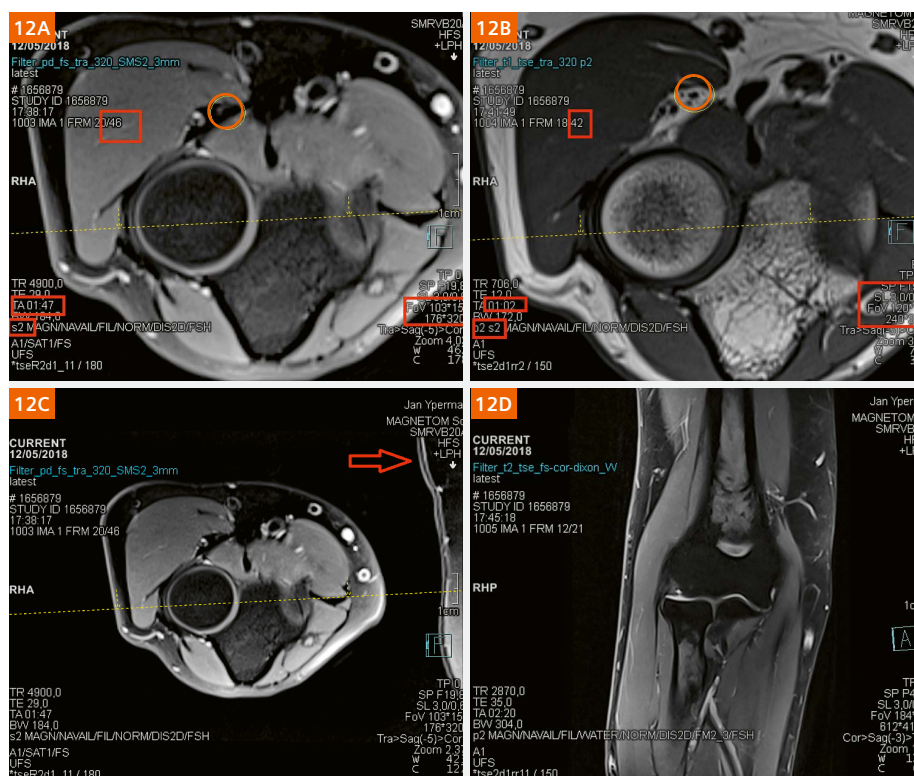
**Figure 10:**

A 30-year-old female patient presented with bluish discoloration and swelling of the radial side of the ring finger, pain, and acceleration in swelling for several weeks. T1 and Proton Density iso – slightly hyperintense, PD fat-sat hyperintense, peripheral fast-enhancing sharply demarcated subcutaneous mass with hypointense spots and hypoenhancing center. SMS makes it possible to have all these high resolution thin slices in an amazingly short acquisition time (notice 22 seconds for 30 slices T1 TSE 2.3 mm see 10C). Surgically confirmed partially thrombosed hemangioma). The T1 after contrast was done using Dixon fat-sat since this challenging environment contains more air than tissue. Again, all images are acquired with the Ultra Flex Small coil.

Just as in wrist imaging, elbow imaging is no longer done using the knee coil in superman position, but conveniently off center with the elbow lying comfortably next to the body. Superman no longer holds a position in our department, he just got fired.

**Figure 11:**

Elbow exam with the arm resting comfortably to the right of the abdomen (right flank indicated by large yellow arrows). SMS imaging T1 and PD fat-sat with thin slices 3 mm, high in-plane resolution (0.5 mm) and 42 T1 TSE slices in one minute and two seconds. Notice the high image quality allowing you to zoom in and pick up details like the hilum of a small lymph node (arrows in 11A, B).

**Figure 12:**

Our first elbow exam with the Ultra Flex Small coil; off center, arm resting comfortably to the right of the abdomen (right flank indicated by large red arrow). SMS imaging T1 and PD fatsat with thin slices 3 mm, high in-plane resolution (0.5 mm); acquisition of 42! T1 TSE slices in one minute and two seconds. Zoomed images in the upper row show detail such as annular ligament surrounding radial head or, for example, the course of the radial nerve (circle).

Learn more about Simultaneous Multi-Slice!

For more insights into this exciting new technology, designed for unprecedented speed in imaging to shorten patient's table time visit us at

www.siemens.com/magnetom-world

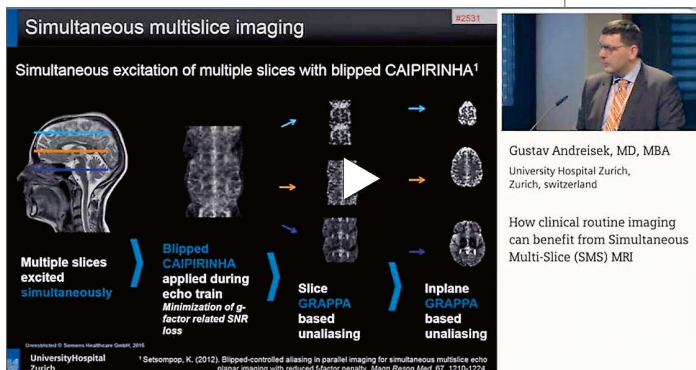
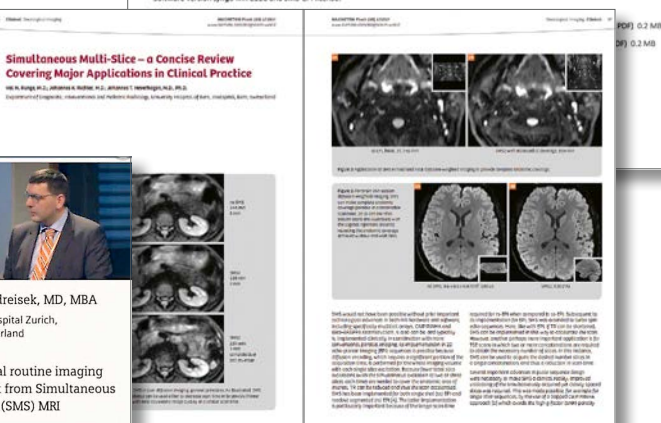
> Hot Topics > Simultaneous Multi-Slice

Here many scientists and clinicians worldwide share their insights, experiences and perspectives on this innovative new technology.

SMS-DWI Protocols

Simultaneous Multi-Slice DWI for Abdomen and Breast Protocols

Diffusion-weighted imaging (DWI) has great potential in body oncology; however, being a single-shot technology, the acquisition is relatively time consuming. Simultaneous Multi-Slice (SMS)-EPI deploys multiband pulses to excite multiple slices simultaneously. This excitation is combined with a blipped CAIPIRINHA approach during readout to reduce g-factor related SNR loss. As a result, an additional acquisition time reduction of up to 40% without compromising image quality compared to a standard GRAPE 2 can be achieved with SMS 2 in combination with GRAPE 2 in breast and abdominal scans. Protocols, .narr files and DICOM images for MAGNETOM Aera 1.5T and MAGNETOM Skyra 3T can be downloaded here. Prerequisite: Software version syngo MR E11C and SMS-EPI license.



GO protocols – consistent results in all joints

The new 18-channel Knee Coil is easy to handle, lightweight, and particularly comfortable for our patients. In the first four months of our experience with 1.5T MAGNETOM Sola to date, we have not yet had a single patient who did not fit in the knee coil. As shown in Figure 13, the patient is laying comfortably with her feet first leaving sufficient room in the knee coil and sufficient room for the other leg.

GOKnee3D, with the appealing concept of high resolution scanning at short examination times using SPACE 3D with CAIPIRINHA-based 4-fold acceleration, was introduced as early as 2017 by Jan Fritz, M.D., of Johns Hopkins University School of Medicine [1]. The GOKnee T2 FS comes out of the ‘Siemens sequences box’ at 0.8 mm isotropic. We enhanced that resolution to 0.6 isotropic proton density, which still provided us with more than enough signal. The new knee coil has improved patient comfort significantly, allowing patients to lie still. Based on prior experience, meniscal and

cartilage tear detection and characterization are highly facilitated by real 3D high resolution, while bone marrow edema is equally well depicted when compared to standard knee imaging.

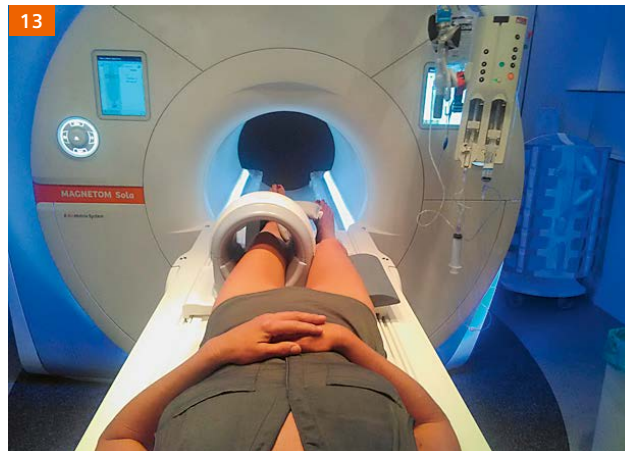

Figure 13:
Sufficient room in the 18-channel Knee Coil with 1.5T
MAGNETOM Sola.

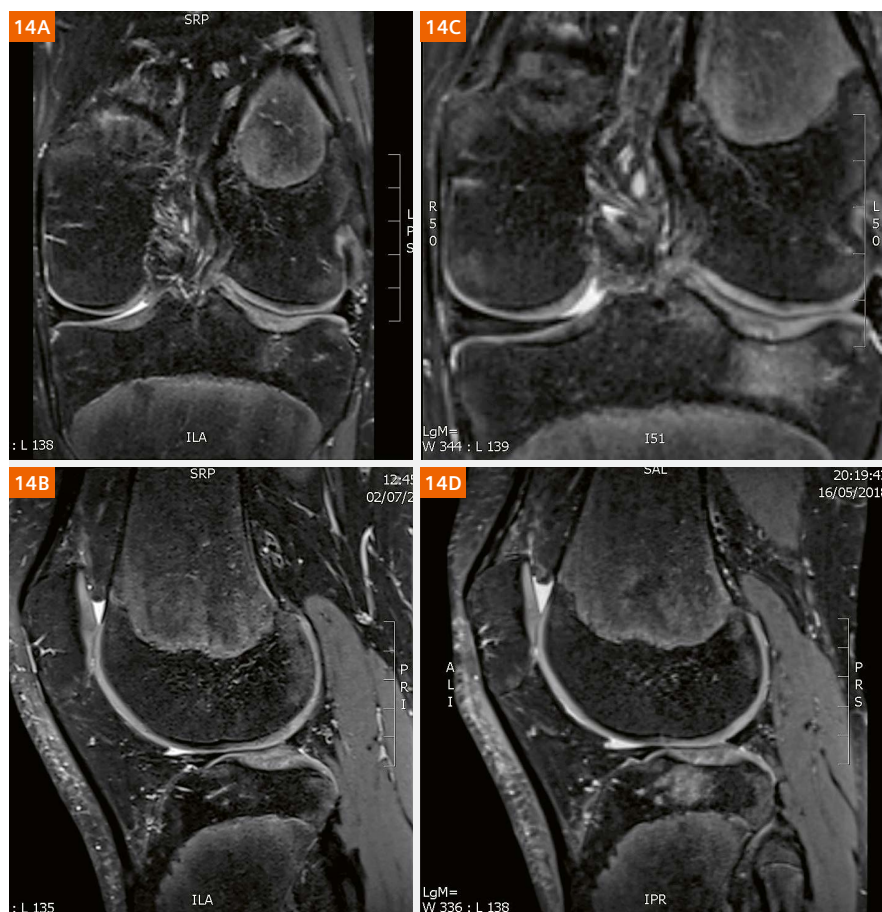
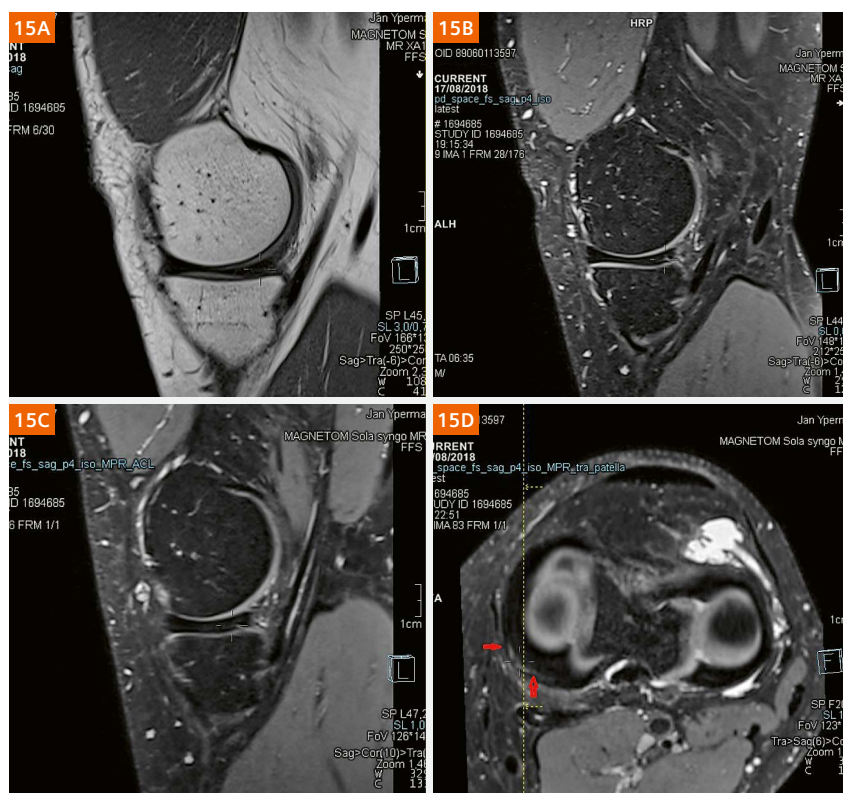


Figure 14:
In May 2016, the GOKnee sequence **(14C, D)** demonstrates subchondral stress fracture and chondral fracture with adjacent bone marrow edema. Marked healing on the follow-up exam in February 2017 **(14A, B)**. Increasing resolution from 0.8 **(14C, D)** to 0.6 isotropic **(14A, B)** sharpens the image a great deal; still there is sufficient signal even at this higher resolution. The acquisition time for this higher resolution of 0.6 isotropic has increased to 6 min. Adding 38 x 3 mm slices, sagittal SMS T1 TSE takes another 40 seconds and an axial GE another 38 seconds, which altogether with the localizer adds up to a table time of less than 10 minutes.

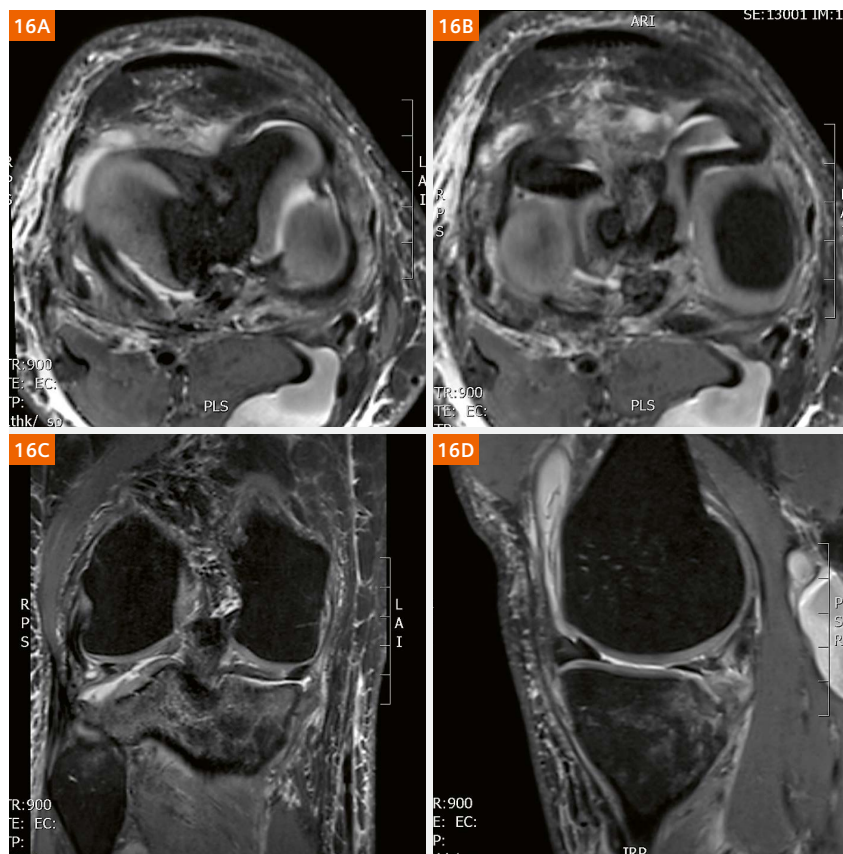
GOKnee3D Protocols

Fast high-res 3D knee exams in 10 min.
Download .exar1 files for 1.5 and 3T at
www.siemens.com/magnetom-world
> Clinical Corner > Protocols

**Figure 15:**

The axial reconstructions in the meniscal plane (15D) make it particularly easy to pick up small tears that were previously unrecognized, as is the case in this peripheral tear in the posterior horn medial meniscus (arrow) with hyperintense signal extending to the cartilage both on the native sagittal slice (15B) and 1 mm thick reconstruction (15C). GOKnee3D is excellent at depicting small details.

Though not all knee pathology is subtle.

**Figure 16:**

This patient endured a severe crash during a horse carriage race. GOKnee3D 0.6 isotropic reveals bilateral bucket handle meniscal tears, tibial plateau fracture, and torn cruciate ligaments. This resulted in hemarthrosis, ruptured capsule, and a Baker cyst. Bone marrow edema is easily depicted. Having a comfortable coil and comfortable position even in painful conditions is of real value and key to high image quality.

Seeing these consistent GOKnee3D results on MAGNETOM Sola makes it tempting to expand this concept further to the shoulder, ankle, wrist, hip, and elbow. This is how GOKnee performs on the elbow (same patient as in Figure 12).

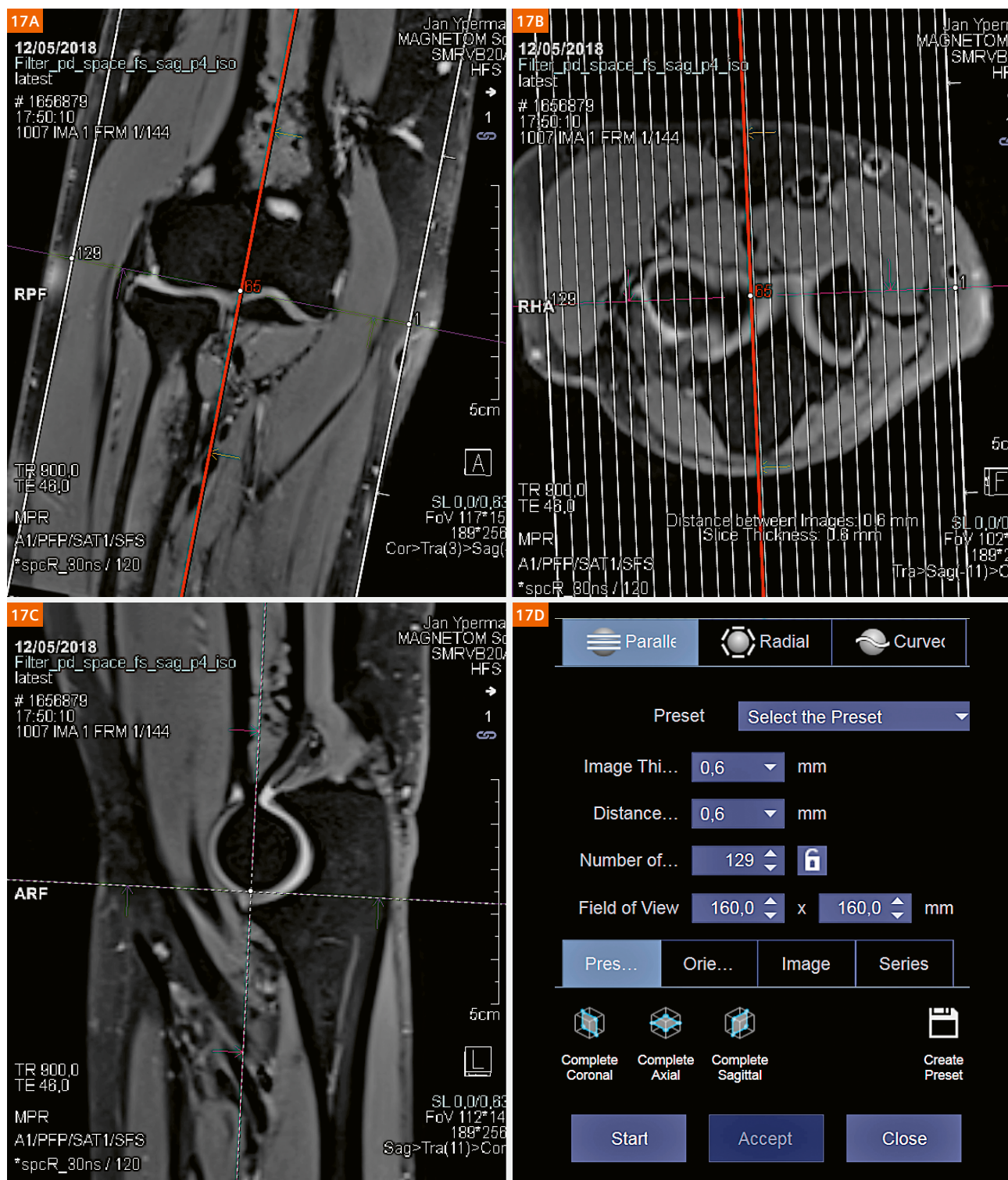


Figure 17:

Screenshot of our very first 'GOElbow'. 0.6 isotropic acquisition enables high resolution reconstructions at will.

Since that first 'GOElbow' (Figures 12 and 17), all of our elbow exams enjoy the high resolution that Space3D_caipi4 technique offers, in addition to the SMS axial acquisitions (except in the presence of metallic hardware¹, that is). Other joints were quick to follow. Here is an example of cartilage lesions in hip imaging using 'GOHip'.

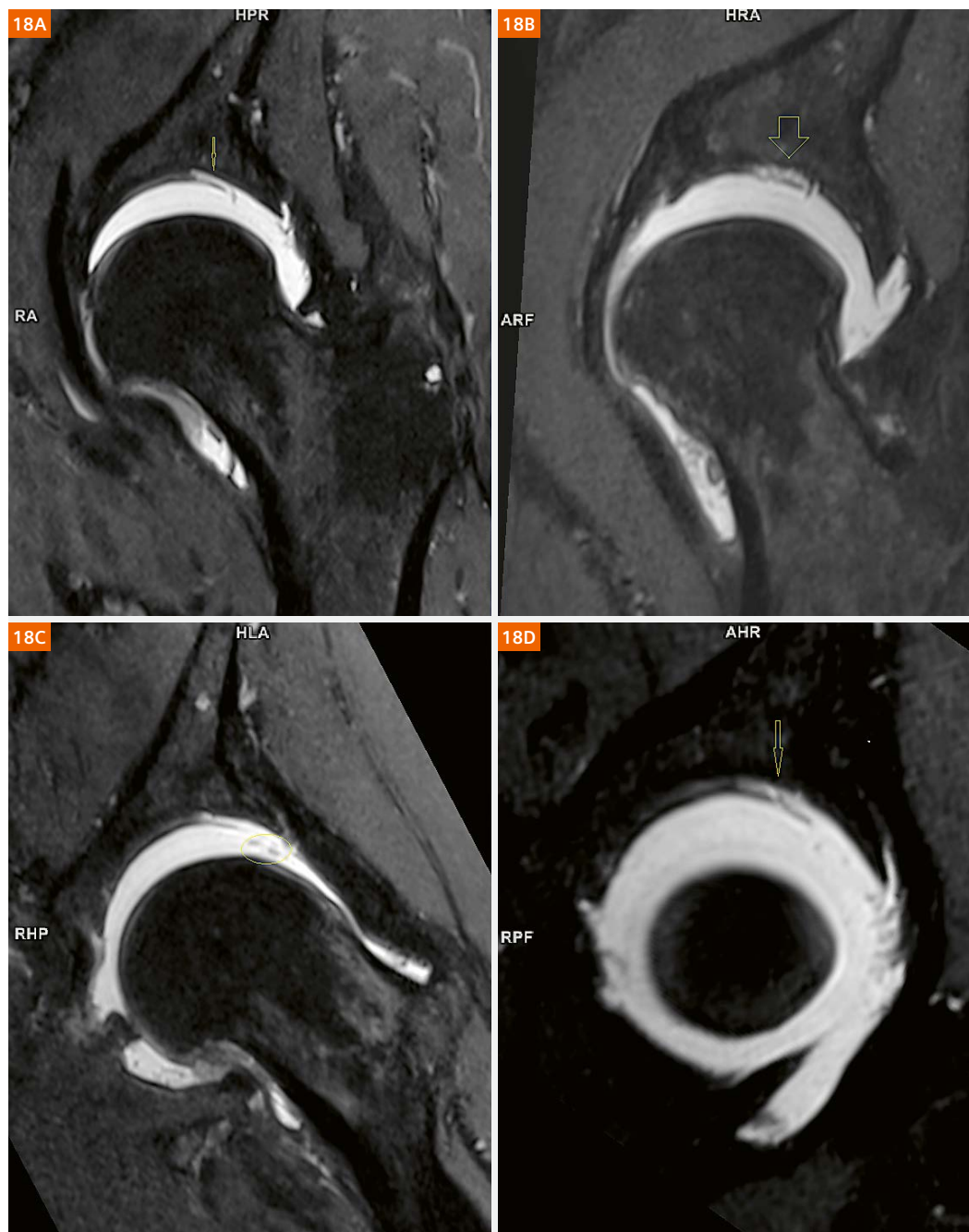


Figure 18: MR arthrogram hip exam (using skin traction), the Space3D_caipi4 sequence further enhanced up to 0.5 isotropic (5 min 41 acquisition time) with native slices (**18A**) and MPR reconstructions depicts cartilage delamination, denudation, and rice bodies in exquisite detail. To be consistent, we call this exam: 'GOHip'.

¹The MRI restrictions (if any) of the metal implant must be considered prior to patient undergoing MRI exam. MR imaging of patients with metallic implants brings specific risks. However, certain implants are approved by the governing regulatory bodies to be MR conditionally safe. For such implants, the previously mentioned warning may not be applicable. Please contact the implant manufacturer for the specific conditional information. The conditions for MR safety are the responsibility of the implant manufacturer, not of Siemens.

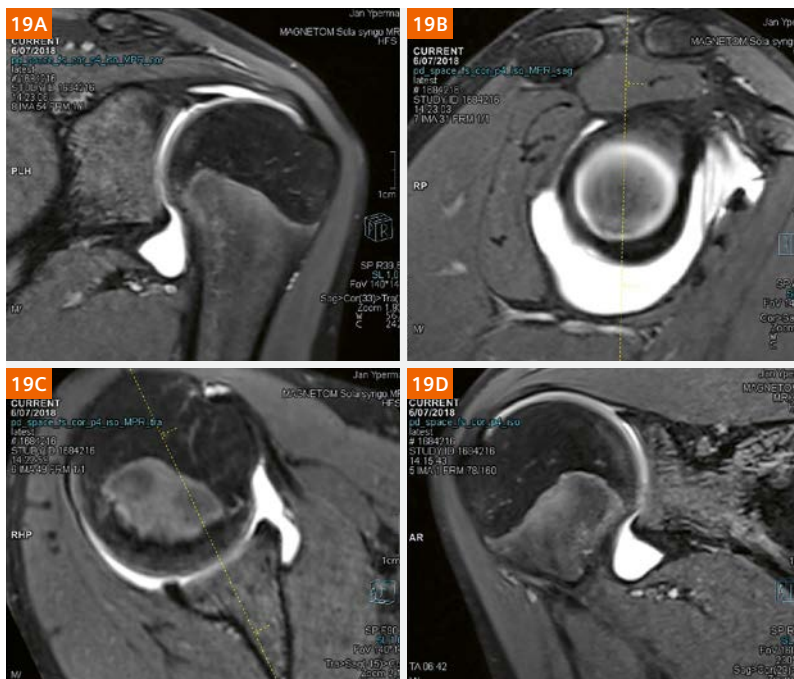


Figure 19: Normal MR arthrogram using Space3D_caipi4 technique, a.k.a., 'GOShoulder'. Coronal acquisition 0.5 mm isotropic resolution (19D) and three orthogonal thin slice MPR reconstructions. Exquisite cartilage delineation is shown.

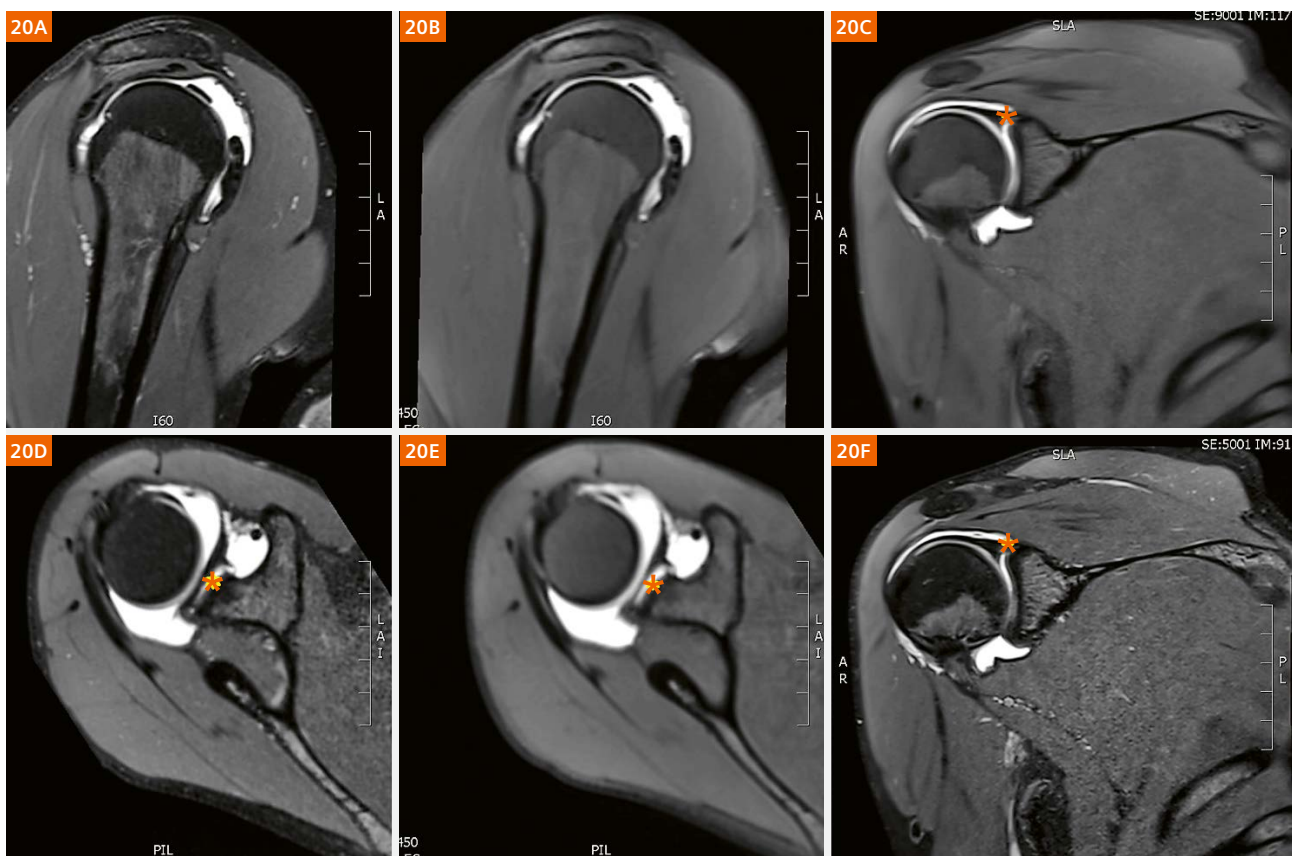


Figure 20:

Changing a few parameters in the Space3D_caipi4 results in a nice T1 CAIPIRINHA 4 SPACE acquisition, ideal for an arthrogram. This young basketball player had unexplained shoulder pain during and after the game. Slap II lesion (*) easily demonstrated in two 'GOShoulder' acquisitions after arthrogram: T1 fatsat and PD fatsat Space3D_caipi4 each with 0.5 mm isotropic resolution. Coronal acquisition (20C, F) with axial (20A, D) and sagittal MPR reconstructions (20A, D and 20B, E).

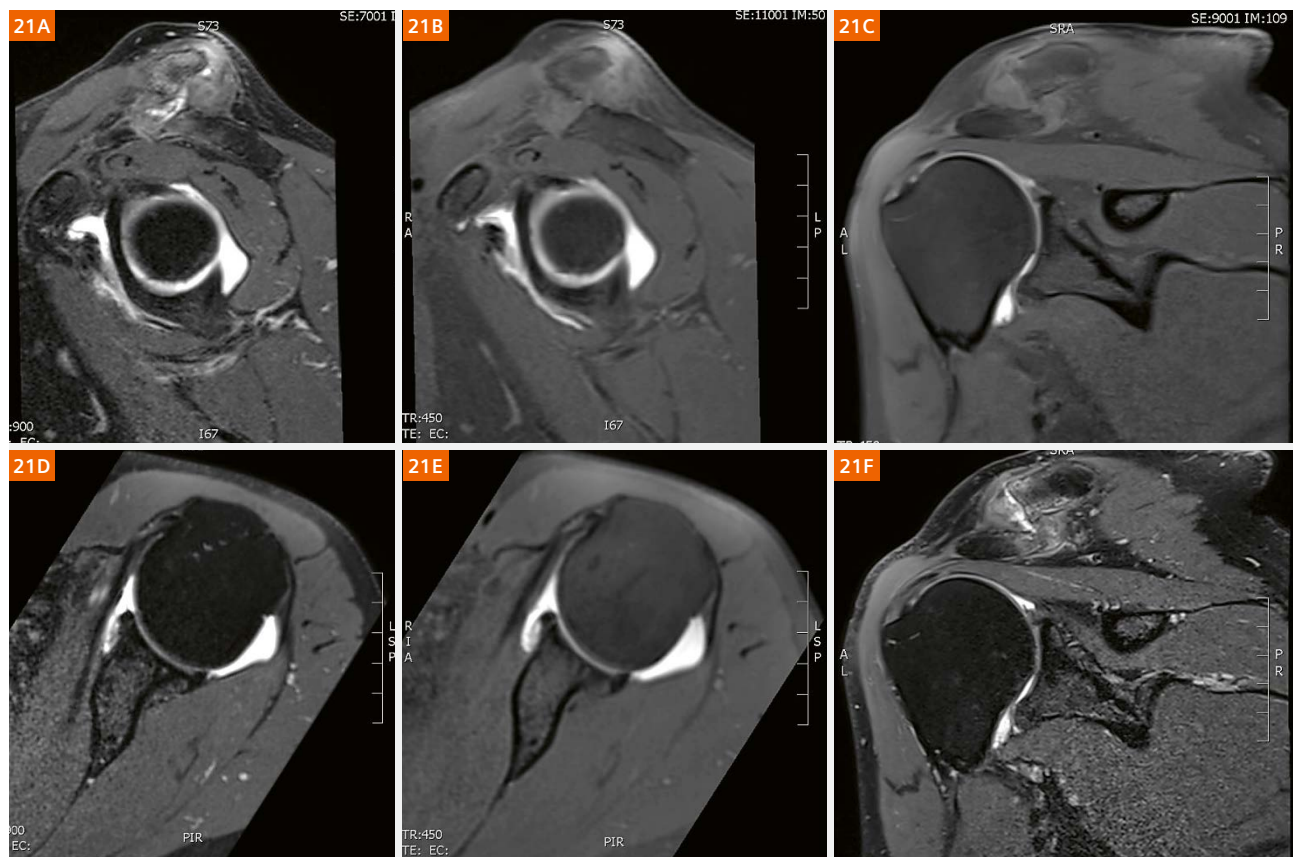


Figure 21:

Luxated AC joint degree III to determine if there was a concomitant labral lesion. Coronal acquisition after arthrogram with axial and sagittal reconstructions performed. The scan was quick, easy, and robust even in this patient in pain.

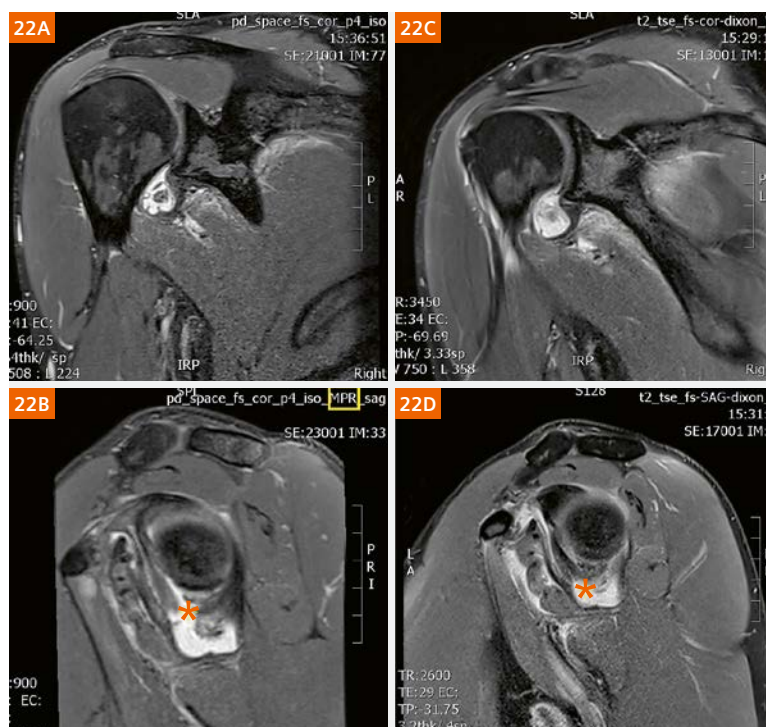

Figure 22:

Patient who fell while cycling and landed on outstretched hand. No arthrogram was performed since the exam was within a week of trauma.

'GOShoulder' PD Space3D_caipi_fatsat coronal acquisition 0.4 mm isotropic and sagittal 1 mm MPR (22A, B) and coronal and sagittal 3 mm Dixon fatsat PD (22C, D).

Thin slices of 'GOShoulder' demonstrate more accurately the bony avulsion (orange star) of the anterior pillar inferior glenohumeral ligament. Even with these thin slices, there is still sufficient signal as compared to the classic 3 mm slices.

In conclusion, for larger joints GO is going well with the “GO” meaning go-od. Things are going similarly well for smaller joints such as the ankle and wrist.

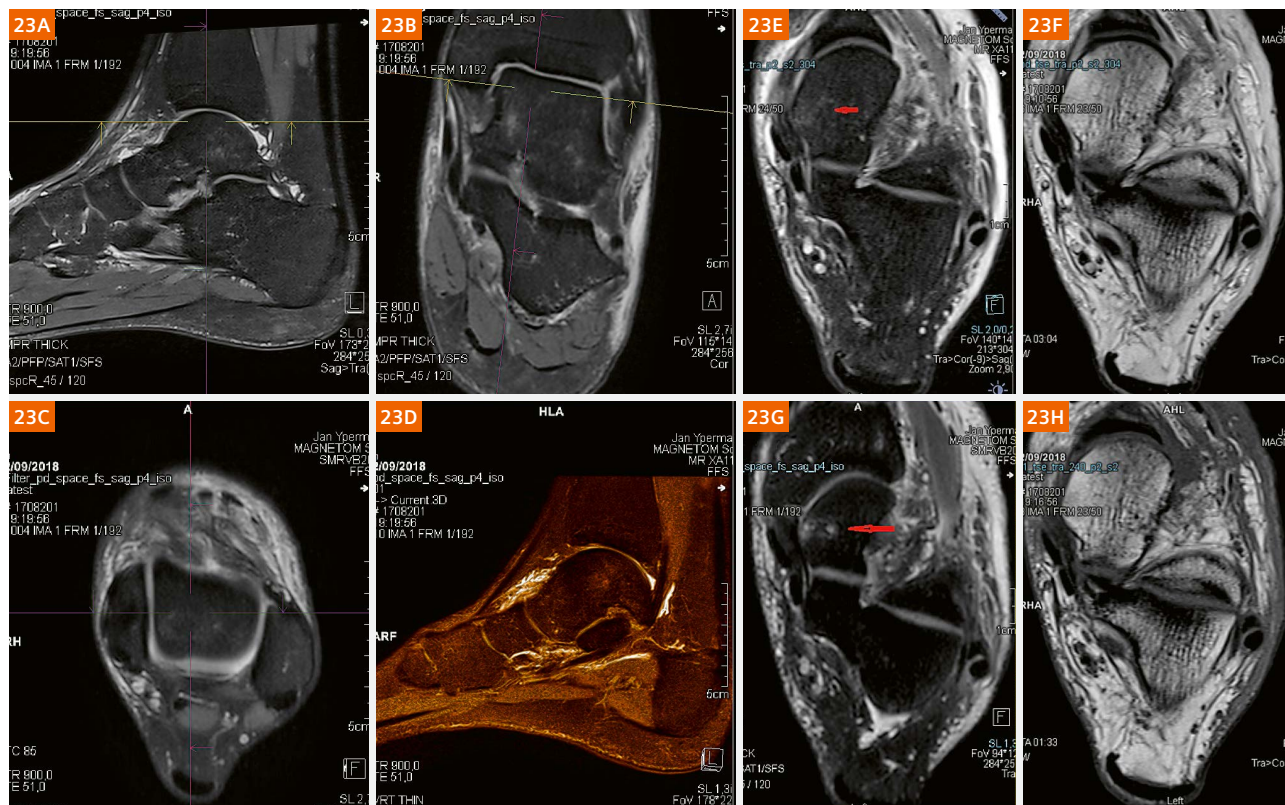


Figure 23: A basketball player presented with an ankle sprain. 3D isotropic imaging 0.5 mm. Overview in 3D left screenshot (23A–D). Right Screenshot (23E–H) shows axial MPR reconstruction (23G) together with 2D ax SMS PD FS (23E) and ax SMS PD (23F) and SMS T1 TSE (23H). MPR axial reconstruction ‘GOAnkle’ demonstrates bone edema (red arrow) actually even better than the 2D intermediate weighted FS. ‘GOAnkle’!

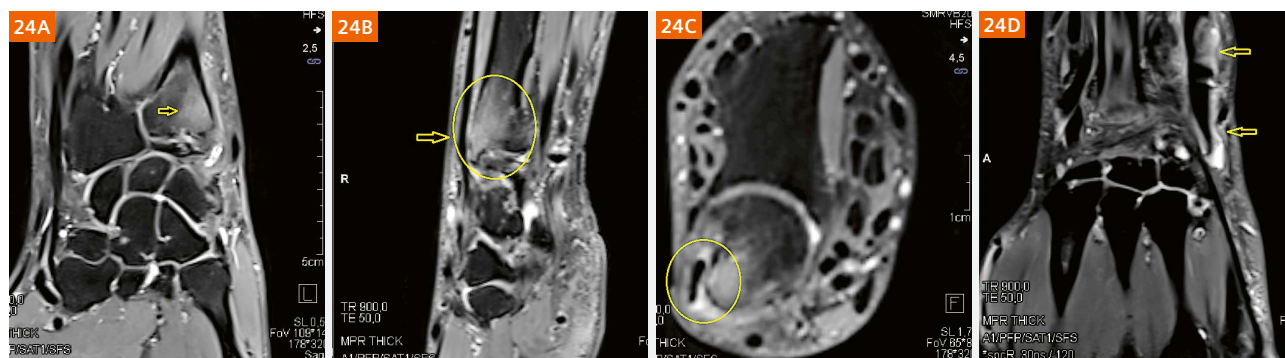


Figure 24: ‘GOWrist’ with 0.5 mm 3D isotropic acquisition (5 minutes acquisition time) and MPR reconstructions in 3 directions with bone edema (yellow circle and arrow, 24A and B) distal ulna and styloid process and friction tenosynovitis (yellow circle and arrow, 24C and D) extensor carpi ulnaris tendon. Scan provides exquisite detail in sagittal and coronal planes with this 0.5 isotropic resolution. Even the axial MPR is diagnostic.

In conclusion: MAGNETOM Sola, SMS TSE, and 3D SPACE CAIPIRINHA 4 make a formidable team. The MAGNETOM Sola platform does indeed play an important role in the background with stable homogeneity of the magnetic field, stable RF pulses, and abundant gradient power to run rather than walk through *k*-space and, finally, high density coils to start with. Indeed, the success of ‘GO-PickYourJoint’ as well as the success of SMS TSE is highly dependent on the signal we get from the 18-channel Knee Coil, UltraFlex Small and Large, and even Body 30.

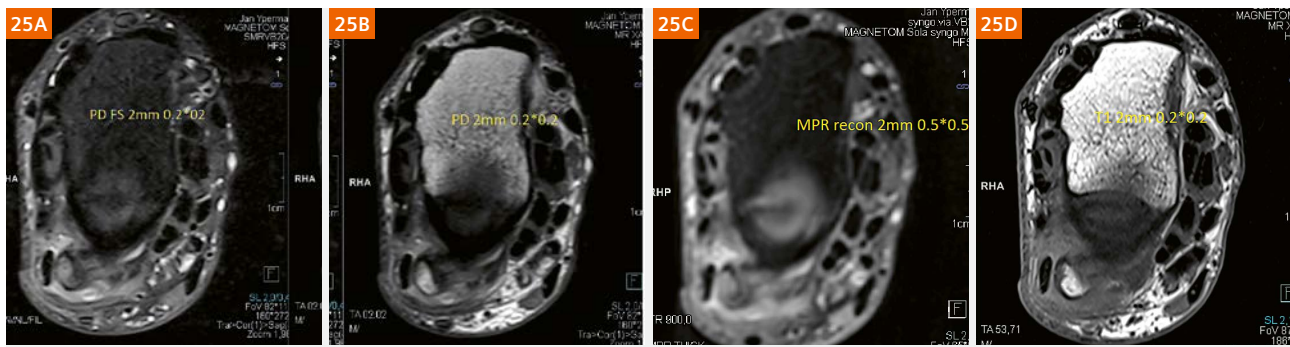


Figure 25: When comparing the axial MPR reconstruction 2 mm thickness and 0.5 inplane resolution, to the high resolution PD and T1 images, there is a clear difference in the inplane resolution, still the tenosynovitis and the bone edema are easy to interpret but thin slice high resolution axial images using SMS is clearly the winner here. Check acquisition time T1 (25D): 54 seconds for 30 slices 2 mm “thick” 0.2 inplane resolution.

To prove the force of MAGNETOM Sola you need only take a look at the hips. The first hip exams caught my eye immediately. The signal is there in the cartilage.

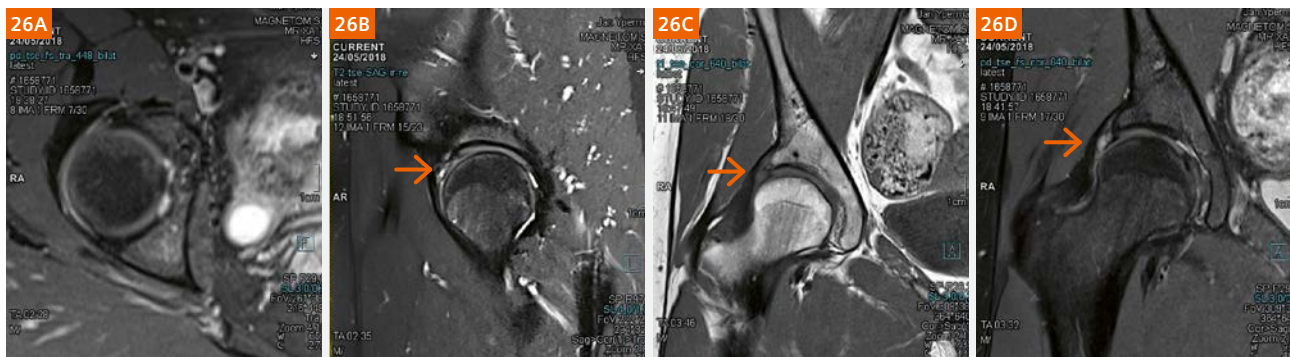


Figure 26: Right side hip pain in a 28-year-old female patient. Axial and coronal intermediate-weighted fatsat 3 mm slices, coronal T1 3 mm slices and 4 mm sagittal SPAIR fatsat revealing labral tear and cyst. The signal in the cartilage looks like what one might expect from a 3T system. Remember, these images are zoomed in and still this detail is present due to the 640 matrix, FOV 309 x 389.

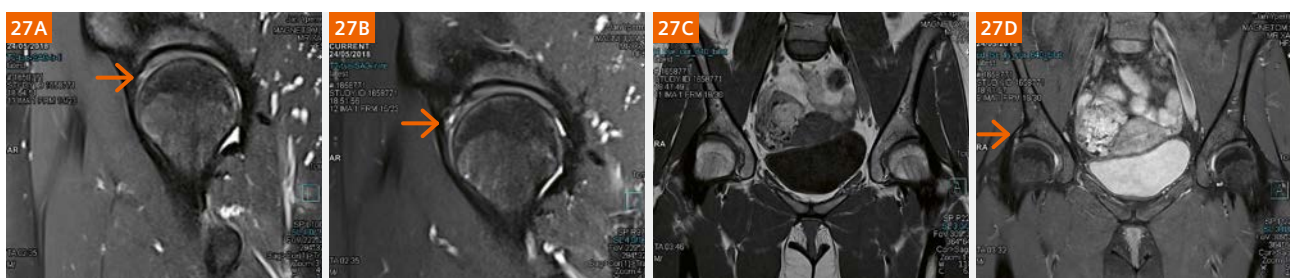


Figure 27: Same patient as in Figure 26. Coronal intermediate-weighted fatsat and T1 TSE 3 mm slices and 4 mm sagittal SPAIR fatsat revealing labral tear and cyst on right side and cartilage tears left side.

Contact

Johan Dehem, M.D.
Jan Yperman Ziekenhuis
Briekestraat 12
8900 Ypres
Belgium
Phone: +32 57 35 74 00
johan.dehem@yperman.net



Reference

- 1 Kalia V, Fritz B, Johnson R, Gilson WD, Raithel E, Fritz J. CAIPIRINHA accelerated SPACE enables 10-min isotropic 3D TSE MRI of the ankle for optimized visualization of curved and oblique ligaments and tendons. Eur Radiol. 2017 Sep;27(9):3652-3661.