

Adding Value in CMRI with MAGNETOM Sola's BioMatrix Technology

Johan Dehem, M.D.

VZW Jan Yperman, Ypres, Belgium

Grasping the anatomy and physiology of moving organs to capture dynamic contrast enhancement during free breathing is an excellent example of the added value of compressed sensing. Another great illustration of how compressed sensing brings new value can be found in cardiac imaging.

The value of this technology can also be found in terms of patient comfort. Scanning the left ventricle short axis with standard segmented TrueFISP Cine entails the patient holding their breath ten times. Using Compressed Sensing Cardiac Cine TrueFISP in high resolution, the same short axis scan only takes two breath-holds. Furthermore, table time for a standard scan, for example

for ischemic heart disease, drops from more than 30 to less than 20 minutes due to this drastic reduction in breath-holds, which also results in increased patient comfort. As it is possible to scan five slices in the same breath-hold, we scan significantly more long axis views than before giving my referring cardiologists all the cines they love so much. Adding value in diagnostic confidence!

It is possible to achieve consistent, good results even in patients who don't necessarily follow a healthy diet (Fig. 1). BioMatrix Technology and high-density coils ensure the signal, while Compressed Sensing enables short breath-holds or, even better, free breathing acquisition, which was previously not possible.

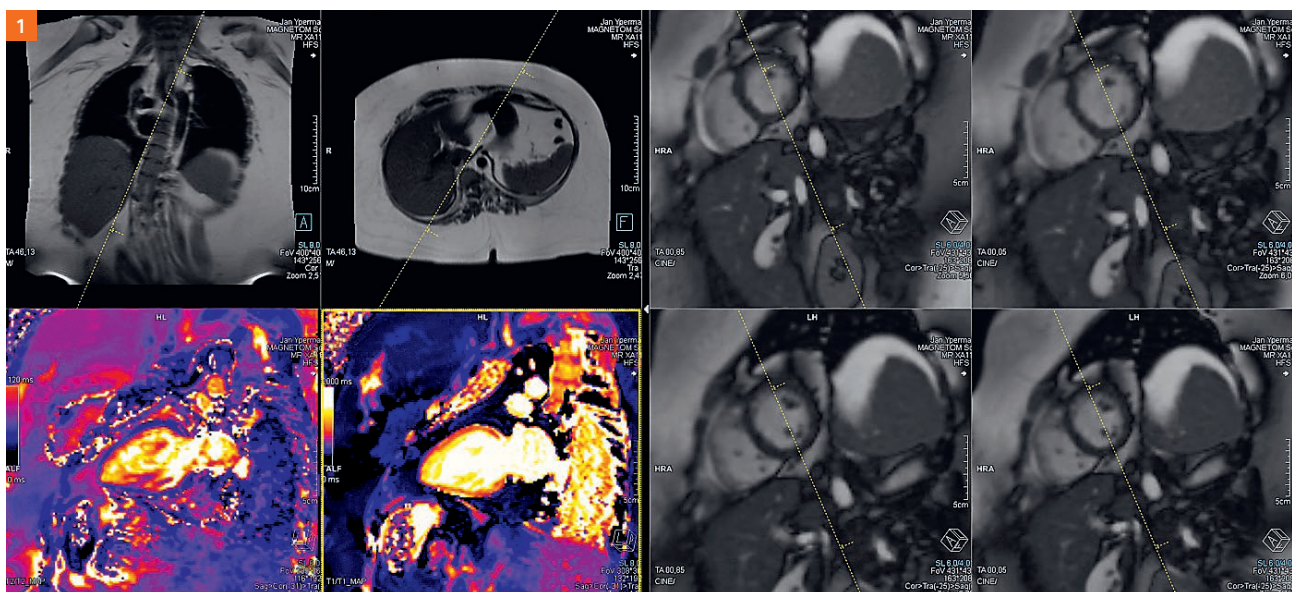


Figure 1:

This very obese patient has atypical retrosternal pain. Transthoracic ultrasound of the heart was considered “non-diagnostic” because of the obesity. The large bore of MAGNETOM Sola is indispensable to accommodating this patient, as you can see in the left part of the image. The right part of the image shows free-breathing real-time Compressed Sensing Cardiac Cine with adaptive triggering. Acquisition time per slice varies (depending on the adaptive triggering) between 0.05 and 0.85 seconds.

Even in patients who cannot hold their breath at all, and in patients with severe arrhythmia, this adaptive triggering variant effectively eliminates all motion artifacts. Real-time cardiac imaging has finally achieved long-sought quality and robustness with high spatial and temporal resolution. Referring physicians quickly learned that cardiac MRI in patients with severe dyspnea or very low ejection fraction, for example, is also feasible. Since many of these patients are bedridden, access to scans is fortunately facilitated by the BioMatrix Dockable Table with e-drive.

Compressed Sensing Cardiac Cine really is a no-brainer: Patients prefer it, referring cardiologists prefer it, and very ill patients have easy access to cardiac MRI – a clearcut winner! In addition, MAGNETOM Sola has other cardiac tricks up its sleeve: PSIR HeartFreeze, the latest advancement, delivers delayed enhancement images acquired in free breathing in crisp and clear high resolution. There was previously an option for high resolution delayed enhancement; it required, however, a breath-hold for every slice, which took too long for sick patients. The high-end motion correction algorithm of PSIR HeartFreeze eliminates this problem.

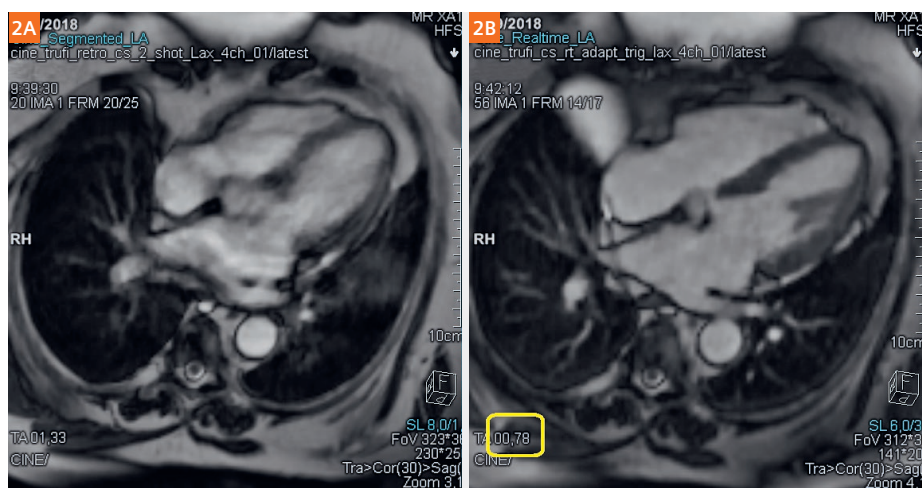


Figure 2:

This patient was simply too nervous to cooperate (2A) when running the standard retrograded Compressed Sensing Cardiac Cine TrueFISP. Changing gears to Compressed Sensing Cardiac Cine TrueFISP with adaptive triggering (2B) is a simple, yet effective tool to eliminate breathing and arrhythmia artifacts. Time of acquisition for the 4-chamber-view with adaptive triggering: 0.78 seconds (yellow box).

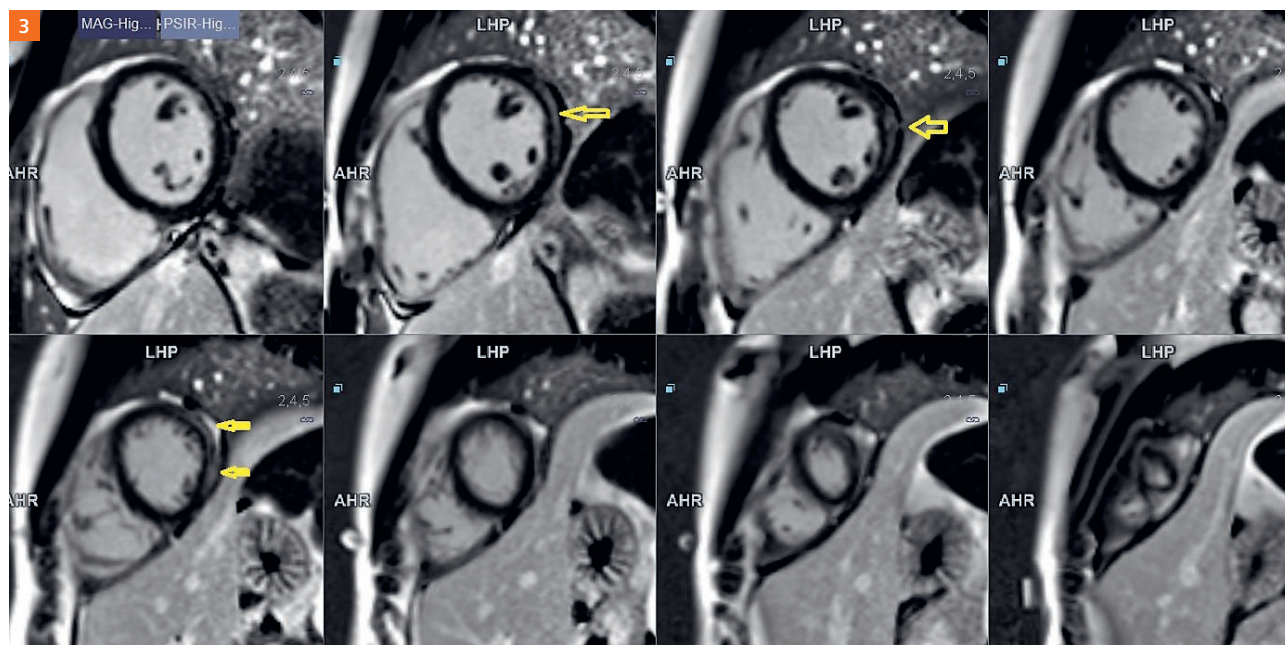


Figure 3:

Myocarditis. Typical epicardial delayed enhancement. Although early on admission, high quality PSIR HeartFreeze reveals the diseased myocardium during free breathing. The high quality also makes it easy to delineate and, therefore, quantify the scar burden as seen in Figure 4.

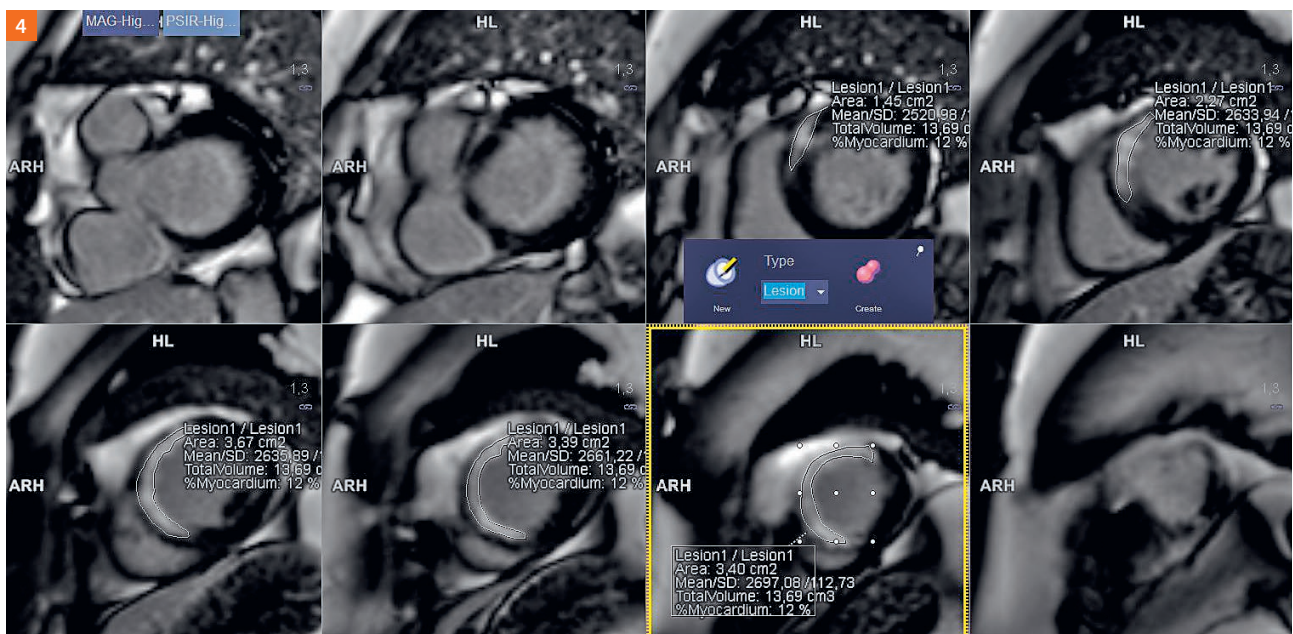


Figure 4:

Delayed enhancement on PSIR HeartFreeze. Finally, it is easy to delineate the extension of the LAD infarction and calculate a volume of 14 cm³ corresponding to 12% myocardial infarction.

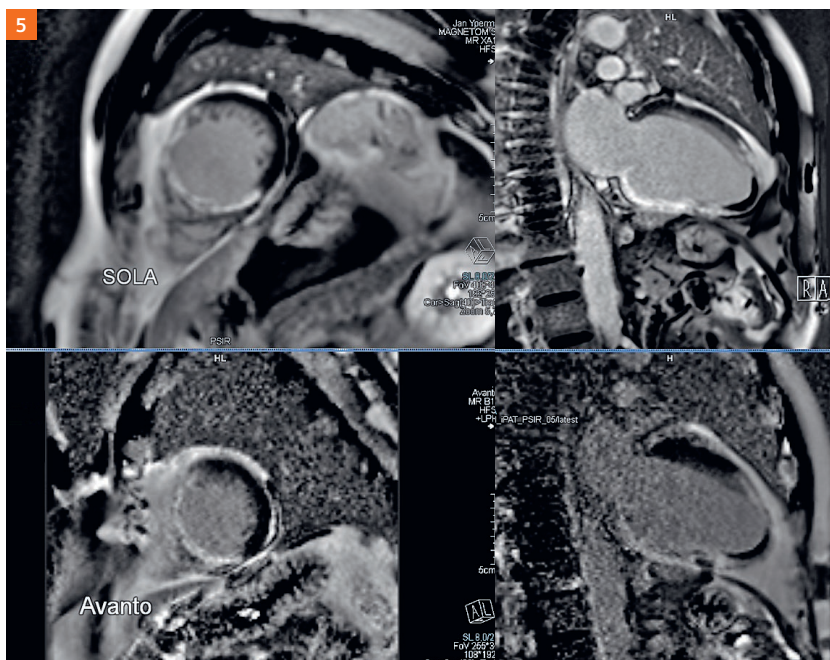


Figure 5:

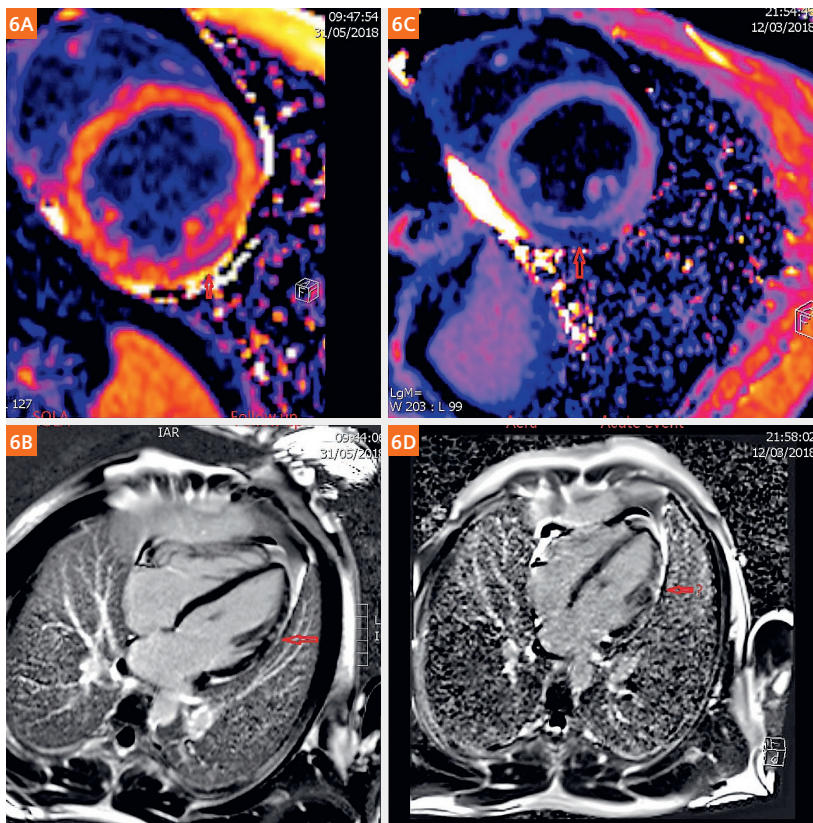
Non-cooperative patient, history of abuse, admitted after resuscitation and STEMI infarction. Acute phase: on MAGNETOM Avanto, breath-hold PSIR TrueFISP, sax and 2-chamber-view (lower row) with respiration artifacts.

Follow-up exam on MAGNETOM Sola (top row) with PSIR HeartFreeze accurately delineates large scar burden with no-reflow phenomenon.

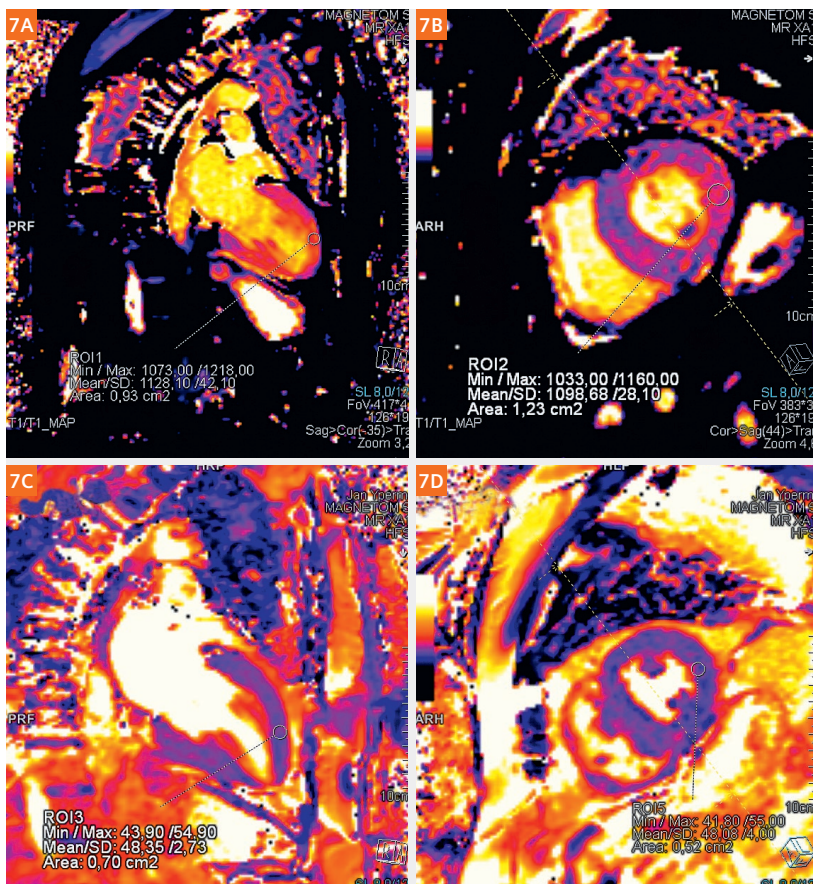
Comparing classic delayed enhancement imaging with PSIR HeartFreeze says it all! Before PSIR HeartFreeze, multiple breath-holds were required in sick patients as shown in Figure 5.

While comparing recent exams with older exams it is striking to see how MAGNETOM Sola improves detection and reading of cardiac lesions. Just like in the case of this follow-up exam for myocarditis (Fig. 6).

Cardiac amyloidosis used to be a difficult diagnosis, especially since amyloidosis has such a dramatic impact on the heart function and, hence, on the condition and cooperation of your patient. The ability to scan during free breathing brought to scanning cardiac amyloidosis the convenience we had always hoped for.

**Figure 6:**

Myocarditis acute phase T1 mapping with MyoMaps and delayed enhancement imaging on MAGNETOM Aera (**6C, D**) Myocarditis follow-up T1 mapping with MyoMaps and PSIR HeartFreeze acquired on MAGNETOM Sola (**6A, B**). Conspicuity of the lesions on MAGNETOM Sola is dramatically improved despite pronounced regression of lesions (T1 map post-gadolinium, **6C**, red arrows).

**Figure 7:**

82-year-old male with severe shortness of breath. T1 native (T1 mapping with MyoMaps) is increased up to 1128 (**7A**) while T2 value (T2 mapping with MyoMaps) is normal, not increased (**7C**). Classic finding for cardiac amyloidosis.

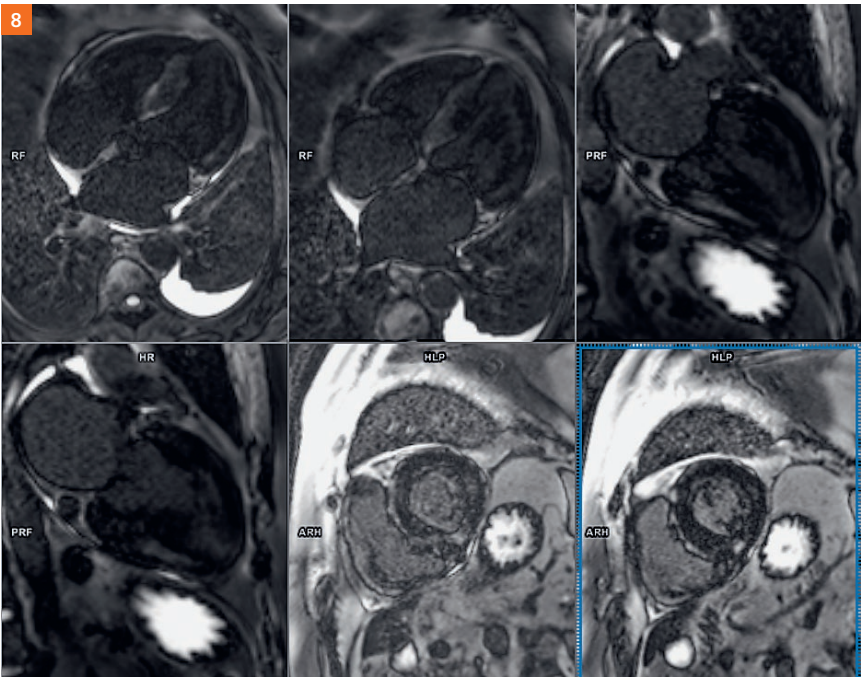


Figure 8: Classic, long known finding in a case of cardiac amyloidosis: Diffuse infiltrated myocardium, hard to “null” on the delayed enhancement. PSIR HeartFreeze free breathing acquisition at least provides images without motion artifacts. Please note that this patient is in very poor health and has an ejection fraction of 16.78%! See Figure 9.

Finally, all of this high-end cardiac imaging is neatly packaged in the Cardiac Dot Engine, which is easy to handle even for my junior technologist who just started last month. Although automatic planning of cardiac views may seem boring to some operators, seeing errors often dramatically reduced and interoperator results becoming way more consistent eliminates any potential doubt. Also, it allows the operator time to give their full attention to the patient.

	Absolute values	BSA normalized values
Ejection fraction	16%	
End diastolic volume	162.04 mL	74.41 mL/m ²
End systolic volume	135.92 mL	62.41 mL/m ²
Stroke volume	26.12 mL	11.99 mL/m ²
Cardiac output	2.98 l/min	1.37 l/min/m ²
Wall mass (mean)	234.52 g	107.69 g/m ²

Table 1: Left ventricle functional parameters.

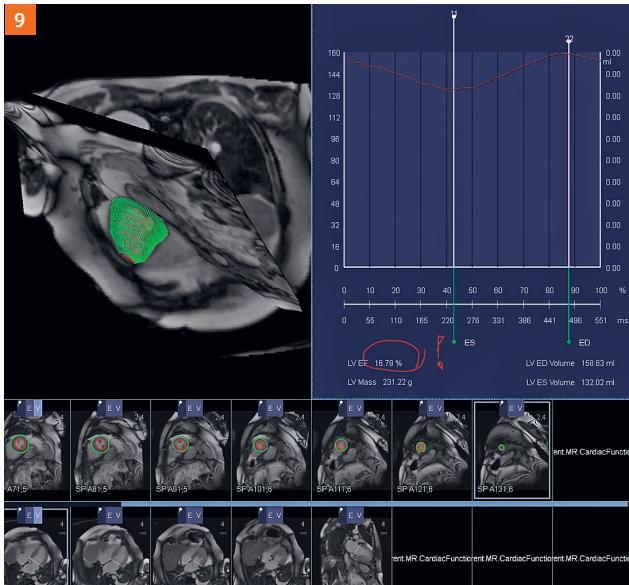


Figure 9: Also classic indication of cardiac amyloidosis, the severe wall thickening and more than severe impact on heart function (Table 1).

Contact

Johan Dehem, M.D.
Jan Yperman Ziekenhuis
Briekestraat 12
8900 Ypres
Belgium
Phone: +32 57 35 74 00
johan.dehem@yperman.net



