

Post Treatment MR of Prostate Cancer

Christopher R. Lunt, MB ChB, FRCR; David J. Ferguson, MB BCH BAO FFR (RCSI), FRCPC;
Silvia D. Chang, MD, FRCPC, FSAR

Vancouver General Hospital and BC Cancer, Vancouver, BC, Canada

Multiparametric MRI has in recent years become the imaging method of choice in the investigation of prostate cancer, for detection, decision making regarding targeted biopsy, and to provide information for local staging. MR is also used in the follow up of patients on active surveillance and in those who have undergone treatment of their cancer in the setting of suspected recurrence.

Recurrence of prostate cancer following treatment is most often detected following a rise in serum prostate specific antigen (PSA) levels. How this biochemical recurrence (BR) is defined depends on the modality of treatment; with two consecutive serum PSA concentrations of > 0.2 ng/mL considered to represent BR in patients who have undergone radical prostatectomy (RP), and PSA > 2 ng/mL above the initial nadir value in patients treated with radiotherapy considered to represent recurrence [1].

No consensus values have been established for the newer focal therapies such as cryotherapy or high intensity focused ultrasound (HIFU).

Biochemical recurrence is reported to occur in 27–53% of men treated with curative intent. Between 16–35% of treated men will be given second line therapy, however the interval between initial BR and the need to begin treatment can often be measured in years [2].

Nonetheless local recurrence is associated with an increased risk of metastatic disease, and in patients with

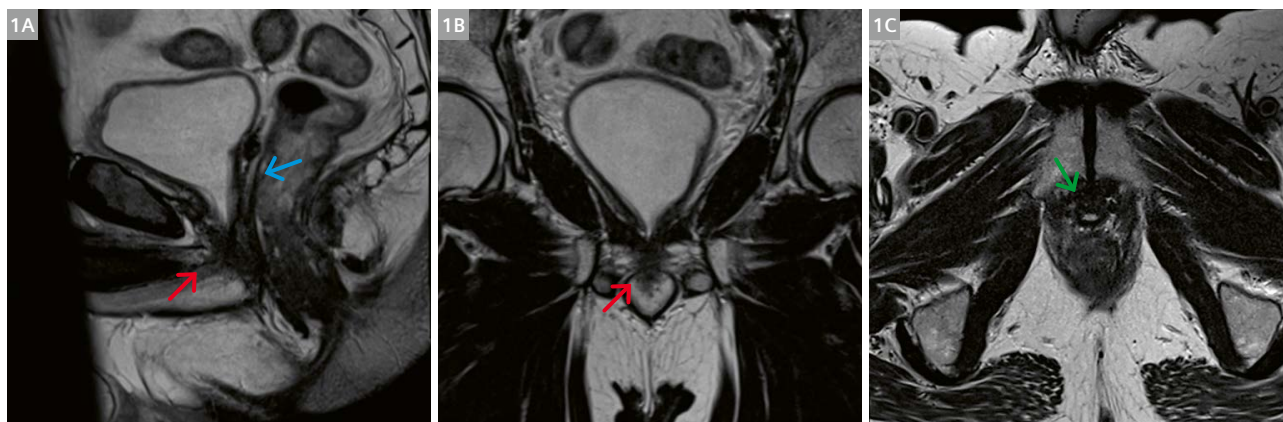
local recurrence who are not treated the mean time to detection of distant metastases is 3 years.

Absolute reliance on PSA in the monitoring of treated patients can be unreliable as very poorly differentiated tumors may not produce PSA and this lack of PSA production may be present in the tumor at the time of diagnosis or may occur due to novel mutation in metastatic tumor clone cells later during the period of surveillance.

Therefore patients presenting with symptoms attributable to recurrence such as bone pain or symptoms of a pelvic mass or retroperitoneal nodal enlargement should be investigated even in the absence of a serum PSA rise [3].

Initial investigation of men with biochemical recurrence should attempt to establish if the tumor is localized to the residual prostate gland or within the surgical bed in which case radical salvage therapy could be considered, or if distant metastases are present in which case salvage therapy, with its significant associated comorbidity should be avoided in favor of systemic treatment, the timing and method being guided by the location and extent of disease.

Standard assessment for distant metastases in cases of biochemical recurrence in our institutions currently comprises of CT abdomen to assess for lymph node recurrence and MDP bone scan. In cases where the location of



1 Orthogonal T2 sagittal (1A), coronal (1B), and axial (1C) small FOV images demonstrating normal MR appearances following radical prostatectomy. The prostate and seminal vesicles are absent and the bladder neck is pulled down to the proximal urethra (red arrows). Uniform low signal scarring is seen at the site of the seminal vesicles (blue arrow). Uniform low signal is seen at the anastomosis, similar to the bladder wall (green arrow).

recurrence is not characterized, a prostate specific membrane antigen (PSMA) PET-CT is currently being trialed.

MR of the prostate or prostate bed in post treatment patients is performed using a standard MR prostate protocol utilizing orthogonal small field of view (FOV) T2, axial diffusion-weighted imaging (DWI), axial wide FOV T1, and dynamic gadolinium enhanced sequences. The latter being crucial to accurate detection in some patients.

Assessment following radical prostatectomy

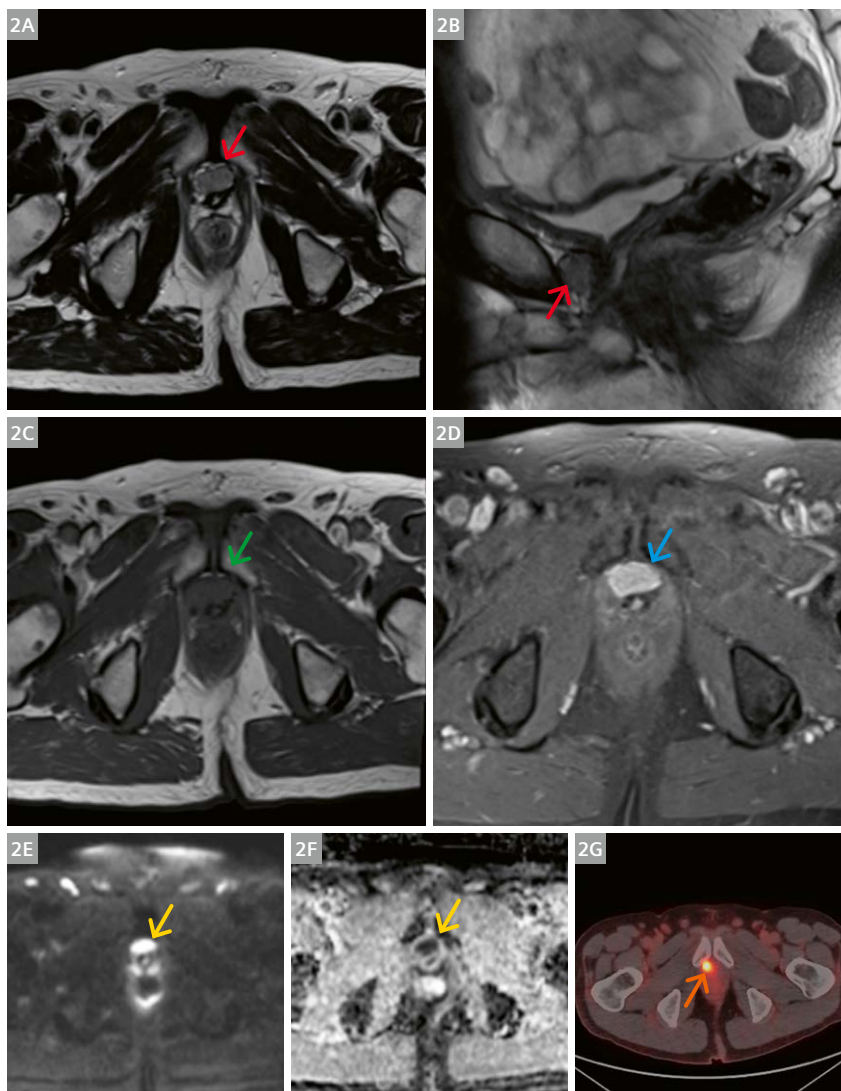
Surgical removal of the entire prostate gland necessitates the formation of a urethrovesical anastomosis and usually includes removal of the seminal vesicles [4]. Pelvic lymphadenectomy may also be performed at the surgeon's discretion depending on the stage and grade of the tumor as assessed by digital rectal examination, imaging and biopsy histology. Patients with high or intermediate risk disease will usually undergo lymph node dissection,

however in low risk disease the need for lymphadenectomy is controversial.

Minimally invasive prostatectomy is now the most commonly employed surgical technique with or without robotic assistance [5]. This may include nerve sparing in suitable patients in an attempt to preserve sexual function.

Following prostatectomy the serum PSA level is expected to fall to < 0.2 ng/mL, in the event this does not occur, residual local disease or occult distant metastases should be suspected.

Normal MR appearances following RP show the bladder neck pulled down to form an inverted conical shape and the vesico-urethral anastomosis which should appear uniformly low signal on the T2 sequences due to the presence of fibrotic tissue. There should be no or minimal evidence of diffusion restriction around the anastomosis, and no early contrast enhancement, however delayed uniform enhancement of the fibrotic tissue is normal (Fig. 1).



2 (2A, B) T2 axial and sagittal images demonstrating recurrence anterior to the anastomosis following radical prostatectomy seen as intermediate signal tumor (red arrows). (2C) T1 sequence, tumor is isointense to skeletal muscle (green arrow). (2D) Tumor shows avid enhancement following gadolinium contrast administration (blue arrow). (2E, F) Tumor shows restricted diffusion with low signal on ADC sequence (yellow arrows). (2G) PSMA PET-CT shows isotope uptake within the area of tumor seen on MR (orange arrow).

Local recurrence occurs in 23–43% of patients, most commonly at the anastomosis (75%), or in a retained portion of a seminal vesicle or vas deferens (20%). Soft tissue in the prostatectomy bed away from the anastomosis and nodal or visible skeletal metastases should also be carefully excluded in the setting of rising PSA. The typical appearance of recurrent local disease is soft tissue which is isointense to skeletal muscle on T1 sequences, slightly hyper-intense to muscle on T2 and demonstrates diffusion restriction and rapid contrast enhancement and washout (Fig. 2).

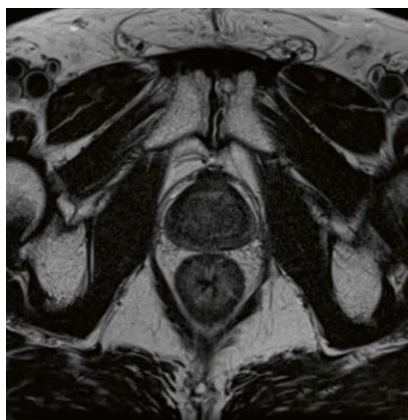Prostate MR following external beam radiotherapy

The use of external beam radiotherapy (EBRT) for treatment of prostate cancer is primarily associated with lower risk tumors, although with the addition of androgen deprivation therapy (ADT) higher risk tumors can also be treated, often in the setting of patients with significant comorbidity precluding surgery or in patients who have declined invasive treatment [2].

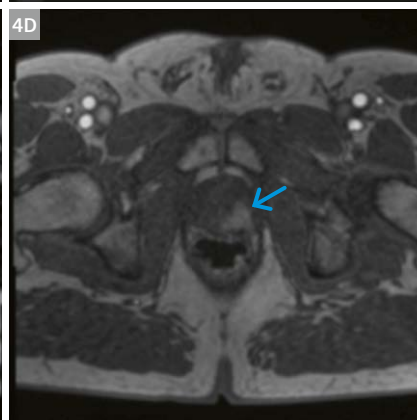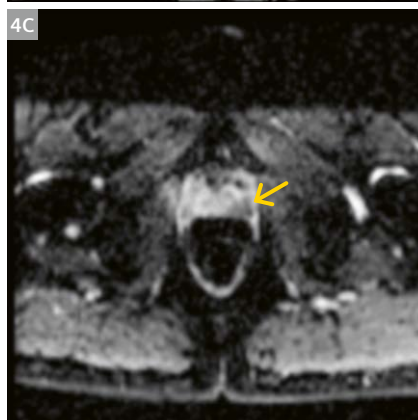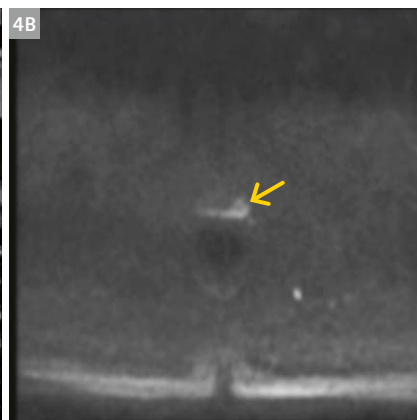
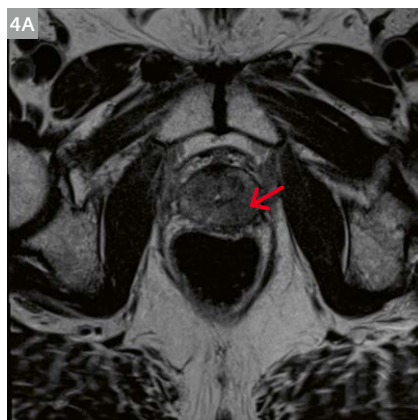
Biochemical recurrence following RT is defined as a PSA rise of > 2 ng/mL above the initial PSA nadir. In this setting localization of the site of recurrence is crucial as salvage surgery carries significant morbidity and should be reserved for those patients who might still be cured. Therefore confirmation through biopsy is mandatory.

Following EBRT the prostate gland shows diffuse atrophy with reduced signal on T2 sequences which can mask areas of recurrent tumor. Normal differentiation between the peripheral and transition zones becomes indistinct and post EBRT changes in the adjacent muscle and bone marrow may be seen. Atrophy of the seminal vesicles is commonly seen [6] (Fig. 3).

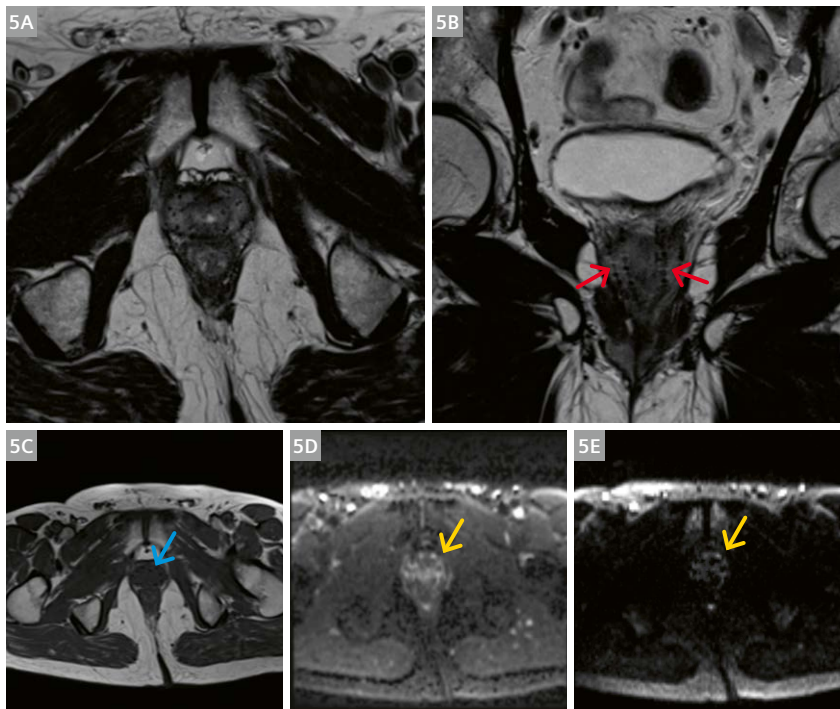
Recurrence most often occurs at the site of initial tumor and may still appear lower in T2 signal than the surrounding prostate tissue. Multiparametric (mp) MRI has been shown to be superior to anatomical imaging, and diffusion restriction or tissue demonstrating early enhancement with washout should be considered suspicious. Gradual enhancement without washout is typically seen in patients treated with RT [7] (Fig. 4).



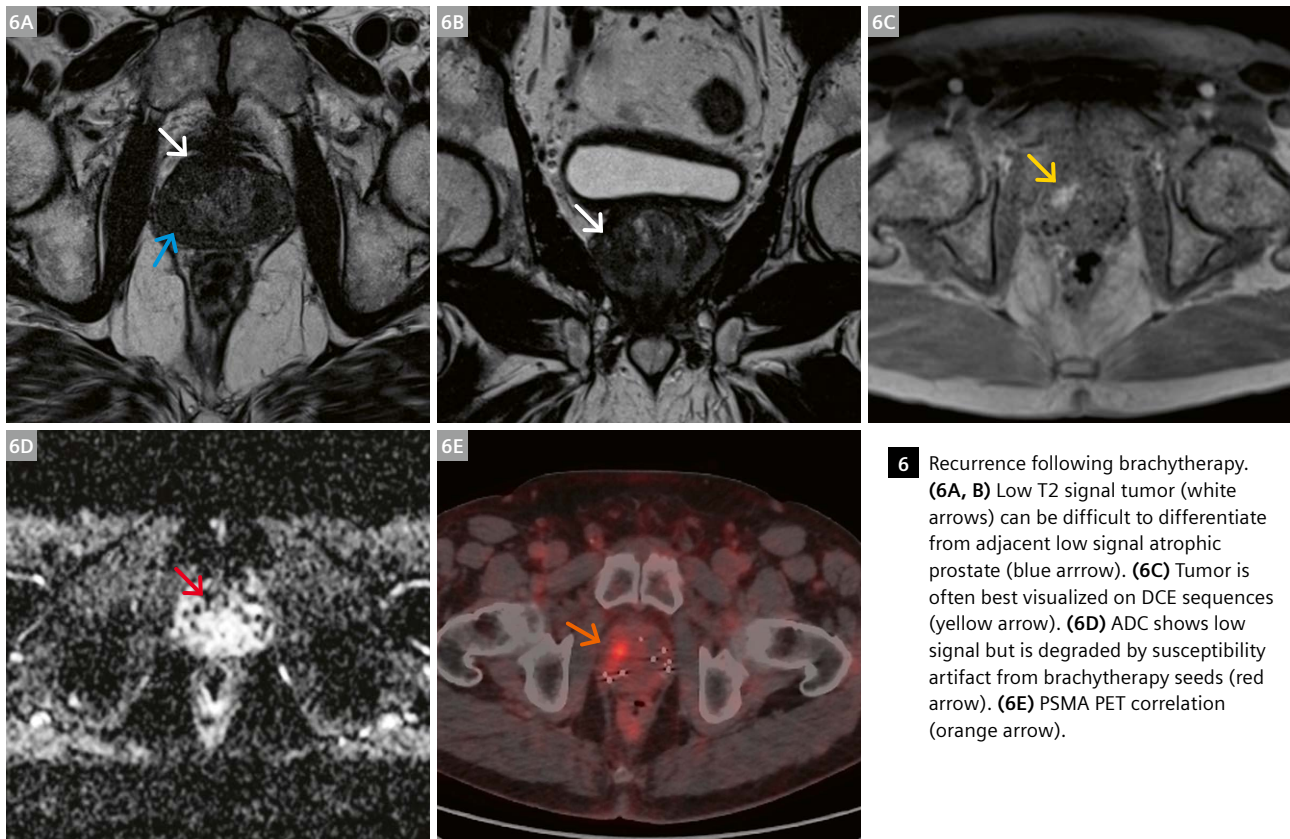
3 Expected findings following external beam radiotherapy (EBRT): Diffuse atrophy of prostate with decreased signal on T2 sequences, loss of normal distinction between peripheral and transition zones, increase T2 signal in muscle and bone marrow. Diffuse low signal thickening of bladder and rectal walls may also be seen.



4 Recurrence of prostate cancer following EBRT. (4A) T2 axial image showing subtle low signal in the left midgland (red arrow), (4B) corresponding high signal on DWI (yellow arrow) and (4C) low ADC values (yellow arrow) with (4D) avid contrast enhancement on DCE sequence (blue arrow) in keeping with tumor.



5 Normal appearances following brachytherapy: **(5A, B)** Homogeneous low T2 signal throughout the gland with reduced differentiation between peripheral and transitional zones. **(5B)** On the coronal image, seeds are seen to run in parallel (red arrows). **(5C)** T1 images show seeds with susceptibility artifact (blue arrow). **(5D, E)** DWI and ADC sequences show marked susceptibility artifact limiting use (yellow arrows).



6 Recurrence following brachytherapy. **(6A, B)** Low T2 signal tumor (white arrows) can be difficult to differentiate from adjacent low signal atrophic prostate (blue arrow). **(6C)** Tumor is often best visualized on DCE sequences (yellow arrow). **(6D)** ADC shows low signal but is degraded by susceptibility artifact from brachytherapy seeds (red arrow). **(6E)** PSMA PET correlation (orange arrow).

Trans-perineal brachytherapy

The insertion of metal seeds into the prostate to deliver highly localized doses of ionizing radiation is performed using a transrectal ultrasound probe and a template grid for guidance. Typically patients with low grade, low volume cancer are offered brachytherapy if there has been no previous prostatic surgery (TURP), the prostate volume is below 50 mL and the International Prostate Symptom Score is ≤ 12 [2].

No consensus exists regarding the definition of biochemical recurrence in patients treated with brachytherapy [1, 8]. 30–60% of patients experience a rise in PSA around one year following the insertion of the seeds which can last for around 12 months. After this period a persistently rising PSA should be viewed with suspicion.

Brachytherapy causes a similar appearance in the prostatic parenchyma to EBRT with homogeneous low T2 signal and loss of normal zonal anatomy. The low signal associated with treatment can mask low signal recurrence. In addition, multiple seeds can be visualized running in parallel on coronal images and may also be seen outside of the gland in the periprostatic fat, the bladder wall and in the base of the penis/perineum (Fig. 5). Areas of susceptibility artifact due to seeds severely limit the interpretation of DWI sequences and recurrences are often best visualized using DCE [6] (Fig. 6).

Androgen deprivation therapy (ADT)

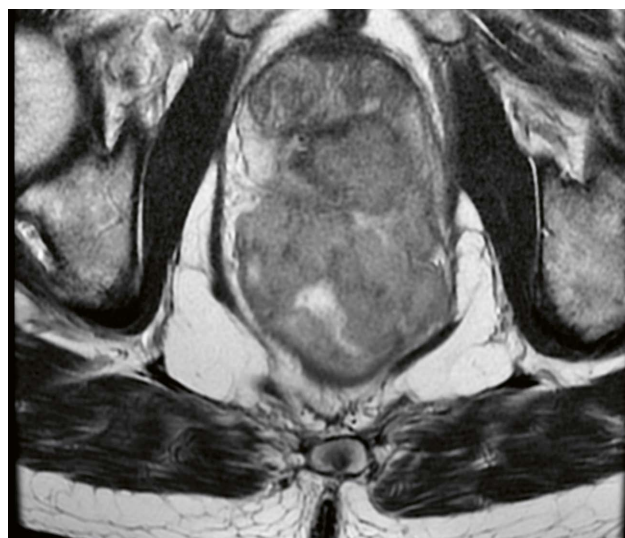
Androgen deprivation therapy can be used in the setting of incurable disease or as an adjunct to radiotherapy. Initial treatment can often result in a significant reduction in tumor volume. Diverse morphologic and signal changes are possible following the initiation of ADT with diffuse atrophy of the gland due to apoptosis of prostate cells the

most commonly seen appearance. Loss of the normal zonal definition due to decreased peripheral zone signal is often seen, and the seminal vesicles usually atrophy. Residual tumor can be identified by areas of diffusion restriction and rapid enhancement with washout [9, 10] (Figs. 7, 8).

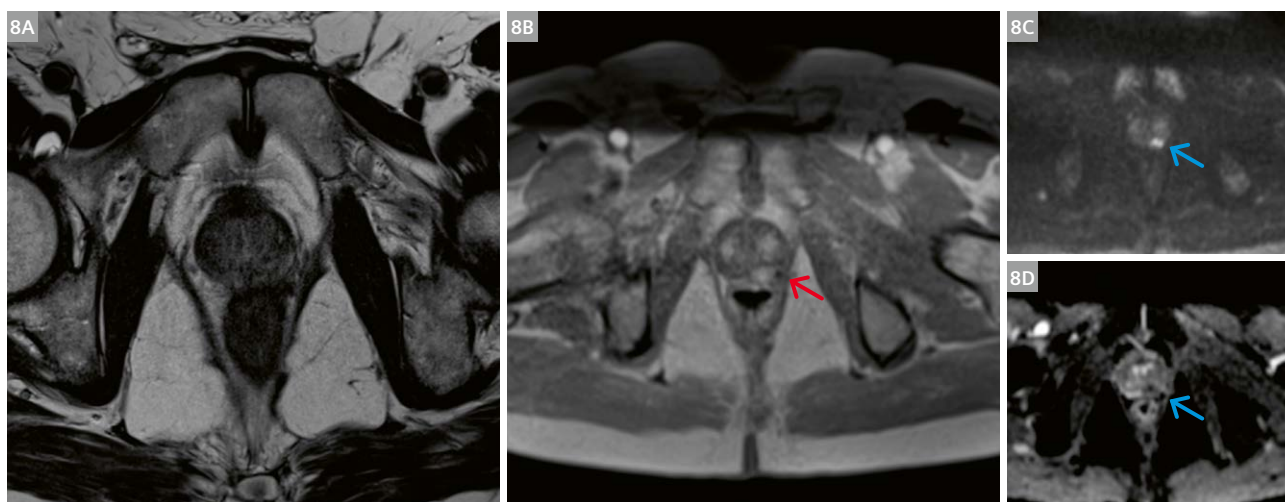
Focal therapies

Various modalities for the focal treatments of prostate cancer have been proposed and implemented in recent years, most relying on targeted destruction of localized areas of the prostate gland where tumor is located.

Cryotherapy involves ablation tissue by extremely cold temperatures using probes inserted transperineally



7 Pre ADT axial T2 image with extensive tumor invading the rectum and pelvic sidewall.



8 Same patient following 8 months of ADT treatment. **(8A)** T2 image showing marked reduction in tumor volume without clearly identifiable residual disease. **(8B)** Left mid gland peripheral zone tumor is seen on DCE (red arrow) and **(8C)** DWI, and **(8D)** ADC sequences (blue arrows).

using a template grid. Ice ball formation leads to lysis of cells within the treatment zone.

High intensity focused ultrasound causes coagulation necrosis by converting mechanical energy into heat and generating a cavitation affect.

Photodynamic therapy involves pre-treatment of the patient with a photosensitizer molecule which absorbs light of a specific frequency and transfers energy to adjacent oxygen molecules creating reactive oxygen species that trigger cell destruction.

Focal laser ablation involves thermal destruction of tissue via a fiberoptic cable placed within the tumor and is performed with MR guidance.

Irreversible electroporation uses two electrodes to increase the permeability of cell membranes leading to apoptosis and necrosis.

Post treatment appearances following focal therapy are variable; often a central zone of necrosis is demonstrated with absence of enhancement, surrounded by an enhancing rim of granulation tissue. The T2 sequences often demonstrate heterogeneous or hypointense signal in the area of treatment. High signal on T1 sequences can be seen due to hemorrhage and blood products, and

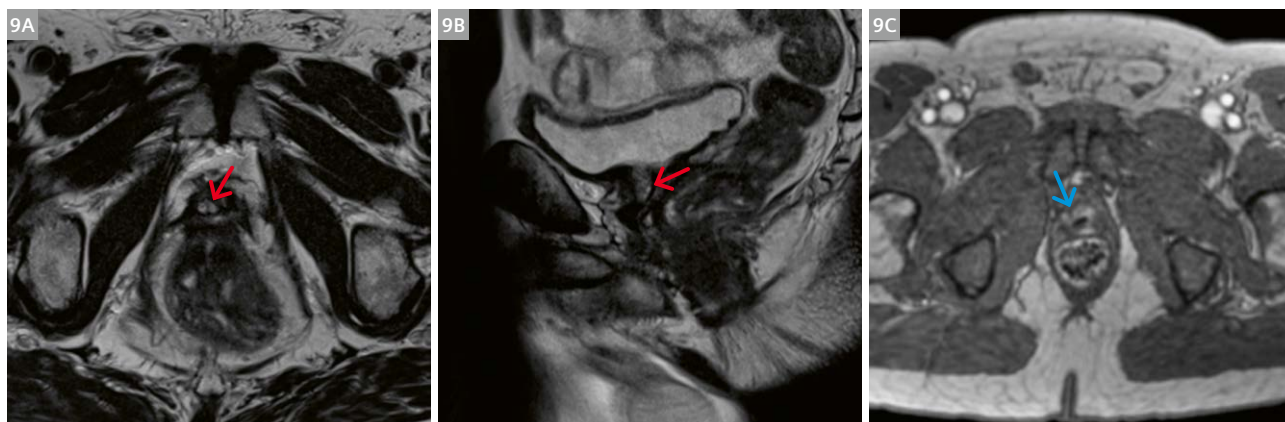therefore subtraction sequences are important to differentiate this from enhancement (Fig. 9).

Recurrence following focal therapy can appear as low signal which blends in with the adjacent low T2 signal fibrotic tissue. Low ADC values are suspicious only if combined with high signal on the DWI sequence in order to accurately distinguish recurrent tumor from areas of fibrotic tissue.

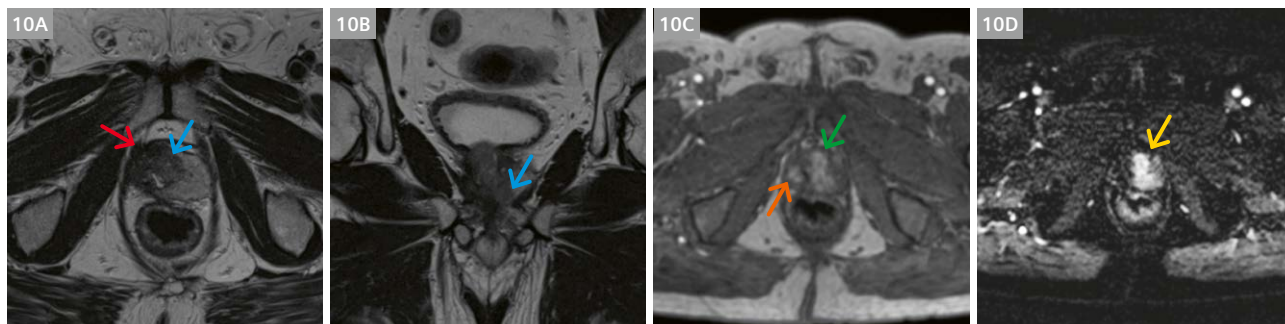
Focal enhancement with washout is also suspicious for residual viable tumor however areas of nodular enhancement at the borders of treated lesions secondary to reactive normal prostate tissue can mimic recurrence [11].

Mimics of recurrence

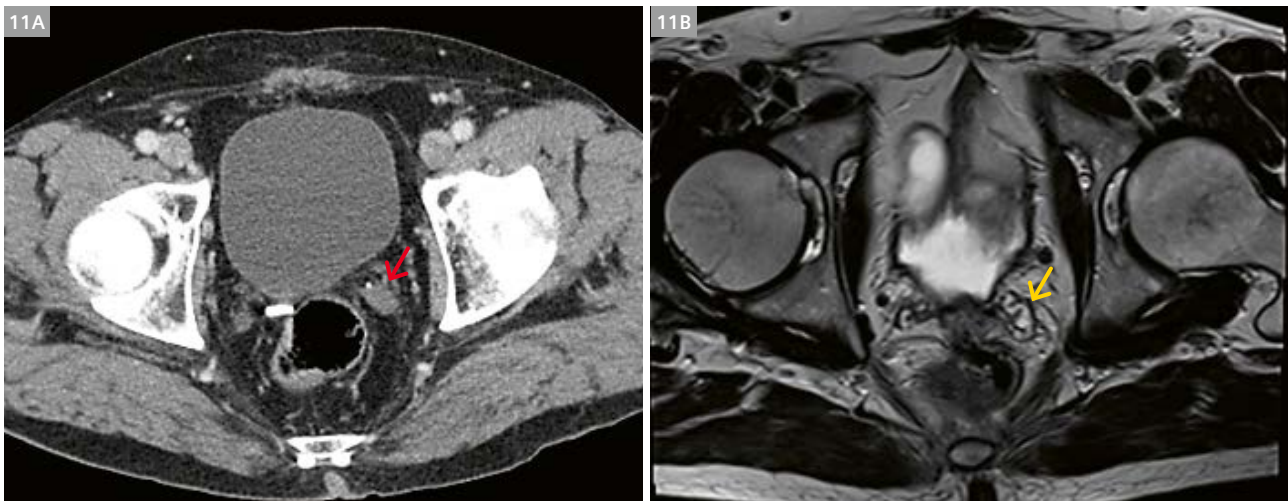
Retained seminal vesicle: Often first identified on CT, the seminal vesicle is retained in 20% of radical prostatectomies [12], commonly related to difficulties in surgical technique or intentionally to reduce the risk of neurovascular bundle injury. MR typically demonstrates a typical convoluted appearance with no evidence of diffusion restriction or abnormal enhancement (Fig. 11).



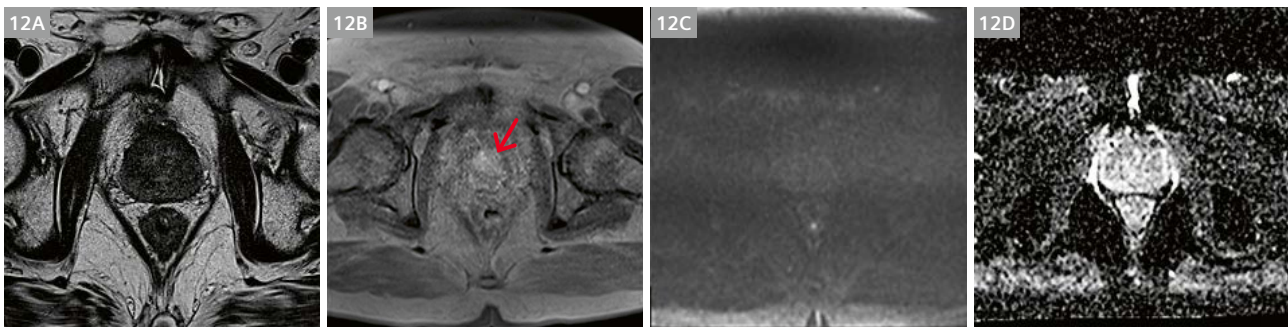
9 (9A, B) Axial and sagittal images showing post HIFU ablation zone with central areal of high signal necrosis (red arrows). (9C) Axial DCE image showing peripheral rim enhancement around the site of ablation in a different patient (blue arrow).



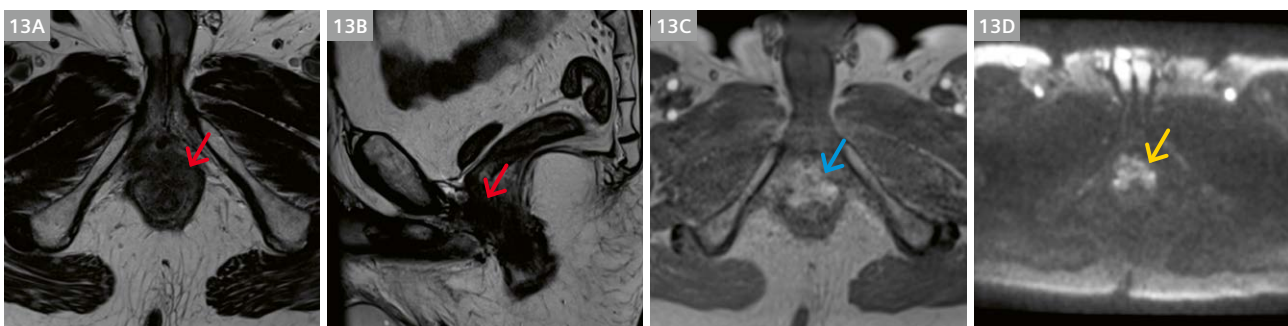10 Recurrence following phototherapy. (10A, B) T2 sequence showing low signal fibrosis at treatment site (red arrow) with adjacent intermediate signal recurrence (blue arrows). (10C, D) DCE images show enhancement corresponding to the area of abnormality (green arrow). Subtraction images are mandatory to distinguish blood product within the treatment zone (orange arrow) from enhancing tumor (yellow arrow).



11 (11A) Retained seminal vesicle can be mistaken for recurrence especially on CT (red arrow). (11B) Characteristic convoluted appearance on T2-weighted MR confirms diagnosis (yellow arrow).



12 Fibrosis or scar tissue following radiotherapy can be difficult to distinguish from tumor. (12A) Scar is diffusely low signal on T2, (12B) 3 minute delayed post gadolinium sequence demonstrates late enhancement (red arrow). (12C, D) Absence of diffusion restriction.



13 Low signal tumor involving prostate resection bed in a patient treated with radiotherapy and salvage cystoprostatectomy following recurrence, biopsy showed invasive rectal adenocarcinoma. (13A, B) Low signal in resection bed involving rectum (red arrows). (13C) Enhancing tumor (blue arrow), (13D) diffusion restriction (yellow arrow).

Focal fibrosis or scarring is commonly seen following EBRT and tissue appears low signal on T2 with no diffusion restriction and diffuse high values on the ADC map. Enhancement should be absent or show delayed gradual uptake without rapid washout (Fig. 12).

Granulation tissue tends to show high signal on T2 sequences with no evidence of diffusion restriction or early enhancement.

The occurrence of secondary cancers due to prior pelvic radiotherapy is somewhat controversial however abnormal findings within the prostatic bed following radiotherapy or prostatectomy can also be related to tumors arising in adjacent structures and careful examination of the other pelvic organs is mandatory. Unusual tumor behaviour such as failure to respond to ADT in a blockade naïve patient should prompt consideration of biopsy (Fig. 13).

Conclusion

Early detection and localization of recurrent prostate cancer is important for treatment planning and prognosis. Detection in post treatment cases can be challenging however advances in mp-MRI help to differentiate recurrence from mimics with DCE sequences being key in post treatment cases. Radiologist familiarity with imaging appearances of recurrence and mimics helps to make a correct and timely diagnosis.

Contact

Associate Professor Silvia Chang, M.D., FRCPC
Department of Radiology
Vancouver General Hospital
899 West 12th Avenue
Vancouver, BC V5Z 1M9
Canada
Tel.: +1 (604) 875-4340
Silvia.Chang@vch.ca



References

- 1 Cookson MS, Aus G, Burnett AL, et al. Variation in the definition of biochemical recurrence in patients treated for localized prostate cancer: the American Urological Association Prostate Guidelines for Localized Prostate Cancer Update Panel report and recommendations for a standard in the reporting of surgical outcomes. *J Urol.* 2007;177(2):540-545.
- 2 Mottet N, Bellmunt J, Bolla M, et al. EAU-ESTRO-SIOG Guidelines on Prostate Cancer. Part 1: Screening, Diagnosis, and Local Treatment with Curative Intent. *Eur Urol.* 2017;71(4):618-629.
- 3 Cornford P, Bellmunt J, Bolla M, et al. EAU-ESTRO-SIOG Guidelines on Prostate Cancer. Part II: Treatment of Relapsing, Metastatic, and Castration-Resistant Prostate Cancer. *Eur Urol.* 2017;71(4):630-642.
- 4 Allen SD, Thompson A, Sohaib SA. The normal post-surgical anatomy of the male pelvis following radical prostatectomy as assessed by magnetic resonance imaging. *Eur Radiol.* 2008;18(6):1281-1291.
- 5 Tyson MD, II, Andrews PE, Ferrigni RF, Humphreys MR, Parker AS, Castle EP. Radical Prostatectomy Trends in the United States: 1998 to 2011. *Mayo Clinic Proceedings.* 2016;91(1):10–16.
- 6 Rouvière O, Vitry T, Lyonnet D. Imaging of prostate cancer local recurrences: why and how? *Eur Radiol.* 2010;20(5):1254-1266.
- 7 Roy C, Foudi F, Charton J, et al. Comparative sensitivities of functional MRI sequences in detection of local recurrence of prostate carcinoma after radical prostatectomy or external-beam radiotherapy. *AJR Am J Roentgenol.* 2013;200(4):W361-368.
- 8 Roach M, Hanks G, Thames H, et al. Defining biochemical failure following radiotherapy with or without hormonal therapy in men with clinically localized prostate cancer: recommendations of the RTOG-ASTRO Phoenix Consensus Conference. *Int J Radiat Oncol Biol Phys.* 2006;65(4):965-974.
- 9 Kim AY, Kim CK, Park SY, Park BK. Diffusion-weighted imaging to evaluate for changes from androgen deprivation therapy in prostate cancer. *AJR Am J Roentgenol.* 2014;203(6):W645-650.
- 10 Hötter AM, Mazaheri Y, Zheng J, et al. Prostate Cancer: assessing the effects of androgen-deprivation therapy using quantitative diffusion-weighted and dynamic contrast-enhanced MRI. *Eur Radiol.* 2015;25(9):2665-2672.
- 11 De Visschere PJ, De Meerleer GO, Fütterer JJ, Villeirs GM. Role of MRI in follow-up after focal therapy for prostate carcinoma. *AJR Am J Roentgenol.* 2010;194(6):1427-1433.
- 12 Sella T, Schwartz LH, Hricak H. Retained seminal vesicles after radical prostatectomy: frequency, MRI characteristics, and clinical relevance. *AJR Am J Roentgenol.* 2006;186(2):539-546.