COVID-19 Pneumonia – Quantitative Assessment

By Xiaoyong Zhang, RT; Yuquan Wang, RT; Xi Zhao, MD*; Prof. Rongpin Wang, MD
Department of Radiology, Guizhou Provincial People's Hospital, Guiyang, P. R. China
*Siemens Healthineers, China

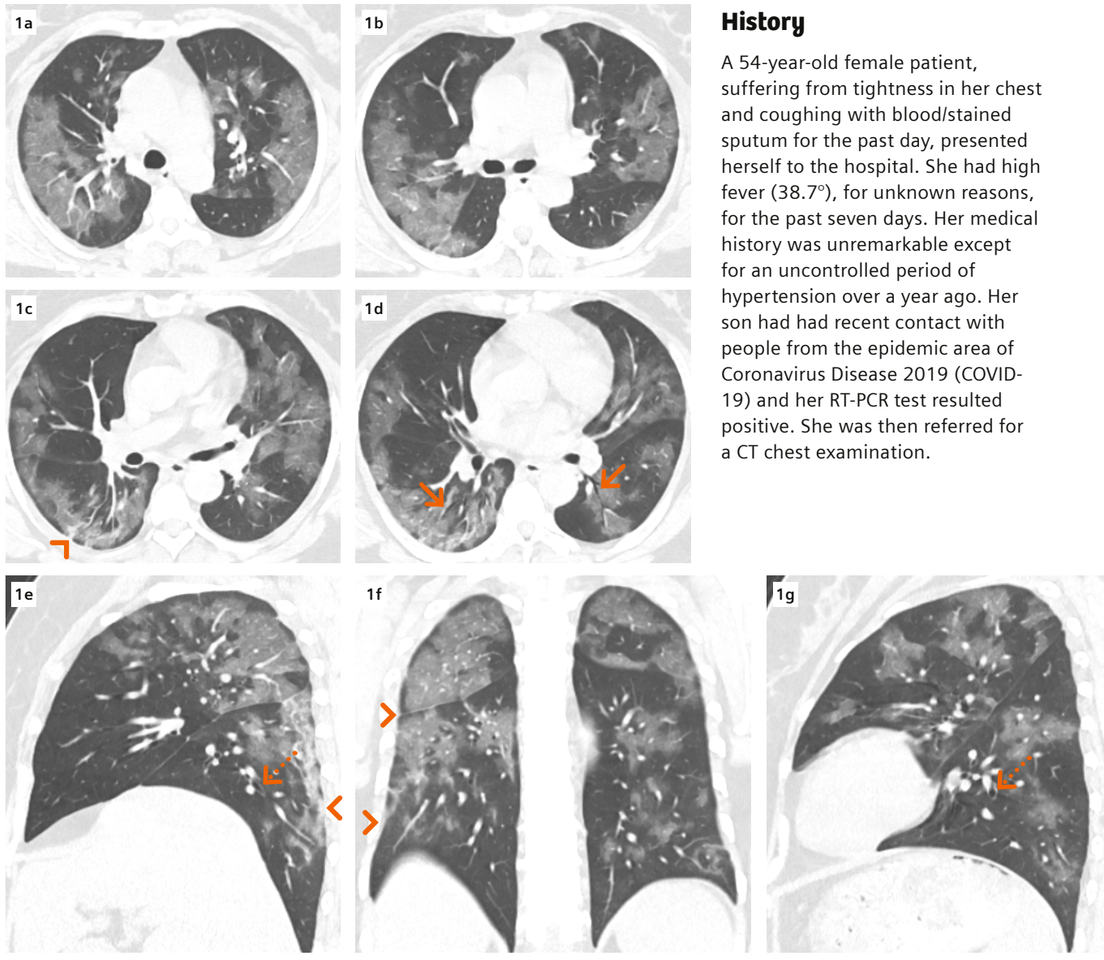

1 Axial images (Figs. 1a–1d), sagittal MPRs of the right (Fig. 1e) and left (Fig. 1g) lungs, and coronal (Fig. 1f) MPR show multifocal and bilateral patchy areas of GGO scattered within both lungs, predominantly in the subpleural, peripheral, and posterior regions. Some regions show partial consolidations. Signs of air bronchogram (arrows), bronchial wall thickening (dotted arrows), interlobular septal thickening and pleural thickening (arrowheads) are also seen.

History

A 54-year-old female patient, suffering from tightness in her chest and coughing with blood/stained sputum for the past day, presented herself to the hospital. She had high fever (38.7°), for unknown reasons, for the past seven days. Her medical history was unremarkable except for an uncontrolled period of hypertension over a year ago. Her son had had recent contact with people from the epidemic area of Coronavirus Disease 2019 (COVID-19) and her RT-PCR test resulted positive. She was then referred for a CT chest examination.

Diagnosis

CT images showed multifocal and bilateral patchy areas of ground-glass opacities (GGO) scattered within both lungs, predominantly in the subpleural, peripheral and posterior regions. Partial consolidations were seen in some of these areas. Signs of air bronchogram, bronchial wall thickening, interlobular septal thickening and pleural thickening were also visualized. No significant mediastinal lymphadenopathy, pericardial or pleural effusion or vascular abnormalities were seen. These findings were consistent with the diagnosis of a COVID-19 pneumonia.

Comments

COVID-19 pneumonia is a highly contagious viral pneumonia caused by a novel coronavirus (SARS-CoV-2) of unclear origin. A chest CT is essential for the diagnostic work-up, with a common finding of a rather mixed and diverse pattern involving both lung parenchyma and lung interstitium. As shown in the study [1], the virus first invades the pulmonary interstitium, manifesting as GGO, then further infiltrates the parenchyma characterizing consolidation. These lesions can be visually evaluated as well as quantitatively analyzed. In this case, the application of *syngo*.CT Pulmo 3D is used, which allows for an automated segmentation of the lungs and quantification of the lung densities. The differences in the lung densities can be shown numerically and graphically with color-coded maps. This helps assessing the severity of the infection and the prognosis in follow-up. ●

Reference
[1] Shuchang Zhou, et al. CT Features of Coronavirus Disease 2019 (COVID-19) Pneumonia in 62 Patients in Wuhan, China. AJR 2020; 214:1–8.

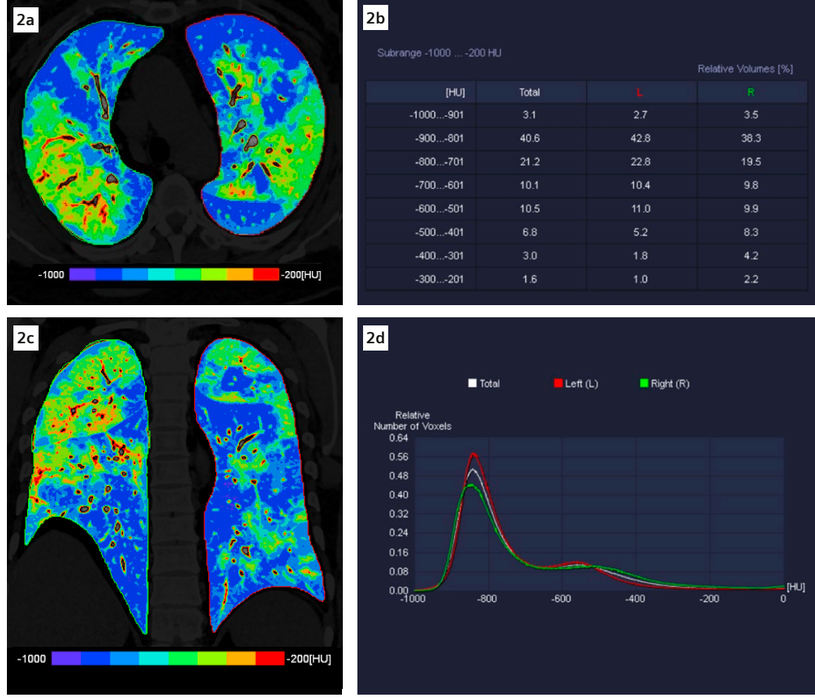

2 The differences in the lung densities are shown numerically divided into subranges (Fig. 2b) and graphically (Fig. 2d) with color-coded maps (Figs. 2a & 2c).

Examination Protocol

Scanner	SOMATOM Perspective
Scan area	Thorax
Scan mode	Spiral
Scan length	255.1 mm
Scan direction	Caudo-cranial
Scan time	2.8 s
Tube voltage	130 kV
Effective mAs	67 mAs
Dose modulation	CARE Dose4D™
$CTDI_{vol}$	7.5 mGy
DLP	251.4 mGy cm
Rotation time	0.6 s
Pitch	1.45
Slice collimation	64 x 0.6 mm
Slice width	1.0 mm
Reconstruction increment	0.7 mm
Reconstruction kernel	I41s / I50s

The outcomes by Siemens Healthineers customers described herein are based on results that were achieved in the customer's unique setting. Since there is no "typical" hospital and many variables exist (e.g., hospital size, case mix, level of IT adoption), there can be no guarantee that other customers will achieve the same results.