

# Improving Productivity in MRI – Clinical Experience in a Multisite Outpatient Practice Setting

Mike Notohamiprodjo, M.D., MHBA; Gerwin Schmidt, M.D.

DIE RADIOLOGIE, Munich, Germany

## Introduction

Magnetic resonance imaging (MRI) is one of the most commonly performed procedures and the financial backbone of diagnostic imaging. Since the populations of industrial countries are continuously aging and average morbidity is therefore increasing, demand for diagnostic procedures is growing. Labor and operating costs, however, are rising while reimbursement for medical procedures is declining. This makes efficient exploitation of the available resources of pivotal importance in an increasingly competitive healthcare market.

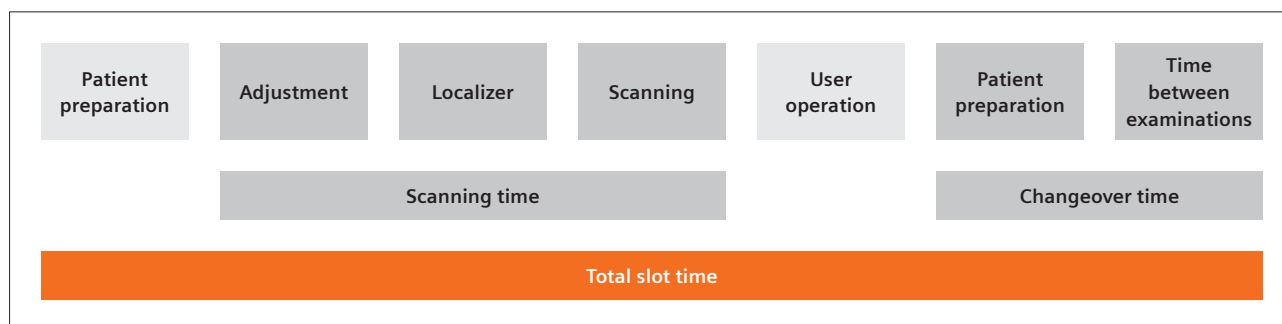
Expanding the number of examined patients per MR scanner will help to meet the growing clinical demand and reliably improve profitability [1].

For this reason, an efficient and productive workflow with short patient changeover and acquisition times is essential. MR protocols should be sufficiently short, without losing time for planning and setting up the examinations. At the same time, high image quality has to be maintained to ensure diagnostic relevance. Investing in new acceleration techniques and workflow solutions will help to achieve these goals and bring forward the break-even point.

The recently introduced BioMatrix Technology and syngo MR XA software provide several methods to streamline the daily workflow of MR technologists. In order to

shorten patient changeover times, automated selection and positioning of coils have been integrated, as has automation of image acquisition using Dot engines. In addition to established parallel imaging techniques such as GRAPPA and CAIPIRINHA, advanced acceleration methods have been integrated into the clinical protocols: Simultaneous Multi-slice (SMS) imaging employs complex RF pulses to simultaneously acquire several sections along the z-axis, allowing a significant reduction in the image acquisition time by shortening the required TR time with little SNR penalty [2], while Compressed Sensing (CS) rapidly accelerates MR imaging by reconstructing sparse data from a highly undersampled *k*-space [3].

DIE RADIOLOGIE, a large radiology network in the Munich area, recently installed a 1.5T MAGNETOM Sola scanner equipped with BioMatrix Technology and the newest acceleration techniques, as provided by the syngo MR XA20 software. Recent studies have shown that these methods can shorten individual sequences and entire examinations. However, we were interested to know whether the integrated technology is also effective in daily clinical routine and whether it could potentially increase the profitability of an MR scanner.



**1** Definition of the components of an examination slot.

To study the effects of these novel techniques on patient throughput and subsequently on profitability, we performed a retrospective study that compared a 1.5T MAGNETOM Sola scanner with its predecessor, the 1.5T MAGNETOM Aera, in daily clinical routine.

## Material and methods

### MR scanners

DIE RADIOLOGIE is one of Germany's largest diagnostic imaging service providers with currently 13 outpatient practice sites in and around the Munich area. It operates 15 MR scanners, performing over 150,000 examinations per year. Over 250 healthcare professionals working as physicians, technologists, front-desk and administrative staff ensure that diagnostic and interventional procedures are performed to a high level.

The MAGNETOM Sola and MAGNETOM Aera (both Siemens Healthcare, Erlangen, Germany) are operated at different but similar sites in Munich. At each of these sites, another 1.5T scanner is operated in an adjacent suite.

The MAGNETOM Sola (software version *syngo* MR XA20; XJ gradients with 33 mT/m at 125 T/m/s, 32 channels) was installed mid-2019 and is equipped with a full coil set (20-channel tiltable head-neck-coil, 24-channel spine coil, 12-channel body coil, 16-channel Shoulder Shape coil, 18-channel Tx/Rx knee coil, 18-channel UltraFlex coil, 16-channel hand/wrist-coil, and 16 channel foot/ankle-coil), as well as the Turbo Suites Essential (iPAT, tPAT, PAT<sup>2</sup>, CAIPIRINHA VIBE, CAIPIRINHA SPACE) and Excelerate (SMS EPI for DWI / DTI / BOLD, SMS TSE, CS TOF, CS SPACE), so that, in particular, Simultaneous Multislice imaging for DWI and TSE sequences and Compressed Sensing for MRCP and 3D time-of-flight sequences can now be integrated into clinical protocols. Furthermore, automated coil selection and patient positioning was applied.

The MAGNETOM Aera (software version *syngo* MR D13D, XQ gradients with 45 mT/m at 200 T/m/s, 48 channels) has been in operation since 2013, and features a similar coil set to the MAGNETOM Sola (32-channel tiltable head-neck coil, 32-channel spine coil, 18-channel body coil, 16-channel shoulder large/small, 15-channel Tx/Rx knee coil, 4-channel flex coil, 16-channel hand/wrist-coil and 16-channel foot/ankle coil). The most recent acceleration techniques, SMS and CS, are not available on this scanner.

Core examination times were between 8 a.m. and 6 p.m. on both systems. During core times, both scanners are usually operated by two technologists. The standard examination slot is 20 minutes long, so that three patients are examined per hour on average.

Usually, several examination slots are grouped by body region to minimize coil setup and examination

times. There is no scheduled break during the day.

The standard examination schedule for both scanners mainly consists of musculoskeletal and body imaging slots.

Prior to the study, internal and external application specialists matched the image quality of the MAGNETOM Sola to the MAGNETOM Aera, applying available acceleration techniques to shorten examination times. Image quality was approved by the authors of the study.

### Data collection

Capacity utilization of the scanners was monitored using the cloud-based service teamplay (Siemens Healthcare, Erlangen, Germany) from August to October 2019.

The extracted data comprised the body region examined, the coils used, the timepoints of patient registration, and all acquired sequences, including localizers and completion of the examination.

Using this data, parameters such as average patient preparation time before examination, average scanning time, average user operating time, average patient preparation time after examination, average time between examinations, and changeover time (sum of the last two items) could be derived (Fig. 1).

Only data collected during the core time between 8 a.m. and 6 p.m. was included. Days on which scanners were out of operation for more than one hour due to maintenance, for example, were excluded from the analysis.

### Statistical analysis

Scanner operating times were found to exhibit normal distribution based on visual evaluation and were therefore summarized as mean values. To investigate differences between scanner operating times, one-tailed *t*-tests were performed on two independent samples with null hypotheses of time differences that equal zero and alternative hypotheses of greater time values for the MAGNETOM Aera than for the MAGNETOM Sola. Due to multiple testing, a *p*-value of < 0.001 (Bonferroni-corrected) was considered statistically significant. Time savings as a percentage were calculated as a time difference in relation to the operating times of the MAGNETOM Aera. Statistical analyses were conducted using Stata 16.1 (Stata Corporation, College Station, TX, USA).

## Results

### Examination mix

The most commonly performed examination on both scanners was MRI of the knee (Sola vs. Aera; 23% vs. 18%), of the lumbar spine (15% vs. 18%), of the cervical spine (12% vs. 16%), and of the shoulder (11% vs. 10%). Significantly more brain MRIs were performed on the MAGNETOM Aera than on the MAGNETOM Sola (6% vs. < 1%) (Fig. 2).

### Clinical throughput

The average number of patients examined during the core time was significantly higher ( $p < 0.001$ ) for the MAGNETOM Sola,  $n = 30$  as opposed to  $n = 26$  for the MAGNETOM Aera. This is a difference of 16%. On the busiest day, the number of examined patients was  $n = 33$  for the MAGNETOM Sola and  $n = 29$  for the MAGNETOM Aera.

The highest reduction in total slot time was achieved for MRI of the thoracic spine (21:55 vs. 28:09 minutes), lumbar spine (18:49 vs. 22:46 minutes), and the abdomen (22:23 vs. 26:57 minutes). The highest reduction in the average scan time was achieved for MRI of the knee (10:56 vs. 13:31 minutes), abdomen (14:20 vs. 17:34 minutes), and thoracic spine (14:41 vs. 17:18 minutes). The average slot time length was significantly shorter ( $p < 0.001$ ), with 19:58 minutes for the MAGNETOM Sola and 22:35 minutes for the MAGNETOM Aera. The total slot time for the most commonly performed regions knee, lumbar and cervical spine, shoulder and ankle was reduced by between 10% and 17% on the MAGNETOM Sola (Fig. 3).

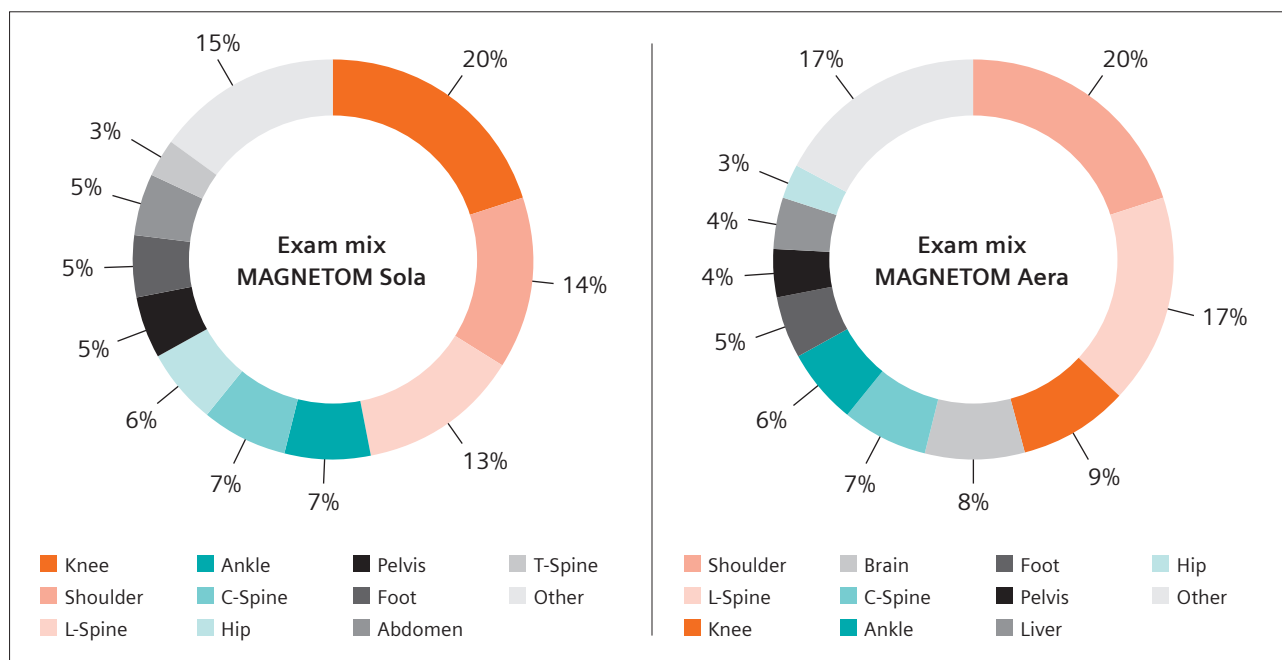
The overall average scanning time (adjustment, localizers, and measurement) on the MAGNETOM Sola was significantly, that is 12%, shorter ( $p < 0.001$ ) than on the MAGNETOM Aera (12 minutes vs. 15 minutes). The average operating time (time for planning, patient communication during measurement) was also significantly, that is 22%, shorter ( $p < 0.001$ ) for the MAGNETOM Sola (1:45 minutes vs. 2:15 minutes). The average changeover time (patient preparation after examination and time

between examinations) was 3:42 minutes for the MAGNETOM Sola and 3:54 for the MAGNETOM Aera (Fig. 4), and therefore not significantly different.

### Discussion

Our clinical productivity study shows that clinical throughput was significantly higher on the MAGNETOM Sola when compared with a similarly equipped MAGNETOM Aera. The average examination slot time was shortened by 2.5 minutes, which can be largely attributed to a shorter scanning time. The most frequently performed MR procedures were shortened by 11–17%, while maintaining similar image quality. These findings are of interest because the MAGNETOM Aera features stronger gradients and a higher number of channels while the MAGNETOM Sola is equipped with more recent accelerated acquisition techniques and coils.

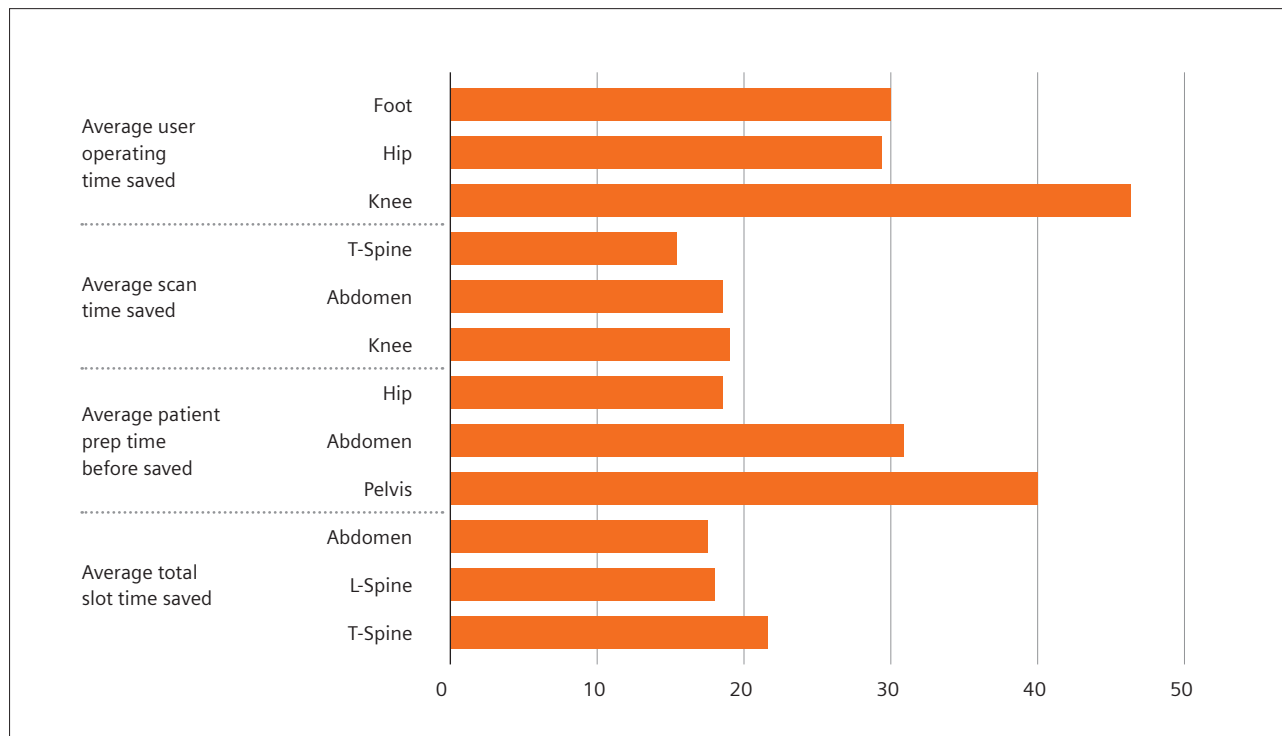
The results of this study are significant because diagnostic imaging providers are also financial units, which are expected to achieve a certain profitability to meet the economic agenda of their respective shareholders. DIE RADIOLOGIE is still privately owned by its associate physicians, so that medical aspects such as high-quality examinations and precise diagnostic tests, an appropriate working environment, and comfortable patient experience still take precedence over purely financial aspects. In principle, a further shortening of the protocols is still potentially possible if necessitated by financial circumstances. However, for the time being we have decided against further accelerating MR protocols.



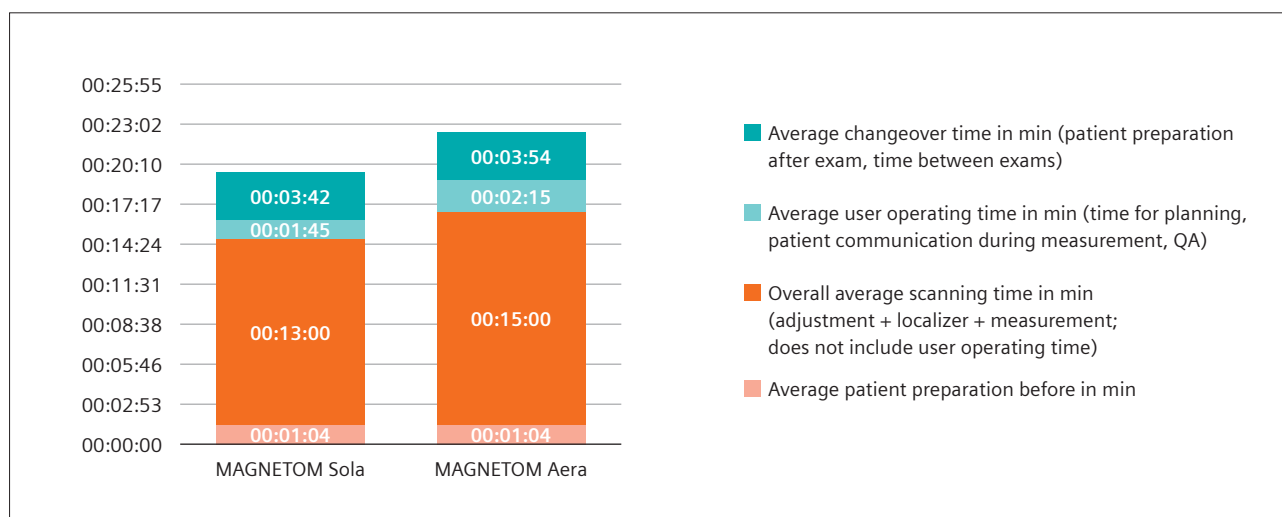
2 Exam mix of the MAGNETOM Sola and Aera.

With increasing patient throughput, a reduction in patient scanning time is one of the key components for shortening the examination slot time. While parallel imaging, usually with a GRAPPA acceleration factor of  $R = 2$ , is applied to most acquisition sequences, we have also integrated SMS acceleration into our clinical routine protocols on the MAGNETOM Sola to allow for a four-fold acceleration (achieved by combining GRAPPA  $R = 2$  and SMS = 2). We have found that SMS acquisition is particular-

ly helpful in examinations in which several slices are acquired, such as transversal sections of extremities or pelvic MR examinations. These findings corroborate previous studies, showing a significant reduction in the examination time when using this respective technique for rapid musculoskeletal imaging [4, 5] or diffusion-weighted imaging, particularly of abdominal organs [2, 6] and the prostate [7].



**3** Top three savings in % by time category.



**4** Time allocation comparison.

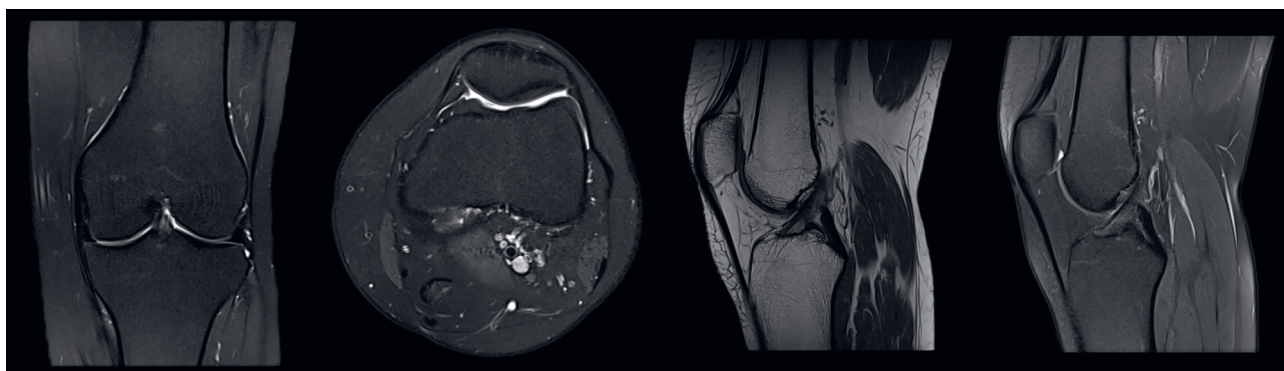
Alternatively, sequences accelerated with Compressed Sensing may lead to a significant reduction in acquisition time, such as for musculoskeletal imaging [1, 8, 9] or body imaging [3, 10, 11]. In our study, Compressed Sensing was applied for the acquisition of MRCP sequences in one breath-hold [3], providing excellent image quality in a considerably shortened acquisition time compared with the lengthy standard navigator-triggered acquisition technique, which is also susceptible to respiratory motion. The significantly shorter acquisition time of MRCP sequences most likely contributed considerably to the reduction in scan time for abdominal MRI on the MAGNETOM Sola.

Another important factor when attempting to accelerate patient throughput is shortening the non-scanning time, which consists of the changeover time and the operating time. The average changeover time was slightly shorter for the MAGNETOM Sola, which features automated coil detection and positioning. The operating

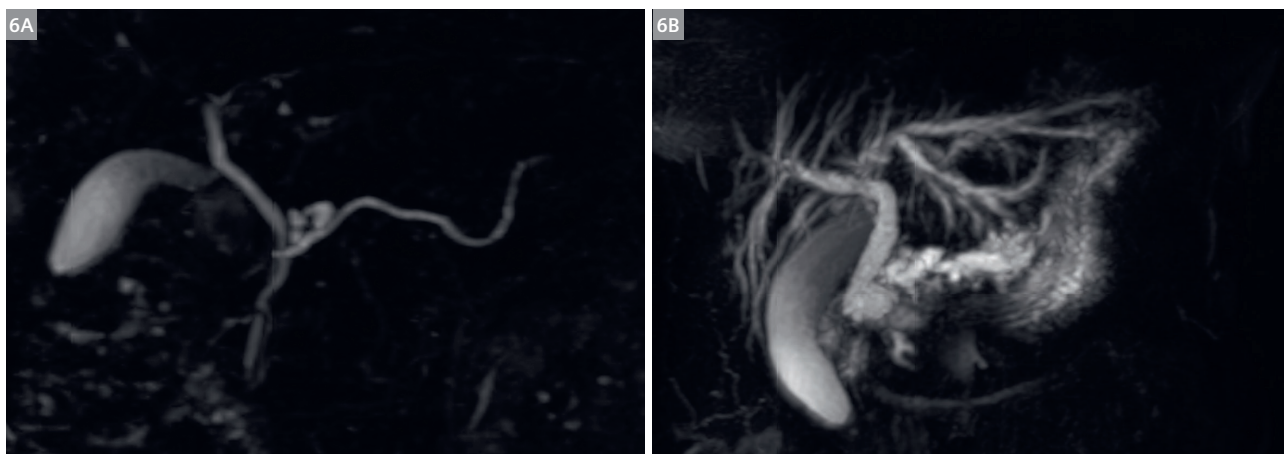
time was shortened by 22%, presumably by exploiting the automated positioning of sequences in spine and knee examinations.

On average, the MAGNETOM Sola permitted the examination of four additional patients during the core scanning time. If we extrapolate the results of this study, we can expect to scan approximately one thousand additional patients each year, or save more than 300 hours of labor time. Both scenarios mean a significant increase in profitability of the scanner with a quick return on investment, while diagnostic image quality is maintained. It should be noted, however, that the additional examinations cause additional workload for the radiologists, so that any further acceleration of complex examinations would require the assistance of artificial intelligence to support quick and reliable diagnosis [12].

This study has its limitations. First, the study was performed three months after installation of the



**5** Example MRI of the knee acquired with the MAGNETOM Sola: Fat-saturated PD-weighted images in three planes (matrix 384 / slice thickness 3 mm / scan time 2 minutes approx. each / GRAPPA 2 / SMS2) and sagittal T1-weighted sequence (matrix 448 / slice thickness 3 mm / scan time 1:30 minutes / GRAPPA 2). Total scan time was approximately nine minutes including localizers / shimming / user operation.



**6** Example MRCP accelerated with CS acquired with the MAGNETOM Sola: **(6A)** Examination of a 56-year-old male patient with a branch duct type intraductal papillary mucinous neoplasia. **(6B)** Examination of a 62-year-old female patient with a papillary mass obstructing the common bile duct and pancreatic duct. Scan time was 18 seconds each.



MAGNETOM Sola, which was compared with a system that had been in operation for seven years, so further refinement of protocols and therefore acceleration is to be expected. Second, each scanner was operated by a different team of technologists, so that changeover and operating times, for example, could also be dependent on the individual speed of the technologist. However, the reduction in slot duration was largely achieved by adjusting the scanning time. Thirdly, we did not factor in repetition of sequences, for example, due to motion artifacts, or canceled examinations, which resulted in an increased time between examinations.

In summary, the advanced acceleration techniques of the MAGNETOM Sola allowed for a significant reduction in examination time, leading to a higher throughput during clinical routine and therefore dramatically increasing profitability of the scanner.

## Acknowledgments

We would like to thank Dr. Roberto Lorbeer from Ludwig-Maximilians-University (LMU) Munich for advice on the statistical analysis.

## References

- 1 Bratke G, Rau R, Weiss K, Kabbasch C, Sircar K, Morelli JN, et al. Accelerated MRI of the Lumbar Spine Using Compressed Sensing: Quality and Efficiency. *J Magn Reson Imaging*. 2019;49(7):e164-e75.
- 2 Taron J, Martirosian P, Schwenzer NF, Erb M, Kuestner T, Weiss J, et al. Scan time minimization in hepatic diffusion-weighted imaging: evaluation of the simultaneous multislice acceleration technique with different acceleration factors and gradient preparation schemes. *MAGMA*. 2016;29(5):739-49.
- 3 Taron J, Weiss J, Notohamiprodjo M, Kuestner T, Bamberg F, Weiland E, et al. Acceleration of Magnetic Resonance Cholangiopancreatography Using Compressed Sensing at 1.5 and 3 T: A Clinical Feasibility Study. *Invest Radiol*. 2018;53(11):681-8.
- 4 Fritz J, Fritz B, Zhang J, Thawait GK, Joshi DH, Pan L, et al. Simultaneous Multislice Accelerated Turbo Spin Echo Magnetic Resonance Imaging: Comparison and Combination With In-Plane Parallel Imaging Acceleration for High-Resolution Magnetic Resonance Imaging of the Knee. *Invest Radiol*. 2017;52(9):529-37.
- 5 Kaller S, Rullmann M, Patt M, Becker GA, Luthardt J, Girbardt J, et al. Test-retest measurements of dopamine D1-type receptors using simultaneous PET/MRI imaging. *Eur J Nucl Med Mol Imaging*. 2017;44(6):1025-32.
- 6 Taron J, Weiss J, Martirosian P, Seith F, Stemmer A, Bamberg F, et al. Clinical Robustness of Accelerated and Optimized Abdominal Diffusion-Weighted Imaging. *Invest Radiol*. 2017;52(10):590-5.
- 7 Weiss J, Martirosian P, Taron J, Othman AE, Kuestner T, Erb M, et al. Feasibility of accelerated simultaneous multislice diffusion-weighted MRI of the prostate. *J Magn Reson Imaging*. 2017;46(5):1507-15.
- 8 Fritz J, Fritz B, Thawait GK, Raithel E, Gilson WD, Nittka M, et al. Advanced metal artifact reduction MRI of metal-on-metal hip resurfacing arthroplasty implants: compressed sensing acceleration enables the time-neutral use of SEMAC. *Skeletal Radiol*. 2016;45(10):1345-56.
- 9 Fritz J, Raithel E, Thawait GK, Gilson W, Papp DF. Six-Fold Acceleration of High-Spatial Resolution 3D SPACE MRI of the Knee Through Incoherent k-Space Undersampling and Iterative Reconstruction-First Experience. *Invest Radiol*. 2016;51(6):400-9.
- 10 Weiss J, Notohamiprodjo M, Taron J, Martirosian P, Nickel D, Bamberg F, et al. Continuous Hepatic Arterial Multiphase Magnetic Resonance Imaging During Free-Breathing. *Invest Radiol*. 2018;53(10):596-601.
- 11 Weiss J, Notohamiprodjo M, Martirosian P, Taron J, Nickel MD, Kolb M, et al. Self-gated 4D-MRI of the liver: Initial clinical results of continuous multiphase imaging of hepatic enhancement. *J Magn Reson Imaging*. 2018;47(2):459-67.
- 12 Rueckel J, Kunz WG, Hoppe BF, Patzig M, Notohamiprodjo M, Meinel FG, et al. Artificial Intelligence Algorithm Detecting Lung Infection in Supine Chest Radiographs of Critically Ill Patients With a Diagnostic Accuracy Similar to Board-Certified Radiologists. *Crit Care Med*. 2020.



Gerwin Schmidt



Mike Notohamiprodjo

## Contact

Prof. Mike Notohamiprodjo  
Deputy Managing Partner  
DIE RADIOLOGIE  
Sonnenstr. 17  
80331 München  
Germany  
Phone: +49 (89) 550596-0  
Mike.Notohamiprodjo@die-radiologie.de