

MRI for prostate and gynecological brachytherapy is here to stay

Firas Mourtada, Ph.D.¹; Daniel G. Petereit, M.D.²; Sushil Beriwall, M.D.³; Joann I. Prisciandaro, Ph.D.⁴

¹Helen F. Graham Cancer Center & Research Institute, Christiana Care Health System, Newark, DE, USA

²Rapid City Regional Cancer Care Institute, Rapid City, SD, USA

³UPMC Hillman Cancer Center, Pittsburgh, PA, USA

⁴Department of Radiation Oncology, University of Michigan, Ann Arbor, MI, USA

Key points

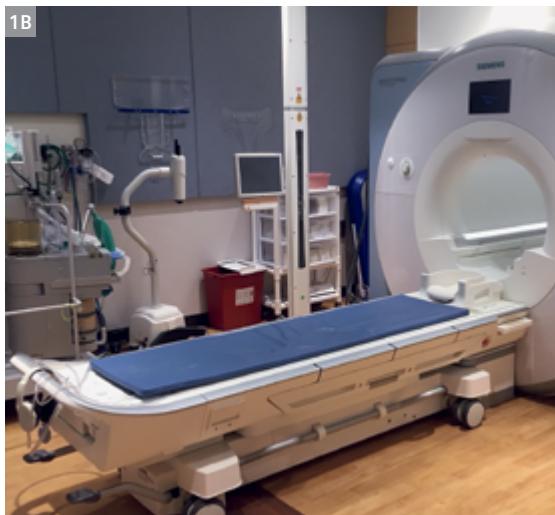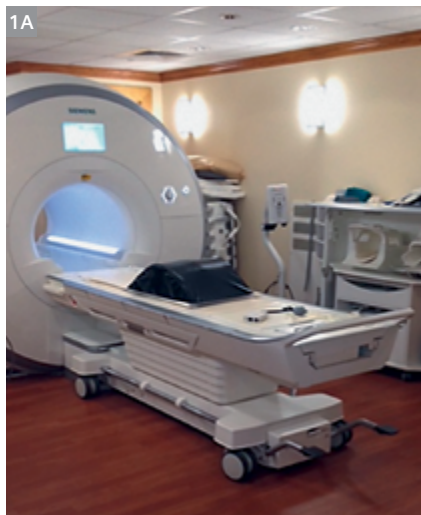In this article, we describe the status of MRI utilization¹ for both gynecological and prostate cancer radiotherapy treatments using HDR brachytherapy in the United States. The current clinical evidence has demonstrated MRI should be incorporated in the standard of care for all gynecological and prostate brachytherapy patients. However, unlike Europe, in the U.S. we continue to look for ways to adapt MRI within our constraints (initial costs and reimbursement), and to provide our patients the best MRI based approach to manage their disease effectively and safely. We share what we have learned from our collective experiences.

Introduction

Brachytherapy has a long history in cancer therapy, with its initial applications performed shortly after the discovery and isolation of radium from pitchblende

by Pierre and Marie Curie in 1898. Two-dimensional radiographic films were used for treatment planning prior to the inception of 3D volumetric imaging in the 1970s. In particular, computed tomography (CT) and transrectal ultrasound (TRUS) were first implemented for several disease sites. More recently, magnetic resonance imaging (MRI) has demonstrated superior soft tissue contrast and spatial resolution, a clear advantage for accurate treatment planning using brachytherapy sources. Over the last few years, the use of MRI for patient selection and treatment planning has gained significant momentum with growing clinical experience. In the United States, MRI utilization for cervical cancers has increased from 2% in 2007 to 34% in 2014 [1]. MRI is superior to ultrasound and CT for visualizing intra-prostatic tumors and evaluating macroscopic extracapsular extension and/or seminal vesicle invasion that would preclude brachytherapy as a monotherapy option. In 2012, the American Brachytherapy Society (ABS) developed guidelines to use MRI for disease staging and treatment planning in “clinically relevant circumstances” by “experienced teams” [2]. In 2017 The American Association of Physicists in Medicine (AAPM) approved the formation of Task Group 303 – MRI Guidance in HDR Brachytherapy – Considerations from Simulation to

¹The product is not commercially available. Radiotherapy where MR data is the only imaging information is ongoing research. The concepts and information presented in this article are based on research and are not commercially available. Its future availability cannot be ensured. Not for clinical use.



1 (1A) MAGNETOM Aera (1.5T) Tim Dockable table at the Christiana Care Health System community hospital, Newark, DE, USA. (1B) Wide-bore MAGNETOM Skyra (3T) MRI with the Tim Dockable table at the University of Michigan, Ann Arbor, MI, USA.

Treatment – in response to the growing interest in MRI guided brachytherapy. The committee consists of brachytherapy physicists and clinicians from academic and community cancer centers, as well as MRI industry representatives. These experts have been charged with developing recommendations and guidelines for the commissioning, clinical implementation, and on-going quality assurance specifically for MRI-based prostate and gynecological HDR brachytherapy. Herein we present on key evidence to support the statement that MRI is here to stay for brachytherapy.

MRI future for prostate cancer brachytherapy

A special issue in the *Brachytherapy Journal* was recently published on the treatment of prostate cancer, including several pivotal articles on the use of MRI in the diagnosis, treatment, response assessment, and “the management of recurrent disease in the setting of rising prostate-specific antigen levels after low-dose-rate (LDR) or high-dose-rate (HDR) brachytherapy” [3]. The goal of the issue was to “bend the brachytherapy curve” by optimizing the therapeutic ratio through the utilization of MRI [3]. To highlight a few articles, Venkatesan *et al.* presented an overview of multi-parametric MRI (mp-MRI) techniques for high-resolution of prostate anatomy. They discussed the pros and cons of using an endorectal coil (ERC) with emerging evidence that it may not be necessary when using a 3T MRI [4]. In a second paper from Venkatesan *et al.*, they summarized prostate cancer findings, tumor staging, and presented an overview of the Prostate Imaging Reporting and Data System (PIRADS). In addition, they presented MRI findings observed in the post-therapy setting, including sites of recurrence, and MRI concepts pertinent to successful salvage brachytherapy [5]. Pugh and Pokharel reviewed MRI utilization in prostate brachytherapy and postulated future pathways for MRI integration. They detailed several advantages of MRI integration including “superior intra-prostatic soft tissue resolution, localization of the dominant intra-prostatic lesion, and improved anatomic visualization of the prostate apex, prostate-bladder interface, prostate-rectal interface, neurovascular bundles, and genitourinary diaphragm” [6].

LDR and HDR brachytherapy using TRUS or CT are commonly used in practice today. However, while the therapeutic ratio is largely favorable, ongoing dilemmas include ‘cold’ base and ‘hot’ spots in the apex, urethral strictures, bladder dysfunction, erectile dysfunction, and biochemical recurrences. The Androgen Suppression Combined with Elective Nodal and Dose Escalated Radiation Therapy (ASCENDE-RT) trial demonstrated an unequivocal improvement in biochemical control rates

for intermediate to high risk patients treated with an LDR prostate brachytherapy boost, but with grade 3 late GU toxicities of 18.4% – half of which were urethral strictures, many of which resolved over time with a prevalence rate of 8.6% at five years [7].

MRI future for gynecological cancers brachytherapy

For gynecological cancer, the International Commission of Radiation Units and Measurements (ICRU) has recently updated their classical 1985 report 38 [8] with ICRU report 89 [9]. The updated report provides an excellent description of current volumetric imaging (MRI and CT) for the cervix with the addition of 4D adaptive target concepts and updated radiobiology and recommended dose volume histogram (DVH) parameters for target and organs-at-risk (OAR) [9]. Some of the ICRU updated guidelines were based on the Groupe Européen de Curie thérapie – European Society for Radiotherapy & Oncology (GEC-ESTRO) recommendations. GEC-ESTRO has taken the lead and recognized volumetric imaging for brachytherapy treatment planning for cervical cancer, with the formation of the gynecological (GYN) GEC-ESTRO work group. Over the last 18 years their work group has published a series of recommendations to assist in the standardization of image-based brachytherapy treatment planning. This has included the definition of a common language and means of delineating the target volumes (i.e., Intermediate Risk-CTV and High Risk-CTV for the definitive treatment of cervical cancer), discussions on issues related to applicator reconstruction, and suggestions on the appropriate MR imaging sequences utilized for treatment planning [10–13]. The outcome data with MRI-based planning is excellent in limited and well responding tumors demonstrating improved local control and decrease morbidities in comparison to historical 2D planning methods as demonstrated by the completed EMBRACE I (An International study on MRI-guided Brachytherapy in locally Advanced Cervical cancer) multicenter protocol [14]. Key findings include an improvement in local control by 10% when comparing limited to advanced image based brachytherapy planning for large tumors (three year local failures rates of 2%, 7–9%, 21–25% for stages IB, IIB, IIIB, respectively), and ongoing, detailed quality of life analysis of vaginal, bladder, and bowel morbidity [15, 16]. The late rectal morbidity appears to be lower when $D_{2cc} \leq 65$ Gy versus ≥ 75 Gy, even though the HR CTV is dose escalated with Image Guided Advanced Brachytherapy (IGABT) [17]. Based on the positive outcomes from the RetroEMBRACE and EMBRACE I protocols, the EMBRACE research group has initiated the EMBRACE II protocol with the intention of

using state of the art treatment techniques for external beam and brachytherapy to enhance local, nodal, and systemic control while minimizing normal tissue toxicity [17].

How to navigate challenges transitioning to MRI-based brachytherapy

Often, we have the preconceived notion that MRI-based brachytherapy is resource intensive. Harkenrider *et al.* recently described their experience with transitioning from CT-based to MRI-based brachytherapy for cervical cancer at Loyola University Medical Center, Maywood, IL, USA) [18]. They suggest that the key to success is a multidisciplinary team approach involving radiation oncology, gynecologic oncology, radiology, and anesthesia. Once the 'big picture' was identified (e.g., MR applicator choice, dose fractionation schedule), they optimized their workflow to best suit their clinic [18].

MRI utilization for brachytherapy can be considered in three fundamental categories: pre-planning target diagnosis; implant guidance; MR-based treatment planning after implant insertion; and MRI-guided implant insertion and treatment planning. With this in mind, the basic requirements for the successful implementation of MRI in brachytherapy include:

1. Access to an MRI scanner (e.g., a diagnostic or dedicated radiation oncology simulator),
2. MR conditional ancillary equipment (e.g., leg straps, immobilization devices, transport table), and
3. an optimized clinical workflow, which involved input from all members of the multidisciplinary team involved in the patient's care.

Additionally, when integrating MR into brachytherapy, it is imperative to review and update the clinical workflow initially and on a periodic basis as your program matures. Considerations for MRI safety must also be a priority for a successful program with ongoing staff training to ensure patient and hardware safety.

At each of our four respective institutions, MRI has been utilized in the care of brachytherapy patients. Our departments are equipped with either the Siemens Healthineers MAGNETOM Aera (1.5T) or MAGNETOM Skyra (3T) MRI scanners (Figures 1A and 1B, respectively). Additionally, to minimize patient motion between planning simulation and treatment, MR-conditional transport systems, such as the Siemens Healthineers Tim Dockable table (Fig. 1C) and the Symphony™ (Qfix, Avondale, PA, USA) patient transport system²,

²The information shown herein refers to products of 3rd party manufacturer's and thus are in their regulatory responsibility. Please contact the 3rd party manufacturer for further information.



1C The Tim Dockable table detached from the Siemens Healthineers MRI simulator.



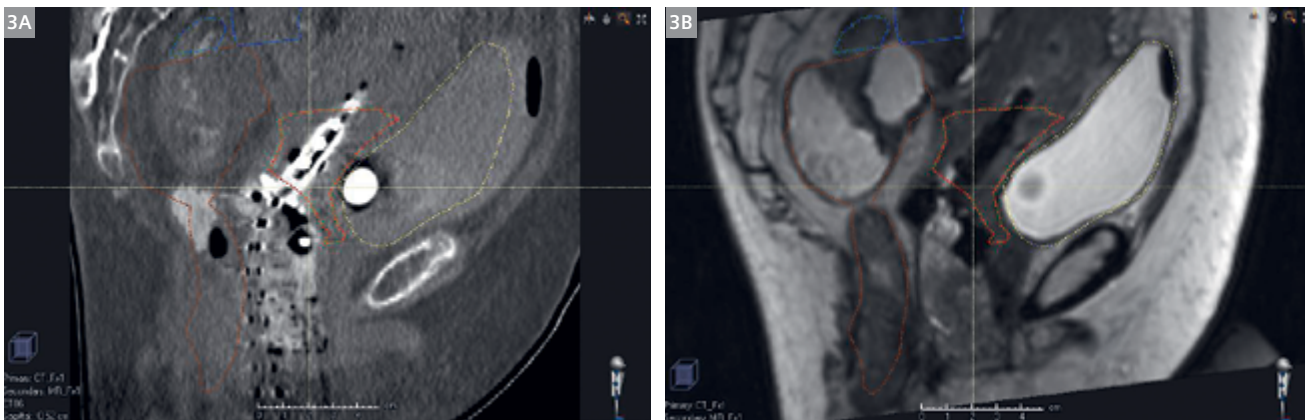
2 Example of a patient transport system (Symphony Patient Transport System, Qfix, Avondale, PA, USA) that can easily move the patient from our Siemens Healthineers Tim Dockable table for the MAGNETOM Aera 1.5T scanner with minimal motion of applicator or needles.
(A) Symphony patient trolley-integrated air pump, two batteries, and adjustable pillars.
(B) Symphony Brachytherapy Transfer Device and leg extension. All devices are MR Conditional.

are being utilized (Fig. 2). However, each institutions approach to MR guided brachytherapy differs based on our resources, time, and financial constraints.

At one community-based cancer center (Helen F. Graham Cancer Center, Newark, DE, USA), for cervical cancer patients, applicator (plastic only) insertion is performed in a prep room that has OR lights and MR safe anesthesia equipment, adjacent to the MR scanner in our Radiology department. In the case of interstitial implants, diagnostic MR images are made available at the time of implant to assist in guiding needle/catheter placement. In general, the procedure starts with the patient lying supine on the Symphony patient trolley and Symphony Brachytherapy Transfer Device (Fig. 2). Once applicator insertion is complete using non-MR compatible stirrups, the patient is transferred onto the Siemens Healthineers Tim Dockable MR table. The patient is then transferred to the MAGNETOM Aera MRI scanner (Fig. 1A), and the 18-channel body coil (attached to Qfix Insight MR Bridge with Body Coil holder) is positioned about 1 cm above the patient's pelvis. MR scout images are taken (sagittal and coronal) to allow the physician to review the applicator placement quality, and if needed, make minor adjustments in the MR vault prior to the acquisition of the final T1- and T2-weighted 3D SPACE image protocols (< 10 min). Once the MR scans are complete, the patient is transferred back to the Symphony patient trolley and taken back to the HDR vault in Radiation Oncology. For MR-based treatment planning, the high risk clinical target volume (HR-CTV) and the organs at risk (OARs) are delineated on the T2-weighted 3D SPACE MRI dataset. MR-based planning is only performed for the first treat-

ment fraction and MR/CT rigid registration tools available in Raystation v 5.0 (Raysearch Labs, Stockholm, Sweden) are used for subsequent HDR fractions planned on CT images (Fig. 3). This rigid registration relies on the Smit Sleeve location (not bony anatomy). The Smit Sleeve is clearly visible on both MR and CT and is reliable to map the MR HR-CTV onto the subsequent fraction CT. The physician can then modify the registered HR-CTV on the CT if needed. For HDR treatment planning, *solid applicator* models provided by the Oncentra planning system (Elekta Inc., Stockholm, Sweden) (Fig. 4) are used to align the applicator on MR or CT images. Based on our commissioning data, the applicator model can map the first dwell position of the source within an uncertainty of 2 mm. The OARs are contoured on CT for each fraction since CT (with contrast) is fairly accurate to contour the bladder and rectum. This workflow has been found to be efficient since the procedure starts at the MR station, saving time for patient transfer under anesthesia. The entire process, applicator insertion, MR imaging, and the HDR fraction delivery is typically completed within 90 minutes.

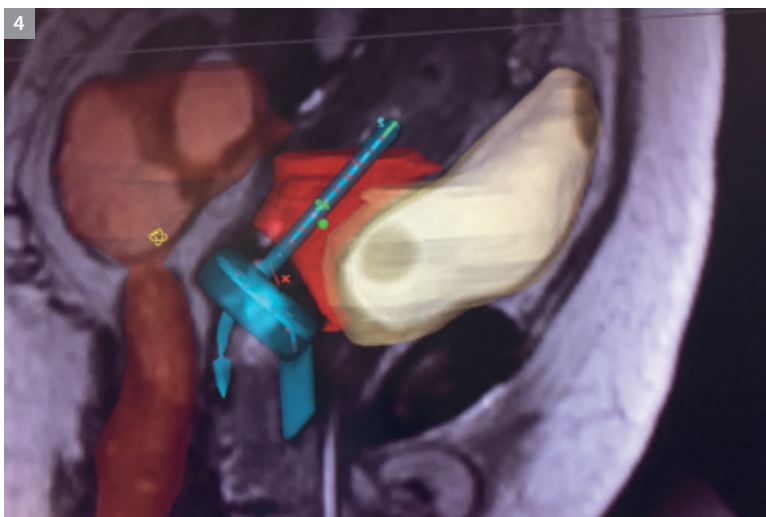
At an academic institution (University of Michigan), the extent to which we have adopted MRI-based brachytherapy varies based on treatment site and applicator. For all treatment sites, applicator insertion is performed either in a dedicated HDR suite or in an operating room. In the case of interstitial implants, diagnostic MR images are made available at the time of implant to assist in guiding needle/catheter placement. For gynecological cancers requiring cylindrical applicators (e.g., for the treatment of post-hysterectomy endometrial cancer),



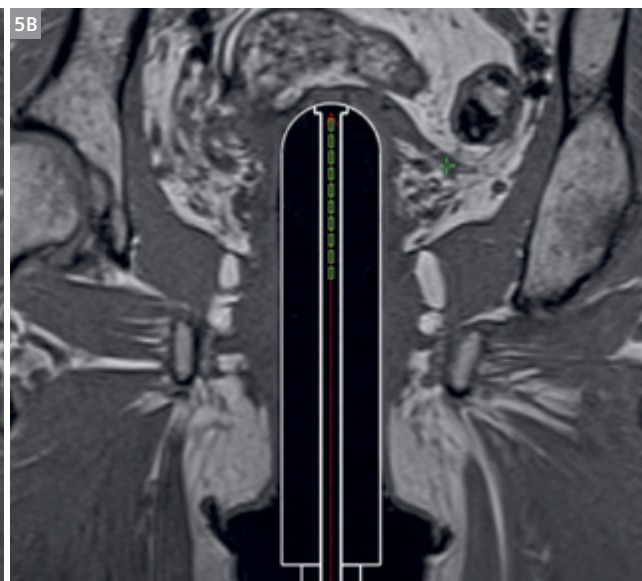
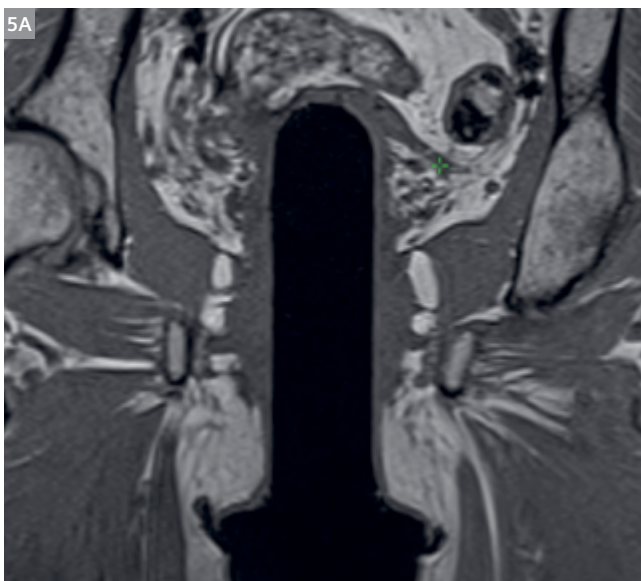
3 HR-CTV target (red dotted line) defined following rigid registration in Raystation planning system, using the Smith Sleeve for a tandem and ring gynecological case of a sixty-year-old patient with stage IV cervical cancer **(3A)** clinical standard CT pelvis protocol (Siemens Healthineers SOMATOM Sensation Open) vs. **(3B)** T2w 3D SPACE AX ISO 1.3 mm³ isotropic MRI (1.5T) MAGNETOM Aera. Coils used: Spine array coil in the Tim Dockable table and the 18-channel Body Matrix coil attached to the Qfix Insight MR Bridge with Body Coil holder. 3D distortion correction is turned on.

patients undergo MR (Fig. 1B) only planning simulations and a T1-weighted (VIBE) coronal image is used for treatment planning [19]. To expedite planning, an applicator model is overlaid on the outline of the applicator as visualized on the MR images (i.e., observed as a signal void) (Fig. 5). In the case of patient's treated with a ring and tandem applicator (e.g., for cervical cancer), we are still in transition to MR only planning simulations, following the purchase of new plastic brachytherapy applicators. At present, both CT and MR simulations are acquired for each treatment fraction, and rigidly registered. The HR-CTV is delineated on a T2-weighted MRI dataset, and the contour is then copied to the CT scan. Treatment plans are generated using the CT planning simulation.

In the future, we intend to transition to MR-only planning simulations, and in an attempt to reduce planning time (i.e., for subsequent treatment fractions), use deformable image registration to automate the contouring of the HR CTV and OARs [20]. For advanced gynecological cancers requiring an interstitial implant, both CT and MR planning simulations are acquired. The HR CTV is defined on a T2-weighted MRI and copied to the rigidly registered CT dataset for treatment planning. Lastly, in the case of prostate HDR brachytherapy, which is restarting following a three-year hiatus, the initial intent is to have diagnostic MR images available at the time of the US guided procedure to assist with dose escalation to intraprostatic lesions.



4 In Oncentra HDR treatment planning system, the tandem and ring *solid applicator* model is accurately registered (within 2 mm uncertainty) to the 3D MR images of patient anatomy shown Figure 3. Images obtained using T2w 3D SPACE AX ISO 1.3 mm³ isotropic MRI (1.5T) MAGNETOM Aera with spine array coil and 18-channel body coils, and 3D distortion correction is turned on.



5 (5A) Paracoronar 3D T1-weighted (VIBE) MRI of a patient with a plastic MR conditional vaginal cylinder in place. (5B) Alignment of the applicator model over the signal void representing the perimeter of the applicator for treatment planning purposes.

Conclusions

MR guided brachytherapy has strong supporting evidence that it will further improve the therapeutic ratio for prostate and gynecologic malignancies, and is feasible to implement in established brachytherapy practices. We believe more radiation oncology centers will and should begin implementing MR into their brachytherapy procedures. We look forward to seeing the future publication of the AAPM TG-303 report for further recommendations to aid brachytherapists in the expansion of MRI utilization in the United States for brachytherapy.

References

- Grover S, H.M., Cho LP, Erickson B, Small C, Small W Jr, Viswanathan AN, Image Guided Cervical Brachytherapy: 2014 Survey of the American Brachytherapy Society. *International Journal of Radiation Oncology Biology Physics*, 2016. 94(3): p. 598-604.
- Viswanathan, A.N., et al., American Brachytherapy Society consensus guidelines for locally advanced carcinoma of the cervix. Part II: high-dose-rate brachytherapy. *Brachytherapy*, 2012. 11(1): p. 47-52.
- Frank, S.J. and F. Mourtada, Bending the slope of the brachytherapy curve: Magnetic resonance imaging-assisted radiosurgery for the treatment of prostate cancer. *Brachytherapy*, 2017. 16(4): p. 657-658.
- Venkatesan, A.M., et al., Prostate magnetic resonance imaging for brachytherapists: Diagnosis, imaging pitfalls, and post-therapy assessment. *Brachytherapy*, 2017. 16(4): p. 688-697.
- Venkatesan, A.M., et al., Prostate magnetic resonance imaging for brachytherapists: Anatomy and technique. *Brachytherapy*, 2017. 16(4): p. 679-687.
- Pugh, T.J. and S.S. Pokharel, Magnetic resonance imaging in prostate brachytherapy: Evidence, clinical end points to data, and direction forward. *Brachytherapy*, 2017. 16(4): p. 659-664.
- Rodda S, T.S., Morris J, Keyes M, Halperin R, Pai H, McKenzie M, Duncan G, Morton, G, Hamm J, Murray N, ASCENDE-RT: An Analysis of Treatment-Related Morbidity for a Randomized Trial Comparing a Low-Dose-Rate Brachytherapy Boost with a Dose-Escalated External Beam Boost for High- and Intermediate-Risk Prostate Cancer *International Journal of Radiation Oncology Biology Physics*, 2017. 98(2): p. 286-295.
- ICRU Report No. 38, Dose and Volume Specification for Reporting Intracavitary Therapy in Gynecology. 1985, International Commission of Radiation Units and Measurements.
- ICRU Report No. 89, Prescribing, Recording, and Reporting Brachytherapy for Cancer of the Cervix. *Journal of the ICRU*, 2013. 13(1).
- Haie-Meder, C., et al., Recommendations from Gynaecological (GYN) GEC-ESTRO Working Group (I): concepts and terms in 3D image based 3D treatment planning in cervix cancer brachytherapy with emphasis on MRI assessment of GTV and CTV. *Radiother Oncol*, 2005. 74(3): p. 235-45.
- Potter, R., et al., Recommendations from gynaecological (GYN) GEC ESTRO working group (II): concepts and terms in 3D image-based treatment planning in cervix cancer brachytherapy-3D dose volume parameters and aspects of 3D image-based anatomy, radiation physics, radiobiology. *Radiother Oncol*, 2006. 78(1): p. 67-77.
- Hellebust, T.P., et al., Recommendations from Gynaecological (GYN) GEC-ESTRO Working Group: considerations and pitfalls in commissioning and applicator reconstruction in 3D image-based treatment planning of cervix cancer brachytherapy. *Radiother Oncol*, 2010. 96(2): p. 153-60.
- Dimopoulos, J.C., et al., Recommendations from Gynaecological (GYN) GEC-ESTRO Working Group (IV): Basic principles and parameters for MR imaging within the frame of image based adaptive cervix cancer brachytherapy. *Radiother Oncol*, 2012. 103(1): p. 113-22.
- Potter, R., et al., The EMBRACE II study: The outcome and prospect of two decades of evolution within the GEC-ESTRO GYN working group and the EMBRACE studies. *Clinical & Translational Radiation Oncology*, 2018. In Press.
- Sturdza, A., et al., Image guided brachytherapy in locally advanced cervical cancer: Improved pelvic control and survival in RetroEMBRACE, a multicenter cohort study. *Radiother Oncol*, 2016. 120(3): p. 428-433.
- Fokdal, L., et al., Image guided adaptive brachytherapy with combined intracavitary and interstitial technique improves the therapeutic ratio in locally advanced cervical cancer: Analysis from the retroEMBRACE study. *Radiother Oncol*, 2016. 120(3): p. 434-440.
- Mazeran, R., et al., Dose-volume effect relationships for late rectal morbidity in patients treated with chemoradiation and MRI-guided adaptive brachytherapy for locally advanced cervical cancer: Results from the prospective multicenter EMBRACE study. *Radiother Oncol*, 2016. 120(3): p. 412-419.
- Harkenrider, M.M., et al., How one institution overcame the challenges to start an MRI-based brachytherapy program for cervical cancer. *J Contemp Brachytherapy*, 2017. 9(2): p. 177-186.
- Owringi, A.M., et al., Clinical implementation of MR-guided vaginal cylinder brachytherapy. *J Appl Clin Med Phys*, 2015. 16(6): p. 490-500.
- Chapman, C.H., et al., Deformable image registration-based contour propagation yields clinically acceptable plans for MRI-based cervical cancer brachytherapy planning. *Brachytherapy*, 2018. In Press.



Joann I. Prisciandaro,
Ph.D.



Sushil Beriwall,
M.D.



Daniel G. Petereit,
M.D.



Firas Mourtada,
Ph.D.

Contact

Firas Mourtada, Ph.D.
Chief of Clinical Physics
Radiation Oncology, Ste 1152
Helen F. Graham Cancer Center &
Research Institute
4701 Ogetown-Stanton Rd
Christiana Care Health System
Newark, DE 19713, USA
Tel: +1 302-623-4691
Fax: +1 302-623-4547
fmourtada@christianacare.org

Not for distribution in the US

On account of certain regional limitations of sales rights and service availability, we cannot guarantee that all products included in this brochure are available through the Siemens sales organization worldwide. Availability and packaging may vary by country and is subject to change without prior notice. Some/All of the features and products described herein may not be available in the United States.

The information in this document contains general technical descriptions of specifications and options as well as standard and optional features which do not always have to be present in individual cases, and which may not be commercially available in all countries.

Due to regulatory reasons their future availability cannot be guaranteed. Please contact your local Siemens organization for further details.

Siemens reserves the right to modify the design, packaging, specifications, and options described herein without prior notice. Please contact your local Siemens sales representative for the most current information.

Note: Any technical data contained in this document may vary within defined tolerances. Original images always lose a certain amount of detail when reproduced.

Siemens Healthineers Headquarters

Siemens Healthcare GmbH
Henkestr. 127
91052 Erlangen, Germany
Phone: +49 9131 84-0
siemens-healthineers.com