

The information presented in the case report is for illustration only and is not intended to be relied upon by the reader for instruction as to the practice of medicine. Any health care practitioner reading this information is reminded that they must use their own learning, training and expertise in dealing with their individual patients.

On account of certain regional limitations of sales rights and service availability, we cannot guarantee that all products included in this brochure are available through the Siemens Healthineers sales organization worldwide. Availability and packaging may vary by country and is subject to change without prior notice. Some/All of the features and products described herein may not be available in the United States.

The information in this document contains general descriptions of the technical options available and may not always apply in individual cases. Siemens Healthineers reserves the

right to modify the design and specifications contained herein without prior notice. Please contact your local Siemens Healthineers sales representative for the most current information.


The customers are employed by an institution that receives financial support from Siemens Healthineers for collaborations.

Note: Any technical data contained in this document may vary within defined tolerances. Original images always lose a certain amount of detail when reproduced. The products/features and/or service offerings (here mentioned) are not commercially available in all countries and/or for all modalities. If the services are not marketed in countries due to regulatory or other reasons, the service offering cannot be guaranteed. Please contact your local Siemens Healthineers organization for further details.

---

#### Siemens Healthineers Headquarters

Siemens Healthineers AG  
Siemensstr. 3  
91301 Forchheim, Germany  
Phone: +49 9191 18-0  
[siemens-healthineers.com](https://www.siemens-healthineers.com)



**The Jikei University School of Medicine  
in Tokyo, Japan**

## **Game-changer in treatment of juvenile nasopharyngeal angiofibroma**

Combined embolization and surgery  
in the ARTIS pheno Hybrid OR

[siemens-healthineers.com/neurosurgery](https://www.siemens-healthineers.com/neurosurgery)

# Introduction

The Jikei University School of Medicine is a private university located in Minato, Tokyo, Japan. With 2,700 beds and 7,500 outpatients per day, The Jikei University Hospitals is one of the largest educational hospital systems in the country.

Prof. Yuichi Murayama, MD, is Chairman of the Department of Neurosurgery. In addition to imaging and dose, his research interests include fibroblasts, thermoreversible gelation polymers, coils, and aneurysms. His numerous publications distinguish him as a leading expert in the field of neurosurgery.

Issei Kan, MD, is a neurosurgeon and neuro- and endovascular surgeon at the Department of Neurosurgery at The Jikei University School of Medicine.

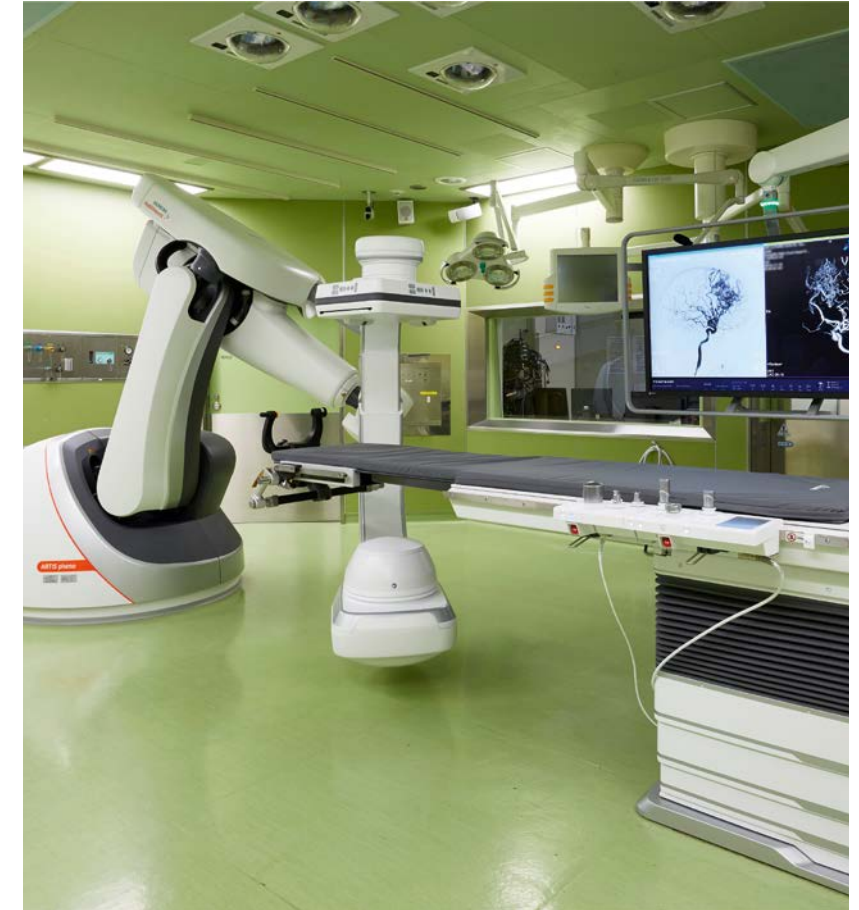
Kazuhiro Omura, MD, is an ear, nose, and throat surgeon at the Department of Otolaryngology at The Jikei University School of Medicine.



# OR setting

The Jikei University School of Medicine has three Hybrid ORs:

- ARTIS pheno robotic imaging system with ARTIS multi-tilt table
- ARTIS pheno robotic imaging system with Getinge Maquet Magnus table
- Artis Q biplane imaging system with ARTIS multi-tilt table

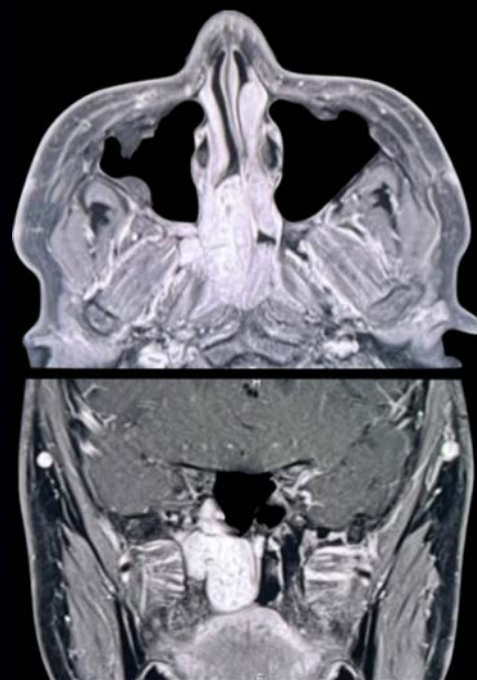


# Case and procedure description

A 15-year old teenager suffered from chronic nasal congestion. Magnetic resonance imaging showed a nasal lesion of about 3 cm in diameter located at the right sphenoid sinus extending to the pterygopalatine fossa. The patient was diagnosed with juvenile nasopharyngeal angiofibroma (JNA), a rare benign tumor. Surgical removal is the treatment of choice for JNAs, so a transnasal endoscopic resection was scheduled for this patient.

Because of the high vascularity of the tumor, the ear, nose, and throat (ENT) surgeon teamed up with Dr. Kan, an endovascular neurosurgeon. Since a recent study revealed that the amount of bleeding can be reduced depending on the remaining nutrient vessels after preoperative embolization<sup>1</sup>, they decided to perform an embolization of the main feeders of the tumor prior to surgical resection.

<sup>1</sup> Maeda M, Omura K, Kan I, et al. Application of Digital Subtraction Angiography in Predicting the Outcomes of Intraoperative Hemorrhage of Juvenile Nasopharyngeal Angiofibroma. *World Neurosurg.* 2023;178:e339-e344. <https://pubmed.ncbi.nlm.nih.gov/37480988/>

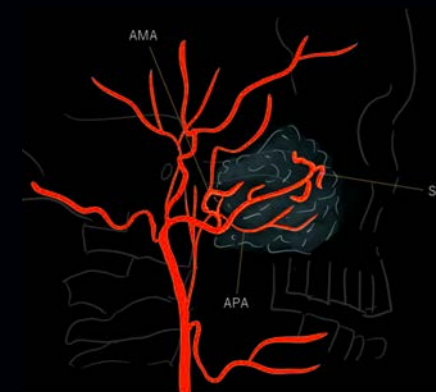

Pre-operative MRI with a 3 cm lesion in the right sphenoid sinus

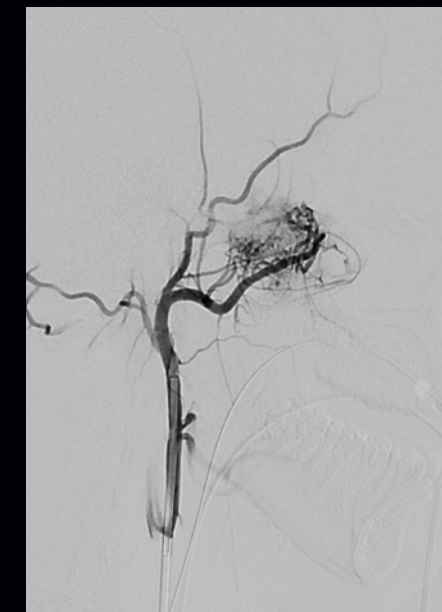
## Step 1 Pre-operative imaging

Two weeks before the surgery, the patient underwent diagnostic angiography. The surgeons identified the sphenopalatine artery as a main feeder in addition to the accessory meningeal and ascending pharyngeal arteries. Endoscopic resection by nasal access meant that the meningeal artery would be located behind the tumor during the resection.

The ENT surgeon asked for the deployment of coils as markers in the meningeal artery so that he could grab and clip it confidently. He also requested coils at the lateral border of the tumor.



Sketch of the tumor showing the three main feeders supplying the angiofibroma (AMA, accessory meningeal artery; APA, ascending pharyngeal artery, and SPA, sphenopalatine artery)



Pre-procedural angiogram of the right external carotid artery



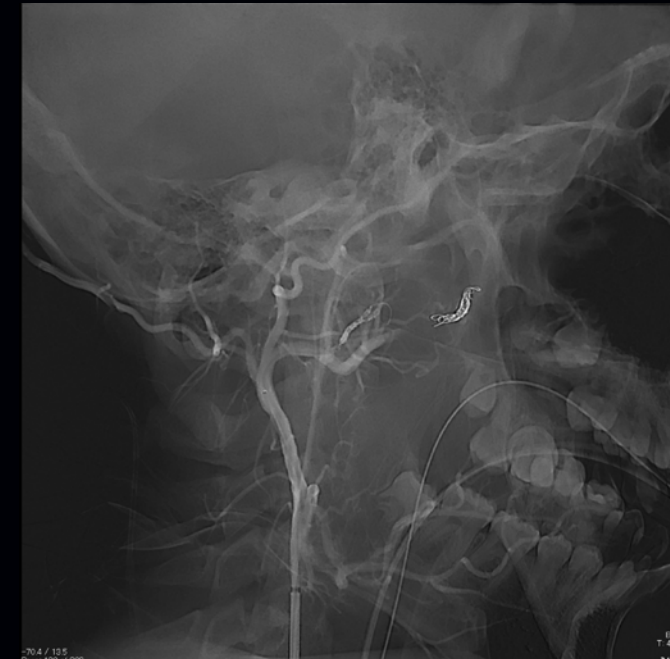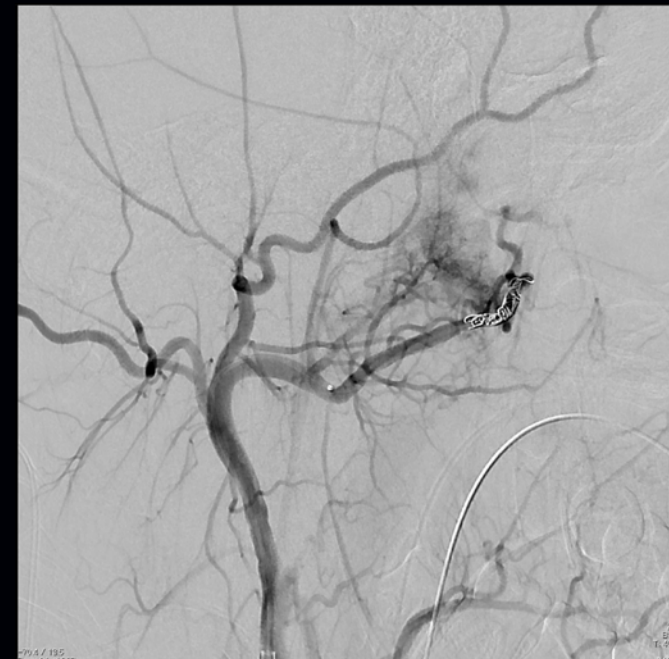## Step 2

# Embolization

The embolization was scheduled right before the resection. Thanks to the Hybrid OR setup, both procedures could be performed consecutively in the same operating room.

The endovascular neurosurgeon started the pre-operative intervention by advancing the catheter as far as possible into the sphenopalatine artery – the main feeder – and injected embolization particles that diffused into the tumor. Embolization by particles could be performed safely because the sphenopalatine artery didn't connect to facial nerves.

The interventionalist then deployed coils in the meningeal artery and in the ascending pharyngeal artery. Coils were safe to use in these arteries that are connected to nerves and to the ophthalmic artery respectively, because they don't migrate and reduce blood flow at their location.



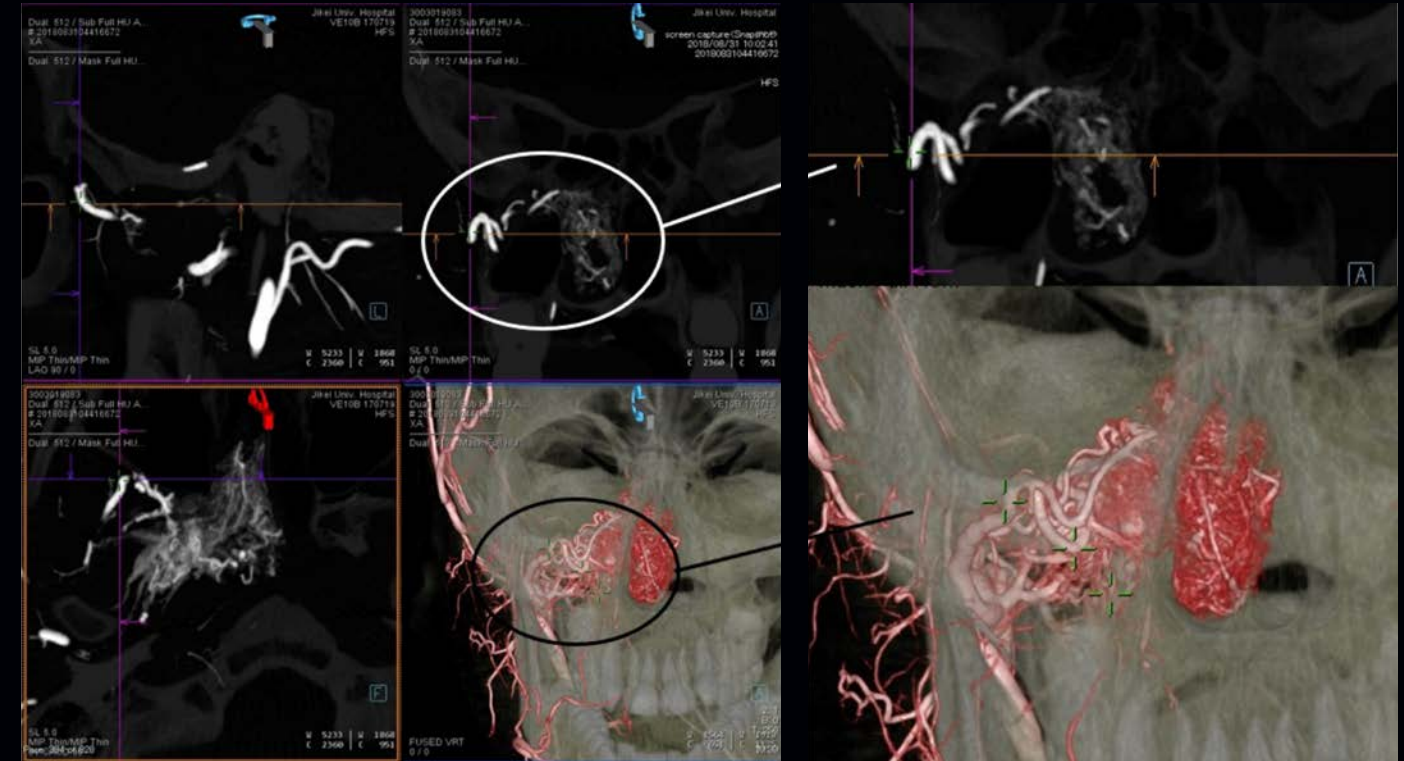
### Step 3

## Post-embolization angiography

Post-embolization angiography showed that the blood supply to the tumor was successfully interrupted.

At The Jikei University Hospital, ENT surgeons usually perform their pre-operative planning on *syngo* DynaCT slice images done with the robotic C-arm, that show bone and soft tissue, whereas endovascular neurosurgeons prefer 3D DSA images to help them understand the spatial relationship of the vessels.

The 3D marker tool proved extremely helpful for satisfying the different preferences of the two disciplines. Both the interventionalist and the ENT surgeon were able to mark the exact locations of the embolization on their preferred images, which were displayed side by side on the same screen. In addition, the 3D marker stayed at the selected location and moved along with the vessels when the images were rotated or scrolled through.



The 3D marker shows the same location on MPR and 3D images. The marker remains in place in both types of images when they're rotated or scrolled through.

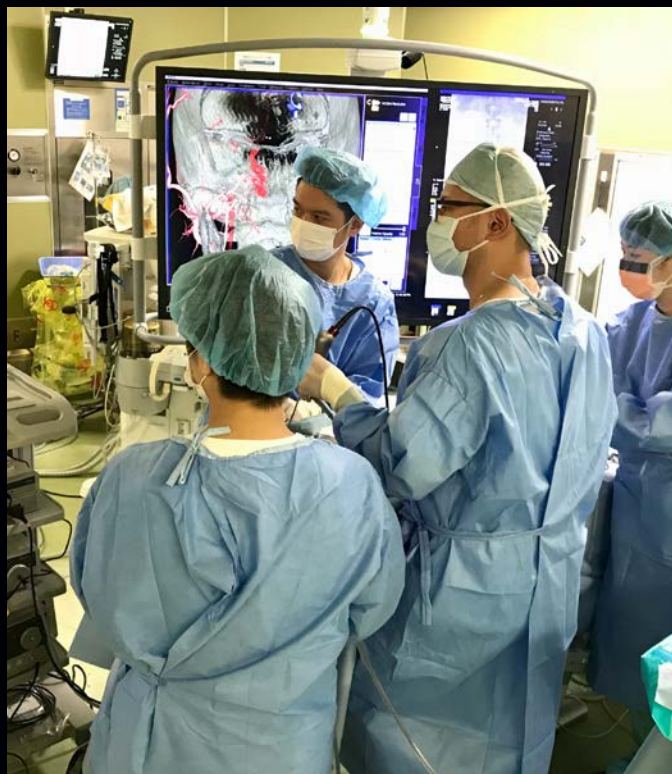#### Step 4

## Endoscopic resection

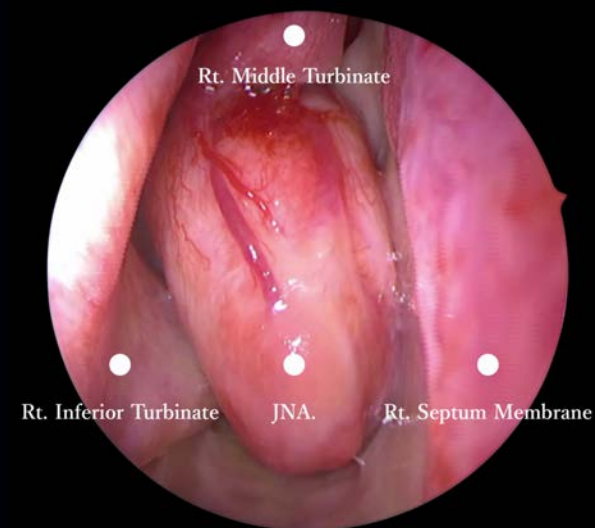
Thanks to the prior intervention and 3D markers, the ENT surgeon was able to grab and clip the tumor confidently. The endoscopic resection went well. The patient was able to leave the clinic early with a positive prognosis.

#### Advantages of the Hybrid OR

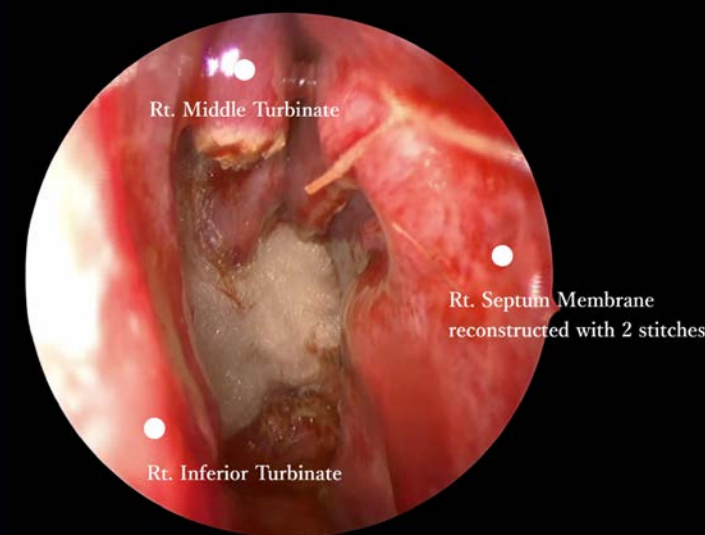
The Hybrid OR setup was very useful for the treatment of JNA, because the interventionalist and the ENT surgeon were able to treat the patient in immediate succession in the same room. The 3D images used by the interventionalist and the slice images (2D) preferred by the ENT surgeon were displayed simultaneously on the screen in the OR. The 3D marker served as a “translator” between the two medical disciplines.



The ENT surgeon and the interventionalist treat the patient in one Hybrid OR. The ARTIS pheno has been removed from the sterile field while the team is using the endoscope.



Pre-operative endoscopic view of the JNA tumor located the rt. choana with attachment to middle turbinate, nasal septum, pterygoid plate, and nasopharynx.



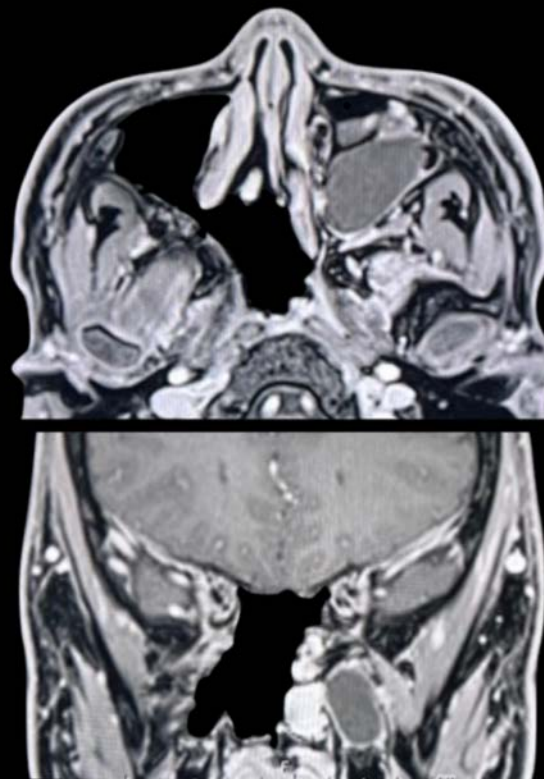
Post-operative endoscopic view of the JNA. A minimum resection was achieved. The tumor was resected with preservation of the septum membrane, inferior turbinate, and part of the middle turbinate, which enhances the physiological function of the nose.



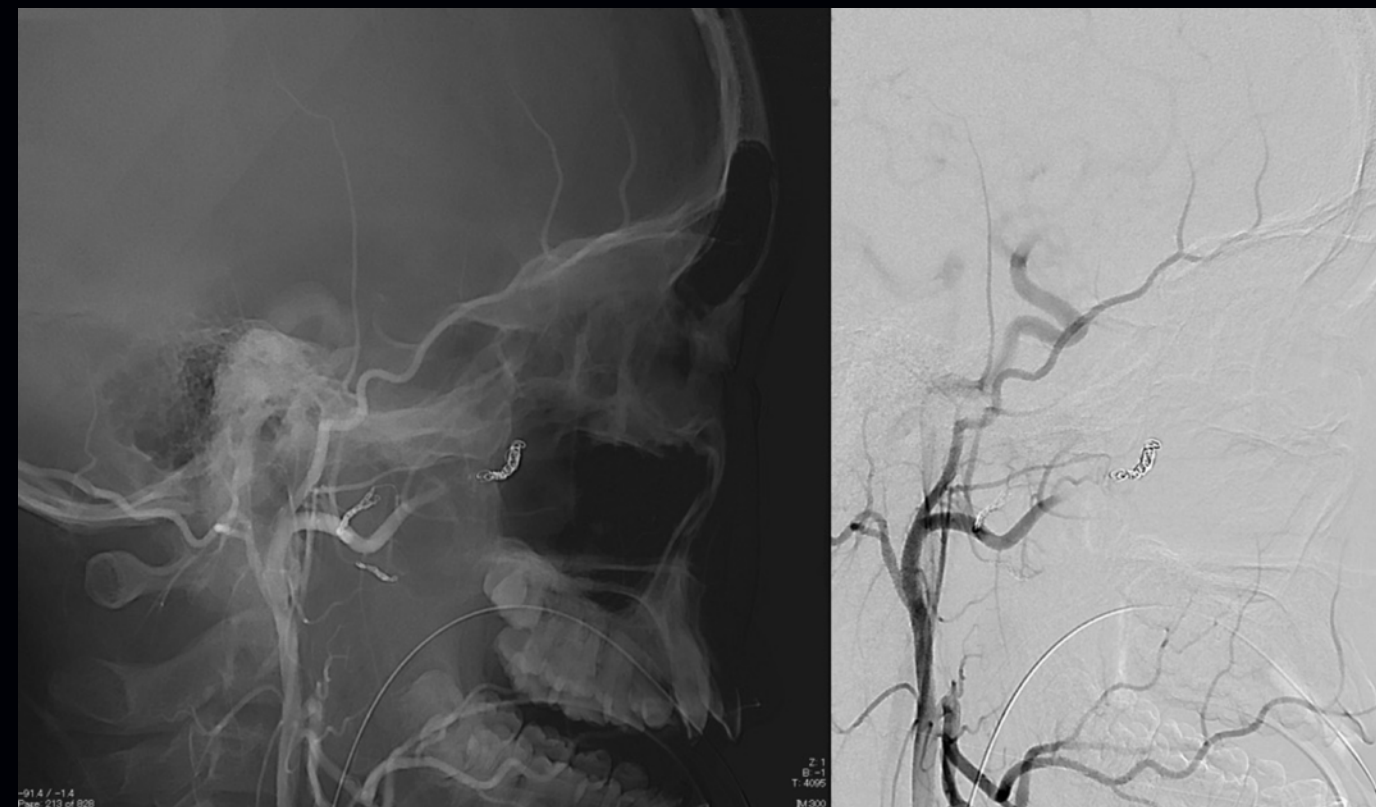## Step 5

# Post-operative imaging

The post-operative angiogram initially showed the successful obliteration of the tumor supply (right), and post-operative MR imaging three months after the operation proved that the tumor had been completely removed.

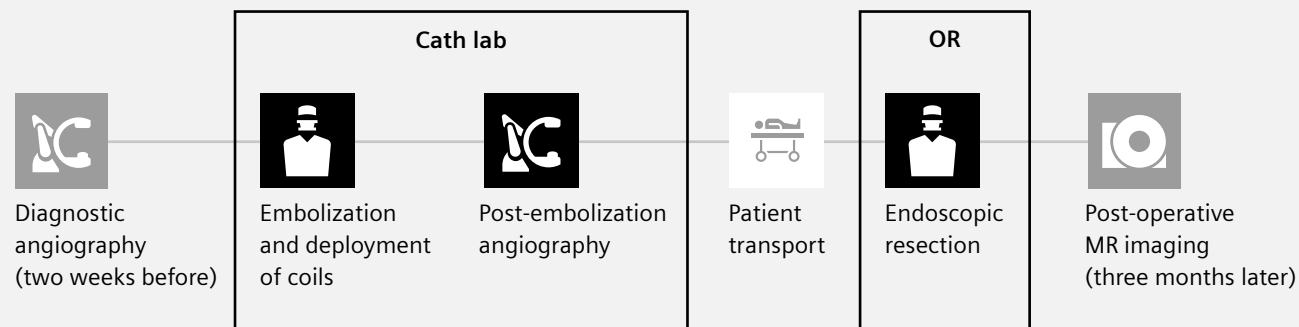


Post-operative MRI three months after the operation



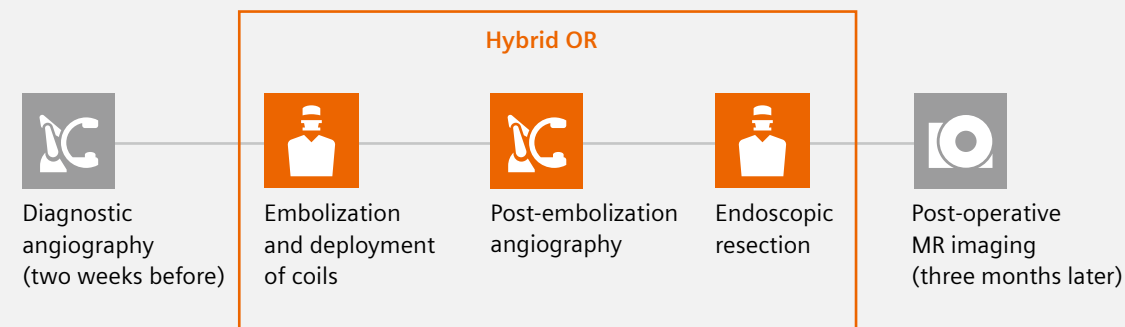
Post-procedural angiogram showing the successful obliteration of the tumor's feeders

# Workflow comparison



## Conventional workflow

Embolization and resection take place in two separate rooms. Transport from cath lab to OR required. There are also risks involved when the two procedures aren't performed immediately after each other.



## Hybrid OR workflow

Embolization and resection are performed in the Hybrid OR in a single session, eliminating the need for patient transport and the risk of delays.



## Seamless interaction in the Hybrid OR



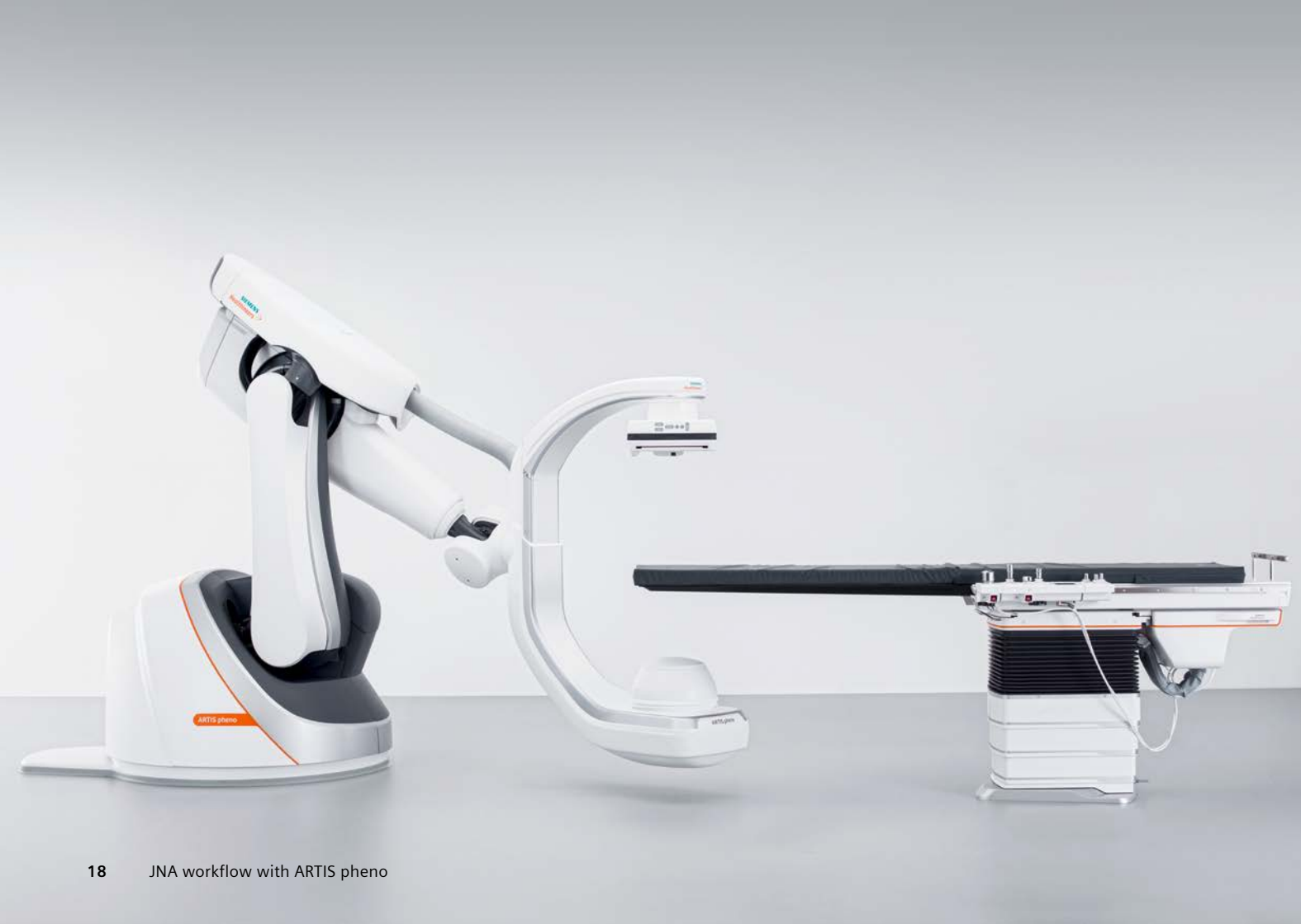**Issei Kan, MD**  
Department of Neurosurgery,  
The Jikei University School  
of Medicine, Tokyo, Japan

*“The 3D marker tool was extremely helpful, because both the neurosurgeon and the ENT surgeon were able to mark the exact locations of embolization on their preferred images, which were displayed side by side on the same screen.”*



**Kazuhiro Omura, MD**  
Department of Otolaryngology,  
The Jikei University School  
of Medicine, Tokyo, Japan

*“The Hybrid OR is very useful for the treatment of JNA. Both the interventional surgeon and myself as the ENT surgeon can operate on the patient in a single session on the same day. The large display allows us to view both slice and 3D images. The screen-split is nice, because we ENT surgeons are used to looking at 2D images, while the interventional surgeons are used to looking at volume renderings.”*



## Benefits of the robotic C-arm in the Hybrid OR

1. Precise targeting and automatic image fusion using pre-operative MRI and *syngo* DynaCT with *syngo* Fusion Package
2. Immediate intra-operative control using the *syngo* DynaCT right after tumor resection verifies a complete resection months before the post-operative MRI
3. Potential to eliminate patient transfers and reduce anesthesia time
4. Financial benefits for the hospital thanks to optimized resources and greater utilization of the Hybrid OR

### Want to know more?



For more information on our workflows, products, and solutions, please scan the QR code or visit [siemens-healthineers.com/neurosurgery](https://siemens-healthineers.com/neurosurgery)