SIEMENS Healthineers

Exostosis under weight-bearing

Multitom Rax Real3D[1] clinical case
Institute and Polyclinic for Diagnostic and Interventional Radiology, University Hospital Carl Gustav Carus, Technical University Dresden, Germany

Study ID 5aac194

[1] Option
Results from case studies are not predictive of results in other cases. Results in other cases may vary.

Clinical background and indication for Multitom Rax Real3D[1] examination

SIEMENS Healthineers

Patient
Male | *Age range* 20 - 30 years

Anamnesis
Known heterotopic exostosis on the lower legs. Deformity with progressive pain especially on the right side.

Indication for Real3D[1] examination
Diagnostic for treatment planning

Study ID 5aac670

Conventional X-ray examinations

The products/features (mentioned herein) are not commercially available in all countries. Their future availability cannot be guaranteed.
[1] Option

Multitom Rax Real3D[1] Settings

Settings for upright scan with High Quality Protocol

Tube voltage	117 kV
Current time product	304 mAs
Dose area product	1212.27 µGy·m²
Calculated value for $CTDI_{vol,32}$	9.7 mGy
Scan time	16 sec
Number of projections	314

Reconstruction settings for sectional views

Pixel size	0.4 mm
Reconstruction kernel	sharp (equivalent to Br69)
Slice thickness	0.5 mm

The products/features (mentioned herein) are not commercially available in all countries. Their future availability cannot be guaranteed.
[1] Option

Multitom Rax Real3D[1]
Diagnostic findings

SIEMENS Healthineers

Multiple heterotopic exostosis with degenerative changes in the tibiotalar joint. Medial tilting of the talus and medial rotational error of the forefoot (see on the coronal and VRT view).

For treatment, an osteotomy with rotation correction and autologous bone graft was done.

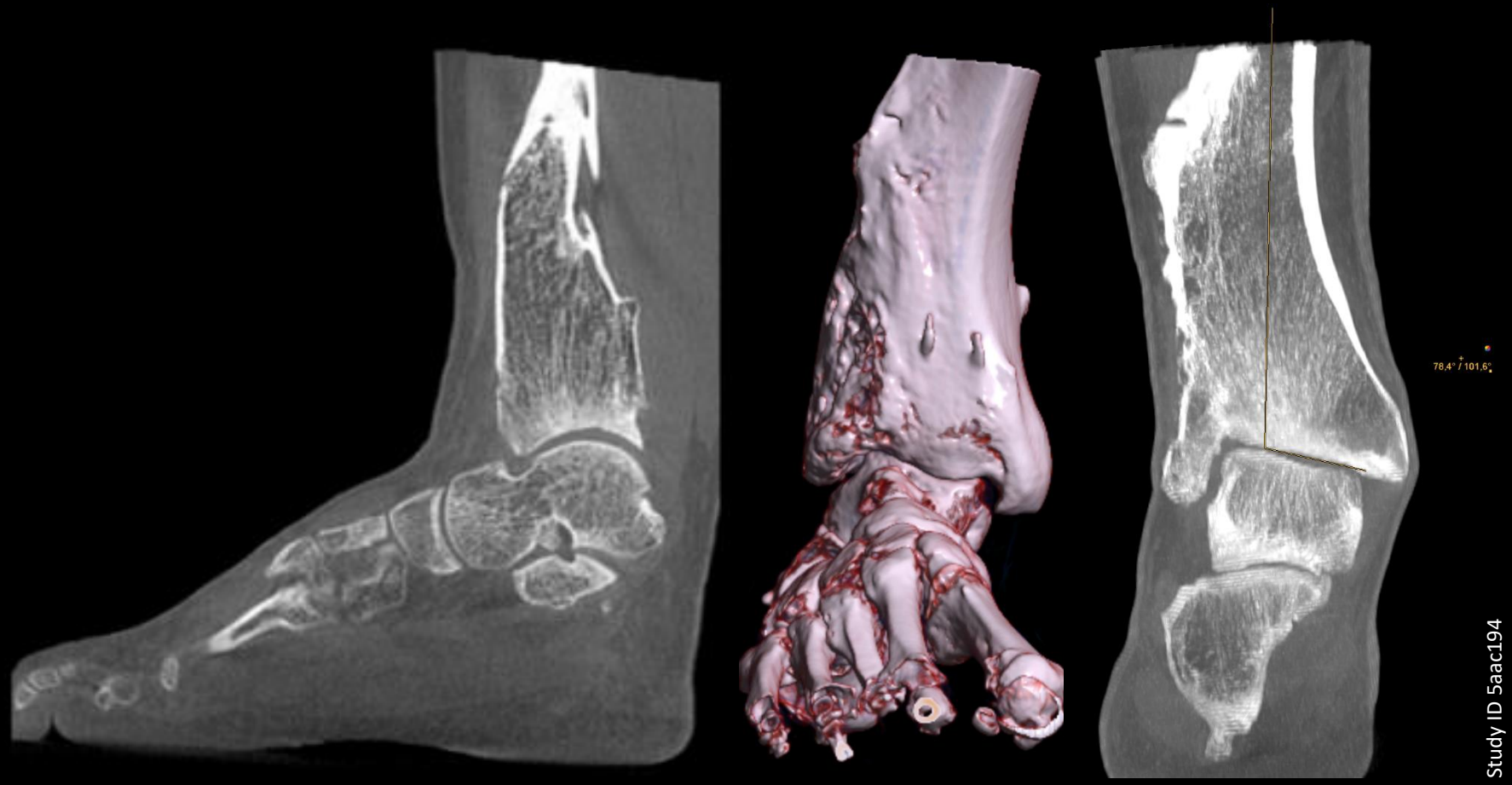

Sagittal view *VRT view* *Coronal view*

The products/features (mentioned herein) are not commercially available in all countries. Their future availability cannot be guaranteed.
[1] Option

“3D-weight-bearing imaging represents the position and relative movement of the bones within joints better than lying tomographic examinations.”[1]

Eric Langer, MD
University Hospital Carl Gustav Carus, Technical University Dresden, Germany

[1] The statements by Siemens Healthineers customers described herein are based on results that were achieved in the customer’s unique setting. Since there is no “typical“ hospital and many variables exist (e.g., hospital size, case mix, level of IT adoption) there can be no guarantee that other customers will achieve the same results.

The products/features (mentioned herein) are not commercially available in all countries. Their future availability cannot be guaranteed.

Results from case studies are not predictive of results in other cases. Results in other cases may vary.

Dr. Eric Langer is employed by an institution that receives financial support from Siemens Healthineers for collaborations.