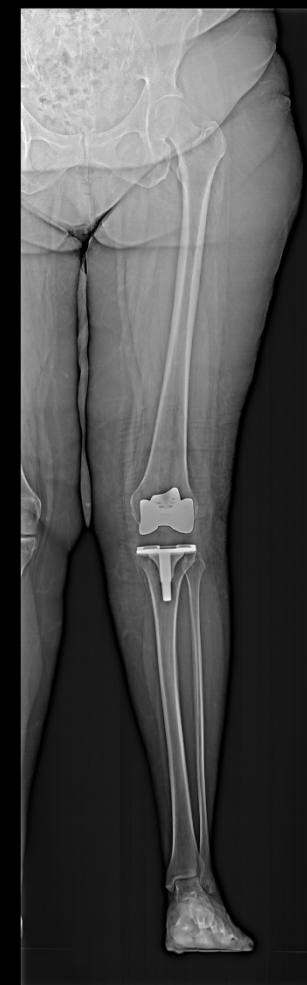

Postoperative control after inlay replacement of a knee arthroplasty

Multitom Rax True2scale Body Scan¹ clinical case
Krankenhaus der Augustinerinnen, Cologne, Germany



¹ Option, True2scale Body Scan is pending 510(k) clearance and is not yet commercially available in the US.
The products/features (mentioned herein) are not commercially available in all countries. Their future availability cannot be guaranteed.
Results from case studies are not predictive of results in other cases. Results in other cases may vary.



Study ID 5aad078

Clinical background and indication for Multitom Rax True2scale Body Scan¹

Patient

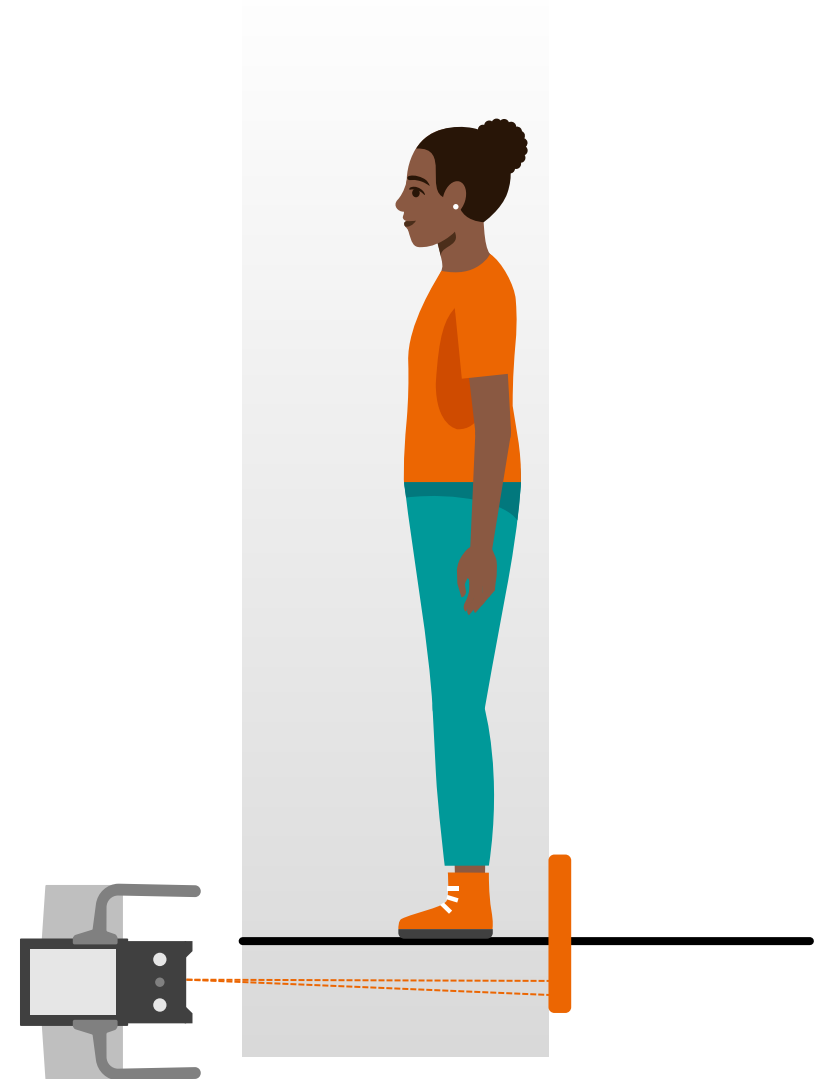
Female | Age range 50 - 60 years | BMI range 30 - 35 kg/m²

Anamnesis

Before the surgery, a multidirectional instability was shown.
Therefore, a postoperative control after inlay replacement of a total knee arthroplasty was needed.

Indication for True2scale Body Scan¹

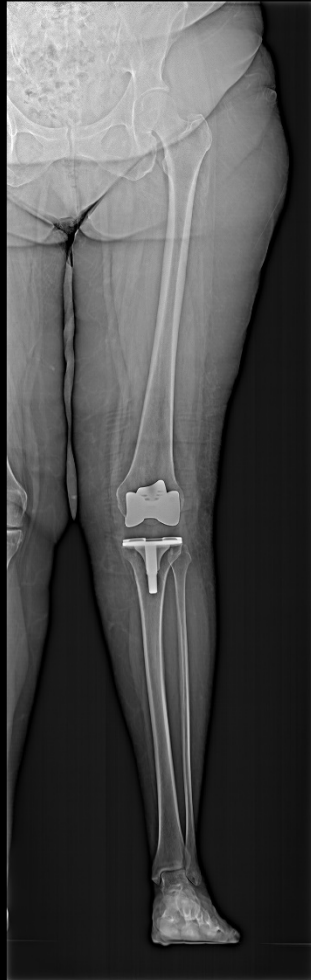A long leg examination was required for postoperative documentation to evaluate the position of the prosthetic elements.



¹ Option, True2scale Body Scan is pending 510(k) clearance and is not yet commercially available in the US.

The products/features (mentioned herein) are not commercially available in all countries. Their future availability cannot be guaranteed.

Multitom Rax True2scale Body Scan¹ Settings



Study ID 5aad078

True2scale Body Scan in one plane using **upright XL** protocol

| | |
|-----------------------------|-----------------------------------|
| <i>Scan range</i> | 102 cm |
| <i>Scan time</i> | 7 sec |
| <i>Tube voltage</i> | 117 kV |
| <i>Current time product</i> | 462 mAs |
| <i>Dose area product</i> | 592 $\mu\text{Gy}\cdot\text{m}^2$ |

¹ Option, True2scale Body Scan is pending 510(k) clearance and is not yet commercially available in the US.

The products/features (mentioned herein) are not commercially available in all countries. Their future availability cannot be guaranteed

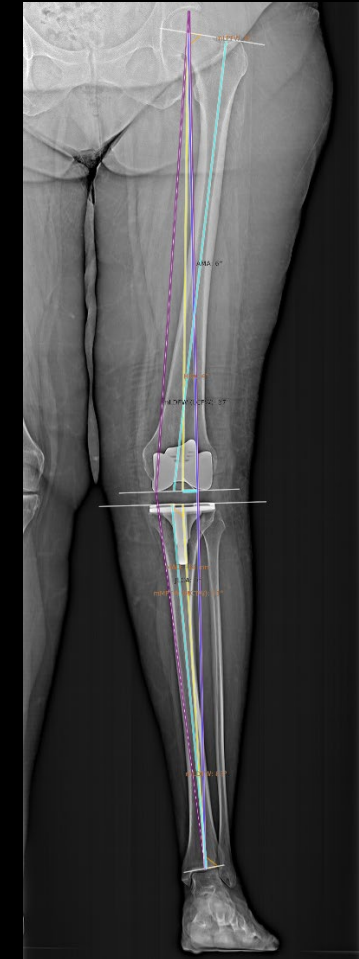
Multitom Rax True2scale Body Scan¹

Diagnostic findings

True2scale Body scan of the full leg was done with the patient in a weight-bearing position. To evaluate postoperative control, the mechanical and anatomical axes of the lower extremity were measured:

- The mechanical axis of the lower extremity corresponds to the purple line from the center of the femoral head to the center of the ankle joint.
- The yellow lines are the femoral mechanical axis, which runs from the head of the femur to the intercondylar notch of the distal femur, and the tibial mechanical axis, which extends from the center of the proximal tibia to the center of the ankle.
- The femoral and tibial anatomical axes are represented by the blue lines.

The measurements showed no abnormalities, so no additional treatment or therapy was needed.



Study ID 5aad078

¹ Option, True2scale Body Scan is pending 510(k) clearance and is not yet commercially available in the US.

The products/features (mentioned herein) are not commercially available in all countries. Their future availability cannot be guaranteed.



“True2scale Body Scan offers a comparable image impression to conventional ortho examinations with good image contrast and good spatial resolution.”¹

Frank Schellhammer, MD

Krankenhaus der Augustinerinnen, Cologne, Germany

¹ The statements by Siemens Healthineers customers described herein are based on results that were achieved in the customer's unique setting.

Since there is no “typical” hospital and many variables exist (e.g., hospital size, case mix, level of IT adoption) there can be no guarantee that other customers will achieve the same results.



The products/features (mentioned herein) are not commercially available in all countries. Their future availability cannot be guaranteed. True2scale Body Scan (option) is pending 510(k) clearance and is not yet commercially available in the US.

Results from case studies are not predictive of results in other cases. Results in other cases may vary.

Dr. Frank Schellhammer is employed by an institution that receives financial support from Siemens Healthineers for collaborations.