



White paper

Contrast-enhanced Ultrasound Imaging

ACUSON Sequoia ultrasound system

David P. Duncan, Ph.D.
Michele Baillie, B.Sc., RDMS, RDCS
Siemens Medical Solutions USA, Inc., Ultrasound Business Area
Issaquah, Washington

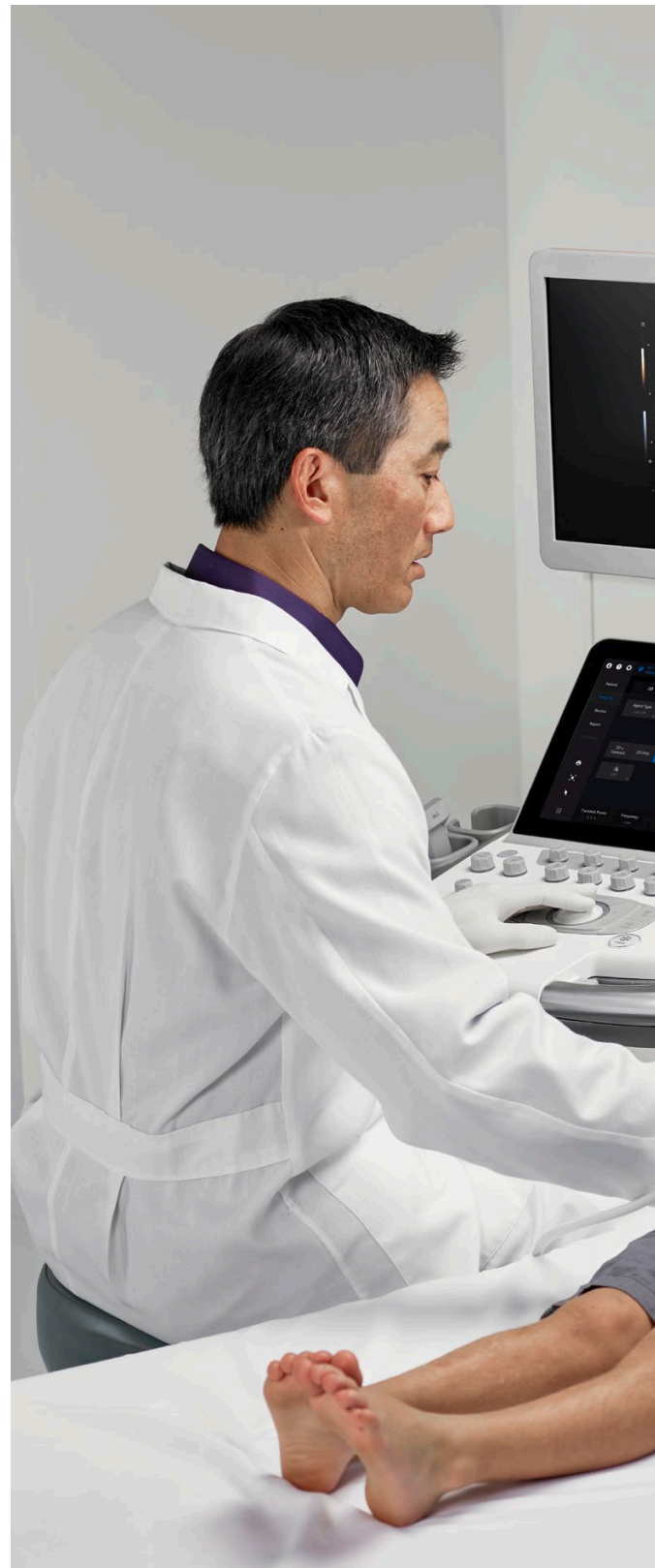siemens-healthineers.com/sequoia

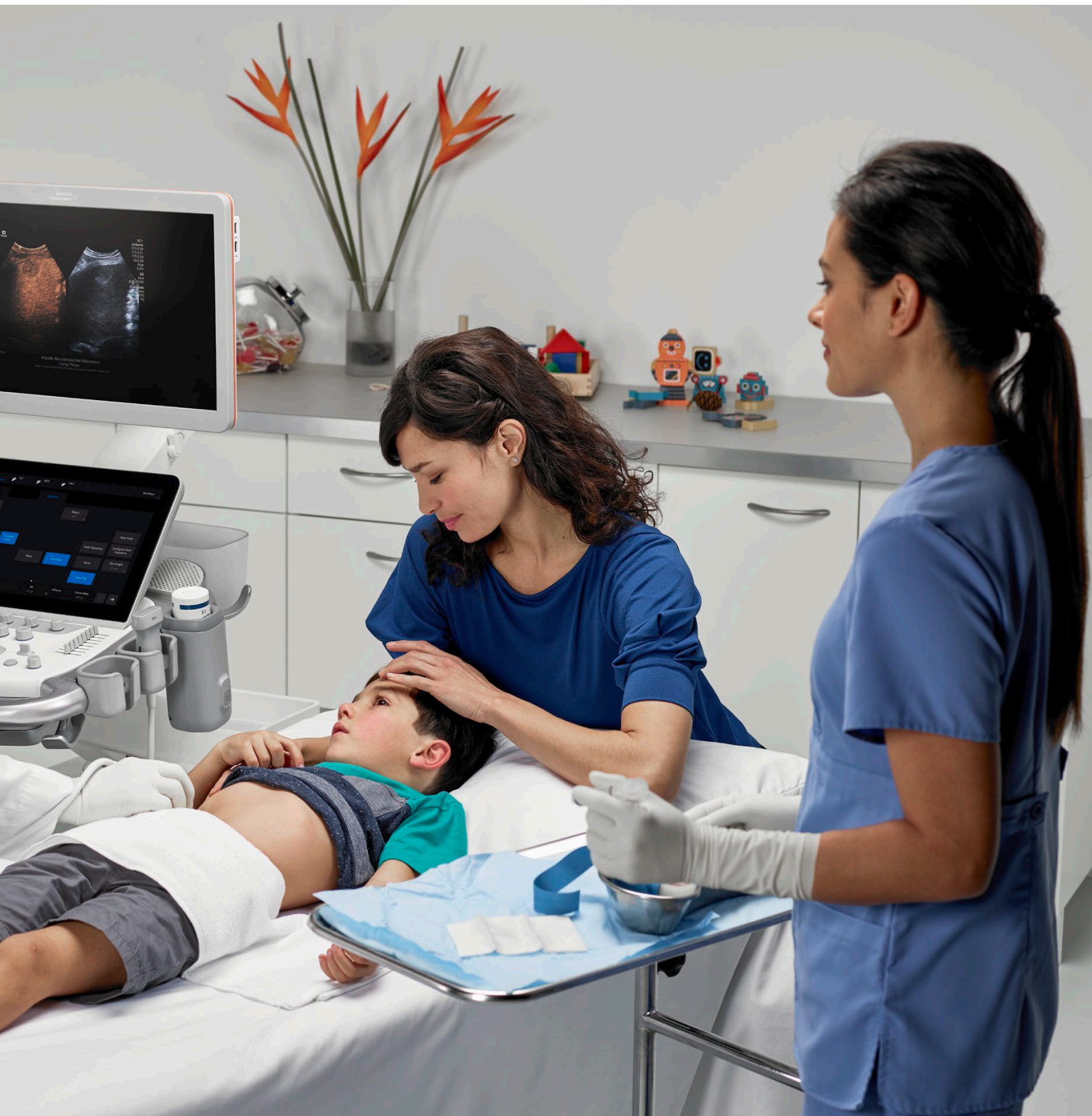Introduction

The ACUSON Sequoia ultrasound system with BioAcoustic imaging technology provides an integrated user experience with detailed and information-rich images that dramatically improves the way ultrasound is performed today. The general imaging system was developed in response to one of the most prevalent challenges in ultrasound imaging – the ability to image different sized patients with consistency and clarity.

Benefits

- A fast, fully-focused B-mode image from near field to far field
 - Unique and patented technologies that allow the ACUSON Sequoia system to virtually eliminate color flash artifacts
 - The DAX transducer can penetrate as deep as 40 cm to deliver unprecedented images at depth without compromising diagnostic quality
 - Improved contrast-enhanced ultrasound (CEUS) penetration and bubble longevity
-





CEUS and Microbubbles

Contrast-enhanced ultrasound (CEUS) imagery has become a mainstay in the modern clinic. Ultrasound contrast agents are low-cost, non-toxic, and can provide a safer alternative to the contrast agents of other medical imaging modalities. When used effectively, they can be a valuable tool in helping clinicians make a diagnosis and strengthen diagnostic confidence.

The BioAcoustic imaging technology of the ACUSON Sequoia system improves CEUS bubble longevity. CEUS uses microbubble-based contrast agents to improve the visualization and assessment of lesions. With the ACUSON Sequoia system, the view time of contrast agents is significantly longer, allowing clinicians more time to scan for additional incidental lesions during their examinations and with up to twice the sensitivity.¹

Ultrasound contrast agents consist of very small bubbles with diameters of 1–10 microns known as “microbubbles.” Microbubble contrast agents are introduced into the bloodstream with a bolus injection or as a continuous intravenous (IV) infusion. Their small size allows them

to travel throughout the body’s entire cardiovascular system but still keeps them intravascular. To help the microbubbles persist long enough in the body for clinical utility, they are filled with a high molecular-weight gas and typically come with an elastic shell to slow their breakdown.

When microbubbles are present in the body and are imaged with ultrasound, they help a clinician visualize the blood and blood-perfused areas of the body by differentiating them from non-blood-filled areas with enhanced image contrast. The higher frame rates typical in ultrasound allow clinicians not only to see blood-filled areas of the body with great detail, but also to better observe the hemodynamics of wash-in and wash-out perfusion patterns with greater fidelity.

When a microbubble is isonified by an ultrasonic pressure wave, the bubble resonates, and its size rapidly oscillates. The frequency at which a bubble resonates is tied closely to its nominal resting size. When a bubble is resonating, it generates very strong acoustic backscatter (or echoes)

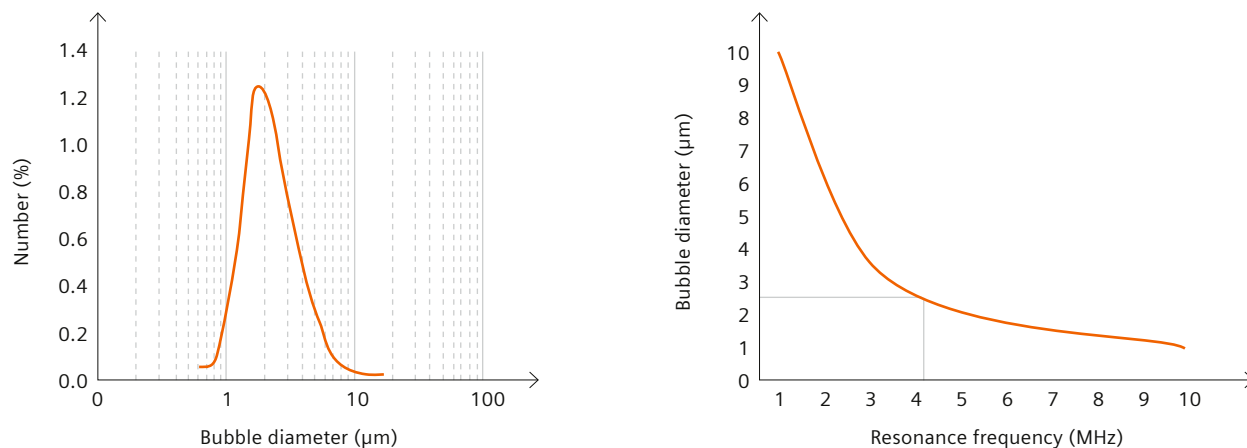


Figure 1: Bubble size distribution of a typical vial of SonoVue contrast agent and a bubble resonance frequency chart. It is important for clinicians to consider the resonance of the agent when deciding on the transducer and imaging frequency range for a given clinical application so as to set imaging expectations appropriately.²

that make the microbubble show up brightly in the final reconstructed ultrasound image. As such, most commercially available contrast agents consist of a wide distribution of bubble sizes to allow them to cover a large number of potential clinical applications and imaging frequencies. A typical distribution of SonoVue® bubble sizes and associated resonance frequency chart is shown in Figure 1.

Microbubbles not only resonate near their natural frequency when exposed to ultrasound, but also generate multiple, higher harmonics when resonating. (Figure 2)

This generation of higher harmonics occurs even at relatively low ultrasound pressures, i.e. low transmit power levels. The fact that microbubbles generate harmonics at low transmit power levels is a key factor that drives a majority of current ultrasound agent imaging techniques. This will be discussed in more detail in the next section.

Eventually, microbubbles will break down, but they also can be prematurely destroyed. Intentional microbubble destruction is caused most often by setting high transmit power levels. Higher transmit pressures cause microbubble shell disruption and bubble destabilization, speeding up the bubble's destruction process. While high transmit power is the most common reason for bubble destruction, it also could be caused by other biological processes.

Injecting small gas bubbles into a circulatory system may seem potentially hazardous, but extensive clinical experience has shown that the tiny given volume of air or gas (under 200 μ l) is not dangerous, and the safety of microbubbles compares well to that of conventional agents used in other modes of imaging.³ Although microbubbles originally were designed to enhance conventional ultrasound scanning, their use and evolution has opened up powerful applications and improved patient results.

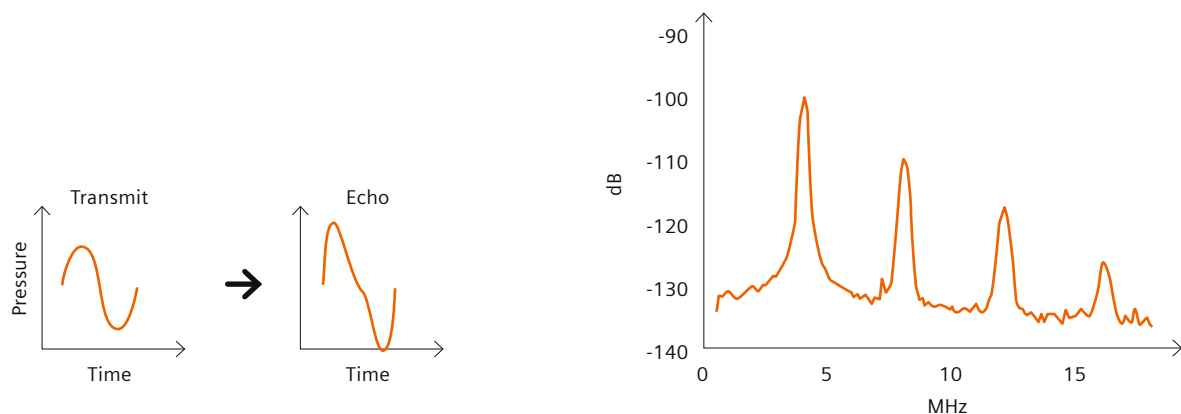


Figure 2: Microbubbles generating multiple, higher harmonics when resonating.

CEUS Technology

As microbubbles generate strong harmonics at lower power levels and tissue generally does not, most contrast agent imaging techniques exploit this property to image only the echoes from the contrast agent while simultaneously suppressing those from tissue.

Another term that is frequently used when describing the echoes from the contrast agent is “non-linear.” A non-linear echo is any echo that was generated from a contrast bubble or tissue that does not scale proportionally with the transmitted ultrasound level.

Conversely, any echo that does scale with the transmitted ultrasound level is termed “linear.”

The most common and effective known technique to isolate and separate non-linear echoes from linear ones is contrast pulse sequencing. A contrast pulse sequence is a series of scaled (or weighted) transmissions and receptions that work to isolate, enhance, and detect the non-linear responses from bubbles and attempt to reject any linear echo contributions from tissue – which as mentioned previously, does not generate many harmonics at low power levels.

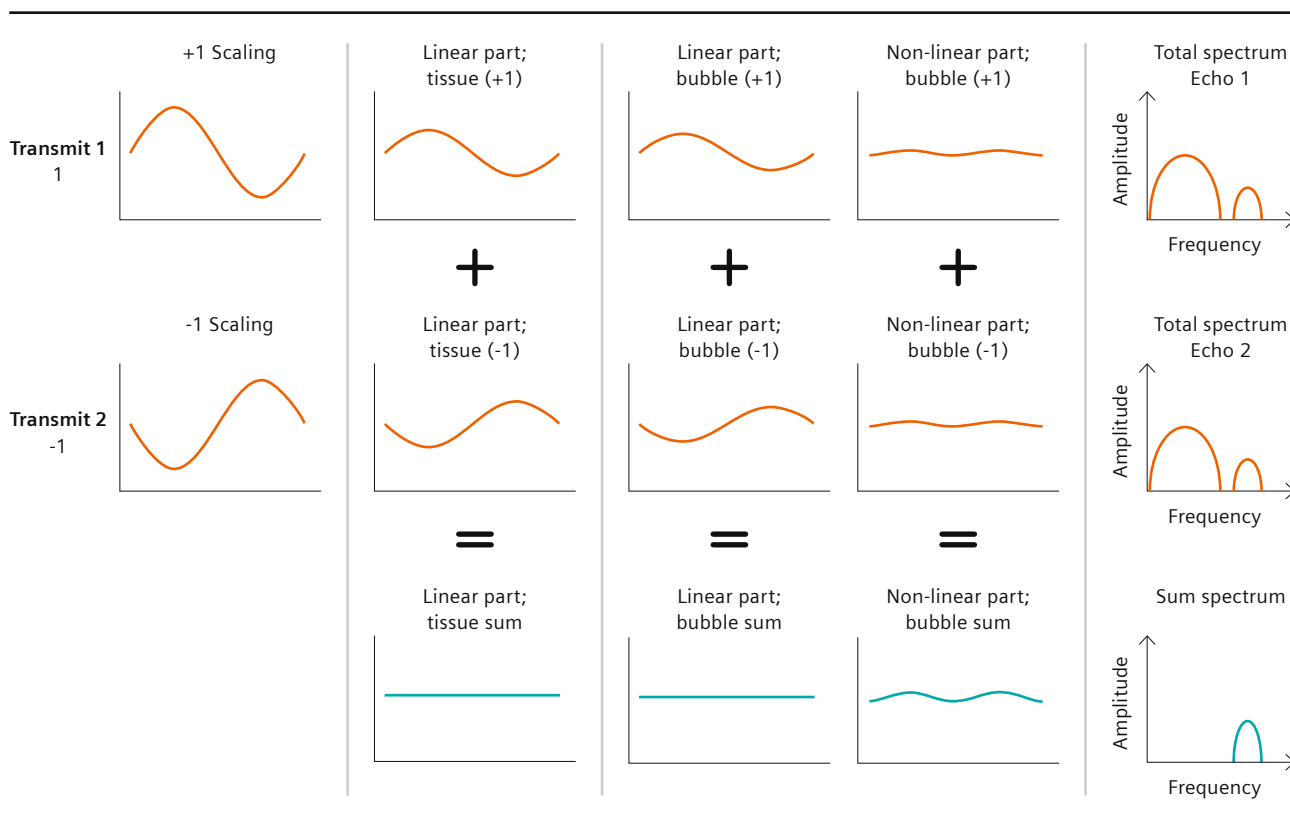


Figure 3: Contrast Harmonic Imaging (CHI) sequence

In ultrasound, the contrast pulse sequencing technique is most often used in two difference sequence arrangements – a 2-pulse sequence and a 3-pulse sequence.

Contrast Harmonic Imaging (CHI)

The 2-pulse sequence exploits the second harmonic during imaging. The pulse arrangement has signals with a transmission weight of [1, -1] and reception weights of

[1, 1]. This sequence is designed to suppress signals in the fundamental frequency band while amplifying the second harmonic content in each echo. The negative transmission weight can be viewed as changing a pulse's phase by 180 degrees, thus this type of contrast pulse sequencing is commonly known as "phase inversion". On Siemens Healthineers products that support contrast agent imaging using this type of pattern sequence, the technology is known as Contrast Harmonic Imaging, or CHI. (Figure 3)

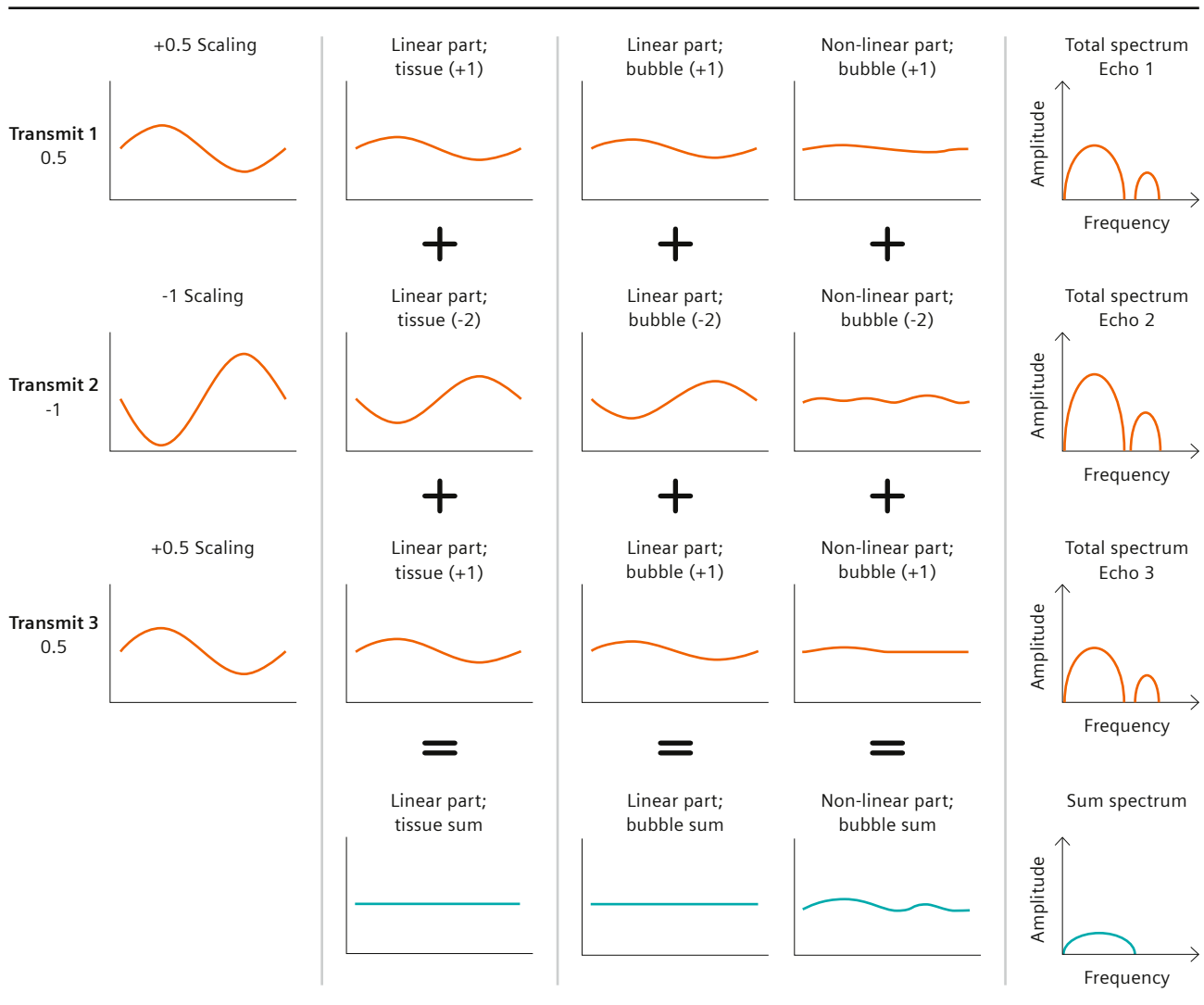


Figure 4: Contrast Pulse Sequencing (CPS) arrangement

Contrast Pulse Sequencing (CPS)

The 3-pulse sequence technique, which is used most commonly on Siemens Healthineers platforms, uses the fundamental imaging mode and a combination of power and phase modulation. The pulse sequence in this instance has transmission weights of [0.5, -1, 0.5] and receive weights of [1, 1, 1]. In this sequence, using the composite method of power and phase modulation, is designed to reject tissue signals within the echo while enhancing any non-linear components found within the fundamental frequency band from the contrast agent. In Siemens Healthineers products which support this type of patterned sequence, the feature takes its name from the actual technique and is known as Contrast Pulse Sequencing or CPS. (Figure 4)

To form a typical contrast agent image, the transducer array forms focused-beam transmissions and builds up the image in a line-by-line format, scanning the focused beam transmissions across the surface of the array. For any given line of the contrast image, a single contrast pulse sequence is fired (one transmission after the other) until all the echoes from the sequence have been captured. Once the echoes are collected, they are processed and then displayed on the output image. (Figure 5)

As each contrast pulse sequence has a different number of firings per image line, each sequencing method will differ also in its overall performance and in any trade-offs. The next section discusses important metrics of what makes a superior contrast agent image.

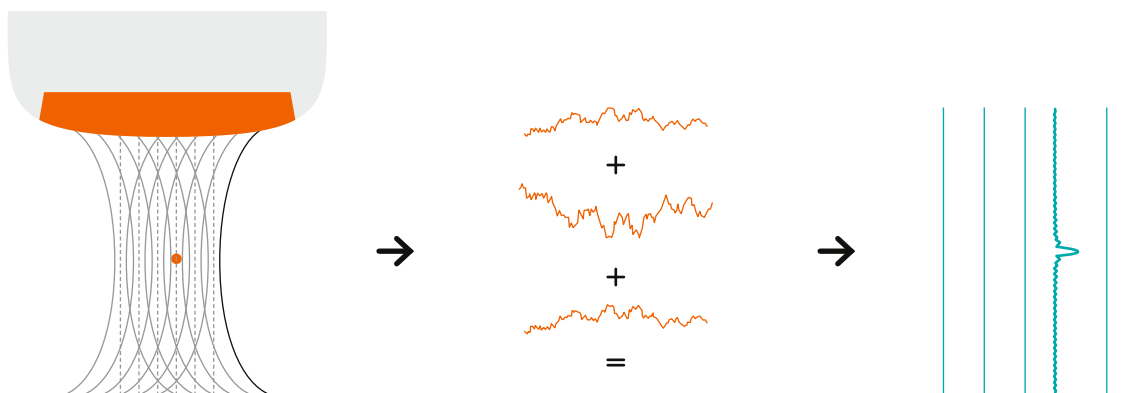


Figure 5: Image formation process in conventional CEUS imaging. The transducer scans in a line-by-line format (left image). At each line position, multiple firings are transmitted – in this example, a 3-pulse sequence is used in the middle CPS image. The 3 echoes from each firing at a given line position are summed (center image) and then laid onto the output image (right image).

Performance Metrics – Contrast-Agent Sensitivity and Specificity

The quality of any ultrasound contrast agent imagery from a given system and its imaging technique is typically measured by two metrics: contrast agent sensitivity and specificity.






Within the context of contrast agent imaging, sensitivity is a measure of how small of a contrast signal can be detected and imaged by a given imaging system or technique. A system or technique is said to have high sensitivity when it can detect and image very tiny concentrations of a contrast agent. A system with higher sensitivity also can mean that a given agent can be imaged for longer periods of time.

Contrast specificity is a measure of how well contrast agent signals are separated from tissue and other clutter when imaged by a given system or technique. As any tissue-generated echoes that are not effectively suppressed are intermixed and visualized along with the echoes from the contrast agent, this makes it more

difficult to be confident in microbubble detection and localization. When a system suppresses tissue and other clutter well, the contrast agent is better visualized and clinical decisions are made with more confidence.

The contrast agent imaging techniques (CPS and CHI) differ slightly in sensitivity, specificity, detail resolution, and frame rates (Figure 6). Since CPS uses more pulses and images at the fundamental frequency band (typically wider), it tends to enjoy higher sensitivity than CHI. Also, since there is generally few non-linear echoes generated by tissue, CPS also tends to have very good specificity. These advantages, however, come with a trade-off as a CPS image will take longer to collect because the sequence is three pulses instead of two and hence will have lower frame rates. Also, CPS images at the fundamental frequency band tend to have lower detail resolution, although optimization and hardware setups may allow the results to vary.

CPS (Contrast Pulse Sequencing)

- 3-pulse, low-MI sequence (fundamental imaging mode)
- Higher specificity 
- Higher sensitivity 
- Slight increase in penetration 
- Lower frame rates 
- Lower resolution 

CHI (Contrast Harmonic Imaging)






- 2-pulse, low-MI sequence (2nd harmonic imaging mode)
- Lower specificity 
- Lower sensitivity 
- Slight decrease in penetration 
- Higher frame rates 
- Higher resolution 

Figure 6: CPS versus CHI Characteristics. Contrast agent imaging techniques (CPS and CHI) differ slightly in sensitivity, specificity, detail resolution, and frame rates.

Clinical Performance

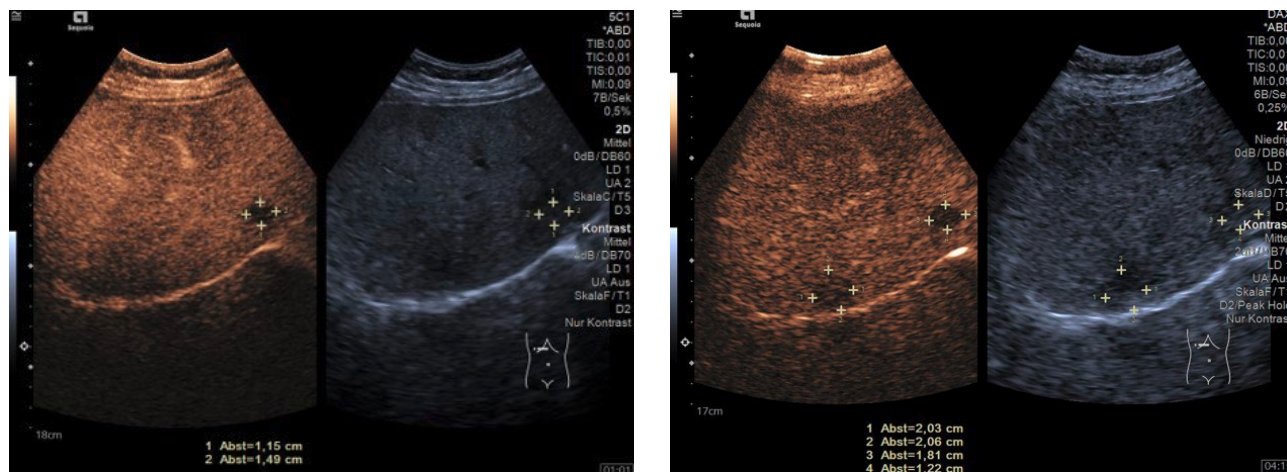


Figure 7: The DAX transducer provides a 30% improvement in penetration for imaging larger patients, thereby giving clinicians visual access to deeper areas within the liver that have not been previously seen. As shown in this example, a larger body habitus patient has been imaged with the 5C1 (left image) and the DAX (right image). While lesion detection was excellent on the 5C1, the DAX provided visualization of an additional lesion at a much deeper level – a level that conventional contrast imaging struggles to image.

The increasing prevalence of obesity in many countries^{4,5} can present a problem when evaluating technically difficult patients with ultrasound as a first-line imaging modality. Concerns about long-term effects of radiation exposure from X-ray and computed tomography (CT) scans have made the ability to image large patients more important than ever. One of the breakthroughs

introduced with the ACUSON Sequoia system is the deep abdominal transducer (DAX).

With the ability to penetrate as deep as 40 cm, DAX expands the population of patients who can be diagnosed successfully with ultrasound. The benefits extend to all imaging modes, including contrast and

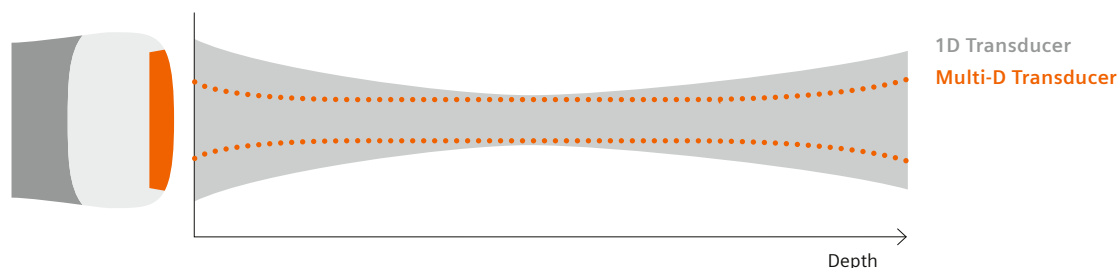


Figure 8: The advanced Multi-D beam formation of the Deep Abdominal Transducer (DAX) enables thinner slice thickness enabling imaging throughout a range of up to 40 cm.

shear wave elastography, making DAX a powerful transducer for larger and technically difficult patients.

The ACUSON Sequoia system also offers several other new transducers that take ultrasound sensitivity to a new level by using new materials and construction techniques. When coupled with high signal-to-noise ratio (SNR) signal processing, the system yields penetration improvements in harmonic imaging of up to 65% over prior systems with comparable transducer types.¹ Next-generation micro-pinless transducer connectors maintain low noise and signal fidelity and are easy to use.

InTune Coherent Pulse Formation

Key acoustic performance elements in contrast and harmonic imaging are the agile, dual-linear transmitters of the ACUSON Sequoia system. With 16-point programmability of the InTune pulse former, ultrasound pulses can be precisely tuned for superior harmonic performance and penetration on all transducers. For example, in 4.0 MHz harmonic mode, sensitivity is increased three times over previous systems through precision transmit wave shaping and higher receive sensitivity.¹ This allows harmonic imaging to be used as a default mode for most ultrasound exams, improving spatial and contrast resolution.

InTune Coherent Pulse Formation technology is also an important factor in contrast imaging, with increased tissue cancellation and maximum bubble response for higher specificity. Extremely low distortion of the transmit pulse and precise phase control achieve 10 times the acoustic fidelity of previous systems.¹

Support for a wide frequency range improves high-frequency imaging and allows third harmonics imaging on some transducers for improved near-field contrast resolution.

Another design improvement is the ability to maintain a constant and sustainable energy delivery over deep depths and with long pulses, such as those used in shear wave elastography employing acoustic radiation force impulse (ARFI) techniques. A capable transmit power supply helps overcome many limitations of conventional systems to provide uniform, consistent, acoustic energy over the field of view. This results in better contrast studies and more accurate, repeatable, and reproducible stiffness measurements.

InTune Coherent Pulse Formation technology is a key factor in improved harmonic and contrast imaging.

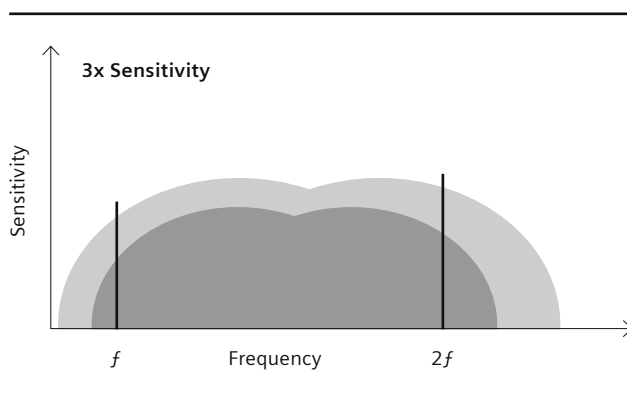


Figure 9: InTune Coherent Pulse Formation

Clinical Application

Contrast imaging Overcoming technical barriers

The enormous architectural power of the ACUSON Sequoia system can provide visualization of contrast deeper and with greater clarity than ever before. Tissue cancellation has been improved over the ACUSON Sequoia legacy 512 ultrasound system¹ transmit power supplies with high-voltage scale agility, contributing to a high linear-response rejection ratio.

Contrast sensitivity up to two times higher than the original ACUSON Sequoia legacy system allows the visualization of small vessel perfusion and in many cases the ability to visualize a diagnostic level of contrast agent for a much longer, late-phase contrast perfusion assessment.¹ This may increase diagnostic confidence by offering a differentiation of focal liver lesions using the CEUS LI-RADS algorithm.⁶ (Figure 10)

Average Contrast Sensitivity as a Function of Time
1:50000 Dose of SonoVue/Lumason

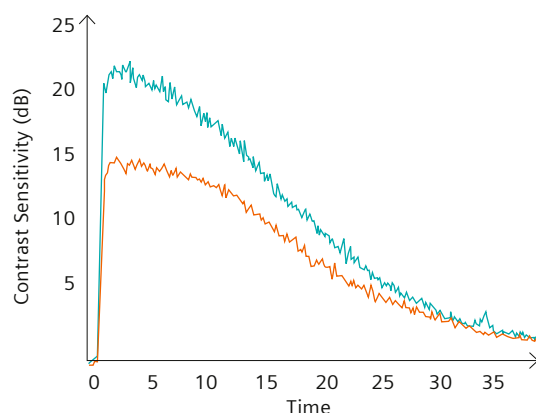


Figure 10: The ACUSON Sequoia (blue line) has approximately 6 dB (2 times) more sensitivity at depth in contrast imaging than its predecessor, the ACUSON Sequoia legacy system (orange line), in the first 10 minutes post-injection, with 10 times better tissue cancellation, potentially leading to higher diagnostic confidence.

Clinical case studies

CEUS has gained widespread global acceptance as the method of choice for sensitive visualization of blood flow. With a focus on value-based healthcare, as well as the cumulative impact of ionizing radiation for patients, CEUS offers a low-cost and well-tolerated alternative to help clinicians observe tissue perfusion, which is often a key indicator for disease states such as lesion characterization in the liver.

The following clinical case studies highlight the practical use of CEUS for the characterization of focal liver lesions. They provide technical information about the ACUSON Sequoia ultrasound system and the benefits of BioAcoustic imaging technology, which allow significantly longer bubble visualization, increased penetration in contrast imaging, and up to twice the sensitivity in contrast mode in abdominal imaging.¹

CEUS uniquely balances the sophisticated interaction between the contrast agent and the ultrasound wave. This technology harmonizes the vascularization and timing of liver perfusion, and leverages the expertise of the clinician and sophistication of the technology.

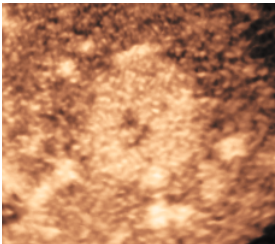
Liver

CEUS real-time characteristics

CEUS is a dynamic study that allows the user to characterize a lesion in real time by examining the wash-in and wash-out enhancement of the CEUS agent.

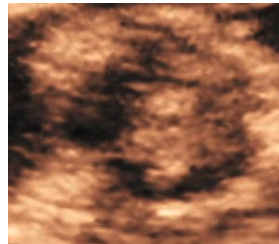
Depending on the lesion type, the wash-in and wash-out will vary. The timing of these events is critical in allowing the clinician to determine the lesion type.

Real-time assessment CEUS characteristics



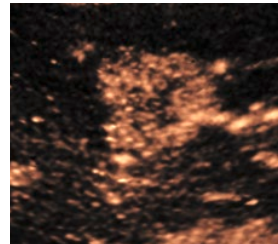
Region of interest enhancement versus surrounding tissue

- Hyper-enhanced
- Iso-enhanced
- Hypo-enhanced



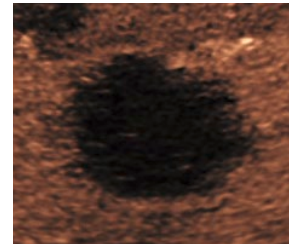
Location of contrast enhancement on initial fill

- Centrally
- Peripherally



Pattern of contrast fill within the region of interest

- Nodular/globular
- Stellate/spoke wheel



Wash-out characteristics, presence/absence

- Rapid
- Slow/weak
- Sustained enhancement

Enhancement phases of the Liver

Dual blood supply of the liver from the hepatic artery and the portal vein gives rise to three overlapping vascular phases on a CEUS exam. The timing of these phases is demonstrated in the signal intensity/time chart (Figure 11), and it has been found that liver lesions

can be characterized according to the wash-in and wash-out enhancement phases. A diagnostic algorithm was developed to map these characteristics with a positive predictive value (PPV) of malignancy vs. benignancy of more than 90%.^{7,8}

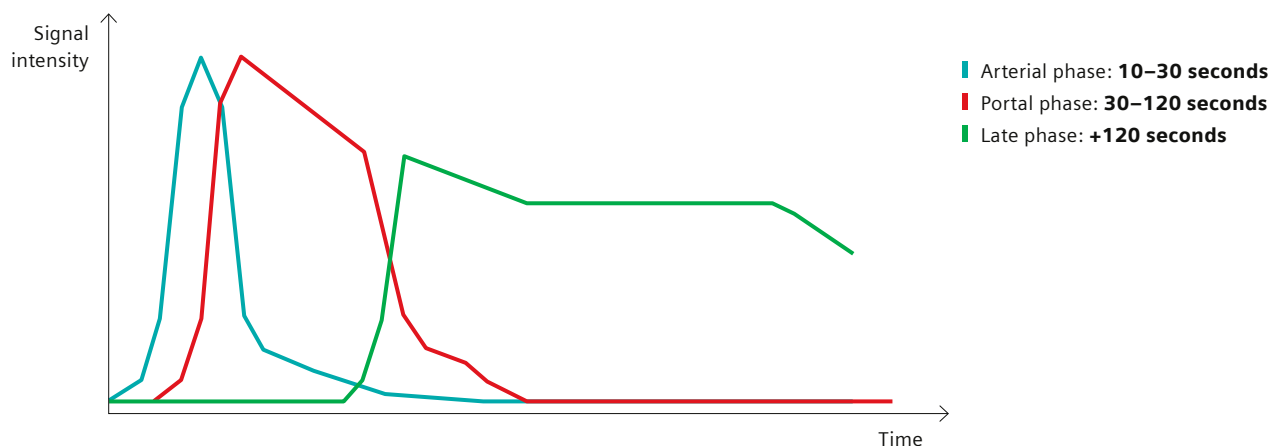


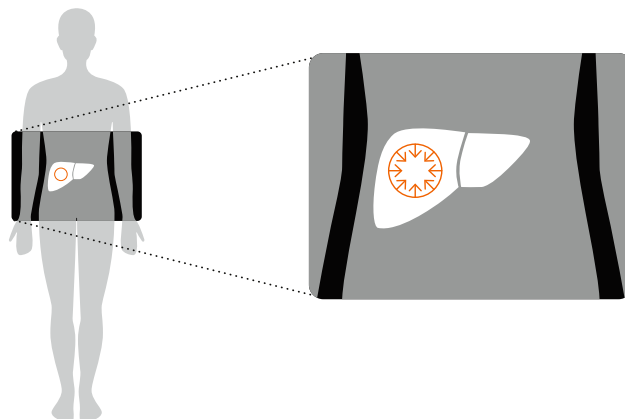
Figure 11: Demonstrates the timing of the three overlapping vascular phases on a contrast-enhanced ultrasound exam.⁸

Benign Lesion – Hemangiomas

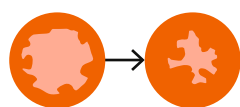
Characteristics

Hemangiomas are the most common type of benign liver lesion. They are composed of an abnormal collection of entangled vessels that usually present themselves as a well-defined hyperechoic lesion in the parenchyma.

Approximately 20–30% of hemangiomas present as atypical in appearance.¹ CEUS is an excellent complimentary exam as it can distinguish quickly the presence of hemangiomas, including the atypical type.



Flow phases



Arterial phase

- Peripheral nodular hypervascular enhancement with centripetal progression
- Globular fill pattern



Portal venous phase

- Complete or partial fill-in



Late phase

- Sustained enhancement

- Liver tissue (non contrast-enhanced)
- Enhancement

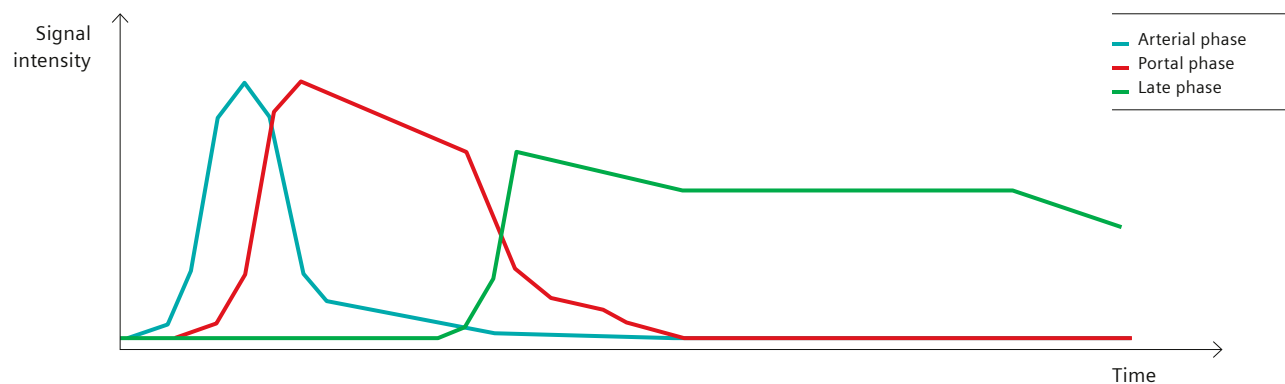
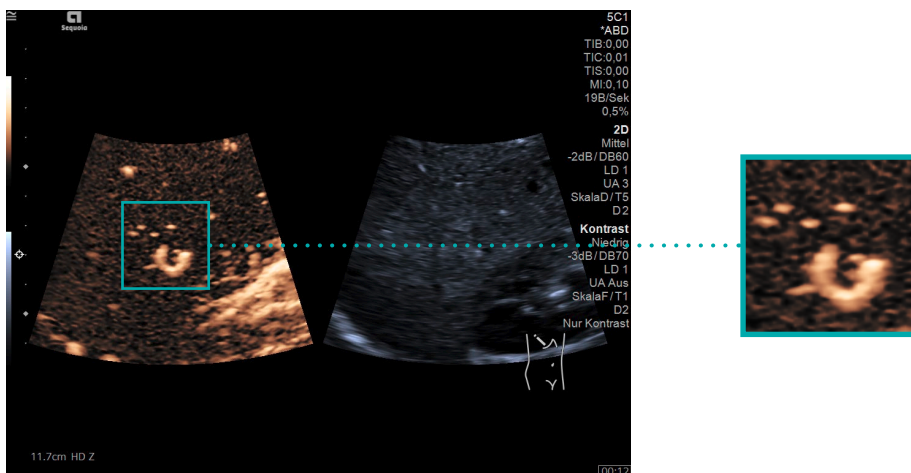


Figure 12: Demonstrates the typical ultrasound characteristics for helping to characterize hemangiomas on CEUS.

Case study

The 2D ultrasound image shows the typical appearance of a subtle hemangioma – a well-defined hyperechoic lesion with some color flow noted within it.

In the early arterial phase (12 seconds), note the centripetal fill pattern with the periphery of the mass filling first.

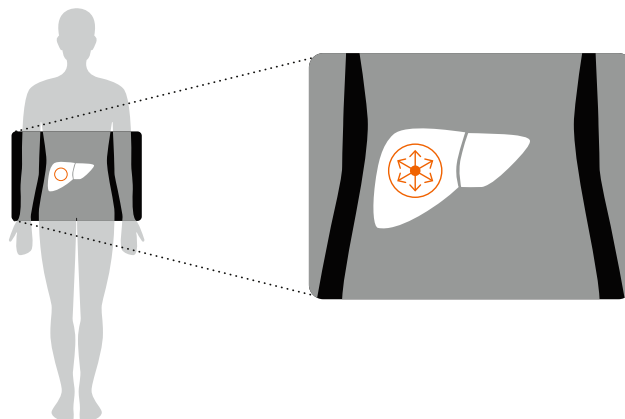


Arterial phase: 10–35 seconds

Benign Lesion – Focal Nodular Hyperplasia

Characteristics

Focal nodular hyperplasia (FNH) is the second most common type of a benign liver lesion, and is usually asymptomatic and vascular in nature. FNH is usually found incidentally and associated with young women but can be found in men as well. FNH is believed to occur as a result of a localized hepatocyte response to an underlying congenital arteriovenous malformation.⁹ There have been no reports of FNH becoming malignant, however due to the fact that FNH and a fibrolamellar variant of hepatocellular carcinoma have a similar imaging feature,⁸ CEUS is an excellent way to help distinguish between the two. Early arterial centrifugal flow (spoke-like from the center out to the periphery), sustained contrast enhancement, and the possible presence of a central scar in the late phase are classic flow characteristics of FNH.



Flow phases

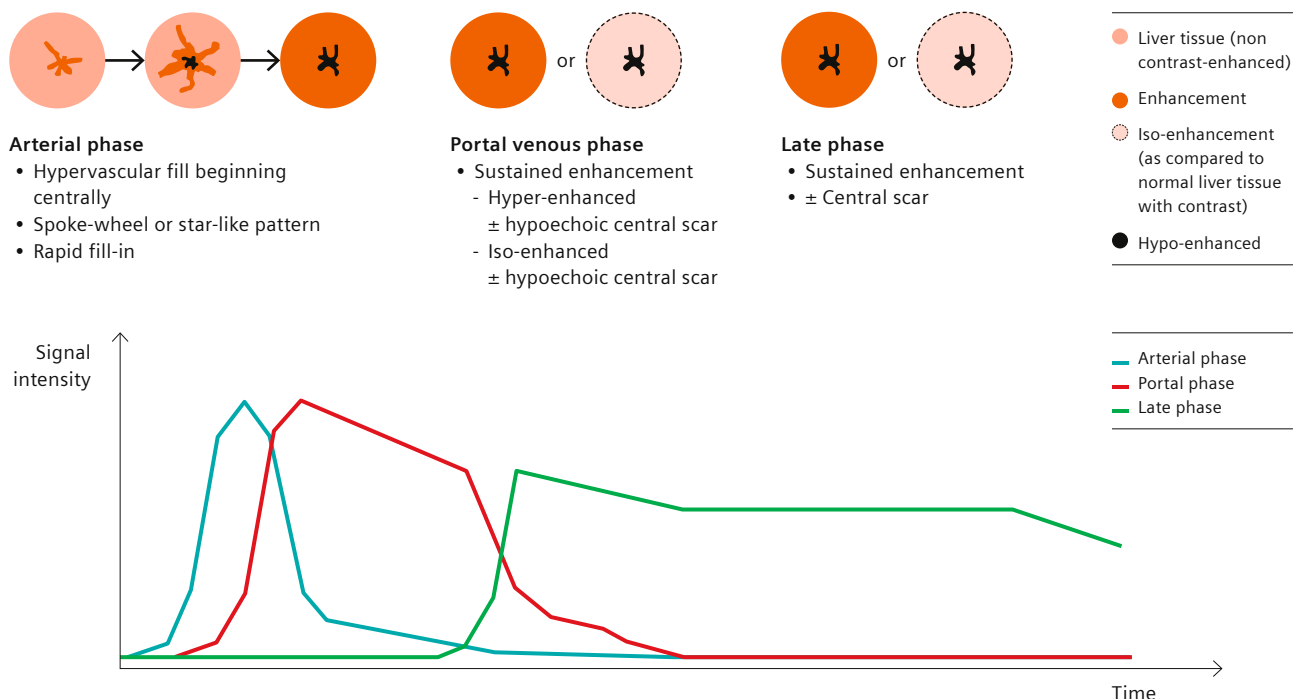
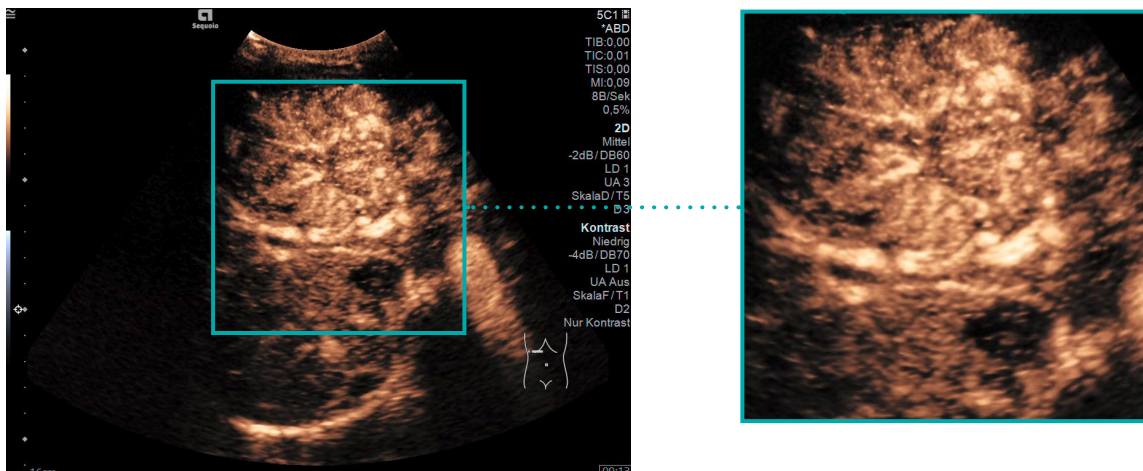


Figure 13: Demonstrates the typical ultrasound characteristics for helping to characterize FNH on CEUS.

Case study

This case demonstrates the classic appearance of FNH on CEUS. The arterial contrast phase (11–13 secs) displays the typical centrifugal (spoke-like) filling pattern of the lesion.

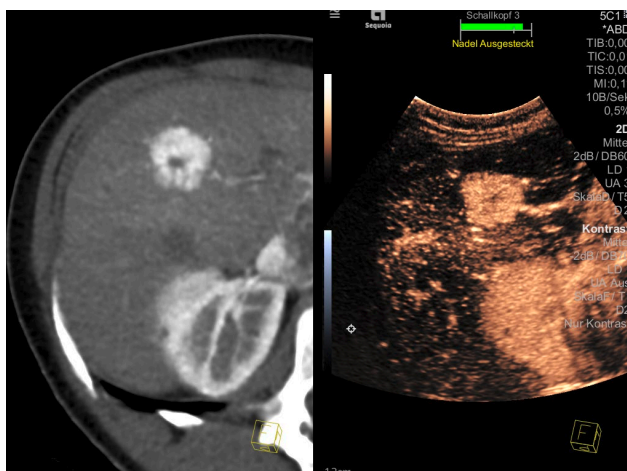


Arterial phase: 10–35 seconds

Case study

Showing how CEUS can be further enhanced by fusion imaging, these images demonstrate a lesion during the arterial phase of a CEUS exam, fused with the corresponding CT data in real time.

The arterial phase images show classic hyper-enhancement of the lesion with what appears to be a central scar and show typical CEUS characteristics of FNH.



Arterial phase: 10–35 seconds

Malignant Lesions

Characteristics

Suspicious malignant lesions typically exhibit hypervascular fill followed by wash-out. The timing of wash-out is very important in helping to determine malignancy.⁸

Non-hepatocyte in origin:

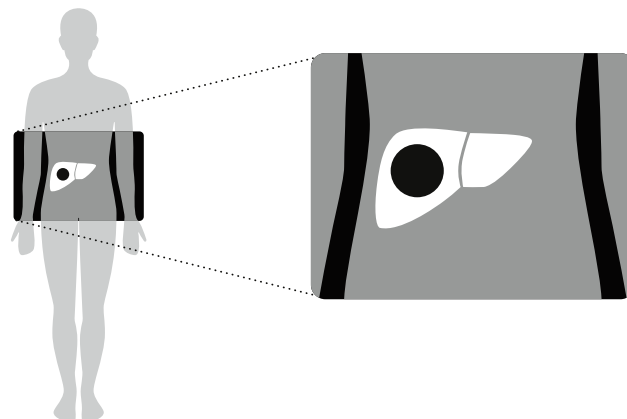
Metastasis

- Fast appearing and rapid wash-out is suggestive of metastasis

Hepatocyte in origin:

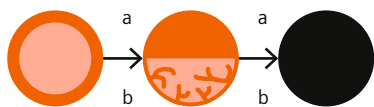
Hepatocellular carcinoma (HCC)

- Wash-out appearing late and weak is suggestive of HCC



Flow phases

Suspected metastatic lesions



Arterial phase

- Rim enhancement
- Two types of wash-in
 - a. Hypervascular with fast wash-out
 - b. Hypovascular with wash-out
- Fast wash-out can sometimes occur before the end of the arterial phase

Portal venous phase

- Wash-out (fast)

Late phase

- Wash-out

- Liver tissue (non contrast-enhanced)
- Enhancement
- Iso-enhancement (as compared to normal liver tissue with contrast)
- Weak/slow wash-out
- Wash-out

Suspected HCC lesions



Arterial phase

- Homogenous hypervascular wash-in (typical)
- Hyper-enhanced

Portal venous phase

- Hyper-enhanced or iso-enhanced prior to wash-out variation
- Typically shows wash-out which is often slow / weak

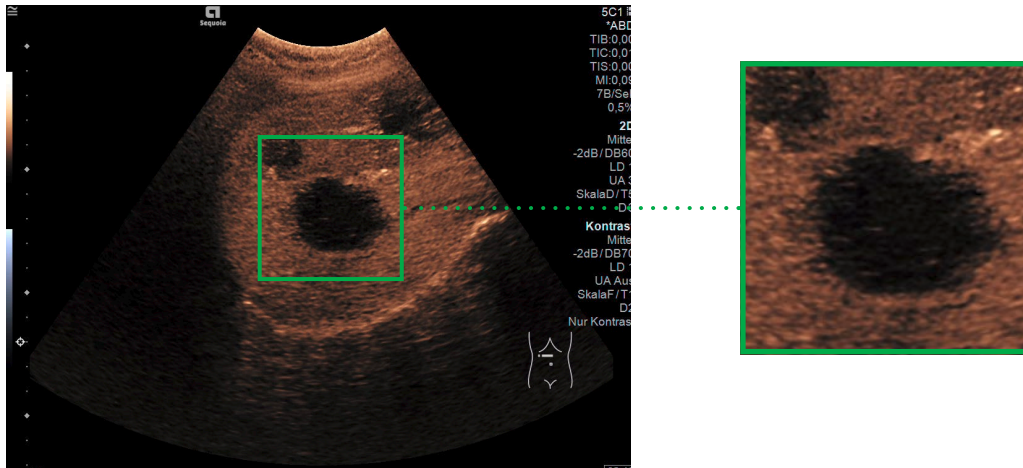
Late phase

- Wash-out (hypo-enhanced) is typical presentation
- Can have weak wash-out and very late (5+ minutes)
- Late-phase timing is key to differentiate HCC vs. Mets

Figure 14: Illustration of phases for suspected metastatic and HCC lesions.

Case study

The lesions displayed are all consistent with the classic CEUS appearance for malignant metastasis. In the largest lesion, rapid and complete wash-out is seen.



Late phase: +120 seconds

Conclusion

Microbubble ultrasound contrast agents are an important element of imaging as they provide an inexpensive, safe alternative to contrast agents of other modalities and can be a valuable tool in assisting clinicians to make a diagnosis and strengthen diagnostic confidence.

The ACUSON Sequoia ultrasound platform was built from the ground up and designed to be the best clinical tool for imaging ultrasound contrast agents. The platform provides enhanced sensitivity and specificity in contrast-agent imaging with high fidelity. This is achieved as linear InTune transmitters, cleaner power supplies, low-noise amplifiers, and innovative signal processing all work together to make the contrast-agent imaging performance the best in the market.

Providing an intuitive workflow coupled with high-end technology, the ACUSON Sequoia platform offers world-class contrast-agent imaging with unmatched contrast sensitivity and specificity. The system supports current and future advanced diagnostic capabilities with an unmatched image quality, user experience, contrast imaging, and elastography capabilities. The longevity of the imaging engine hardware and flexible upgrade path design of the computing engine ensures the integration of future diagnostic ultrasound technologies to enhance system performance and investment protection.

References

1. Data on file with Siemens Healthineers.
2. Greis, Christian. (2004). Technology overview: SonoVue (Bracco, Milan). *European radiology*. 14 Suppl 8. P11-5. 10.1007/s10406-004-0076-3.
3. Blomley, Martin J K, Jennifer C. Cooke, Evan C. Unger, Mark J. Monaghan, David O. Cosgrove. "Microbubble contrast agents: a new era in ultrasound." May 19, 2001. <https://www.ncbi.nlm.nih.gov/pmc/articles/PMC1120332/>.
4. Ezzati M et al. Worldwide trends in body-mass index, underweight, overweight, and obesity from 1975 to 2016: a pooled analysis of 2416 population-based measurement studies in 128.9 million children, adolescents, and adults. *Lancet*. 2017; 390:2627-42.
5. Seidell JC. Obesity, insulin resistance and diabetes – a worldwide epidemic. *British Journal of Nutrition* n. 2000, 83(Suppl 1):S5-S8.
6. Wilson SR, Lyshchik A, Piscaglia F, Cosgrove D, Jang H, Sirlin C, Dietrich C, Kim TK, Willmann JK, Kono Y. CEUS LI-RADS: algorithm, implementation, and key differences from CT / MRI. *Abdominal Radiology*. 2017. DOI: 10.1007/s00261-017-1250-0.
7. Wilson SR and Burns PN. An Algorithm for the diagnosis of Focal Liver Masses Using Microbubble Contrast-Enhanced Pulse Inversion Sonography. *AJR*:186 May 2006; 1401-1412 2.
8. Ham et al. 1994 Focal Liver Lesions: Characterization with Non-enhanced and Dynamic Contrast Material-enhanced MR. *Imaging Radiology* 1994; 190:417-423.
9. <https://emedicine.medscape.com/article/368377-overview>

Stand-alone clinical images may have been cropped to better visualize pathology. The products/features mentioned in this document may not be commercially available in all countries. Due to regulatory reasons, their future availability cannot be guaranteed.

Please contact your local Siemens Healthineers organization for further details.

ACUSON Sequoia, BioAcoustic, and InTune are trademarks of Siemens Medical Solutions USA, Inc.

SonoVue and LUMASON are registered trademarks of the Bracco Group.

At Siemens Healthineers, our purpose is to enable healthcare providers to increase value by empowering them on their journey towards expanding precision medicine, transforming care delivery, and improving patient experience, all enabled by digitalizing healthcare.

An estimated 5 million patients globally everyday benefit from our innovative technologies and services in the areas of diagnostic and therapeutic imaging, laboratory diagnostics and molecular medicine, as well as digital health and enterprise services.

We are a leading medical technology company with over 170 years of experience and 18,000 patents globally. With more than 48,000 dedicated colleagues in 75 countries, we will continue to innovate and shape the future of healthcare.

Siemens Healthineers Headquarters

Siemens Healthcare GmbH
Henkestr. 127
91052 Erlangen, Germany
Phone: +49 9131 84-0
siemens-healthineers.com

Legal Manufacturer

Siemens Medical Solutions USA, Inc.
Ultrasound
22010 S.E. 51st Street
Issaquah, WA 98029, USA
Phone: 1-888-826-9702
siemens-healthineers.com/ultrasound