Clinical Care Should Not Depend on Zip Code: Starting a University Radiology Department in the Countryside

Jan Borggrefe, M.D.

Department for Diagnostic Radiology, Neuroradiology, and Nuclear Medicine, Johannes Wesling University Hospital, Minden, Germany

Introduction

When I started as an advanced radiology resident at University Hospital Cologne in Germany ten years ago, I arrived at a time of major change: The radiology department was in need of modernization, and a new head had just taken over. Within just a few years, and using admirable energy and skill, he transformed the department into a highly attractive, scientifically vibrant, up-and-coming university institute.

The transformation included a comprehensive digital strategy; the in-depth implementation of cutting-edge technologies such as high-focus ultrasound and dual-energy CT; the establishment of various research groups and collaborations; the introduction of highly specialized, clinically excellent consultation hours; and the creation of a strong interventional radiology and neuroradiology department. In this wonderful, dynamic environment, I was able to develop optimally as a radiologist, neuroradiologist, and scientist. It was this experience that eventually enabled me to establish a university radiology department myself.

1 View of Johannes Wesling University Hospital

Diagnostic imaging for everyone – everywhere

In 2020, I was appointed Chair of Radiology at Mühlenkreiskliniken ("Mill County Clinics"), a 2,000-bed group of hospitals in the German countryside, far away from the big cities (Figs. 1, 2). The institution had no animal labs, no preclinical science, and no research structures on site. The comments from my colleagues were varied, but they all went in the same direction: "It looks good on paper, but what are you doing? There are only cows and mills out there and you won't find colleagues to support your project ..." Indeed, Minden and the surrounding towns are quite rural. The nearest big city is 50 miles away, and a vast nothingness yawns to the north and south. Coming

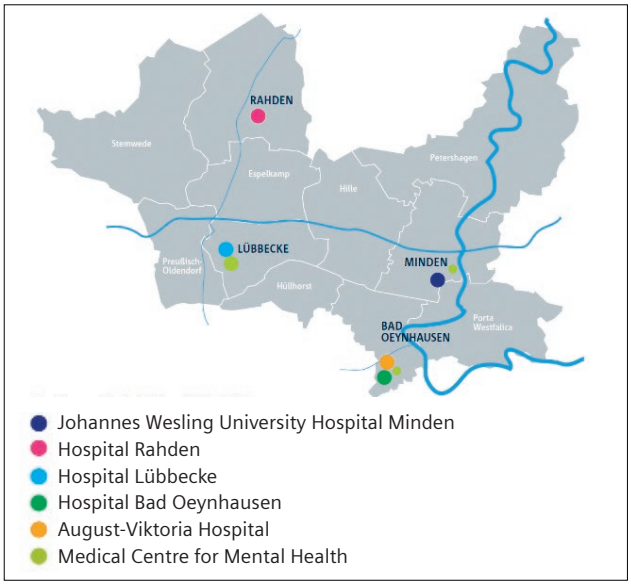

2 **The hospitals in the Mühlenkreiskliniken group**
The map gives an overview of the sites in the Mühlenkreiskliniken group (2,000 beds, 5 hospitals, and a large psychiatric hospital).

from the vibrant Rhine-Ruhr area, I sensed strong social contrasts, but also a refreshing serenity. The radiological fleet and IT status at Johannes Wesling University Hospital in Minden were somewhere between 12 and 20 years old when I started. The group's five peripheral sites that we look after were not well-perfused with doctors and were also in need of modernization. At two of the five sites, it was no longer possible to provide a radiological specialist. However, the main hospital in Minden, which has 920 beds, was rebuilt as a flagship in 2008 and became a university hospital of Ruhr University Bochum in 2016. The goal of the initiative was to train doctors "in the country for the country," in the hope that they would stay. However, a report from the German Science and Humanities Council called the new location into question again one year later, and it was also under considerable pressure to make its contribution academically.

So, after I moved to rural East Westphalia with my family and some anxiety during the COVID-19 pandemic, the site developed with a good momentum. In our network, we were able to attract several bright young radiologists, who found the rural residential location paired with an exciting department rather appealing. However, with an annual research budget of €/US$ 20,000, we didn't have much room for maneuver to make scientific developments beyond the clinical essentials.

Nevertheless, our first grant applications to Ruhr University Bochum were well-supported and they allowed us, together with the hospital, to build up our own artificial intelligence (AI) lab. With the tailwind from our previous research performance and the strategic new acquisition of radiological equipment, we were able to convince start-ups, cooperating university departments, and Siemens Healthineers to support our department. Clearly, I had considerably underestimated the interest in rural care. After all, in times of shortages of skilled workers and increasing economic challenges, it's the rural areas where the current applications of AI and telematics are really needed.

Clinically meaningful digital infrastructure

Therefore, this specific problem of ours became the core issue in the course of the first year. Thanks to our decisive digital strategy, we were given the task of working with IT and hospital management to convert the millions of euros in IT funding into clinically meaningful infrastructures. To this end, we are gradually building a hospital network for interdisciplinary clinical care and science, procuring new RIS/PACS systems and telematics infrastructure for teleradiology work across sites, and leaving room for the partner companies to codevelop solutions for these tasks. Within the first two years, we published about 30 scientific papers with our new infrastructure and thus inspired many local clinical disciplines to participate in research. Once again, it was clear that radiology offers the absolute key position in scientific work for university development when resources are limited.

Cutting-edge technology

In terms of device technology, we are not focusing on ultra-high field or pre-clinical MRI, but rather on applications that both optimize performance in everyday clinical use and offer new scientific inspiration.

We have replaced a MAGNETOM Avanto system with a 1.5T MAGNETOM Sola MR scanner and the Dot engines on the new MAGNETOM Sola have refined our workflow and have nearly halved the scan times we had with our previous 1.5T scanner (Figs. 3, 4).

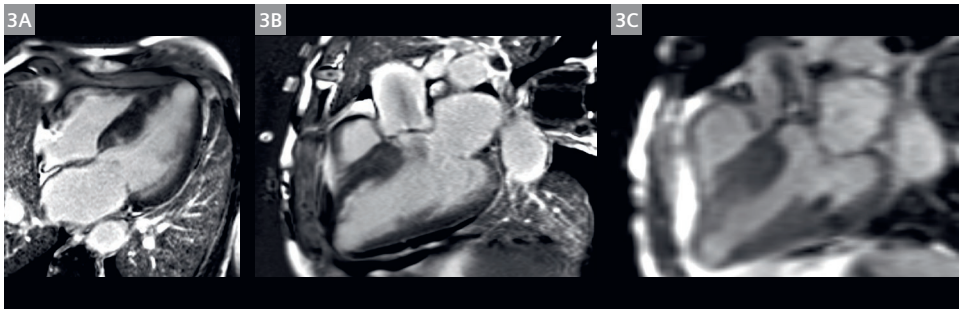

3 Cardiac amyloidosis
The Dot engines on the new 1.5T MAGNETOM Sola MR scanner have refined our workflow and have nearly halved the scan times we had with our previous 1.5T MAGNETOM Avanto system. This case shows a 90-year-old male patient with multiple late enhancing lesions, especially of the cardiac septum, due to amyloidosis **(3A)** and high-grade aortic stenosis. About 30% of patients with amyloidosis also present with aortic stenoses.

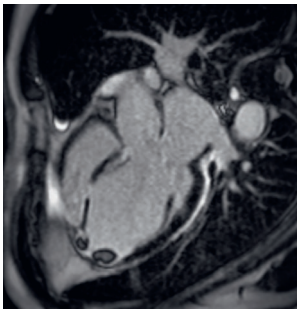

4 Cardiac scar / thrombus
A T1 post-contrast MRI scan from our 1.5T MAGNETOM Sola scanner showing a 64-year-old patient with postischemic scarring at the septum and cardiac apex, and intraventricular thrombus at the apex.

With the MAGNETOM Free.Max, a lower-field 0.55T MRI scanner, we are working on a device concept that is helium- and energy-saving[1] and, due to its low cost, has the potential to bring MRI to rural settings and even to developing countries – or maybe, as an "MRI-in-the-Box", to grocery stores in the far future. In the context of sky-rocketing energy costs, however, the scanner is also attracting interest across Germany. Currently w use our MAGNETOM Free.Max for everything except heart and mamma imaging. Here are examples of stroke imaging (Fig. 5); MR angiography (Fig. 6), and MRI for intervention planning (Figs. 7, 8).

With the new ARTIS icono angiography system, we are building a third interventional suite as a hybrid OR. We are pleased about a performance increase of over 40% with more than 1,000 interventions per year. In terms of research and specialist radiological training, we benefit greatly from having radiology, neuroradiology, and nuclear medicine all under one roof. This offers many additional development opportunities for our staff, which we supplement with a variety of collaborations, such as the establishment of an interdisciplinary ultrasound team, and rotations for resident radiologists to an external private praxis for specialization e.g., in muskuloskelettal MRI.

With photon-counting CT, we created a motivated group of residents to specialize in research as a team and, at the same time, managed to work economically with 50 to 60 patients per day. Recently, patients have begun spontaneously traveling to us from various European countries, because they appreciate the low radiation dose and quality, especially of the cardiac photon-counting examinations (Figs. 9, 10).

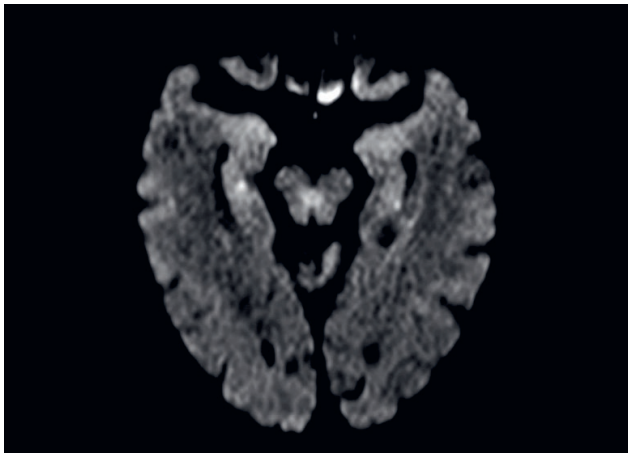

5 Bilateral transient global amnesia (TGA) in the hippocampus
The MAGNETOM Free.Max 0.55T MRI scanner has a lower signal-to-noise ratio than high-field MRI. However, it has distinct advantages in the presence of susceptibility artifacts, e.g., in lung and bone imaging, and with prostheses[2]. We primarily use the scanner for musculoskeletal, spine, thorax, and head imaging, and for patients who are scared of scanners with narrower bores. In stroke imaging, our MAGNETOM Free.Max picks up the smallest DWI lesions, such as in this case of bilateral hippocampal lesions in a patient with TGA.

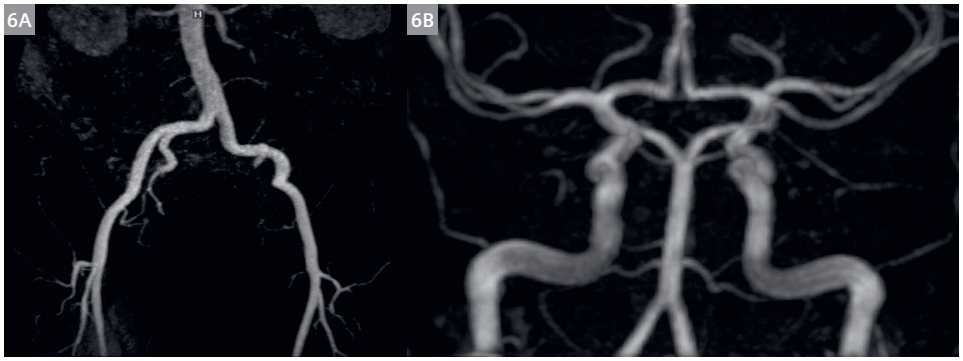

6 MR angiography using MAGNETOM Free.Max and (6A) 3D Flash (6B) TOF
The MAGNETOM Free.Max MRI allows for segmental angiographies with excellent quality. Here we show examples in the pelvic region and a time-of-flight angiography without relevant clinical findings.

[1]The statements by Siemens Healthineers' customers described herein are based on results that were achieved in the customer's unique setting. Since there is no "typical" hospital and many variables exist (e.g., hospital size, case mix, level of IT adoption) there can be no guarantee that other customers will achieve the same results.
[2]The MRI restrictions (if any) of the metal implant must be considered prior to patient undergoing MRI exam. MR imaging of patients with metallic implants brings specific risks. However, certain implants are approved by the governing regulatory bodies to be MR conditionally safe. For such implants, the previously mentioned warning may not be applicable. Please contact the implant manufacturer for the specific conditional information. The conditions for MR safety are the responsibility of the implant manufacturer, not of Siemens Healthineers.

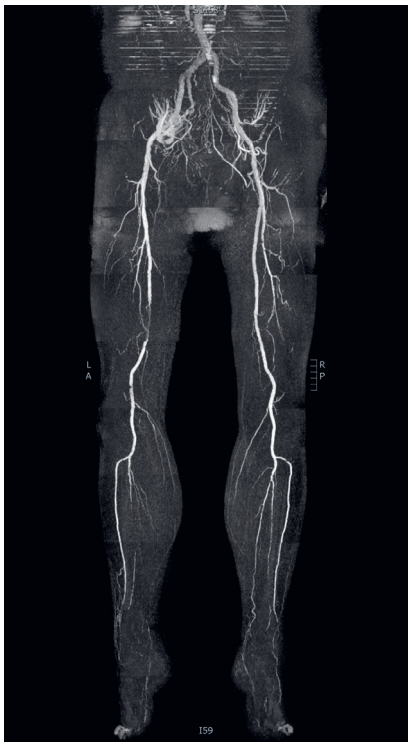

7 QISS MR angiography (MRA)
The QISS MRA enables a very decent angiography of the entire pelvis and legs within about 20 minutes and without any contrast enhancement. The sequence changes our procedures: We perform QISS for imaging before interventions in order to plan the treatment indication and pathways. The presented case shows a high-grade stenosis of the superficial femoral artery at the right side, and mid-grade stenoses of smaller vessels such as at the left anterior tibial artery. It also provides a good overview of occlusions in the lower leg vessels.

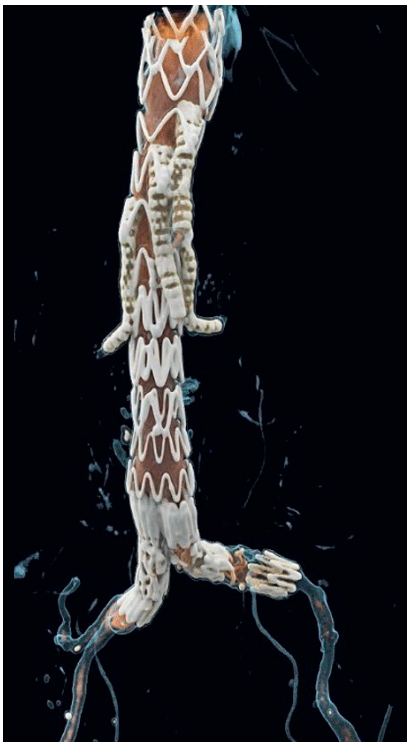

8 Imaging of a prosthesis
The excellent image quality produced by photon-counting Computed Tomography provides detailed depictions of prosthesis struts, even in small stents, so that, besides endoleaks, we have strongly improved the evaluation of implants[2].

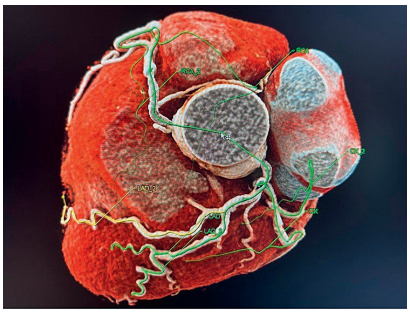

9 Autosegmentation of the heart
For me, one of the most striking *syngo*.via features is the cardiac CT platform. It comes with a fully automated and thus fast and easy-to-use heart workflow. When patients travel to us for coronary CT imaging and see their heart in Cinematic Rending and the finely cut MPI reconstruction of their coronary vessels, they usually say something like, "Wow! This is why I came here."

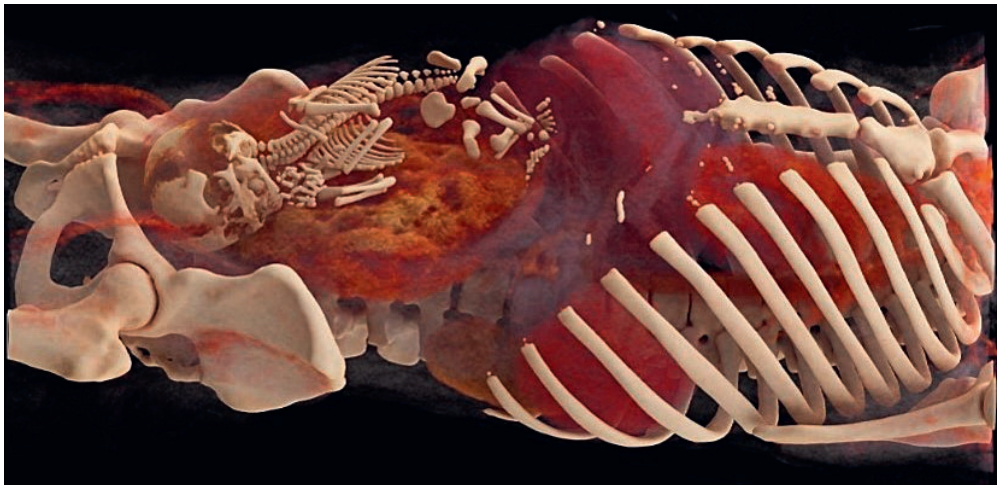

10 Photon-counting CT allows us to save radiation dose
Our current photon-counting CT protocols enable massive reductions in radiation dose throughout the body. Particularly in high-contrast investigations, we can halve contrast and radiation dose.

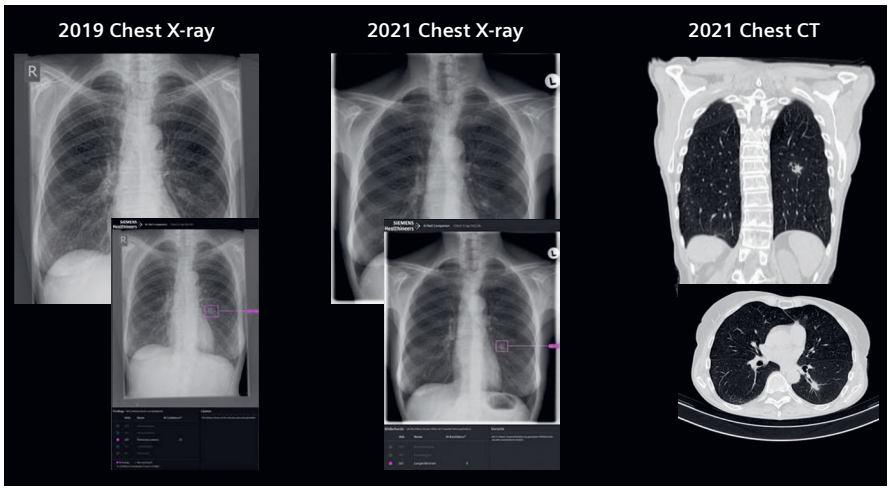

11 Thorax AI
AI-Rad Companions support CT and X-ray examinations as a cloud service for our main site in Minden and, via the central server, for the smaller sites in Lübbecke, Bad Oeynhausen, and Rahden. In this case, the AI-Rad Companion found a retrohilar lung tumor that was overlooked in both the current and earlier investigations. The high confidence (10 out of 10) of the deep learning algorithm led to a CT scan. The tumor was fully resected, and as of the 6-month follow-up, we assume the patient is cured.

Motivation by collaboration

Our scientific cooperations and visitors regularly bring fresh ideas to the site and help to set their own accents in the AI field. Working in such a state-of-the art environment and supporting product development and clinical testing is highly motivating for our staff.

Our steadily growing concept is very well received by patients and physicians alike. Instead of one application, we now receive 40 applications in response to a job ad. And while there are shortages elsewhere, we have significant overstaffing in the technologist team. This is allowing us to expand services, which is necessary: With the university outpatient clinic and outpatient specialty care, radiology in Germany is moving from being a cost center to an essential clinical business line. We filter patients for our understaffed rural university hospital, and we are on our way to doubling our services in the near future. The overall structure now also brings seven additional well-trained specialists to the small sites in Rahden, Lübbecke, and Bad Oeynhausen. Further, three high-end servers at the main site provide cloud access to a variety of AI algorithms such as AI-Rad Companions for the peripheral sites, as well as the expertise to read all this information. It is not uncommon for the AI to make essential findings that were overlooked before (Fig. 11).

Conclusion

"Clinical care should not depend on zip code". Many people agree on that – to meet this challenge, good networks, regional high-performance centers, and attractive training structures are needed to meet the demand for care in rural areas.

Contact

Jan Borggrefe, M.D., EBIR-ES, FCIRSE
Professor of Radiology / Neuroradiology
Director Department for Diagnostic Radiology, Neuroradiology, and Nuclear Medicine
Johannes Wesling University Hospital Minden / Mühlenkreiskliniken
Hans-Nolte-Straße 1
32429 Minden
Germany
Tel.: +49 571 7904601
Jan.Borggrefe@muehlenkreiskliniken.de


Jan Borggrefe, M.D., EBIR-ES, FCIRSE


The MKK team